

HOSTED BY



ELSEVIER

Contents lists available at ScienceDirect

Turkish Journal of Emergency Medicine

journal homepage: <http://www.elsevier.com/locate/TJEM>

Rare etiological causes of iliofemoral deep venous thrombosis: Reports of 2 cases



Emrah Ereren^a, Ali Kemal Erenler^{b,*}, Vedat Bakuy^a, Mustafa Omer Yazicioglu^c,
Sercan Duman^a

^a Department of Cardiovascular Surgery, Bakirkoy Dr. Sadi Konuk Education and Research Hospital, Istanbul, Turkey

^b Department of Emergency Medicine, Samsun Education and Research Hospital, Samsun, Turkey

^c Department of General Surgery, Ataturk Education and Research Hospital, Ankara, Turkey

ARTICLE INFO

Article history:

Received 1 May 2014

Received in revised form

21 June 2014

Accepted 7 July 2014

Available online 11 January 2016

Keywords:

Deep venous thrombosis

Etiology

Emergency department

ABSTRACT

Deep venous thrombosis is frequently seen in lower extremities. However, when seen in the iliac level, mass effect of an underlying pathology must be considered. In this report, we present two cases with upper region deep venous thrombosis, which had underlying pathologies of appendicitis and non-Hodgkin lymphoma.

Copyright © 2015 The Emergency Medicine Association of Turkey. Production and hosting by Elsevier B.V. on behalf of the Owner. This is an open access article under the CC BY-NC-ND license (<http://creativecommons.org/licenses/by-nc-nd/4.0/>).

1. Introduction

Deep venous thrombosis (DVT) is a disease seen more frequently in the elderly and carries with it the risk of pulmonary embolism as a serious complication. Stasis, hypercoagulability, and endothelial damage are the main factors responsible for the etiopathogenesis. This classical triad was identified by Rudolf Virchow about 150 years ago.¹ Although DVT is mostly seen in lower veins of extremities, when seen at iliofemoral level, clinical course is more serious and incidence of post-thrombotic sequela increases.² At the iliac level, intra-abdominal mass effect is rarely seen in the etiology of DVT. In this report, we present two iliofemoral DVT cases with mass effect involving a psoas abscess secondary to perforated appendicitis and a non-Hodgkin lymphoma presented to emergency department (ED).

2. Case reports

2.1. Case 1

A 66-year-old male presented to ED with swelling in the right leg, leg pain, and fever (39.5 °C) for 15 days. In the color venous

Doppler ultrasonography (USG), a subacute thrombosis beginning from the distal right iliac vein with minimal canalisation was determined. In the anamnesis, it was noted that the patient suffered abdominal pain and fever for a month before seeing a physician. The abnormal laboratory findings were as follows: WBC of 10100/mm³; sedimentation rate of 93 mm/hs; and CRP of 43 mg/L. Abdominal USG and contrasted computed tomography (CT) were performed on the patient. We saw a collection compatible with a psoas abscess of 84 × 38 mm revealing liquid with the aid of peripheric contrast. It was located near the anterior region of the right iliopsoas muscle and extended from the level of iliac bifurcation to right main femoral vein (Fig. 1). A broad spectrum antibiotic (including aerobics and anaerobics) and anticoagulant therapy was initiated, then the patient underwent surgery to drain the abscess. After laparotomy, perforated appendicitis was determined. After appendectomy and abscess drainage, low molecular weight heparin (LMWH) therapy was initiated. During venous Doppler USG 3 months later, total recanalisation was observed and the patient was considered fully recovered.

2.2. Case 2

A 64-year-old male patient was admitted to our ED due to swelling in his left leg, pain, and a growing mass on his groin for the past year. On anamnesis, no concomitant diseases were determined and his vital signs were found to be normal on

* Corresponding author.

E-mail address: akerenler@hotmail.com (A.K. Erenler).

Peer review under responsibility of The Emergency Medicine Association of Turkey.

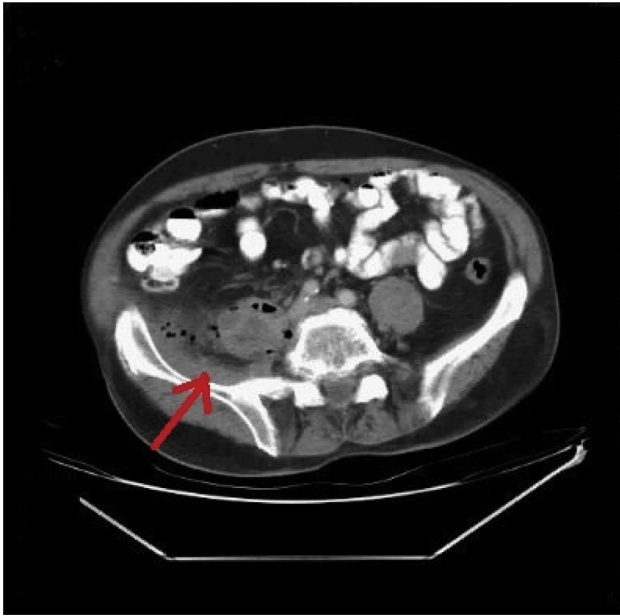


Fig. 1. A collection 84×38 mm in size revealing air and liquid fillings in it. Compatible with psoas abscess with peripheral contrast enhancement.

admission. A venous Doppler USG for DVT and a superficial tissue USG for abscess were performed. An acute venous thrombosis extending from the level of the distal left major femoral vein and a bilobulated mass lesion with high-density ingredients were determined. After USG, a CT was performed for the mass on the left inguinal region and a nodular hypodense lesion about 5 cm in size next to psoas muscle extending to pelvis was determined. In addition, a hypodense lesion of the same density (30 HU) and 72×55 mm in size was determined in the left inguinal region (Fig. 2a and b). Anticoagulant therapy (LMWH) was initiated and the mass in the inguinal region which compresses the femoral vein was removed by an excisional biopsy procedure. The result of the biopsy was non-Hodgkin lymphoma (diffuse large cell, B-cell lymphoma, LCA+, CD20+). Chemotherapy and radiotherapy was added to anticoagulant therapy. A control Doppler USG was performed after 3 months and total recanalisation was observed. The patient underwent chemotherapy regulated by an oncology clinic.

3. Discussion

Tumors and intra-abdominal abscesses resulting in iliofemoral venous thrombosis are rare in the literature. In a case report, Wong et al revealed an intra-abdominal abscess accompanying mycotic left iliac artery swelling causing pressure upon the left iliac vein in a patient with septicemia secondary to salmonella arteritis. The diagnosis could not be confirmed by the initial Doppler USG of the patient due to compression of femoral vein with mass. As the prognosis worsened, iliac DVT was confirmed by CT aortogram.³ As shown by this report, imaging of the iliac vein compression is important in patients with suspected DVT.

In a study by Maksimovic et al, 91 patients with DVT were investigated and it was reported that 5 of them had sarcoma, 2 had metastatic sarcoma, 1 had lymphoma, 2 had femoral artery aneurysm, and 2 had popliteal artery aneurysm. This study also revealed 10 patients with signs of DVT. These patients' diagnoses were not confirmed radiologically, but instead were given diagnoses of pseudo-DVT. In one patient, a psoas abscess was determined, and in another, a gluteal abscess was determined.⁴

Psoas abscess is rarely seen and there are only a few studies in the literature about psoas abscess complicated with DVT. In a study in 2007, it was reported that a total of 24 patients were determined as secondary retroperitoneal abscess due to perforated appendicitis between the years 1955 and 2005. It was also reported that none of these patients presented with classical signs and symptoms of appendicitis.⁵ In another case report presenting femoro-popliteal DVT secondary to left psoas abscess, the difficulty of diagnosing a psoas abscess before clinical use of CT was emphasized.⁶

In the literature, it was reported that a psoas abscess can be drained either surgically or percutaneously. We also planned surgery on our patient for psoas abscess. In a case report about a 14 years old boy with the signs of DVT, psoas abscess and accompanying primary piriform abscess were drained surgically. Consequently, antibiotherapy and anticoagulation was administered. This was proposed to be the best method of treatment.⁷ Another psoas abscess in a patient with signs of Phlegmasia Cerulea Dolens also underwent percutaneous drainage.⁸

The primary factors causing DVT in malignancy patients are mass effect, paraneoplastic effects, and chemotherapy. Upper extremity DVT only comprises 2% of all DVT patients.⁹ In hematologic malignancies, particularly after splenectomy, pulmonary embolism and portal vein thrombosis are reported.¹⁰ In a study by Hastaoğlu et al, after a detailed examination of 45 patients presented with

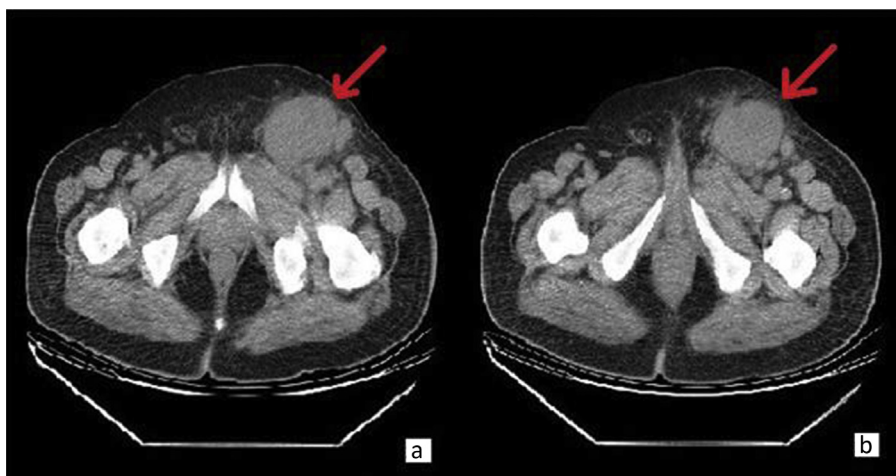

Fig. 2. a–b A well-circumscribed hypodense lesion of 72×55 mm in CT.

DVT, a new diagnosis of malignancy (in the stomach, lung and bladder) in 3 (6.6%) of the patients was made and early diagnosis contributed to the survival of these patients.¹¹

4. Conclusion

In DVT, in addition to medical therapy, elimination of mass effect is useful for early canalisation. Beyond that, early diagnosis of lymphoma and psoas abscess (which may cause mass effect) can increase the survival rate of patients with DVT.

References

1. Hwang HG, Schulman S. Respiratory review of 2013: pulmonary thromboembolism. *Tuberc Respir Dis.* 2013;75:89–94.
2. Comerota AJ, Gravett MH. Iliofemoral venous thrombosis. *J Vasc Surg.* 2007;46:1065–1076.
3. Wong OF, Lam TSK, Wong TT, Fung HT. An uncommon cause of deep vein thrombosis: mycotic aneurysm secondary to salmonella arteritis. *Hong Kong J Emerg Med.* 2009;16:255–261.
4. Maksimović Z, Cvetković S, Marković M, Perišić M, Colić M, Putnik S. Differential diagnosis of deep vein thrombosis (Article in Serbian). *Srp Arh Celok Lek.* 2001;129:13–17.
5. Hsieh CH, Wang YC, Yang HR, Chung PK, Jeng LB, Chen RJ. Retroperitoneal abscess resulting from perforated acute appendicitis: analysis of its management and outcome. *Surg Today.* 2007;37:762–767.
6. Demuren OA, Abomelha M. Psoas abscess presenting with femoro-popliteal vein thrombosis. *Saudi Med J.* 2002 Jan;23:96–98.
7. Arai Y, Kawakami T, Soga H, Okada Y. Psoas abscess associated with iliac vein thrombosis and piriformis and gluteal abscess. *Int J Urol.* 1999;6:257–259.
8. Dhaliwal J, Jayatunga A. Spontaneous psoas abscess: presenting with phlegmasia cerulea dolens. *Ann R Coll Surg Engl.* 2011;93:15–16.
9. Biyani CS, Basu S, Bottomley DM, Shah TK. Prostatic adenocarcinoma masquerading as lymphoma and presentation with axillary-subclavian vein thrombosis. *Urol Oncol.* 2003;21:3–6.
10. Mohren M, Markmann I, Dworschak U, et al. Thromboembolic complications after splenectomy for hematologic diseases. *Am J Hematol.* 2004;76:143–147.
11. Hastaoğlu O, Sokullu O, Sanioglu S, et al. The relationship between deep venous thrombosis and undiagnosed malignant disease. *Türk Göğüs Kalp Damar Cer Derg.* 2008;16:241–243.