



Journal of Coloproctology

www.jcol.org.br



Original Article

Immunohistochemical study of the canonical and non-canonical Wnt signaling pathway in colorectal carcinoma and non-neoplastic mucosa[☆]



Rodrigo Felipe Ramos^{a,*}, Celina Tizuko Fujiyama Oshima^b, Thiago Simão Gomes^b, Ana Maria Amaral Antonio Mader^c, Caio Dal Moro Alves^d, Jaques Waisberg^d

^a Department of Surgery, Universidade Federal Fluminense (UFF), Niterói, RJ, Brazil

^b Department of Pathology, Escola Paulista de Medicina (EPM), Universidade Federal de São Paulo (UNIFESP), São Paulo, SP, Brazil

^c Department of Pathology, Faculdade de Medicina do ABC (FMABC), Santo André, SP, Brazil

^d Department of Surgery, Escola Paulista de Medicina (EPM), Universidade Federal de São Paulo (UNIFESP), São Paulo, SP, Brazil

ARTICLE INFO

Article history:

Received 3 March 2015

Accepted 8 June 2015

Available online 8 July 2015

Keywords:

Colorectal neoplasms

Wnt proteins

Frizzled receptors

Axin signaling complex

Immunohistochemistry

ABSTRACT

Colorectal cancer is linked to several signaling pathways such as Wnt pathway. Our objective is to detect and verify the integrity of protein members of Wnt signaling pathway in colorectal carcinoma and non-neoplastic colorectal tissue. Sixty-four patients with colorectal carcinoma provided samples of colorectal neoplasia and non-neoplastic tissues, which were prepared in tissue microarray blocks and subjected to immunohistochemical analysis. The primary antibodies used were Wnt-1, Wnt-2, Wnt-5a, Frizzled-1, Frizzled-5 and axin. Immunoreexpression of Wnt-2 protein was significantly lower in colorectal tumor tissue and axin protein immunoreexpression was significantly higher in tumor tissue. There was no significant difference in the expression of Wnt-1, Wnt-5a, Frizzled-1 and Frizzled-5 proteins in both tissues. The higher expression of Wnt-2 protein in non-neoplastic colorectal tissue suggests the participation during the hyperproliferative stage of colorectal mucosa. The increased axin protein immunoreexpression in colorectal tumor suggests a decrease in the formation of the β -catenin destructor complex.

© 2015 Sociedade Brasileira de Coloproctologia. Published by Elsevier Editora Ltda. All rights reserved.

Estudo imunistoquímico da via de sinalização canônica e não canônica da proteína Wnt em carcinoma colorretal e em mucosa não neoplásica

RESUMO

O câncer colorretal está ligado a várias vias de sinalização, como a via Wnt. Nosso objetivo é detectar e verificar a integridade das proteínas da via de sinalização Wnt no carcinoma

Palavras-chave:

Neoplasias colorretais

[☆] Study carried out at the Interdisciplinary Surgical Science Post-Graduation Program, Escola Paulista de Medicina (EPM), Universidade Federal de São Paulo (UNIFESP) in the Laboratory of Experimental Molecular Pathology, Department of Pathology.

* Corresponding author.

E-mail: rofelippe@terra.com.br (R.F. Ramos).

<http://dx.doi.org/10.1016/j.jcol.2015.06.002>

2237-9363/© 2015 Sociedade Brasileira de Coloproctologia. Published by Elsevier Editora Ltda. All rights reserved.

Proteínas Wnt
 Receptores frizzled
 Complexo de sinalização da axina
 Imunoistoquímica

colorretal e no tecido colorretal não neoplásico. Sessenta e quatro pacientes com carcinoma colorretal forneceram amostras de neoplasia e tecidos não neoplásicos, que foram colocadas em blocos de tissue microarray e submetidas à análise imuno-histoquímica. Os anticorpos primários utilizados foram Wnt-1, Wnt-2, Wnt-5a Frizzled-1, Frizzled-5 e axina. A imunexpressão da proteína Wnt-2 foi significativamente menor no tecido tumoral e a imunexpressão da proteína axina foi significativamente superior no tecido do tumor. Não houve diferença significativa na expressão de Wnt-1, Wnt-5a, frizzled-1 e nas proteínas Frizzled 1 e 5 em ambos os tecidos. A maior expressão de Wnt-2 da proteína no tecido colorretal não neoplásico sugere a participação desta proteína durante o estágio de hiperproliferação da mucosa colorretal. O aumento da imunexpressão da proteína axina no tumor colorretal sugere uma diminuição na formação do complexo de destruição da proteína β -catenina.

© 2015 Sociedade Brasileira de Coloproctologia. Publicado por Elsevier Editora Ltda.

Todos os direitos reservados.

Introduction

Worldwide, colorectal cancer (CRC) is the third most common malignancy in men and the second most common in women.¹

In the lower portion of the crypts of Lieberkühn, there are stem cells that are responsible for the proliferation, differentiation and self-renewing of the colon epithelium.² The maintenance of the stem cell compartment and the transition from proliferation to differentiation are regulated by Wnt cell signaling receptors (Wingless and wnt-related protein).³

The Wnt pathway acts during embryogenesis in vertebrates and invertebrates and in the regulation of cellular proliferation, differentiation and apoptosis.⁴

Frizzled, LRP (low-density lipoprotein receptor-related protein) 5 and LRP 6 are participating receptors in the canonical Wnt signaling pathway, inducing stabilization of the β -catenin protein in the cytoplasm. This regulation of stability is mediated by the APC (adenomatous polyposis coli) tumor suppressor gene through a complex of proteins that also includes, axin, GSK3 (glycogen synthase kinase 3) and CK1 (casein kinase 1), which form the so-called destructor complex of β -catenin. Axin/ β -catenin interaction is an important control point for the Wnt pathway that plays a role in tumor genesis.⁵ The increase in the pool of β -catenin in the cytoplasm by Wnt stimulation occurs due to blocking of the destructor complex by the Disheveled (Dsh) protein, mediating the transcription of Wnt target genes in the nucleus.⁶ Deletions or mutations in the axin gene have been observed in various tumor types, including CRC and hepatocellular carcinoma.⁷

The non-canonical pathway is a generic term for all Wnt signaling pathways that promote transcription that is not mediated by β -catenin⁸ and is activated by Frizzled receptors independently of the activation of LRP 5 and LRP 6.

The canonical pathway has received considerable attention over the years due to its essential role in the homeostasis of the colon epithelium and in the genesis of CRC. However, the mechanisms of action of the non-canonical Wnt signaling pathway in CRC are not yet completely understood.⁹

In mammals, 19 types of Wnt proteins have been described.⁹ Some Wnt proteins such as Wnt-3 and Wnt-1 can activate both the canonical pathway and the non-canonical pathway, while others, such as Wnt-5a protein, appear to be

specific to the non-canonical pathway.⁸ Frizzled receptors can receive signals from one or more proteins of the Wnt pathway, such as the Frizzled-5 receptor, which receives signals from both the canonical pathway (Wnt-2) and the non-canonical pathway (Wnt-5a).¹⁰

In CRC, Wnt-1 and Wnt-2 proteins are considered stimulators of carcinogenesis,^{11,12} whereas the Wnt-5a protein appears to have tumor suppressor characteristics.¹⁰ However, the real role of Frizzled receptors in colorectal carcinogenesis remains obscure.¹³

Identification of regulatory proteins involved in the Wnt pathway offers opportunities to develop new therapies directed at CRC^{14,15} using monoclonal antibodies against therapeutic targets such as the Wnt-1 and Wnt-2 proteins and for the axin protein and Frizzled receptors.¹⁶ De Almeida et al.¹⁷ showed that a soluble biological receptor was capable of blocking the autocrine Wnt signal in vitro, and experiments in mice showed no signs of toxicity after several weeks. He et al.¹⁸ developed a monoclonal antibody capable of blocking the Wnt-1 protein and observed increased apoptosis in CRC cell lines. Although still in phase I, these studies have already demonstrated that the use of the Wnt signaling pathway as a possible therapeutic target is promising.

The aim of this study was to investigate the canonical and non-canonical pathways of Wnt signaling in colorectal carcinoma and adjacent non-neoplastic colorectal mucosa through the immunexpression of Wnt-1, Wnt-2, Wnt-5a, Frizzled-1, and Frizzled-5 and axin proteins.

Method

Samples

This study was approved by the Research Ethics Committees of the participating institutions. The study was conducted using samples from 64 patients with CRC who underwent curative or palliative surgery. Thirty-four (53%) patients were men and 30 (47%) were women. The median age was 69.2 (range, 41-94 years). Colorectal tissue samples were obtained from 64 patients who underwent surgery for CRC and were divided into two groups: group A – tissue samples from CRC; and group

B – tissue samples obtained from non-neoplastic colorectal mucosa located 10 cm cranial to the tumor.

Histopathological analysis

Tissue samples from CRC and non-neoplastic colorectal tissues were fixed in 10% formalin and embedded in paraffin blocks for histological analysis. Conventional histological sections were prepared from each block at 3- μ m thick. All of the slides were stained with hematoxylin-eosin (HE) and reviewed by a pathologist for confirmation of the diagnosis. To characterize the histology, the histological grade of the malignancy according to the International Classification of Diseases for Oncology (ICD-O) was used.

In the HE-stained slides, the surgical margins and best-preserved areas most representative of the tumor were marked to obtain the cylinder used in TMA (tissue microarray). Areas of necrosis, hemorrhage and areas with low cellularity were excluded. Next, the blocks were separated to verify the quality and quantity of the tissue to be used and to mark the areas for biopsy. The TMA blocks were prepared using a Beecher device (Beecher Instruments, Silver Spring, MD, USA).

Immunohistochemistry

For immunohistochemical studies, the streptavidin-biotin technique (LSAB-DakoCytomation, CA, USA) was used. The polyclonal antibodies used were as follows: Wnt-1 (G-19) (goat) (R&D Systems, Minneapolis, MN, USA), Wnt-2 (H-20) (goat) (R&D Systems, Minneapolis, MN, USA), Wnt-5a (goat) (R&D Systems, Minneapolis, MN, USA), Frizzled-1 (F-13) (goat) (R&D Systems, Minneapolis, MN, USA), Frizzled-5 (L-12) (goat) (R&D Systems, Minneapolis, MN, USA) and axin (H-98) (rabbit) (1:100 Santa Cruz Biotechnology Inc., CA, USA). All of the antibodies were used at a 1:100 dilution.

For immunohistochemical studies, 4- μ m thick histological sections were prepared according to previously described techniques.¹⁹ Incubation with the antibodies was performed in a moist incubation chamber at 4 °C for at least 16–18 h (overnight). After three washes in PBS buffer pH 7.2–7.6, further incubation was performed with biotinylated secondary antibody (LSAB-DakoCytomation, CA, USA) in a humidified chamber at room temperature for 30 min. Subsequently, the same process was performed using a streptavidin-biotin-peroxidase kit (LSAB-DakoCytomation, CA, USA). Washes were then made with PBS buffer pH 7.2–7.6, and the color was developed with liquid DAB (DakoCytomation, CA, USA) at room temperature for 5 min. After washing in running water for 3 min, counter-staining was performed using Harris hematoxylin for 1 min. The sections were dehydrated in 3 absolute ethanol baths and 3 xylene baths and then mounted with cover slips using Entellan resin (Sigma Chemical Co., Saint Louis, MO, USA) for analysis in an optical microscope.

The immunoreactivity of the Wnt-1, Wnt-2, Wnt-5a, Frizzled-1, Frizzled-5 proteins and axin was analyzed based on the proportion of the number of positive cells (percentage of positivity) and the intensity of immunostaining according to a standardized scale. The percentage of positive cells or positivity was classified as follows: zero=less than

5% immunostained epithelial cells of the lesion; 1=5–25%; 2=26–50%; 3=51–75%; and 4=more than 76% immunostained epithelial cells in the lesion. The intensity of immunoe-expression was evaluated as follows: 0=negative; 1+=weak; 2+=moderate; and 3+=strong. The final score was calculated by multiplying the score of the percentage of positivity by the score for the reaction intensity. The final score was classified as reduced expression (score value between 0 and 8) or strong expression (score value between 9 and 12).²⁰

All of the slides were analyzed by two independent examiners considering only the degree of immunostaining and without access to or knowledge of the anatomopathological data. In cases of discrepancy in the evaluation, the slides were re-evaluated, and a consensus evaluation was obtained.

Clinical and anatomopathological data

The following clinical and anatomopathological data were collected from the medical records of the patients: clinical characteristics (age, gender, ethnicity), macroscopic tumor characteristics (location, appearance, size), microscopic characteristics (lymph node invasion, degree of cellular differentiation, and venous, lymphatic and neural infiltration), TNM²¹ classification, presence of synchronous metastases, and tissue immunoe-expression of the antibodies used (percentage of positivity and intensity of immunoe-expression).

Statistical study

Quantitative results were reported as the median and standard deviation. Qualitative data were described according to the frequency of distribution. Associations between a protein's positivity and the clinicopathological characteristics of interest were evaluated using Fisher's exact test. The level of significance adopted was 5% ($p \leq 0.05$). Statistical analysis was performed using SPSS software version 15.0 (The Predictive Analytics Company, Chicago, IL, USA).

Results

Fifty-nine patients (92.2%) underwent curative surgery, and 5 patients (7.8%) underwent palliative surgery. The CRC was located in the colon in 40 patients (62.5%) and in the rectum in 24 patients (37.5%). Neoadjuvant therapy was administered in 10 patients (15.6%), all of whom had rectal carcinoma. The average size of a colorectal neoplasm was 5.2 (range, 0.5–12 cm). The size of the lesion in its largest diameter was >5 cm in 43 patients (67.1%) and \leq 5 cm in 21 patients (32.8%). Lymph node metastasis was detected in 31 cases (48.4%), while 33 patients (51.6%) had lymph nodes free of any compromising neoplasm. Venous vascular invasion was observed in 21 patients (32.8%), lymphatic vascular invasion in 24 patients (37.5%) and neural invasion in 12 patients (18.7%). In relation to the degree of cellular differentiation, 11 cases (17.2%) were classified as well-differentiated carcinomas, 51 cases (79.7%) as moderately differentiated and 2 cases (3.1%) as poorly differentiated. The CRC had infiltrated superficially (T1 + T2) into the intestinal wall in 18 cases (28.1%) and had infiltrated deeply (T3 + T4) in 46 cases (71.9%). Simultaneous

Table 1 – Frequency of immunoreactivity scores of non-neoplastic colorectal tissues and colorectal carcinoma.

Protein expression	NNCRT		CRC		p value
	Strong	Weak	Strong	Weak	
Wnt-1	3/53 (5.6%)	50/53 (94.4%)	2/58 (3.4%)	56/58 (96.6%)	1.00
Wnt-2	19/60 (33.3%)	41/60 (66.7%)	10/62 (16.1%)	52/62 (83.9%)	0.05
Wnt-5a	0	49/49 (100%)	0	58/58 (100%)	0.28
Frizzled-1	4/52 (7.7%)	48/52 (92.3%)	3/42 (7.2%)	39/42 (92.8%)	0.70
Frizzled-5	0	50/50 (100%)	0	61/61 (100%)	0.35
Axin	13/49 (26.5%)	26/49 (73.5%)	34/61 (55.7%)	27/61 (44.3%)	0.04

NNCRT, non-neoplastic colorectal tissue; CRC, colorectal carcinoma; p value obtained with Fisher's exact test.

metastases in the liver and/or other locations were observed in 14 cases (21.9%). Relapse occurred in 13 patients (20.3%), and 12 patients (18.7%) died. The average follow-up time was 19.1 months (range, 3–36 months).

Immunoexpression of the Wnt-1 protein in non-neoplastic colorectal tissue and colorectal carcinoma showed no significant difference ($p = 1.0$). Immunoexpression of the Wnt-2 protein in colorectal carcinoma was significantly lower ($p = 0.05$) than in non-neoplastic colorectal tissue (Table 1 and Fig. 1). Immunoexpression of the Wnt-5a protein in non-neoplastic colorectal tissue and colorectal carcinoma showed no significant difference ($p = 0.28$) between them. Immunoexpression of the Frizzled-1 and Frizzled-5 proteins showed no significant differences ($p = 0.7$ and $p = 0.35$, respectively). Axin protein immunoexpression was significantly reduced ($p = 0.039$) in non-neoplastic colorectal tissue relative to neoplastic tissue (Table 1 and Fig. 2).

Discussion

Despite the evidence on Wnt proteins and their Frizzled receptors and their participation in colorectal carcinogenesis, the interactions and regulatory mechanisms of these proteins are not completely understood.²² Several mutations in oncogenes,

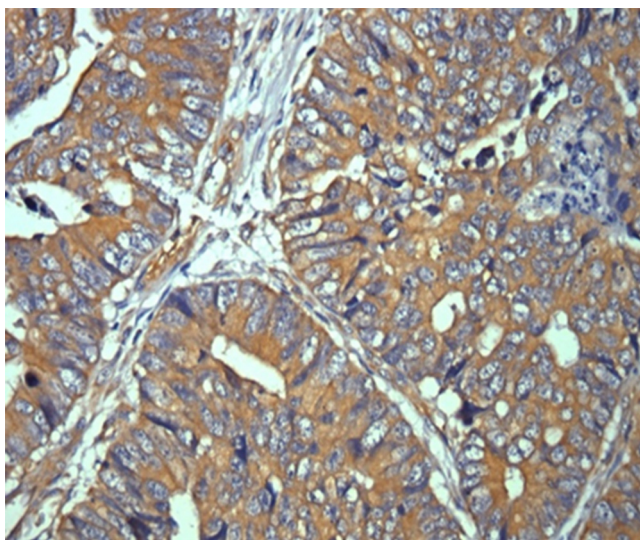


Fig. 1 – Photomicrograph of colorectal carcinoma with positive immunoreactivity for Wnt-2 antibody in the cytoplasm of tumor cells (immunohistochemistry; 200×).

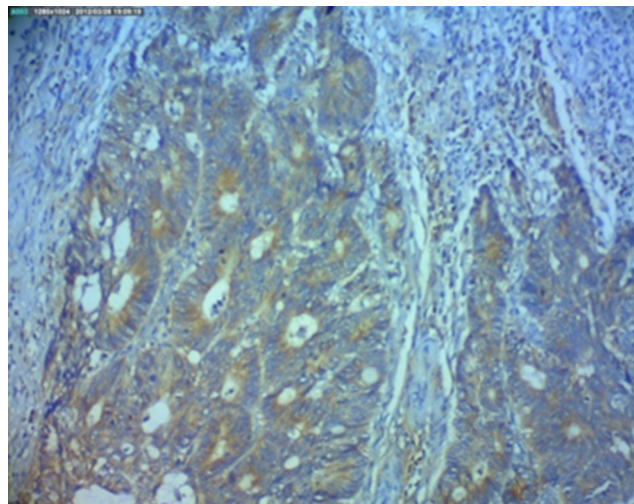


Fig. 2 – Photomicrograph of colorectal carcinoma with positive immunoreactivity antibody axin in the cytoplasm of tumor cells (immunohistochemistry; 100×).

tumor suppressor genes and other proteins that comprise the signal transduction pathways have been associated with colorectal neoplasias. However, few of these mutations, when known, occur in all tumors and at all stages of the disease.

Although Wnt-1 is one of the most studied proteins of the canonical Wnt signaling pathway, there are few studies showing the expression of this protein in colorectal tissues. Stanczak et al.²³ showed increased expression of Wnt-1 protein in normal colorectal mucosa and decreased expression of this protein in tumor tissue. Holcombe et al.¹¹ found abundant expression of Wnt-1 protein in normal mucosa and colorectal tumor tissue. In the present study, no significant difference was found when the expression of Wnt-1 in non-neoplastic colorectal tissue was compared with colorectal tumor tissue. These conflicting results could suggest that other mechanisms may be involved in colorectal carcinogenesis in addition to the activation of Wnt-1 protein.

Wnt-2 protein is an important inducer of the Wnt canonical signaling pathway.²² Other authors^{11,12} have shown little or even the absence of expression in normal colorectal mucosa but increased immunoexpression in colorectal tumor tissue. The current study showed strong expression of Wnt-2 protein in non-neoplastic colorectal tissue and reduced expression in tumor tissue.

Of the proteins involved in the non-canonical Wnt signaling pathway, Wnt-5a protein appears to have tumor-suppressor behavior primarily for its ability to inhibit the canonical Wnt signaling pathway and reduce the pool of β -catenin protein in the cytoplasm.¹⁰ Dejmek et al.²⁴ showed that expression of Wnt-5a is associated with an increased five-year survival in patients with Dukes' stage B CRC. Previous studies^{11,22} using RT-PCR found Wnt-5a protein expression in normal cell lines, particularly at the base of the crypts, but not in CRC tissues. The present sampling, however, found markedly reduced expression of Wnt-5a protein in both neoplastic and non-neoplastic colorectal tissues. This fact can be explained by the use of non-neoplastic tissues from the same patients as controls because it has been demonstrated that loss of Wnt-5a gene stimulates the canonical Wnt signaling pathway in patients with CRC.²⁵ Dejmek et al.²⁴ suggested that expression of Wnt-5a protein in patients with CRC seems to be associated with the early stages of neoplasia, a result different from the findings of the present study in which the majority of patients were in the more advanced stages of CRC.

The interaction of Wnt proteins with Frizzled receptors is considered crucial to the understanding of Wnt signaling, both in embryogenesis and in development of tumors.¹⁹ Despite intensive research into the Wnt signaling pathway and the participation of its constitutive proteins,²⁶ the role of the Frizzled proteins in this condition remains unclear. Few studies have examined the expression of Frizzled receptors in colorectal tissue. You et al.²⁷ observed that the Frizzled-1 and Frizzled-2 receptors were overexpressed in dysplastic mucosa adjacent to CRC, underexpressed in normal mucosa and not expressed in neoplastic tissue. In patients with sporadic CRC, Holcombe et al.¹¹ found expression of Frizzled-1 and Frizzled-2 receptors only in patients with poorly differentiated lesions, suggesting that the regulation of the Frizzled proteins is an important step in the process of tumor invasion. In the present study, both the Frizzled-1 and Frizzled-5 receptors showed decreased expression in non-neoplastic colorectal tissue and CRC.

The axin gene acts as a tumor suppressor gene through a negative feedback system, regulating the signal responses of the Wnt signaling pathway.²⁸ Normally, axin protein reduces the levels of β -catenin in the cytoplasm. However, mutations in this gene lead to an increase in the concentration of β -catenin in colorectal tumors. Jin et al.²⁹ analyzed 54 CRC specimens from patients and found that 11% had axin gene mutations, suggesting that this change may be associated with colorectal carcinogenesis. Webster et al.³⁰ studied the axin gene in 4 different CRC cell lines and showed that mutation of this gene alters its binding capacity to the GSK3 β gene thereby preventing the formation of the destructor protein complex of β -catenin.

Thus, abnormally high levels of axin protein expression can mask a functional difference because the levels of expression of this gene tend to be low.⁵ Such an effect may explain the fact that strong expression of this protein in tumor tissue was found in this study, while reduced expression was found in non-neoplastic colorectal tissue, a finding also observed by Hughes and Brady.²⁸

Some of the differences found in the results of the current study, when compared with those found in the literature,

can be explained by factors related to the method used in the research. Most studies^{15,16,27} used an RT-PCR method, whereas the current study used an immunohistochemical method. Another important factor was the use of tissue culture cell lines for analysis in these studies. Other authors^{12,26} showed differences in the expression of proteins in neoplastic tissues of patients compared with the same tumor cell line from tissue culture. More sophisticated methods such as in situ hybridization or laser capture microdissection (LCM) could better elucidate these issues.

Thus, in the present study, different degrees of expression of Wnt, Frizzled receptors and axin proteins were found in neoplastic colorectal tissues compared with non-neoplastic tissues, findings that were also observed by other authors.^{11,12,23,26} Because the Wnt signaling pathway and APC gene¹¹ pathway act in the transformation of normal epithelium into proliferative epithelium, it is possible that most of the proteins of these pathways involved in tumorigenesis are expressed both in the tumor tissue and in the adjacent mucosa of these same tumors.

The results showing the absence of increased expression of proteins of the non-canonical Wnt pathway (Wnt-1, Wnt-5a, Frizzled-1 and Frizzled-5) suggest that this route is not fully enabled in sporadic CRC, and therefore contributes less to the genesis of CRC. However, the Wnt-2 protein, typical of the canonical Wnt signaling pathway, showed a significant difference between the levels of immunohistochemical expression in non-neoplastic colorectal tissue and tumor tissue. The higher expression of Wnt-2 protein in non-neoplastic colorectal tissue suggests the participation of the proto-oncogene Wnt-2 during the early and/or hyperproliferative stage of pre-neoplastic changes of the colorectal mucosa.

Conflicts of interest

The authors declare no conflicts of interest.

Acknowledgment

The authors thank Fundação de Amparo à Pesquisa do Estado de São Paulo (FAPESP) for financial support.

REFERENCES

1. Ferlay J, Shin HL, Bray F, Forman D, Mathers C, Parkin DM. Estimates of worldwide burden of cancer 2008: GLOBOCAN 2008. *Int J Cancer*. 2010;127:2893-917.
2. Ricci-Vitiani L, Fabrizio E, Palio E, De Maria R. Colon cancer stem cells. *J Mol Med*. 2009;87:1097-104.
3. Fevr T, Robine S, Louvard D, Huelsken J. Wnt/beta-catenin is essential for intestinal homeostasis and maintenance of intestinal stem cells. *Mol Cell Biol*. 2007;27:7551-9.
4. Moon RT. Wnt/beta-catenin pathway. *Sci STKE*. 2005;271:1-3.
5. Parveen N, Hussain MU, Pandith AA, Mudassar S. Diversity of axin in signaling pathways and its relation to colorectal cancer. *Med Oncol*. 2011;28:S259-67.
6. Lui TT, Lacroix C, Ahmed SM, Goldenberg SJ, Leach CA, Daulat AM, et al. The ubiquitin-specific protease USP34 regulates

- axin stability and Wnt/ β -catenin signaling. *Mol Cell Biol*. 2011;31:2053-65.
7. Cadigan KM. Wnt/ β -catenin signaling: turning the switch. *Dev Cell*. 2008;14:322-3.
 8. McDonald SL, Silver A. The opposing roles of Wnt-5a in cancer. *Br J Cancer*. 2009;101:209-14.
 9. Nusse R. Wnt signaling. *Cold Spring Harb Perspect Biol*. 2012;4:a011163.
 10. Topol L, Jiang X, Choi H, Garrett-Beal L, Carolan PJ, Yang Y. Wnt-5a inhibits the canonical Wnt pathway by promoting GSK-3-independent β -catenin degradation. *J Cell Biol*. 2003;162:899-908.
 11. Holcombe RF, Marsh JL, Waterman ML, Lin F, Milovanovic T, Truong T. Expression of Wnt ligands and Frizzled receptors in colonic mucosa and in colon carcinoma. *Mol Pathol*. 2002;55:220-6.
 12. Vider BZ, Zimmer A, Chastre E, Prevot S, Gespach C, Estlein D, et al. Evidence for the involvement of the Wnt 2 gene in human colorectal cancer. *Oncogene*. 1996;12:153-8.
 13. Burns CJ, Zhang J, Brown EC, Van Bibber AM, Van Es J, Clevers H, et al. Investigation of Frizzled-5 during embryonic neural development in mouse. *Dev Dyn*. 2008;237:1614-26.
 14. Ueno K, Hiura M, Suehiro Y, Hazama S, Hirata H, Oka M, et al. Frizzled-7 as a potential therapeutic target in colorectal cancer. *Neoplasia*. 2008;10:697-705.
 15. Luu HH, Zhang R, Haydon RC, Rayburn E, Kang Q, Si W, et al. Wnt/ β -catenin signaling pathway as novel cancer drug targets. *Curr Cancer Drug Targets*. 2004;4:653-71.
 16. Curtin JC, Lorenzi MV. Drug discovery approaches to target Wnt signaling in cancer stem cells. *Oncotarget*. 2010;1:563-77.
 17. De Almeida VI, Miao L, Ernst JA, Koepfen H, Polakis P, Rubinfeld B. The soluble wnt receptor Frizzled8 CRD-hFc inhibits the growth of teratocarcinomas in vivo. *Cancer Res*. 2007;67:5371-9.
 18. He B, Reguart N, You L, Mazieres J, Xu Z, Lee AY, et al. Blockade of Wnt-1 signaling induces apoptosis in human colorectal cancer cells containing downstream mutations. *Oncogene*. 2005;24:3054-8.
 19. Badiglian Filho L, Oshima CT, de Oliveira Lima F, De Oliveira Costa H, De Sousa Damião R, Gomes TS, et al. Canonical and noncanonical Wnt pathway: a comparison among normal ovary, benign ovarian tumor and ovarian cancer. *Oncol Rep*. 2009;21:313-20.
 20. Krajewska M, Krajewski S, Epstein JI, Shabaik A, Sauvageot J, Song K, et al. Immunohistochemical analysis of bcl-2, bax, bcl-X, and mcl-1 expression in prostate cancers. *Am J Pathol*. 1996;148:1567-76.
 21. TNM 7th edition (2010). www.uicc.org/uicc_old/resources/tnm
 22. Dimitriadis A, Vincan E, Mohammed IM, Roczo NN, Phillips WA, Baidur Hudson S. Expression of Wnt genes in human colon cancers. *Cancer Lett*. 2001;166:185-91.
 23. Stanczak A, Stec R, Bodnar L, Olszewski W, Cichowicz M, Kozłowski W, et al. Prognostic significance of Wnt-1, β -catenin and E-cadherin expression in advanced colorectal carcinoma. *Pathol Oncol Res*. 2011;17:955-63.
 24. Dejmek J, Dejmek A, Säfholm A, Sjölander A, Anderson T. Wnt-5a protein expression in primary Dukes B colon cancers identifies as subgroup of patients with good prognosis. *Cancer Res*. 2005;65:9142-6.
 25. Smith K, Bui TD, Poulson R, Kaklamanis Williams G, Harris A. Up-regulation of macrophage wnt gene expression in adenoma-carcinoma progression of human colorectal cancer. *Br J Cancer*. 1999;81:496-502.
 26. Giles RH, van Es JH, Clevers H. Caught up in a Wnt storm: Wnt signaling in cancer. *Biochim Biophys Acta*. 2003;1653:1-24.
 27. You XJ, Bryant PJ, Jurnak F, Holcombe RF. Expression of Wnt pathway components frizzled and disheveled in colon cancer arising in patients with inflammatory bowel disease. *Oncol Rep*. 2007;18:691-4.
 28. Hughes TA, Brady HJ. Regulation of axin2 expression at the levels of transcription, translation and protein stability in lung and colon cancer. *Cancer Lett*. 2006;233:338-44.
 29. Jin LH, Shao QJ, Luo W, Ye Zy Li Q, Lin SC. Detection of point mutations of the axin1 gene in colorectal cancers. *Int J Cancer*. 2003;107:696-9.
 30. Webster MT, Rozycka M, Sara E, Davis E, Smalley M, Young N, et al. Sequence variants of the axin gene in breast, colon, and other cancers: an analysis of mutations that interfere with GSK3 binding. *Genes Chromosomes Cancer*. 2000;28:443-53.