

THE PRESENT AND FUTURE

STATE-OF-THE-ART REVIEW

Functional Tricuspid Regurgitation

A Need to Revise Our Understanding

Gilles D. Dreyfus, MD, PhD,*†‡ Randolph P. Martin, MD,‡ K.M. John Chan, PhD,*†§ Filip Dulguerov, MD,*
Clara Alexandrescu, MD||



CrossMark



ABSTRACT

The assessment of the etiology and severity of functional tricuspid regurgitation (FTR) has many limitations, especially when tricuspid regurgitation (TR) is more than severe. Instead of relying solely on TR severity, a new approach not only takes into account the severity of TR, but also pays strict attention to tricuspid annular dilation (size), the mode of tricuspid leaflet coaptation, and tricuspid leaflet tethering—factors often influenced by right ventricular enlargement and dysfunction. To simplify things, we propose a new staging system for functional tricuspid valve pathology using 3 parameters that may more accurately reflect the severity of the disease: TR severity, annular dilation, and mode of leaflet coaptation (extent of tethering). We believe that by utilizing these parameters, cardiologists and cardiac surgeons will be offered a better system for appraisal and decision-making in FTR. (J Am Coll Cardiol 2015;65:2331-6)

© 2015 by the American College of Cardiology Foundation.

Functional tricuspid regurgitation (FTR) is primarily due to tricuspid annulus (TA) dilation and right ventricular enlargement and dysfunction, which lead to abnormalities of tricuspid anatomy and function. FTR is most often secondary to left-sided heart disease, especially in the setting of mitral valve pathology (1). The most frequent left-sided heart valve diseases, which can, in turn, lead to FTR, are mitral regurgitation (MR), mitral stenosis, and aortic stenosis. It is also important to note that atrial fibrillation, especially if chronic, can be an important etiologic factor in the development of FTR, primarily through its effect on tricuspid annular dilation (1,2). With the increasing recognition of mitral valve diseases, it is also noteworthy that approximately 30% to 50% of patients with severe MR have significant FTR (3,4). Additionally, patients who develop pulmonary hypertension, either due to left-sided heart disease or other

etiologies, often develop right ventricular dilation and dysfunction, which can lead to abnormalities of the tricuspid annular size, as well as tricuspid leaflet tethering problems, all of which can also produce significant FTR (Central Illustration). Patients with significant FTR may remain asymptomatic, despite impaired right ventricular function. FTR carries an adverse prognosis, which is related to its severity (5). The severity of tricuspid regurgitation (TR) is often the only parameter measured when assessing FTR; however, it is not the only criterion that should be utilized when evaluating the pathological processes and severity involved in FTR.

Hence, it is very important to recognize that FTR is not a valvular disease; it is an abnormality that is the result of disease processes that alter the TA size as well as produce abnormalities of right ventricular size and function, which thereby alter the mode of

From the *Department of Cardiac Surgery, Cardiothoracic Center of Monaco, Monaco; †Department of Cardiac Surgery, National Heart and Lung Institute, Imperial College London, London, United Kingdom; ‡Department of Cardiology, Piedmont Heart, Atlanta, Georgia; §Department of Cardiac Surgery, Sarawak General Hospital Heart Center, Kuching, Sarawak, Malaysia; and the ||Department of Cardiology, Cardiothoracic Center of Monaco, Monaco. Prof. Dreyfus has served as a speaker for educational courses with Edwards Lifesciences. Dr. Martin has served as a speaker for Medtronic Valve, Edwards Lifesciences, Abbott Vascular, and Sorin. All other authors have reported that they have no relationships relevant to the contents of this paper to disclose.

[Listen to this manuscript's audio summary by JACC Editor-in-Chief Dr. Valentin Fuster.](#)

[You can also listen to this issue's audio summary by JACC Editor-in-Chief Dr. Valentin Fuster.](#)

Manuscript received February 15, 2014; revised manuscript received December 28, 2014, accepted April 3, 2015.



**ABBREVIATIONS
AND ACRONYMS**

ACC = American College of Cardiology

FTR = functional tricuspid regurgitation

MR = mitral regurgitation

RV = right ventricle

TA = tricuspid annulus

TEE = transesophageal echocardiography

TR = tricuspid regurgitation

TV = tricuspid valve

2DE = 2-dimensional echocardiography

3DE = 3-dimensional echocardiography

tricuspid leaflet coaptation and produce tricuspid valve (TV) tethering. Because the right ventricle (RV) is more compliant than the left ventricle, the RV size may easily double without affecting its function. Currently, assessment by noninvasive imaging of right ventricular global size and function is less reliable than assessment of left ventricular size and function. However, when assessing FTR, it is very important to have a systematic approach to judging its effect—based not only on the severity of the TR, but also upon tricuspid annular size, mode of tricuspid leaflet coaptation, as well as the extent of tricuspid leaflet tethering. All of these taken together will help guide decision-making with respect to the need for concomitant surgical intervention

on the TV during left-sided heart valve surgery, particularly when TR is less severe. These parameters will also help in determining whether additional surgical repair techniques are needed during TV surgery.


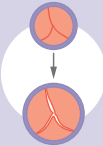

TV AND ANNULAR ANATOMY

The TV is made of 3 leaflets, but not all leaflets play an equal role in FTR. The septal leaflet, whose

papillary muscle is attached to the septum, is affected by the septal shift from right to left, but this is usually limited. The posterior leaflet is the smallest of the 3, and its papillary muscle is attached to the inferior wall of the RV. Thus, the diaphragm limits its displacement. The anterior leaflet is the biggest in surface area and is almost always anchored to a single papillary muscle, which is attached to the free wall or the anterior wall of the RV. This most important of TV leaflets is greatly affected by annular dilation, and TR appears when it is sufficient enough to reduce the coaptation height to a minimum. As the annulus dilates, the anterior and posterior leaflets are pulled away from the coaptation point, resulting in gaps that create TR jets (6). Papillary muscle displacement, another mechanism to explain FTR, is correlated with RV dilation. In such conditions, the papillary muscles become displaced, resulting in a changing of the position of the coaptation point and in leaflet tethering (6).

The TA is a very complex and dynamic structure, which changes its shape and size during the cardiac cycle. The TA, although saddle- or oval-shaped, is nonplanar. Although it is currently evaluated by 2-dimensional echocardiography (2DE) (both transthoracic and transesophageal), it is likely better

CENTRAL ILLUSTRATION Functional Tricuspid Regurgitation Development, Assessment, Diagnosis, and Treatment

FTR DISEASE PROCESSES	FTR ASSESSMENTS	DIAGNOSIS AND TREATMENT		
<p>Left-sided heart disease</p> <p>Atrial fibrillation</p> <p>Right ventricular (RV) afterload increase (with or without pulmonary hypertension)</p> <p>RV remodeling</p> <p>Altered RV function</p> <p>Tricuspid annular dilation. (In some instances leaflet tethering occurs with the same triggering factors)</p> <p>Abnormalities of tricuspid anatomy and function lead to functional tricuspid regurgitation (FTR)</p>	<p> Tricuspid regurgitation (TR) TR is the leakage of blood backwards through the tricuspid valve each time the right ventricle contracts <i>Color flow jet visualization is used to evaluate PISA radius and effective regurgitant orifice or regurgitant volume</i></p> <p> Annular dilation The annular ring is attached to the tricuspid valve leaflets. Dilation can result in poor leaflet apposition <i>2D-echocardiography coupled with 3D imaging is used to accurately measure annular diameter</i></p> <p> Leaflet coaptation mode Coaptation is the surface where the leaflets meet. If decreased, contact is made at the leaflet edge (edge-to-edge), leaflet tethering can restrict leaflet closure <i>3D-echocardiography is recommended to measure tenting volume (TV) — the area within the tricuspid leaflets</i></p>	<p>Stage 1</p> <p>TR severity: None or mild</p> <p>Annular diameter: <40 mm</p> <p>Coaptation mode: Normal (body-to-body), with no leaflet tethering</p> <p>Medical treatment. No surgical intervention is indicated</p>	<p>Stage 2</p> <p>TR severity: Mild or moderate</p> <p>Annular diameter: >40 mm</p> <p>Coaptation mode: Abnormal (edge-to-edge), with or without tethering of <8 mm below the annular plane</p> <p>Concomitant tricuspid valve annuloplasty is recommended</p>	<p>Stage 3</p> <p>TR severity: Severe</p> <p>Annular diameter: >40 mm</p> <p>Coaptation mode: No coaptation, with or without tethering of >8 mm below the annular plane</p> <p>Concomitant tricuspid valve annuloplasty and leaflet augmentation (if tethering is present)</p>

assessed with 3-dimensional echocardiography (3DE). Because of the changes in the TA shape and size during the cardiac cycle, as well as changes secondary to alterations in RV size and function, the best method for determining TA size and assessing the degree of regurgitation is yet to be established. Because of the changes in the TA shape and size during the cardiac cycle, as well as changes secondary to alterations in RV size and function, there is yet to be an established best method for determining TA size and assessing degree of regurgitation, both of which are dynamic processes that could alter not only with the phases of cardiac cycle, but with respiratory changes as well.

SEVERITY OF TR

Judging the severity of TR by echocardiography has often proved difficult, whether by qualitative, semi-quantitative, or quantitative techniques. This is especially prominent in less severe TR (7,8). Echocardiographic methods of assessing TR severity are based primarily on techniques used for assessing MR severity. However, there are important differences between the 2 valves and their orifices, subvalvular apparatuses, and respective ventricles. Although the major method used to evaluate severity of TR is predominantly color flow jet visualization, it is important to realize that the color Doppler TR jet is often variable, depending upon the echocardiographic window used. Also of critical importance is the fact that the color jet is a mean velocity map, not a flow map, and is affected by many factors, including instrument setting and hemodynamics, among others. It is equally important to understand that the type of regurgitant orifice affects the shape and distribution of the color jet in the right atrium. Semiquantitative methods also have significant limitations in trying to quantitate the severity of TR. The recent American Heart Association (AHA)/American College of Cardiology (ACC) guidelines (9) primarily use the vena contracta in an attempt to quantitate the severity of TR. The vena contracta is the smallest high-velocity region of the flow jet on the atrial side of the tricuspid orifice. Vena contracta measurements attempt to measure the width of this high-velocity region of flow. If the regurgitant orifice is truly circular, it correlates with the effective regurgitant orifice area in primary MR. However, if the regurgitant orifice is elliptical, its measurement and accuracy are more problematic. Hence, vena contracta measurements are not accurate with elliptical slit-like orifices when multiple jets are present. Also, as previously mentioned, the measured width of the vena contracta

is markedly dependent upon which portion of systole it is measured in. A vena contracta width >6.5 mm (7.0 mm in the recent ACC/AHA guidelines) is used to indicate severe TR. However, current guidelines do not substantiate which vena contracta width should be used to differentiate mild TR from moderate TR.

Although the vena contracta width has been included in the latest ACC/AHA and European Society of Cardiology/European Association of Cardio-Thoracic Surgery guidelines as a method for judging the severity of TR, the tricuspid regurgitant orifice is seldom circular and may, in fact, be more star-shaped (due to failure of proper coaptation along the 3 commissures of the TV) or even slit-like, producing multiple jets of TR. This limits the usefulness of the vena contracta as a quantitative marker of TR severity and FTR. Although evaluation of proximal isovelocity surface area (PISA) radius is not included in the current ACC guidelines, the published data suggest that a PISA radius >9 mm at a Nyquist limit of 28 m/s is indicative of severe TR. A PISA radius <5 mm is indicative of mild TR. But, as is well-recognized with PISA measurements for MR, eccentric regurgitant jets prevent beam alignment and limit this technique's accuracy with standard 2-dimensional imaging. The published data also suggest that an effective regurgitant orifice >40 mm² or a regurgitant volume >45 ml is indicative of severe TR. However, the reproducibility of these measurements and, again, the variability of the TR with alterations in respiration and right ventricular function make this measurement of limited utility. Also, there are no quantitative criteria for grading mild and moderate TR, and it is not possible to distinguish between the 2 grades of TR using quantitative grading. It must be emphasized that respiratory changes in TR are extremely important to recognize, as are the influences of pre-load, afterload, and alterations in right ventricular function. It is well recognized that the tricuspid regurgitant orifice area increases with inspiration, due to both enlargement of the TA as well as alterations in valve tenting. However, qualitative and quantitative measurements of TR severity have seldom taken this into account.

PROPOSED NEW METHOD FOR ASSESSING THE TRICUSPID APPARATUS IN FTR

The assessment of FTR should be revised to better aid clinical decision and management. As mentioned previously, we believe that this should be on the basis of 3 criteria that can be measured by echocardiography: TR severity, the tricuspid annular diameter, and the mode of tricuspid leaflet coaptation

(leaflet tethering). We agree wholeheartedly with the recent simplification of tricuspid grading into 3 grades (8). However, we suggest that TR should be divided not by grades, but as follows: no TR and mild TR should be 1 entity; mild-moderate and moderate TR should be a second entity; and severe TR should be a third entity. We recognize that TR grading is extremely labile, echocardiographic window-dependent, respiratory-dependent, and that sequential analyses should be performed.

TRICUSPID ANNULAR ASSESSMENT

Currently, the TA is measured and identified by various echocardiographic views for identifying annular insertion of the tricuspid leaflets. As the tricuspid leaflets occupy 3-dimensional (3D) space, they are, therefore, better evaluated by 3DE. Multiple authors have shown that 3DE brings better spatial evaluation of TV anatomy because it mimics an intraoperative surgical view and offers better identification of valvular leaflets and their variability (8,10). 3DE has many advantages when evaluating organic or structural TV lesions, such as rheumatic leaflet restriction or interference between pacemaker wire and septal leaflets (11). In the setting of FTR, transthoracic 3DE has been demonstrated to be more accurate in measurements of tricuspid annular size than 2DE (8). Data is currently limited as to the value of transesophageal echocardiography (TEE), especially 3D-TEE, but it is the impression of many that 3DE, whether 2DE or TEE, will become the standard procedure for accurately measuring tricuspid annular dimensions (**Central Illustration**).

Tricuspid leaflet anatomy is currently assessed by routine transthoracic 2DE. It must be recognized that, from the apical 4-chamber view, as well as from the parasternal short-axis view, angulation of the transducer will determine which 2 of the 3 tricuspid leaflets are best visualized. Many experienced echocardiographers believe that the best way to identify the leaflets themselves, as well as annular dimensions, is with subcostal short-axis views of all 3 tricuspid leaflets, as well as transgastric TEE views of all 3 tricuspid leaflets.

Currently, tricuspid annular diameters are measured in diastole from the apical 4-chamber view. This gives a measurement from approximately the mid-septal annulus to the midanterior annulus (although it could be the posterior) and has been shown to be a predictor of the severity of TR (12). The TA is considered dilated when it is >40 mm (9). In 2005, Dreyfus *et al.* (13) published a series of 311 patients for whom tricuspid annular dilation was the triggering factor

for surgical correction, irrespective of the grading of TR severity. In most of these patients, despite the absence of significant TR, the TA was significantly dilated. Performance of tricuspid annuloplasty resulted in improved New York Heart Association functional class and prevented progression of FTR in long-term follow-up. Others have more recently reported similar results (14,15). Dreyfus *et al.* (13) used a threshold of annular diameter of 70 mm measured intraoperatively from the anterior septal commissure to the anterior posterior commissure. This corresponded to a diameter of 40 mm, as measured by echocardiography from an apical 4-chamber view.

We are well aware that using a measurement of 40 mm, obtained from the 4-chamber view, may not be accurate. Tricuspid annular diameter measured by 2DE is known to systematically underestimate the actual TA diameter when compared with 3D-TEE. However, it is 1 of the initial steps that can be used to evaluate annular size. Again, depending upon how the echocardiographic beam is aimed, it will intersect the septal-anterior annulus or septal-posterior annulus. Recognizing its limitations, we believe that the measurement has 2 main advantages. First, transthoracic 2DE is a routine technique, as opposed to 3DE or even 3D-TEE. Second, viewing the TA from the 4-chamber 2DE view has been stated to estimate the size of the TA. Hence, this threshold value of 40 mm (or 21 mm/m² diameter indexed to body surface area) is the size mentioned in the most recent ACC/AHA guidelines, and in the European Society of Cardiology Guidelines it is a Level IIa indication for a tricuspid surgical annuloplasty when associated with mild or moderate TR (9). However, we again emphasize that other views, particularly subcostal short-axis views of the TV and transesophageal views of the TV—especially transgastric—may be more accurate, especially when coupled with 3D imaging to accurately measure the TA.

MODE OF LEAFLET COAPTATION

The third criterion that we propose—leaflet coaptation—should be analyzed carefully. The coaptation is the surface of contact between the leaflets that is measured indirectly by coaptation height. The greater the coaptation, the less regurgitation is likely to occur. A safe coaptation takes place between the body of each leaflet and, therefore, is called body-to-body coaptation. If, for any reason (annular dilation, leaflet tethering), the coaptation surface is decreased, then coaptation can take place on the free edge of the leaflet, either symmetrically (edge-to-edge) or asymmetrically (edge-to-body). In these cases, the likelihood of developing TR becomes very high, as,

according to filling conditions, there is no longer any safety margin to compensate or avoid regurgitation. The next step is a lack of coaptation, where the leaflets never meet. Coaptation is affected by many more variables on the right side, as opposed to the left side. Hence, due to more rapid changes in RV size, shape, and function, the mode of leaflet coaptation is more relevant on the right side. Normal coaptation of the tricuspid leaflets during systole takes place either at the level of the annulus or apically, just below it, with a good surface-to-surface coaptation (about 5 to 10 mm of the leaflets' bodies in contact with each other during systole). From the apical 4-chamber view, the septal and anterior leaflets are usually seen, although it can also be the septal and posterior leaflets. As soon as annular dilation occurs, the leaflet coaptation mode tends to become edge-to-edge. If the RV dilates at the same time, which is part of the same pathophysiologic process, then not only is coaptation edge-to-edge, but it also occurs below the annular plane. It must be emphasized that the mode of leaflet coaptation is an important consideration when deciding on the need for surgical intervention. For example, an edge-to-edge leaflet coaptation with mild TR and an annular diameter of >40 mm is indicative of significant tricuspid valvular pathology and should be considered for tricuspid annuloplasty, as any changes in pre-load, afterload, and right ventricular function will elicit more regurgitation. If leaflet coaptation is occurring below the annular plane, then it can also be called surface-to-surface or edge-to-edge. The distance of leaflet coaptation point from the plane of the TA can be measured and is called the tethering distance. The area contained within the leaflets and the annular plane can be measured and is called the tenting area. Leaflet tethering is considered significant when the tethering difference is >8 mm or the tenting area is >1.6 cm² (12). When significant leaflet tethering is present, no leaflet coaptation occurs at any stage of the cardiac cycle, thereby creating a single cavity between the RV and the right atrium. With 3DE, the extent of TV tethering can be measured in terms of tenting volume, and this parameter may be more accurate (16). The concept of TV tenting is not as well appreciated as an entity that requires specific surgical treatment, such as those that we have previously described (14). TV tenting volume has also been reported to independently determine residual TR after tricuspid annuloplasty. In predicting residual TR after tricuspid annuloplasty, a TV tenting volume >2.3 ml shows a sensitivity of 100% and a specificity of 84% (16). It must be emphasized that significant tethering does not necessarily indicate tricuspid valve replacement, as we have shown with anterior leaflet extension techniques (17).

SUMMARY

Using these parameters, we suggest classifying functional TV pathology into 3 stages that can help in decision making on the basis of TR grading, annular dilation, and leaflet coaptation mode (Table 1). Stage 1: there is no or mild TR; the TA is not dilated, measuring <40 mm; and leaflet coaptation is normal, occurring at the level of the annulus and with a good surface of coaptation between the leaflets. Stage 2: there is mild or moderate TR, the TA is dilated to >40 mm, and leaflet coaptation is impaired, occurring only at the edges. Stage 3: there is severe TR; the annulus is dilated to >40 mm; leaflet coaptation is impaired, occurring only at the edges or not at all; and there may additionally be leaflet tethering with the coaptation or theoretical coaptation point occurring ≥8 mm below the level of the annulus. This new staging system for functional tricuspid valvular pathology, which combines more than 1 parameter, offers a more consistent and reliable guide with respect to the need for surgical intervention on the TV during left-sided heart valve surgery and also the type of surgery required (Central Illustration).

In Stage 1 disease, no surgical intervention is indicated. In Stage 2 disease, concomitant TV valve annuloplasty is recommended. For decades, it was believed that FTR would spontaneously disappear after correction of the MR. However, we now know that this is not true in most cases and that FTR is, in fact, a progressive disease if left uncorrected at the time of left-sided heart valve surgery (13,15). We have previously demonstrated that tricuspid annular dilation can be present without significant TR and that performing an annuloplasty results in improved New York Heart Association functional class and prevents progression of the TR, which occurs when tricuspid annuloplasty is not performed (13). Others have more recently reported similar results. In an observational study, Navia et al. (14) reported that the risk of developing subsequent severe secondary

TABLE 1 Stages of Functional Tricuspid Regurgitation

	Stage 1	Stage 2	Stage 3
TR severity	None or mild	Mild or moderate	Severe
Annular diameter, mm	<40	>40	>40
Leaflet coaptation mode	Normal*	Edge-to-edge*	Absent†
Treatment	Medical treatment	Tricuspid annuloplasty	Tricuspid annuloplasty + leaflet augmentation‡

*No leaflet tethering (<8 mm). †Leaflet tethering may be present (≥8 mm). ‡If leaflet tethering is present. TR = tricuspid regurgitation.

TR correlated with not repairing moderate TR at the time of initial surgery. Similarly, in a randomized trial of patients with moderate TR and tricuspid annular dilation (>40 mm), Benedetto et al. (15) reported that TR was absent at 1 year in 71% of those who received an annuloplasty compared with 19% in those who did not. Severe TR was present in 0% of the annuloplasty group versus 28% of the non-annuloplasty group. Yilmaz et al. (18) reported in an observational study that 13% of patients had moderate or worse TR at the time of mitral valve surgery, which was not treated. At 5 years, this had increased to 29.9%, a progression of untreated TR similar to that observed in our previous reports (13,18). In this study, only 1 patient required reoperation for severe TR at 4.5 years. However, there are no established criteria for reoperation due to severe TR, as many factors must be considered, including pulmonary hypertension, right ventricular function and stroke volume, and liver and renal function. The reoperation rate for severe TR cannot be considered a valid endpoint in studies on TV surgery, as it is too subjective and depends on the clinician. Other factors that can contribute to progression of FTR should also be considered, such as untreated or new-onset atrial

fibrillation, post-capillary pulmonary hypertension related to residual or recurrent MR, or persistent left ventricular dysfunction.

In Stage 3 disease, concomitant tricuspid annuloplasty is also recommended. In addition, if significant leaflet tethering is present, augmenting the anterior tricuspid leaflet is recommended to ensure good long-term results and avoid recurrent TR. This is a surgical technique that we have previously described (17,19) and have been using for >10 years, with excellent long-term results showing reverse remodeling of the RV.

Recognizing how labile TR severity can be, FTR should be revisited from its initial assessment, including other parameters of tricuspid valvular pathology. TR must be recognized as a severe disease, which reduces survival, limits functional capacity, and causes end organ dysfunction. There is no effective medical therapy for TR, and appropriate referral for surgical intervention is necessary.

REPRINT REQUESTS AND CORRESPONDENCE: Prof. Gilles D. Dreyfus, Cardiothoracic Center of Monaco, 11 bis, avenue d'Ostende, 98000 Monaco. E-mail: gdreyfus@ccm.mc.

REFERENCES

- Rogers JH, Bolling SF. The tricuspid valve: current perspective and evolving management of tricuspid regurgitation. *Circulation* 2009;119:2718-25.
- Carpentier A, Deloche A, Hanania G, et al. Surgical management of acquired tricuspid valve disease. *J Thorac Cardiovasc Surg* 1974;67:53-65.
- Koelling TM, Aaronson KD, Cody RJ, et al. Prognostic significance of mitral regurgitation and tricuspid regurgitation in patients with left ventricular systolic dysfunction. *Am Heart J* 2002;144:524-9.
- Cohen SR, Sell JE, McIntosh CL, et al. Tricuspid regurgitation in patients with acquired, chronic, pure mitral regurgitation. I. Prevalence, diagnosis, and comparison of preoperative clinical and hemodynamic features in patients with and without tricuspid regurgitation. *J Thorac Cardiovasc Surg* 1987;94:481-7.
- Nath J, Forster E, Heidenreich PA. Impact of tricuspid regurgitation on long term survival. *J Am Coll Cardiol* 2004;43:405-9.
- Spinner EM, Shannon P, Buice D, et al. In vitro characterization of the mechanisms responsible for functional tricuspid regurgitation. *Circulation* 2011;124:920-9.
- Lancellotti P, Moura L, Pierard LA, et al., for the European Association of Echocardiography, Document Reviewers. European Association of Echocardiography recommendations for the assessment of valvular regurgitation. Part 2: mitral and tricuspid regurgitation (native valve disease). *Eur J Echocardiography* 2010;11:307-32.
- Badano L, Muraru D, Enriquez-Sarano M. Assessment of functional tricuspid regurgitation. *Eur Heart J* 2013;34:1875-85.
- Nishimura RA, Otto CM, Bonow RO, et al. 2014 AHA/ACC guideline for the management of patients with valvular heart disease: a report of the American College of Cardiology/American Heart Association Task Force on Practice Guidelines. *J Am Coll Cardiol* 2014;63:e57-185.
- Stankovic I, Daraban AM, Jasaityte R, et al. Incremental value of en face view of the tricuspid valve by two-dimensional and three-dimensional echocardiography for accurate identification of tricuspid valve leaflets. *J Am Soc Echocardiogr* 2014;27:376-84.
- Mediratta A, Addetia K, Yamat M, et al. 3D echocardiographic location of implantable device leads and mechanism of associated tricuspid regurgitation. *J Am Coll Cardiol Img* 2014;7:337-47.
- Kim HK, Kim YJ, Park JS, et al. Determinants of the severity of functional tricuspid regurgitation. *Am J Cardiol* 2006;98:236-42.
- Dreyfus GD, Corbi PJ, Chan KMJ, et al. Secondary tricuspid regurgitation or dilatation: which should be the criteria for surgical repair? *Ann Thorac Surg* 2005;79:127-32.
- Navia JL, Brozzi NA, Klein AL, et al. Moderate tricuspid regurgitation with left-sided degenerative heart valve disease: to repair or not to repair? *Ann Thorac Surg* 2012;93:59-67, discussion 68-9.
- Benedetto U, Melina G, Angeloni E, et al. Prophylactic tricuspid annuloplasty in patients with dilated tricuspid annulus undergoing mitral valve surgery. *J Thorac Cardiovasc Surg* 2012;143:632-8.
- Min SY, Song JM, Kim JH, et al. Geometric changes after tricuspid annuloplasty and predictors of residual tricuspid regurgitation: a real time three-dimensional echocardiography study. *Eur Heart J* 2010;31:2871-80.
- Dreyfus GD, Raja SG, John Chan KM. Tricuspid leaflet augmentation to address severe tethering in functional tricuspid regurgitation. *Eur J Cardiothorac Surg* 2008;34:908-10.
- Yilmaz O, Suri RM, Dearani JA, et al. Functional tricuspid regurgitation at the time of mitral valve repair for degenerative leaflet prolapse: the case for a selective approach. *J Thorac Cardiovasc Surg* 2011;142:608-13.
- Fukuda S, Gillinov AM, McCarthy PM, et al. Determinants of recurrent or residual functional tricuspid regurgitation after tricuspid annuloplasty. *Circulation* 2006;114:1582-7.

KEY WORDS annular dilation, leaflet coaptation mode, leaflet tethering, tricuspid annuloplasty with or without leaflet augmentation, tricuspid regurgitation grading, 2D/3D echocardiographic evaluation