

# Absence of exit block due to direct capture of the left atrial appendage: A visual confirmation



Mindy Vroomen, MD,<sup>\*</sup> Mark La Meir, MD,<sup>††</sup> Harry J. Crijns, MD, PhD,<sup>\*</sup> Laurent Pison, MD, PhD<sup>\*</sup>

From the <sup>\*</sup>Department of Cardiology and <sup>†</sup>Department of Cardiac Surgery, Maastricht University Medical Center and Cardiovascular Research Institute Maastricht, Maastricht, The Netherlands, and <sup>‡</sup>Department of Cardiac Surgery, UZ Brussel, Brussels, Belgium.

## Introduction

A hybrid atrial fibrillation (AF) procedure combines epicardial surgical and endocardial catheter ablation. One of the benefits of a 1-stage procedure is the possibility to map endocardially under direct thoracoscopic vision. This opportunity appeared to be very useful in this case.

## Case report

A 69-year-old man with symptomatic longstanding persistent AF of 2 years' duration underwent a hybrid AF ablation procedure. His medication consisted of flecainide, metoprolol, and warfarin. Antiarrhythmic drugs were stopped 5 days before the procedure.

Via a bilateral thoracoscopic approach, we isolated the pulmonary veins (PVs) in pairs using a bipolar radiofrequency clamp (Atricure, West Chester, OH). AF organized into left atrial (LA) flutter. A His bundle catheter (St Jude Medical, St Paul, MN) and coronary sinus catheter (Medtronic, Minneapolis, MN) were inserted. After transseptal puncture, a long sheath (SL0; St Jude Medical) was advanced from the groin into the LA, and the patient was fully heparinized. A roofline connecting both superior PVs was made using a bipolar radiofrequency linear pen device (Atricure, West Chester, OH). Since this resulted in conversion (of LA flutter) to sinus rhythm, the flutter probably was LA roof-dependent. We then placed a circular mapping catheter (Lasso; Biosense Webster Inc, Diamond Bar, CA) at the ostium of the left superior PV (LSPV). The thoracoscopic view from the left side of the patient makes clear how the left atrial appendage (LAA) lies on top of the LSPV (Figure 1A). Entrance block (absence of PV potentials on the Lasso catheter

during pacing from the coronary sinus catheter) was clearly present. Nevertheless, pacing from the Lasso catheter from dipole 2–3 (output 10 mA, pulse width 2 ms) resulted in what seemed to be local capture in the PV and conduction to the LA (arrow in Figure 1B). This finding as such excludes exit block. Pacing from the remaining dipoles did not result in local capture. Only dipole 2–3 was oriented toward the LAA. By lifting the LAA from its natural position on top of the LSPV using a surgical forceps during pacing from dipole 2–3 on the Lasso catheter, we visualized the Lasso catheter (dashed line, Figure 1C) at the ostium of the LSPV (asterisk, Figure 1C) and were able to prove that the apparent absence of exit block was due to direct capture of the LAA, as local signals disappear on the Lasso catheter tracings (Figure 1D). This finding also reinforces the fact that the signal on Lasso 9–10 (arrow in Figure 1B) is not a local PV potential but is due to LAA depolarization.

The supplementary movie available online shows how lifting the LAA from its position on top of the LSPV during pacing from the Lasso catheter leads to loss of direct LAA capture.

## Discussion

Entrance block in the absence of exit block occurs in up to 40% of PVs following ablation, if exit block is tested using pacing from inside of the PVs.<sup>1</sup> One possible explanation for this finding is that pacing the circular mapping catheter at high output may directly capture the right atrium or LAA. This is also supported by the fact that only 0.6% of spontaneous PV potentials following circumferential PV isolation are conducted to the LA.<sup>2</sup> P-wave morphology and intracardiac activation sequence can be helpful in recognizing this phenomenon. During this procedure we were able to illustrate and prove the underlying mechanism by temporarily lifting the LAA from its natural position and hence prevent direct capture during pacing in the PV.

**KEYWORDS** Atrial fibrillation; Hybrid ablation; Exit block; Pulmonary vein; Left atrial appendage (Heart Rhythm Case Reports 2016;2:268–269)

Mark La Meir is a consultant for Atricure. **Address reprints and correspondence:** Dr M. Vroomen, Department of Cardiology, Maastricht University Medical Centre, PO Box 5800, Maastricht, The Netherlands. E-mail address: mindyvroomen1@gmail.com.

**KEY TEACHING POINTS**

- Absence of pulmonary vein (PV) exit block after PV isolation might be the result of the left atrial appendage overlying the PV.
- In the setting of a hybrid ablation, the underlying mechanism of absence of exit block can be tested by lifting the left atrial appendage from its position on top of the PV.
- In a nonhybrid setting, P-wave morphology and intracardiac activation sequence are of importance in recognizing this phenomenon.

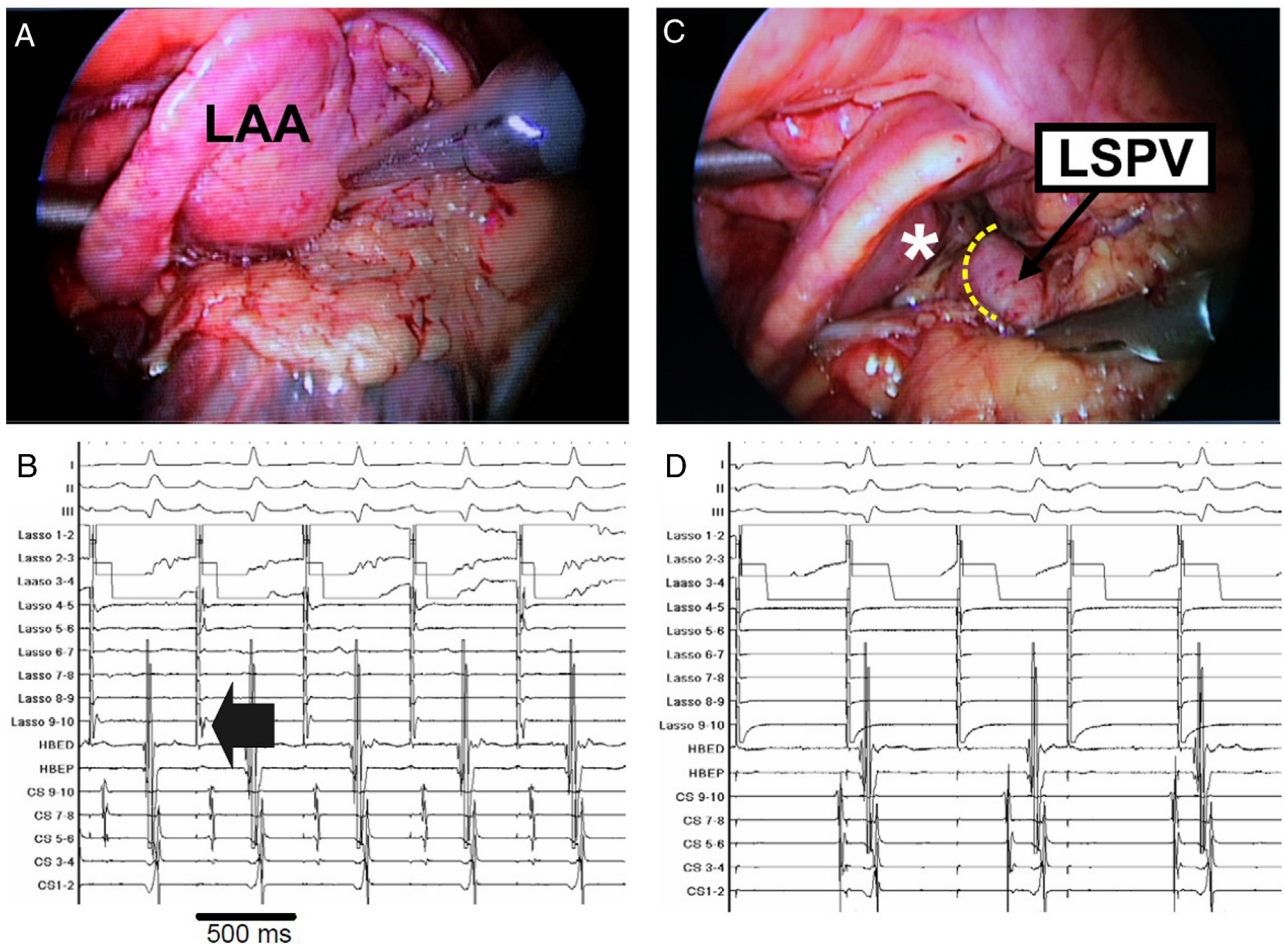
**References**

1. Gerstenfeld EP, Dixit S, Callans D, Rho R, Rajawat Y, Zado E, Marchlinski FE. Utility of exit block for identifying electrical isolation of the pulmonary veins. *J Cardiovasc Electrophysiol* 2002;13:971–979.
2. Duytschaever M, De Meyer G, Acena M, El-Haddad M, De Greef Y, Van Heuverswyn F, Vandekerckhove Y, Tavernier R, Lee G, Kistler P. Lessons from dissociated pulmonary vein potentials: entry block implies exit block. *Europace* 2013;15(6):805–812.

**Appendix**

**Supplementary data**

Supplementary data associated with this article can be found in the online version at <http://dx.doi.org/doi:10.1016/j.hrcre.2015.11.013>.



**Figure 1** Left-sided thoracoscopic view and signals on the Lasso catheter. **A:** Left atrial appendage (LAA) on top of the left superior pulmonary vein (LSPV). **B:** Pacing from the Lasso catheter from dipole 2–3 resulted in what seemed to be local capture in the pulmonary vein and conduction to the left atrium (arrow). **C:** Visualization of the Lasso catheter (dashed line) at the ostium of the LSPV (asterisk). **D:** Local signals disappear on the Lasso catheter tracings, proving that the apparent absence of exit block was due to direct capture of the LAA.