



REVISTA BRASILEIRA DE ANESTESIOLOGIA

Official Publication of the Brazilian Society of Anesthesiology
www.sba.com.br



CLINICAL INFORMATION

Anesthesia Management in a Child with Osteogenesis Imperfecta and Epidural Hemorrhage

Mehmet Ali Erdoğan* ¹, Mukadder Sanlı ¹, Mehmet Ozcan Ersoy ²

1. MD; Assistant Anesthesia Professor, Department of Anesthesiology and Reanimation, Inonu University School of Medicine, Malatya, Turkey

2. MD; Anesthesia Professor, Department of Anesthesiology and Reanimation, Inonu University School of Medicine, Malatya, Turkey

Received from the Department of Anesthesiology and Reanimation, Inonu University School of Medicine, Malatya, Turkey.

Submitted on June 5, 2012. Approved on July 16, 2012.

Keywords:

Anesthesia;
Anesthesia, Intravenous;
Hematoma, Epidural,
Cranial;
Laryngeal Masks;
Osteogenesis Imperfecta.

Abstract

Osteogenesis Imperfecta (OI) results from gene mutation that causes defective or insufficient collagen formation. It may cause various anesthetic complications due to the difficulty in airway management, existence of spinal deformity, respiratory disorders, cardiac anomalies, thrombocyte function disorder, risk of hyperthermia, bacillary invagination, bone deformities and metabolic disorders. The anesthesia management of OI patients should be exercised with caution given certain risks of respiratory disorders. These risks are due to thorax deformity, bone fractures during moving or changing position, mandibular and cervical fractures related with intubation, difficult intubation and malignant hyperthermia. The anesthetic technique using Total Intravenous Anesthesia (TIVA) and laryngeal mask airway is suitable for pediatric patient care with OI. However, these techniques have not yet been reported as useful in neurosurgery case reports. In this study, we present the use of TIVA and ProSeal Laryngeal Mask in a child with OI and epidural hemorrhage. We came to the conclusion that LMA and TIVA can safely be used in the anesthetic management of OI patients with severe anesthetic problems.

© 2013 Sociedade Brasileira de Anestesiologia. Published by Elsevier Editora Ltda.

Este é um artigo Open Access sob a licença de [CC BY-NC-ND](#)

Introduction

Osteogenesis Imperfecta (OI) is a hereditary disease of connective tissues that develops depending on the mutation of the Type I collagen gene. Approximately one in every 30,000 births manifest this disease ¹. Primary bone lesion is characterized with the absence of normal ossification in endochondral bone. As a result, bones become very fragile. Besides fragile

bones, one can observe teeth anomalies, hearing disorder, blue sclera, macrocephaly, kyphoscoliosis, thrombocyte function disorder, respiratory dysfunction based on chest deformity, metabolic disorders and growth deficiency ^{1,2}. OI cases generally require orthopedic surgery due to bone fracture. Even though a direct relationship between OI and malignant hyperthermia has not been proven, malignant hyperthermia symptom and findings have been observed in

*Corresponding author: Inonu University, School of Medicine, Department of Anesthesiology and Reanimation, Malatya, Turkey.

E-mail: drmalierdogan@gmail.com

ISSN © 2013 Sociedade Brasileira de Anestesiologia. Published by Elsevier Editora Ltda. Este é um artigo Open Access sob a licença de [CC BY-NC-ND](#)

doi: 10.1016/j.bjane.2012.07.008

the OI case under general anesthesia³. The anesthesia management of OI patients should be exercised with caution, given there are risks of respiratory disorders due to thorax deformity, bone fractures during moving or changing position, mandibular and cervical fractures related intubation, difficult intubation and malignant hyperthermia. In this study, we present the use of Total Intravenous Anesthesia (TIVA) and ProSeal Laryngeal Mask (PLMA) in a child with OI and epidural hemorrhage.

Case Report

Operation was planned for the case of a 7-year-old girl weighing 10kg due to epidural hematoma. The parents were 3rd degree relatives and we determined no pathology in the family. Severe growth retardation, bone deformities on lower and upper extremities due to old fractures, scoliosis and chest deformity were present in the physical examination (Figure 1). Head and neck movements were limited leading to a Mallampati III score. The patient was agitated, but with a Glasgow coma score of 15 points. Preoperative full blood count, coagulation profile, biochemical and blood gas analysis were normal, apart from 10.2 g.dL⁻¹ hemoglobin. Epidural hematoma was present in the right parietal region in computer tomography (Figure 2).

Considering the development of malignant hyperthermia during the patient's anesthesia preparation; dantrolene sodium, sodium bicarbonate and cold intravenous serums were prepared. We considered bispectral index monitorization in order to determine the anesthetic depth, however this was

not carried out since the patient was going to be operated from her parietofrontal region. We avoided the use of agents that might trigger malignant hyperthermia such as halothane, enflurane and succinylcholine. Propofol and remifentanyl was prepared for TIVA. We prepared laryngeal mask airway (LMA) of various sizes (ProSeal LMA, laryngeal Mask Company, Herley on Thames, UK).

The patient was taken to the operating room without premedication where electrocardiography, pulse oximeter, noninvasive blood pressure and rectal temperature monitorization were carried out. The readings were SpO₂ 96%, heart rate 132 beat.min⁻¹, noninvasive arterial blood pressure 90/57 mm Hg, rectal body temperature 36.8°C. Following a 5-minute preoxygenation, anesthesia was induced with 2.5 mg.kg⁻¹ propofol and 1 µg.kg⁻¹ remifentanyl; the anesthesiologist inserted a PLMA numbered 1.5 while carefully holding the patient's head in neutral position in order not to damage the lower jaw and teeth. Following gastric aspiration via the PLMA drainage tube using a nasogastric catheter, the esophagus probe was affixed in order to measure the esophagus temperature concurrently with the rectal temperature. Anesthesia was maintained with propofol infusion 4 mg/kg/h, remifentanyl 0.25 µg.kg⁻¹.min⁻¹. The propofol and remifentanyl doses applied in accordance to the patient's hemodynamic data varied between 4-10 mg.kg⁻¹.h⁻¹ and 0.25-0.5 µg.kg⁻¹.min⁻¹, respectively.

Anesthesia was maintained with 50% O₂ and 50% air mixture. We used synchronized intermittent ventilation mode with low tidal volume to avoid chest bone fracture. Esophagus and rectal temperatures ranged between 36-37.1°C during

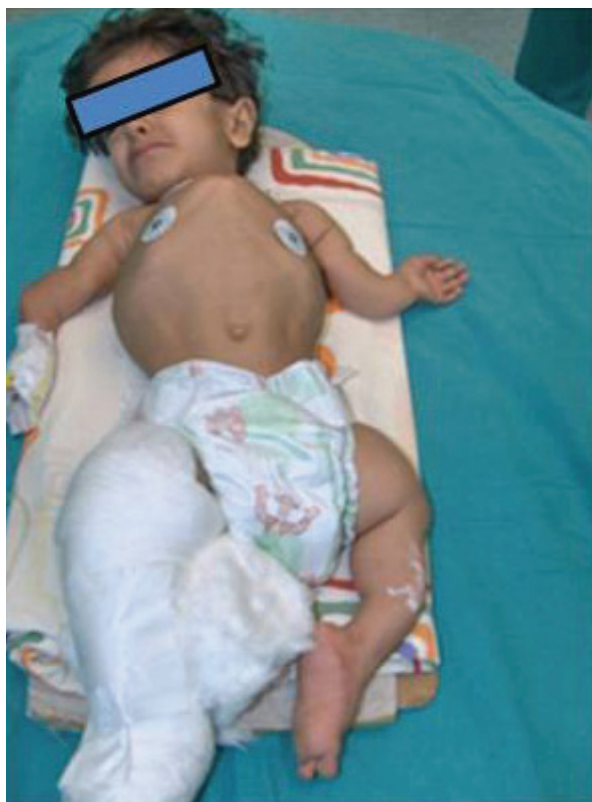

Figure 1 - Photograph of the child with osteogenesis imperfecta prior to monitoring.

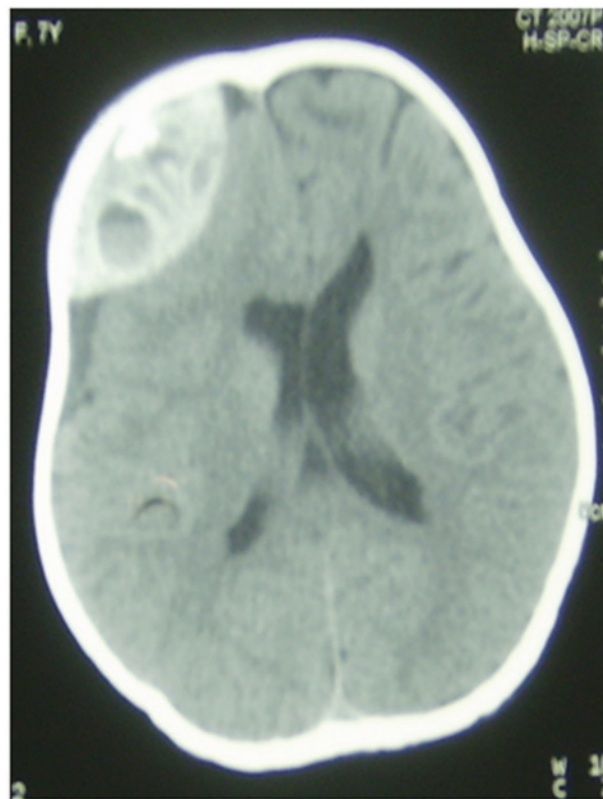


Figure 2 - CT image of an epidural hematoma.

the operation, which lasted about 120 minutes. We administered 100 mL erythrocyte transfusion to the case with a total hemorrhage of 100 mL during the intraoperative period. Saturation did not fall below 97% during the operation and the heart rate and blood pressure varied from their respective pre-operation values by $\pm 20\%$. We gave intravenous paracetamol 15 minutes before the end of the operation. The arterial blood gas analysis performed at the end of the operation was normal, SpO₂ 100%, heart rate was 116 beat.min⁻¹, noninvasive arterial blood pressure was 87/63 mm Hg and rectal body temperature was 36.4°C. We pulled the patient's PLMA after deflation of the cuff, once she had sufficient spontaneous respiration and protective airway reflexes. The patient was taken to the intensive care unit.

Discussion

OI results from gene mutation that causes defective or insufficient collagen formation¹. It may cause various anesthetic complications due to the difficulty in airway management, existence of spinal deformity, respiratory disorders, cardiac anomalies, thrombocyte function disorder, risk of hyperthermia, bacillary invagination, bone deformities and metabolic disorders⁴.

One should exercise care during the perioperative period of OI patients' transportation, placement on the operation table and positioning; parts under pressure should be supported using soft pads. Excessively fragile bones could cause perioperative morbidity. Neck and mandibular fracture may occur during the laryngoscopy due to excessive extension of the neck. Fasciculation induced by succinylcholine may cause fractures. Kyphoscoliosis and thoracic deformities may restrict neck movements, thus, making it difficult to see the larynx. The risk of tooth loss in patients with dentinogenesis imperfecta is high. We advise preoperative determination of mouth and teeth anomalies and the use of mouth protectors for teeth protection on these patients².

The use of LMA for the airway control of OI cases is preferred to prevent the complications that might arise during tracheal intubation^{5,6}. LMA can prevent possible bone fractures due to movement and waking up by soft extubation⁵. We applied PLMA on our patient with head trauma considering the complications that might arise during intubation and extubation. We prevented sympathoactivation that might have occurred with endotracheal intubation and secure airway was obtained without any complication.

Fiberoptic intubation would appear to be a method of securing the airway. Other methods for maintaining cervical spine immobility during intubation include the use of an intubating laryngeal mask airway or of a stylet⁴. Tracheal intubation through intubating laryngeal mask may be safer for securing the airway during neurosurgery. However, a laryngeal mask may be an alternative approach for neurosurgery.

Porsborg et al.³ believe that malignant hyperthermia has developed in the patient on whom they performed general anesthesia using barbiturate, fentanyl, pancuronium

and nitrous oxide. However, they stated that the in vitro contractor test they performed later was normal. They have concluded that the hypermetabolic condition they observed of OI patients is a result of unknown mechanisms aside from malignant hyperthermia. In a retrospective study on the effects of various anesthesia methods on intra and postoperative body temperature of OI patients, Fulderer et al.⁷ observed that body temperatures in the group in which TIVA was used decreased, whereas, the body temperatures of the group on which enflurane was used have increased. However, Santo et al.⁶ stated that they have observed no increase in temperature on patients on whom sevoflurane anesthesia was used. TIVA anesthesia and LMA application are suggested as safe methods in terms of malignant hyperthermia and traumatic complications^{5,8,9}.

The anesthetic management using TIVA and laryngeal mask airway is suitable for caring for pediatric patients with OI^{5,6,8,9}. However, these techniques have not yet been reported to be useful in neurosurgery case reports. We observed no complication during or after the PLMA application in our OI case with epidural hemorrhage on whom we applied TIVA and, in addition, did not observe intraoperative or postoperative hyperthermia or hypermetabolic condition.

In conclusion, we think that LMA and TIVA can safely be used in the anesthetic management of OI patients with severe anesthetic problems.

References

1. Bissonnette B, Luginbuehl I, Marciniak B, Dalens B - Osteogenesis Imperfecta, Syndromes. 1st ed. New York: McGraw-Hill Medical Publishing Division. 2005;618-621.
2. Baum VC, O'Flaherty JE - Anesthesia for Genetic, Metabolic, and Dysmorphic Syndromes of Childhood. 2nd Edition Lippincott Williams & Wilkins. 2007;283-285.
3. Porsborg P, Astrup G, Bendixen D, Lund AM, Ording H - Osteogenesis imperfecta and malignant hyperthermia. Is there a relationship? *Anaesthesia*. 1996;51:863-865.
4. Oakley I, Reece LP - Anesthetic Implications for the Patient With Osteogenesis Imperfecta. *AANA Journal*. 2010;78:47-53.
5. Ogawa S, Okutanı R, Suehiro K - Anesthetic management using total intravenous anaesthesia with remifentanyl in a child with osteogenesis imperfecta. *J Anesth*. 2009;23:123-125.
6. Santos ML, Anez C, Fuentes A, Mendez B, Perinan R, Maria R - Airway management with ProSeal LMA in a patient with osteogenesis imperfecta. *Anesth Analg*. 2006;103:794.
7. Fulderer S, Stanek A, Karbowski A, Eckardt A - Intraoperative hyperpyrexia in patients with osteogenesis imperfecta. *Z Orthop ihr Grenzgeb*. 2000;138:136-139.
8. Kostopanagiotou G, Coussi T, Tsaroucha N, Voros D - Anaesthesia using a laryngeal mask airway in a patient with osteogenesis imperfecta. *Anaesthesia*. 2000;55:506.
9. Karabıyık L, Parpucu M, Kurtipek O - Total intravenous anaesthesia and the use of an intubating laryngeal mask in a patient with osteogenesis imperfecta. *Acta Anaesthesiol Scand*. 2002;46:618-619.