



Available online at  
**ScienceDirect**  
[www.sciencedirect.com](http://www.sciencedirect.com)

Elsevier Masson France  
**EM|consulte**  
[www.em-consulte.com/en](http://www.em-consulte.com/en)



Original article

# Acute quadriceps tendon ruptures: A series of 50 knees with an average follow-up of more than 6 years



M. Boudissa\*, A. Roudet, B. Rubens-Duval, C. Chaussard, D. Saragaglia

Clinique universitaire de chirurgie orthopedique et de traumatologie du sport, hôpital Sud, CHU de Grenoble, avenue de Kimberley, 38130 Échirolles, France

## ARTICLE INFO

*Article history:*  
 Accepted 27 September 2013

*Keywords:*  
 Quadriceps tendon  
 Rupture  
 Surgical repair  
 Traumatic

## ABSTRACT

*Introduction:* Quadriceps tendon ruptures are rare and mainly affect patients over 40 years of age who have a systemic disease. The aim of this study was to evaluate the functional and radiological outcomes following surgical repair of acute quadriceps tendon ruptures.

*Methods:* This retrospective study included 68 knees in 65 patients (three women, 62 men), having an average age of  $55.2 \pm 13.9$  years. The Lysholm and Tegner scores, patient satisfaction, range of motion and X-rays were evaluated.

*Results:* Fifty knees were evaluated with a mean follow-up of  $76 \pm 67$  months (12–253 months). The average Lysholm score was  $93.7 \pm 10$  (range 56–100, median 99) and 49 of 50 knees (98%) had good or very good subjective results. The average Tegner score was  $3.4 \pm 1.6$  (range 1–9, median 4). At the last follow-up, the average active flexion was  $133^\circ \pm 10.8^\circ$  (range  $110^\circ$ – $150^\circ$ , median  $130^\circ$ ). Minor or moderate patellofemoral osteoarthritis was found in 24% of knees, but this was attributed to the surgery or initial injury in only 8% of cases. For 97% of active patients, the surgical repair allowed them to return to work in their pre-injury occupations.

*Conclusion:* Quadriceps tendon ruptures have a good prognosis if they are diagnosed quickly. Treatment consists of surgery and postoperative immobilization for at least 6 weeks. An intensive rehabilitation protocol is also needed to recover good knee function.

*Level of evidence:* Level IV. Retrospective study.

© 2014 Elsevier Masson SAS. All rights reserved.

## 1. Introduction

Quadriceps tendon ruptures are fairly rare, as they occur six times less often than patellar fractures [1,2]. These ruptures mainly occur in patients above 40 years of age affected by a systemic disorder (diabetes, gout, renal failure, fluoroquinolones or corticosteroid treatment) [1,3–7]. The diagnosis is easy because the patient is unable to actively extend the knee, but it is sometimes missed in an emergency setting.

Although the care of recent ruptures is well standardized, few studies have evaluated the results of surgical treatment of acute quadriceps tendon ruptures [3–7]. This is likely due to the low frequency of this tendon rupture, which results in published series having low statistical power. The goal of this study was to evaluate the functional and radiological results of surgical repair of acute quadriceps tendon.

## 2. Patients and methods

### 2.1. The series

Among the 102 patients seen between 1991 and 2011 for quadriceps tendon injury, 26 were excluded immediately for partial ruptures or tears that were not surgically treated and 11 were excluded because the rupture was chronic (more than 3 weeks old). This resulted in a series of 65 patients (68 knees) consisting of three women and 62 men; their mean age at the time of the accident was  $55.2 \pm 13.9$  years (range 18–85 years, median 57 years). At the last follow-up, data was available for 47 patients (50 knees), meaning that 18 patients (18 knees) were lost to follow-up, declined to participate in the study or had died (Fig. 1). The delay between the accident and surgery was a mean of  $2.7 \pm 3.3$  days (range 0–17 days, median 1 day).

Three patients had a bilateral rupture. The body mass index (BMI) was  $28 \pm 4.3$  (range 21.3–41.2) with 77% of patients being obese or overweight. Seven of the patients (11%) had a predisposing factor such as long-term corticosteroid therapy (one patient) and diabetes (six patients). The injury mechanism was a sudden quadriceps contraction in 67% of cases, direct impact in 26% of cases and hyperextension in 11% of cases. The aetiology of the injury consisted

\* Corresponding author.

E-mail address: [mboudissa@chu-grenoble.fr](mailto:mboudissa@chu-grenoble.fr) (M. Boudissa).

## Flowchart

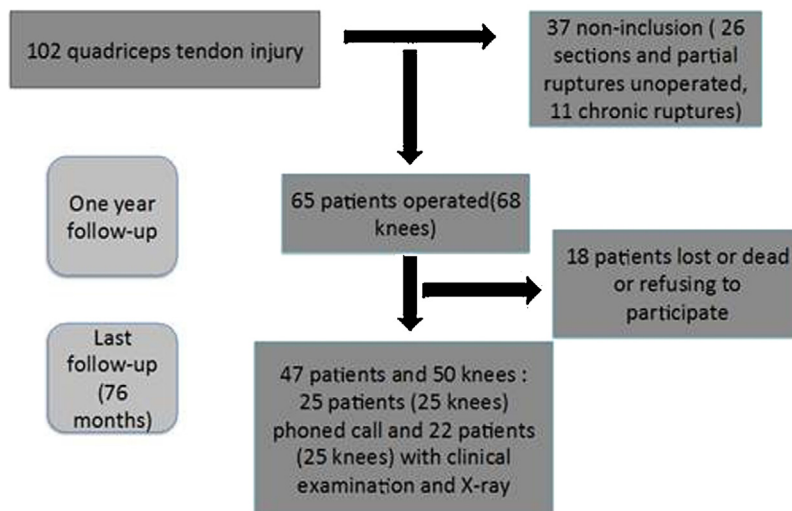


Fig. 1. Flow chart showing the outcome of the study patients.

**Table 1**  
Preoperative X-ray characteristics.

Preoperative X-ray signs (59 knees)	Total (%)
Caton-Deschamps index	0.9
Patella infera	23 (39)
Bone avulsion	20 (34)
Tipped forward	14 (24)
Suprapatellar mass and/or calcifications	21 (36)
At least one indirect sign of rupture	43 (73)

of an accident at home (68%), sports injury (21%), work-related injury (9%) or motor vehicle accident (2%).

Standard preoperative A/P and lateral X-rays of the knee were available in 59 of the knees. The injured knee had a mean Caton-Deschamps index of  $0.9 \pm 0.2$  (range 0.5–1.4, median 0.9) before the surgery. In all, 23 knees (39%) had radiological *Patella infera* [8]. There was an indirect radiological sign of quadriceps tendon rupture in 73% of cases (Table 1).

### 2.2. Surgical technique

The intraoperative injury assessment found 40 tendon avulsions, 26 tendon ruptures and two fracture-avulsions of the proximal pole of the patella. Transosseous reattachment was performed in 62 knees (91%). Two parallel vertical tunnels (proximal to distal) were drilled into the body of the patella. The quadriceps tendon was sutured with two or three large-diameter sutures (preferably non-resorbable) running through the tunnels [1].

Tendon reattachment alone was performed in 51 knees (75%) and suture anchors were added in 11 knees (16%). Non-transosseous tendon repair was performed in six cases (9%). The surgeon based the choice of surgical technique on the intraoperative findings: intratendinous suture for proximal ruptures that could be sutured side-to-side or transosseous suture for avulsions and distal ruptures.

### 2.3. Post-operative recovery

The limb was immobilized for at least six weeks in a leg cylinder cast that allowed immediate weight bearing. It was then replaced by a removable brace until the patient could achieve full active and passive extension without pain (additional 15–30 days).

### 2.4. Assessment methods

Retrospective analysis of the medical records led to data being collected from 65 patients (68 knees) with at least one year of follow-up. An independent examiner contacted 47 patients (50 knees) by telephone. This led to 22 patients (25 knees) coming to the hospital for a clinical and radiological examination and 25 patients (25 knees) agreeing to a telephone follow-up. Postoperative complications, flexion and extension differences between the injured and contralateral knee and the presence of patellofemoral syndrome were assessed. The Lysholm [9] and Tegner [10] scores were calculated and return to work in active patients was determined. Subjective evaluation consisted of asking the patient if he/she was satisfied with the procedure and would have it again if needed. The 22 patients (25 knees) seen again in the clinic had X-rays done of the knee in A/P, lateral in 30° knee flexion and skyline view by a senior surgeon other than the person having performed the data collection over the telephone, to reduce the recall bias. Of these 25 knees, 12 had preoperative X-rays consisting of skyline views and at the last follow-up, 18 had X-rays of the contralateral knee, which allowed us to compare the appearance of the patellar femoral joint before and after surgery, and also relative to the other side.

### 2.5. Statistics

Statistical analysis was performed using StatView 5.5 (SAS Institute, Cary, NC, USA). Student's *t*-test was used to compare quantitative variables and the Chi-square test used with qualitative variables. A paired Student's *t*-test was used with paired data. If the *P*-value was lower than the chosen alpha value of 0.05, the difference was considered significant.

## 3. Results

### 3.1. Complications

There were two complications in this series (3%). One patient had a pulmonary embolism that was successfully treated by anticoagulants. One patient experienced stiffness with less than 90° knee flexion; this was treated with intense rehabilitation and excellent results were achieved at the last follow-up.

**Table 2**

Clinical results at 1 year (68 knees) and at the last follow-up (25 knees evaluated over the phone and 25 by clinical examination and X-rays).

Clinical results	Mean value
<i>12 months follow-up (68 knees)</i>	
Flexion (degrees)	125.1
Complete extension	97%
<i>76 months follow-up (50 knees)</i>	
Lysholm score (/100)	94
Tegner score	3.4
Subjective results	
Very Good	74%
Good	24%
Average	2%
Return to work at same level	97%
PF syndrome	12%
<i>76 months follow-up (25 knees)</i>	
Flexion (degrees)	133
Complete extension	100%
Muscle strength (MRC scale/5)	4.9

### 3.2. Functional results

At the one-year follow-up for the 68 knees, the mean active flexion was  $125.1^\circ \pm 15.7^\circ$  (range  $60^\circ$ – $140^\circ$ , median  $130^\circ$ ) and 66 knees (97%) had full extension. At the latest follow-up (mean  $76 \pm 67$  months, range 12–253 months, median 52 months), mean active flexion was  $133^\circ \pm 11^\circ$  (range  $110^\circ$ – $150^\circ$ , median  $130^\circ$ ) in the 25 knees that were clinically evaluated. Knee flexion was determined to be symmetric in the other 25 knees where the patients were reviewed over the telephone. The mean quadriceps strength was 4.9/5.0 (Table 2). Six patients (12%) still experienced minor knee pain: 1 with effort and 5 due to patellofemoral syndrome. The mean Lysholm score was  $94 \pm 10$  (range 56–100, median 99). The mean Tegner score at follow-up was  $3.4 \pm 1.6$  (range 1–9, median 4) versus  $4 \pm 1.8$  (range 1–10) before the rupture ( $P < 0.05$ ) (Table 2).

Of the 33 patients who were still working at the last follow-up, 97% had returned to the same job with the same level of activity. Only one patient had to be reassigned.

Forty-six of 47 patients (98%) were satisfied or very satisfied of the procedure and were willing to have the same procedure done again if needed (Table 2).

### 3.3. Radiological results

X-rays at the last follow-up were available in 25 knees (37% of initial population) with the mean patient age being  $64.1 \pm 13.3$  years (range 24–81, median 64.5) (Table 3). Overall, given the presence of patellofemoral osteoarthritis (OA) before the surgery and/or in the uninjured contralateral knee, only two of the 25 knees (8%) had patellofemoral OA that could be attributed to the surgery or the injury (Table 3).

**Table 3**

Radiology results at the last follow-up (25 knees).

Patellofemoral osteoarthritis at last follow-up (25 knees)	(%)
Stage 1*	12
Stage 2*	12
Total	24
Patellofemoral osteoarthritis–contralateral knee	12
Patellofemoral osteoarthritis–injured knee (before surgery)	4
Patellofemoral osteoarthritis–attributable to surgical repair or initial injury	8

\* According to Iwano classification [11].

### 3.4. Statistical analysis

There were no significant differences in the functional results (flexion, patellofemoral syndrome, Lysholm and Tegner scores) and radiological results (patellofemoral OA) relative to the early or delayed nature of the surgery, use of suture anchors and patient above or below 50 years of age. A BMI above 30 was significantly associated with radiological signs of patellofemoral osteoarthritis ( $P = 0.001$ ).

## 4. Discussion

### 4.1. Study limitations

One of the limitations of the current study was its design: single-centre retrospective study without a control group. Although a large number of patients were initially included, only 75% of knees could be evaluated again. This is a function of the population under study: trauma context and patients who often reside in another area or country. Subjectivity bias may also have been induced by the telephone follow-up of patients living far away and unable to return to the hospital. Also, those who were reviewed again at the hospital were among the oldest patients in the series, which explains the high incidence of radiological OA at the last follow-up.

### 4.2. Predisposing factors

The relationship between quadriceps tendon ruptures and certain predisposing factors such as diabetes, gout, long-term corticosteroid therapy, fluoroquinolones treatment, chronic kidney failure with tertiary hyperparathyroidism and gouty arthritis is an accepted fact [12]. This can be explained by histological changes in tendons likely to rupture, and compounded by hypovascularization in certain rupture-susceptible areas of the quadriceps tendon [13,14].

In the current study, 11% of patients had predisposing factors. This rate was low relative to the 35% risk factor rate in the Vidil et al. study [3]. But if we included obesity, 37% of the patients in our series had at least one risk factor. Results in the three patients with bilateral rupture were no different than the remainder of the patient series [15].

## 5. Results analysis

The results of the current study are consistent with published studies in terms of good and very good functional outcomes. Vidil et al. [3] reported that 89.5% of patients were satisfied, with very good (53.5%) or good (36%) subjective results. One study had found mean flexion of  $123^\circ$  with a  $2^\circ$  active extension deficit [5]. Return to work without reassignment was possible in 97% of our working-age patients. This was similar to the O'Shea et al. study [4], where 95% of patients had returned to their previous activity level (Table 4).

The typical repair technique used in our surgery department consisted of transosseous quadriceps tendon reattachment using sutures. But this technique is not the only one in use. Some authors advocate using suture anchors, although there is no proof this method is better. Also, biomechanical studies have not found any significant differences in terms of repair strength. A cadaver study comparing the two techniques found that transosseous tunnels provided higher strength [16].

We immobilized the lower limb in a leg cylinder cast for at least six weeks. Some authors advocate early rehabilitation, but have found no significant differences in terms of the range of motion and functional results. We prefer to protect the suture repair because a repeat rupture irremediably affects the prognosis. Rougraff et al. [5]

**Table 4**  
Literature Review.

Series	Sample size	Flexion (degrees)	Lysholm (/100)	Strength/healthy side	Subjective results
Vidil (2004)	47	128 (90–150)	–	4.8/5	90% good and very good results
O'Shea (2002)	27	116 (88–135)	–	No difference	22.9/25 (excellent)
Konrath (1998)	40	125	87 (35–100)	32% patients with 20% deficit	–
Rougraff (1996)	44	123	–	15% patients with 20% deficit	8.5/10
Boudissa (2013)	68	133	94(56–100)	4.9/5	98% good and very good results

found no difference between early rehabilitation and immobilization. West et al. [17] found that with intratendinous ruptures, loose suturing in combination with early rehabilitation did not lead to secondary ruptures within the four years of follow-up. Langenhan et al. [18] compared two rehabilitation protocols: one with weight bearing and immediate progressive mobilization, the other without weight bearing and mobilization beyond 30° after six weeks. He also found no differences in terms of results and complications.

Postoperative complications are rare in this type of surgery and occurred in only 3% of our patients. Late complications are also quite rare, but will negatively affect the prognosis. Complex regional pain syndrome, repeat rupture and persistent joint stiffness are all worrisome scenarios.

## 6. Conclusion

Quadriceps tendon rupture is a relatively uncommon injury that is usually seen in patients older than 40 years of age in the context of a fall with sudden quadriceps muscle contraction. If the injury is diagnosed right away, the prognosis is good. Surgical treatment is required and at least six weeks of postoperative immobilization with intense rehabilitation are needed to attain satisfactory functional outcomes.

## Disclosure of interest

The authors declare that they have no conflicts of interest concerning this article.

## References

- [1] Saragaglia D, Pison A, Rubens-Duval B. Acute and old ruptures of the extensor apparatus of the knee in adults (excluding knee replacement). *Orthop Traumatol Surg Res* 2013;99(Suppl 1):S67–76.
- [2] Waligora AC, Johanson NA, Hirsch BE. Clinical anatomy of the quadriceps femoris and extensor apparatus of the knee. *Clin Orthop Relat Res* 2009;467:3297–306.
- [3] Vidil A, Ouaknine M, Anract P, Tomeno B. Trauma-induced tears of the quadriceps tendon: 47 cases. *Rev Chir Orthop* 2004;90:40–8.
- [4] O'Shea K, Kenny P, Donovan J, Condon F, McElwain JP. Outcomes following quadriceps tendon ruptures. *Injury* 2002;33:257–60.
- [5] Rougraff BT, Reeck CC, Essenmacher J. Complete quadriceps tendon ruptures. *Orthopedics* 1996;19:509–14.
- [6] Konrath GA, Chen D, Lock T, Goitz HT, Watson JT, Moed BR, et al. Outcomes following repair of quadriceps tendon ruptures. *J Orthop Trauma* 1998;12:273–9.
- [7] Ciriello V, Gudipati S, Tosounidis T, Soucacos PN, Giannoudis PV. Clinical outcomes after repair of quadriceps tendon rupture: a systematic review. *Injury* 2012;43:1931–8.
- [8] Caton J, Deschamps G, Chambat P, Lerat JL, Dejour H. Les rotules basses (*Patellae inferae*): à propos de 128 observations. *Rev Chir Orthop* 1982;68:317–25.
- [9] Lysholm J, Gilquist J. Evaluation of knee ligament surgery results with special emphasis on use of a scoring scale. *Am J Sports Med* 1982;10:150–4.
- [10] Tegner Y, Lysholm J, Gillquist J, Oberg B. Two-year follow-up of conservative treatment of knee ligament injuries. *Acta Orthop Scand* 1984;55:176–80.
- [11] Iwano T, Kurosawa H, Tokuyama H, Hoshikawa Y. Roentgenographic and clinical findings of patellofemoral osteoarthritis. With special reference to its relationship to femorotibial osteoarthritis and etiologic factors. *Clin Orthop Relat Res* 1990;252:190–7.
- [12] Grecomoro J, Camarda L, Martorana U. Simultaneous chronic rupture of quadriceps tendon and contra-lateral patellar tendon in a patient affected by tertiary hyperparathyroidism. *J Orthop Traumatol* 2008;9:159–62.
- [13] Maffulli N, Del Buono A, Spiezia F, Longo UG, Denaro V. Light microscopic histology of quadriceps tendon ruptures. *Int Orthop* 2012;36:2367–71.
- [14] Yepes H, Tang M, Morris SF, Stanish WD. Relationship between hypovascular zones and patterns of ruptures of the quadriceps tendon. *J Bone Joint Surg Am* 2008;90:2135–41.
- [15] Gaheer RS, Hawkins A. Rapid recovery from spontaneous and simultaneous bilateral quadriceps tendon rupture in an active, healthy individual. *Orthopedics* 2010;33:512–4.
- [16] Hart ND, Wallace MK, Scovell JF, Krupp RJ, Cook C, Wyland DJ. Quadriceps tendon rupture: a biomechanical comparison of transosseous equivalent double-row suture anchor versus transosseous tunnel repair. *J Knee Surg* 2012;25:335–9.
- [17] West JL, Keene JS, Kaplan LD. Early motion after quadriceps and patellar tendon repairs: outcomes with single-suture augmentation. *Am J Sports Med* 2008;36:316–23.
- [18] Langenhan R, Baumann M, Ricart P, Hak D, Probst A, Badke A, et al. Postoperative functional rehabilitation after repair of quadriceps tendon ruptures: a comparison of two different protocols. *Knee Surg Sports Traumatol Arthrosc* 2012;20:2275–8.