



ELSEVIER

Revista da
ASSOCIAÇÃO MÉDICA BRASILEIRA

www.ramb.org.br


Image in Medicine

A giant aneurysm from the petrous carotid presenting with isolated peripheral facial palsy[☆]

Aneurisma gigante da carótida petrosa apresentando paralisia facial periférica isolada

Pedro Tadao Hamamoto Filho*, Vitor Cesar Machado, Carlos Clayton Macedo-de-Freitas

Discipline of Neurosurgery, Faculdade de Medicina de Botucatu, Universidade Estadual Paulista Julio de Mesquita Filho (Unesp), Botucatu, SP, Brazil

Introduction

Carotid aneurysms from the petrous segment are rare. They are usually asymptomatic and do not present with a sub-arachnoid haemorrhage. Clinical presentation depends on aneurysm's location, size, and direction of growth. Aneurysms in close proximity to the medium ear may cause hypoacusis and tinnitus. Otorrhagia and epistaxis may also occur after the rupture of an aneurysm, as well as Horner's syndrome and symptoms of the jugular foramen nerves. The involvement of the VII nerve is not common. Current treatment options include carotid artery balloon occlusion, whether or not followed by a bypass through the external carotid; embolization with coils; remodelling with stents; or a conservative management by serial imaging exams.¹

Case report

A 77-year-old woman, previously diagnosed with arterial hypertension, was referred to this service within two months of her diagnosis of progressive right facial palsy. She presented

no other symptoms. Aside from right peripheral facial palsy (House-Brackmann score grade IV), her neurological examination appeared normal. A magnetic resonance image showed a large aneurysm arising from the petrous segment of the right internal carotid (Figs. 1 and 2).

An angiogram was performed (Fig. 3). The patient could not tolerate a balloon occlusion test. On the next day, an unremarkable embolization with coil placement was performed. Cerebral blood flow was not modified, and the aneurysm was partially occluded with coils. The patient was discharged after two days, without any other deficit besides facial palsy.

Discussion

Carotid aneurysms from the petrous segment are not common, and its presentation with an isolated peripheral facial palsy is even more rare. This article reported this rare condition.

The internal carotid petrous segment extends from the carotid's entrance to the cranium, through the carotid channel (anterior to the jugular foramen and medial from the styloid processes), until their emergence through the cavernous

[☆] Study conducted at the Department of Neurology, Psychology, and Psychiatry of the Faculdade de Medicina of the Universidade Estadual Paulista Júlio de Mesquita Filho, Botucatu, SP, Brazil.

* Corresponding author.

E-mail: pthamamotof@hotmail.com (P.T. Hamamoto Filho)

0104-4230 © 2012 Elsevier Editora Ltda. Este é um artigo Open Access sob a licença de [CC BY-NC-ND](http://creativecommons.org/licenses/by-nc-nd/4.0/)

<http://dx.doi.org/10.1016/j.ramb.2013.07.004>

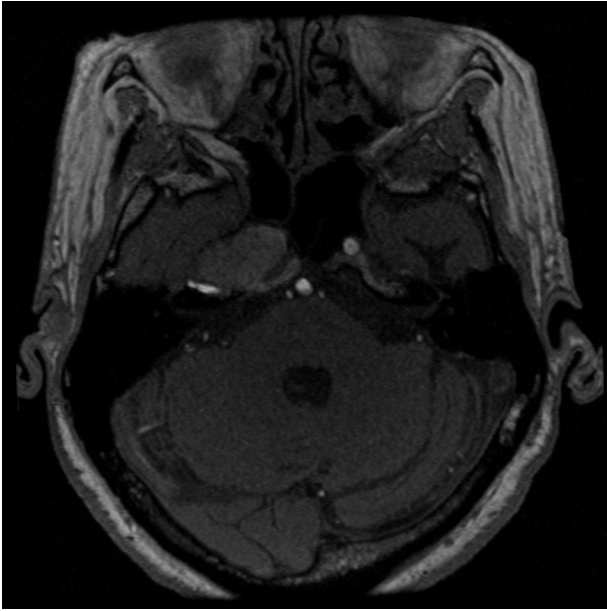


Fig. 1 – A high-resolution magnetic resonance angiography showing the aneurysm within the right carotid channel.

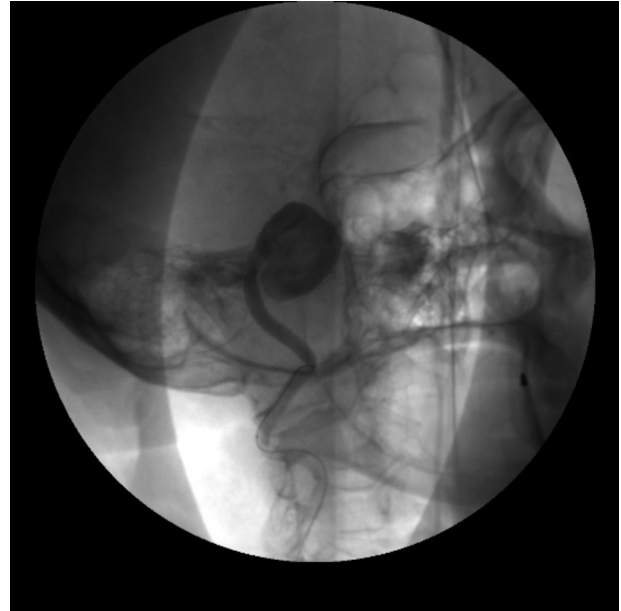

Fig. 3 – An angiogram with selective catheterization of right carotid showing the aneurysm.

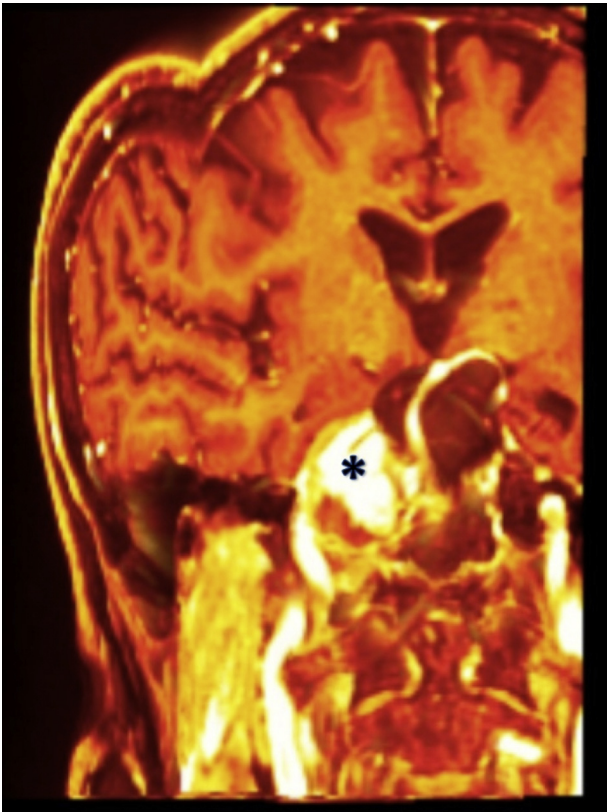


Fig. 2 – A 3-D magnetic resonance angiography reconstruction showing the aneurysm (*) in tight relation to the petrous bone.

sinus. In the petrous segment, the carotid has two main components: vertical and horizontal, with a knee in between. Two branches may arise from the petrous carotid: the vidian and caroticotympanic arteries. The vidian artery passes anteriorly and inferiorly through the foramen lacerous, and anastomoses with external carotid branches. The caroticotympanic artery is an embryonic vestige of the hyoid artery that originates from the petrous carotid knee and passes superiorly through the stapedius to supply blood into the medium ear cavity.^{1,2}

There are three proposed mechanisms in the etiology of aneurysms from the carotid petrous portion: mycotic, traumatic, and congenital.

Infections and inflammations of the medium ear may erode bony structures and involve the artery adventitia, which can become weak and predispose the medium ear to aneurysmal dilatation.³⁻⁶

The cervical petrous transition of the carotid artery makes it susceptible to stretch forces, which in turn make this segment amenable to dissections and pseudoaneurysms, since the cervical portion is mobile and the petrous portion is not.²

Fibromuscular dysplasias have been suggested to be the cause of congenital aneurysms of the petrous carotid. Muscle defects were found at the acute angle of the artery branches' emerging areas. In fact, most of the aneurysms of this segment were found at the caroticotympanic segment.^{7,8}

In the present patient, there was no previous history of trauma or ear infection, and thus, a congenital abnormality was considered.

These aneurysms are generally asymptomatic, and diagnosed as imaging findings. Therefore, the clinical presentation, when present, is variable and depends on the location, size, and direction of growth. Horner's syndrome may occur due to the involvement of sympathetic fibres. Defects in the

IX, X, XI, and XII nerves may occur when the aneurysm extends posteriorly and inferiorly. Ocular movements are affected with aneurysms from the cavernous segment, but not from the petrous segment. The involvement of the VII nerve is uncommon, and generally accompanied by VIII nerve symptoms, such as hypoacusis and tinnitus.

A report by McCarron demonstrated a peripheral facial palsy caused by a carotid dissection through the petrous area. Two hypotheses were considered for this clinical manifestation: a mechanical compression of the nerve, and an alteration of its vascular supply due to emboli or local hemodynamic changes.⁹ These pathophysiological mechanisms are possible in the case of an anatomical variation, in which the internal carotid is responsible for the supply of the VII nerve. Although in the majority of the cases the VII nerve vascular supply is maintained by the external carotid system via the middle meningeal arterial branches, it is believed that McCarron's proposed mechanism could explain the present patient's clinical presentation.

Treatment options include conservative management with serial images; carotid surgical trapping and revascularization with a bypass; endovascular internal carotid balloon occlusion; embolization with coil placement, with or without stent assistance; and flow diverting techniques.

Asymptomatic patients with an incidental diagnosis could be managed conservatively with serial images. Patients who present with bleeding should quickly undergo a more aggressive treatment, either open surgery or endovascular techniques. In cases of symptomatic patients presenting with cranial nerve changes without an aneurysm rupture, the risks and benefits of each procedure should be carefully analyzed. These risks include carotid occlusion and surgical morbidity. Any benefits would revolve around avoiding the growth of the aneurysm. In patients with a pseudoaneurysm, there is a higher risk for rupture and bleeding, leading to a life-threatening condition; thus, more aggressive options should be considered.

Carotid occlusion may not be possible in patients without sufficient collateral flow, as bypass revascularization surgery is not commonly available. The use of stents is inconvenient due to prolonged anti-aggregation therapy.

Conflicts of interest

The authors declare no conflicts of interest.

REFERENCES

1. Liu JK, Gottfried ON, Amini A, Couldwell WT. Aneurysms of the petrous internal carotid artery: anatomy, origins, and treatment. *Neurosurg Focus*. 2004;17:E13.
2. Palacios E, Gómez J, Alvernia JE, Jacob C. Aneurysm of the petrous portion of the internal carotid artery at the foramen lacerum: anatomic, imaging and otologic findings. *Ear Nose Throat J*. 2010;89:303-5.
3. Ehni G, Barrett JH. Hemorrhage from the ear due to an aneurysm of internal carotid. *N Engl J Med*. 1960;262:1323-5.
4. Morantz RA, Kirchner FR, Kishore P. Aneurysms of the petrous portion of the internal carotid artery. *Surg Neurol*. 1976;6:313-8.
5. McGrail KM, Heros RC, Debrun G, Beyerl BD. Aneurysm of the ICA petrous segment treated by balloon entrapment after EC-IC bypass. *J Neurosurg*. 1986;65:249-52.
6. Oyama H, Hattori K, Tanahashi S, Kito A, Maki H, Tanahashi K. Ruptured pseudoaneurysm of the petrous internal carotid artery caused by chronic otitis media. *Neurol Med Chir (Tokyo)*. 2010;50:578-80.
7. Bergès C, Pollak A, Valavanis A, Fisch U. Gradual facial palsy and intrapetrous internal carotid aneurysm: a case report. *Skull Base Surg*. 1993;3(3):164-9.
8. Guha A, Montanera W, Hoffman HJ. Congenital aneurysmal dilatation of the petrous-cavernous carotid artery and vertebral basilar junction in a child. *Neurosurgery*. 1990;26:322-7.
9. McCarron MO, Metcalfe RA, Muir KW. Facial nerve palsy secondary to internal carotid artery dissection. *Eur J Neurol*. 2000;7:723-5.