

Contents lists available at [ScienceDirect](http://ScienceDirect.com)

Journal of Arrhythmia

journal homepage: www.elsevier.com/locate/joa

CrossMark

Original Article

Radiofrequency catheter ablation of left-sided accessory pathways via retrograde aortic approach in children

Canan Ayabakan, MD^{a,*}, Murat Şahin, MD^{b,1}, Alpay Çeliker, MD^{b,1}^a Department of Pediatric Cardiology, Baskent University, Istanbul Research Hospital, Istanbul, Turkey^b Department of Pediatric Cardiology, Acibadem University, Istanbul, Turkey

ARTICLE INFO

Article history:

Received 24 August 2015

Received in revised form

15 December 2015

Accepted 25 December 2015

Available online 11 February 2016

Keywords:

Pediatric

Left sided accessory pathway

Retrograde

Radiofrequency ablation

ABSTRACT

Background: We aimed to analyze the results of retrograde aortic radiofrequency catheter ablation of left-sided accessory pathways in children.**Methods:** Between January 2010 and September 2014, 25 children who underwent left-sided accessory pathway ablation with a retrograde aortic approach were evaluated retrospectively.**Results:** The mean age of the patients was 11.09 ± 3.71 years. Seventeen patients were male (68%). The mean procedure and fluoroscopy times were 71.54 ± 21.05 min and 31.42 ± 19.57 min, respectively. Radiofrequency energy was delivered with 41.38 ± 15.32 W at 52.38 ± 5.45 °C. Sixteen patients (64%) presented with manifest preexcitation and, 9 had concealed accessory pathways. The location of accessory pathway was left lateral in 16 patients, posteroseptal in 5, left anterolateral in 2, and left posterolateral and left posterior in the remaining 2. The acute success rate was 96%. The patients were followed for a mean of 16.68 ± 18.01 months. There were 2 recurrences. No major complications were observed in the peri-procedural period. One patient had groin hematoma, another one had transient severe headache and vomiting. Trivial mitral regurgitation was noted in a patient, which remained the same throughout follow-up. None of the patients developed new aortic regurgitation, pericardial effusion, or thrombi at the site of ablation.**Conclusions:** The retrograde aortic approach can be safely employed with a high success rate for ablation of left-sided accessory pathways in children.© 2016 Japanese Heart Rhythm Society. Published by Elsevier B.V. This is an open access article under the CC BY-NC-ND license (<http://creativecommons.org/licenses/by-nc-nd/4.0/>).

1. Introduction

Radiofrequency (RF) catheter ablation is an established method of therapy for symptomatic supraventricular tachycardia (SVT). It has gained widespread acceptance for the treatment of accessory pathways in pediatric SVTs [1]. Accessory pathways are distributed unevenly along the right and left atrioventricular valve annuli. The left-sided accessory pathways are most common and may be accessed by using the transseptal approach or the retrograde aortic approach, or less commonly, from within the coronary sinus. Each approach has proven to be successful, but has a unique set of risks [2].

Abbreviations: AP, accessory pathway; AVNRT, atrioventricular nodal reentrant tachycardia; AVRT, atrioventricular reentrant tachycardia; CS, coronary sinus; EPS, electrophysiologic study; RF, radiofrequency; SD, standard deviation; SVT, supraventricular tachycardia; WPW, Wolff–Parkinson–White.

* Correspondence to: Pediatric Kardiyoloji Bölümü, Başkent Üniversitesi İstanbul Sağlık Uygulama ve Araştırma Hastanesi, Oymacı sok. No: 7 Altunizade, İstanbul 34662, Turkey. Tel.: +90 216 554 1500x2012; fax: +90 216 325 1259.

E-mail addresses: cayabakan@yahoo.com, maslakinfo@asg.com.tr (C. Ayabakan).

¹ Acibadem Üniversitesi, Pediatric Kardiyoloji Bölümü, Büyükdere Cad. No: 40 Maslak, İstanbul 34457, Turkey. Tel.: +90 212 304 44 44; fax: +90 212 304 44 40.

<http://dx.doi.org/10.1016/j.joa.2015.12.007>

1880-4276/© 2016 Japanese Heart Rhythm Society. Published by Elsevier B.V. This is an open access article under the CC BY-NC-ND license (<http://creativecommons.org/licenses/by-nc-nd/4.0/>).

The aim of the present study was to analyze the data of retrograde aortic RF catheter ablation of left-sided accessory pathways in children.

2. Materials and methods

Our institutional ethical committee approved this clinical study. All consecutive patients with left-sided accessory pathways treated with RF through a retrograde aortic approach were analyzed. The following peri-interventional parameters were noted: procedure time (measured from the first femoral puncture to removal of all sheaths), fluoroscopy time, total duration of RF application, maximum power of RF energy and maximum temperature attained during RF application.

2.1. Electrophysiologic study procedure and ablation technique

The antiarrhythmic drugs were discontinued for 5 half lives before the electrophysiologic study (EPS). After obtaining written informed consent from the parents, all patients underwent EPS

followed by the ablation procedure in a conscious sedation state. Midazolam, propofol, and ketamin were used for anesthesia as needed.

A 6- or 7-F decapolar catheter was positioned inside the coronary sinus. Other diagnostic catheters (usually 5-F quadripolar) were placed in the right ventricular apex, high right atrium, or bundle of His region. The baseline measurements of conduction and refractoriness were performed in sinus rhythm. The PR, QRS, QT, AH, and HV intervals, basal cycle length, and atrioventricular and ventriculoatrial Wenckebach cycle lengths were measured. Programmed atrial and ventricular stimulations were made in an attempt to initiate the atrioventricular reentrant tachycardia (AVRT), to locate the earliest atrial activation site. In case of pre-excitation, the position of the accessory pathway was delineated by assessing the site with the earliest ventricular activation during sinus or paced atrial beat rhythm.

2.2. Retrograde approach

After preliminary mapping, when the presence of a left-sided accessory pathway with the absence of patent foramen ovale was confirmed, a 7-Fr sheath was placed into the right femoral artery. At this point, all patients underwent full heparinization with 100–150 units/kg. A 7-Fr, single curve, tip-deflecting bipolar catheter (Medtronic RF Mariner 110 cm to 2.3 mm) with an electrode size of 4 mm and deflectable tip length of 40–60 mm was inserted through the sheath, advanced to the aorta, and prolapsed through the aortic valve, making a large “J” loop. The catheter was then placed at a site that had the shortest interval between local atrial and ventricular electrograms (during sinus rhythm in the presence of manifest preexcitation) or at the site of earliest retrograde activation (during orthodromic reciprocating tachycardia or ventricular pacing in the presence of concealed accessory pathway). A 5-Fr single curve, 4 mm tip-deflecting bipolar catheter (Medtronic RF Mariner 110 cm to 2.3 mm) was used through a 5-Fr sheath only for the youngest of our patients, who was 4 years old. The trans-septal approach was not utilized in any of these patients, simultaneously or in a separate session.

Fig. 2 shows the placement of coronary sinus and ablation catheters in the right and left anterior oblique positions under fluoroscopy. The RF energy was delivered with a maximum power of 50 W for 10–60 s at the target site until a temperature of 50–60 °C was reached at the catheter tip. The RF energy was given for at least 120 s, when the accessory pathway conduction was abolished. If a sudden increase in impedance occurred during energy application, energy delivery was automatically discontinued.

2.3. Post procedural follow-up

All patients were monitored in the hospital for rhythm and other electrocardiogram (ECG) abnormalities like ST level and T wave changes, suggesting myocardial ischemia. They were also observed for complications like groin hematomas and loss of peripheral pulses. An ECG and echocardiogram were performed before discharge. Mitral/aortic regurgitation, pericardial effusion, and left ventricular systolic functions were specifically monitored. The patients were discharged on aspirin (5 mg/kg/day), which they took for the next 3 months. All patients were seen within 1 week and 4–6 weeks after the procedure; they paid regular biannual visits to the outpatient clinics thereafter, unless they had recurrence of symptoms.

2.4. Statistics

The variables were analyzed by using SPSS 15.0 for Windows (SPSS Inc., 1989–2006). Continuous variables are presented as

mean \pm standard deviation. In case of non-Gaussian distribution, median and quartile values are given. Categorical variables are expressed as number and percentage. *P*-values of <0.05 were accepted as statistically significant.

3. Results

Between January 2010 and September 2014, 59 children underwent accessory pathway ablation, of which 25 (42.4%) had their left-sided accessory pathways accessed via the retrograde aortic approach. The other 34 patients underwent right-sided accessory pathway ablation. The mean age of the patients during the intervention was 11.09 ± 3.71 years (quartiles: 7.96, 12.25, 14.0 years). Our youngest patient was a 17-kg, 105-cm, 4-year-old boy. Seventeen patients (68%) were male, and 8 (32%), female. The mean body weight and height were 49.56 ± 24.92 kg (quartiles 35.5, 46.8, 54.5 kg) and 148.48 ± 18.34 cm (quartiles 135.5, 149.0, 161.0 cm), respectively.

The mean procedure time was 71.54 ± 21.05 min (quartiles 60.0, 70.0, 80.0 min); the fluoroscopy time was 31.42 ± 19.57 min (quartiles 18.73, 26.0, 39.15 min). The RF energy was delivered with 41.38 ± 15.33 W (quartiles 34.75, 47.0, 50.0 W) at 52.38 ± 5.45 °C (quartiles 47.0, 51.50, 57.75 °C) for a total of 5.16 ± 3.14 min (quartiles 3.0, 4.2, 6.4 min). The procedural details are given in Table 1. Sixteen patients (64%) presented with manifest preexcitation on ECG; the remaining 9 patients had only retrograde conduction from the accessory pathway (concealed pathway). Clinical tachycardia was induced in 15 patients (60%), either spontaneously or with atrial/ventricular stimulation. In 3 patients, atrial fibrillation was induced during programmed stimulation along with the reentrant SVT. One of these patients had corrected transposition of the great arteries.

Four patients had accompanying dual AV node physiology, however, atrioventricular nodal reentrant tachycardia (AVNRT) was not induced in the cath-lab, and none of these patients presented with tachycardia (AVRT or AVNRT) after successful ablation of the accessory pathway. Another patient, however, had slow pathway modification for AVNRT before the current retrograde approach. During the initial EPS of this patient, the only inducible tachycardia was AVNRT, which was successfully eliminated with slow pathway modification. However, SVT recurred about a year after the procedure. The second EPS identified the left-sided accessory pathway, which was successfully ablated with a retrograde approach.

The location of the accessory pathway was left lateral in 16 patients, posteroseptal in 5, left anterolateral in 2, and left posterolateral and left posterior in the remaining 2 (Fig. 1). Our

Table 1
Details of the Catheter Ablation Procedure.

	Mean \pm standard deviation	Quartiles (25, 50, 75)
Age at ablation (years)	11.09 ± 3.71	(7.96, 12.25, 14.00)
Sex (female/male)	8/17 (%32/%68)	
Body weight (kg)	49.56 ± 24.92	(33.50, 46.80, 54.50)
Procedure time (min)	71.54 ± 21.05	(60.00, 70.00, 80.00)
Fluoroscopy time (min)	31.42 ± 19.57	(18.73, 26.00, 39.50)
Local temperature (°C)	52.38 ± 5.45	(47.00, 51.50, 57.75)
Duration of RF application (min)	5.16 ± 3.14	(3.00, 4.20, 6.40)
Follow-up (months)	16.88 ± 18.01	(6.00, 6.00, 19.50)

Location of accessory pathways

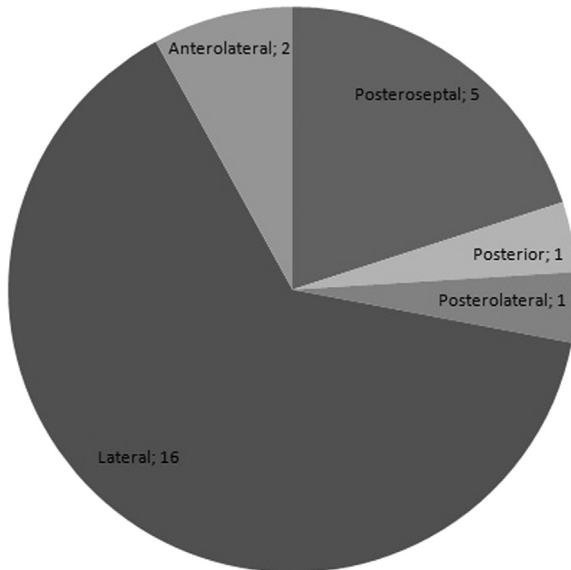


Fig. 1. Location of the accessory pathways.

youngest patient had Wolff–Parkinson–White (WPW) syndrome with a left lateral location. The accessory pathway was successfully ablated in this patient, without complications. No recurrence was observed during 12 months of follow-up (Fig. 2).

The acute success rate in our study group was 96% (24/25 patients). In the patient with WPW syndrome, ablation of the site with earliest ventricular activation, which was located on the left lateral wall, could not eliminate preexcitation even at a temperature of 50 °C, which was attained with 50 W of energy. Clinical tachycardia could not be induced with programmed stimulations. Instead, atrial flutter with ventricular rate of 177/min was induced. The flutter converted to reentrant tachycardia with atrial overdrive pacing and ended with burst atrial stimulations. Repeated trials of tachycardia induction were unsuccessful. The ablation attempt was unsuccessful for this patient.

The patients were followed-up for a mean of 16.68 ± 18.01 months (quartiles: 6, 6, 19.5 months). There were 2 recurrences. The left lateral concealed accessory pathway was successfully ablated in a 14-year-old boy; however, SVT recurred the day following ablation, and it was treated with 300 mg/m²/day propafenone. The patient is still on this medication, without symptoms. Preexcitation returned 19 months after the ablation of a manifest accessory pathway in another patient. The patient was asymptomatic and was followed-up with no medication for 54 months. He presented with SVT (heart rate 203/min), which appeared to be ectopic atrial tachycardia on surface ECG. This patient was receiving methylphenidate for attention deficit syndrome and hyperactivity disorder since 2 months before the presentation. The tachycardia converted to sinus rhythm spontaneously. Methylphenidate was stopped, and propafenone administration was started. EPS and ablation are planned for this patient.

No major complications were observed in the periprocedural period. There was no loss of femoral pulses in any of the patients. Only 1 patient had groin hematoma, which was treated with rest and leg elevation. One patient had severe headache and vomiting, which lasted for several hours after the procedure. The neurological examination was normal, and the condition healed spontaneously. Trivial mitral regurgitation was noted in a patient before discharge, which remained unchanged throughout follow-up. No

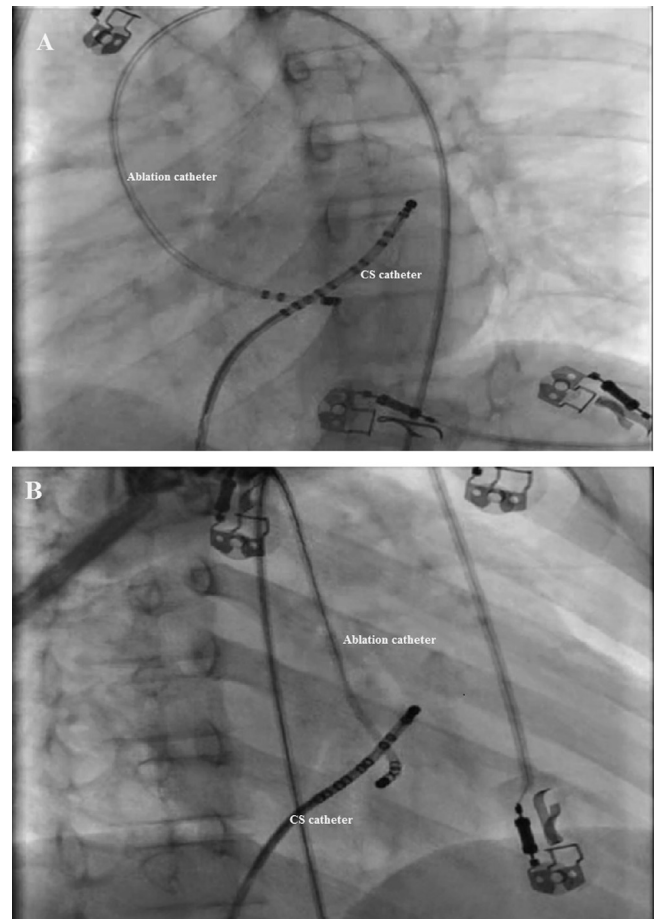


Fig. 2. The placement of coronary sinus and ablation catheters in a left lateral accessory pathway under fluoroscopy. (A) left anterior oblique position (B) right anterior oblique position, CS: coronary sinus.

patient developed new aortic regurgitation, pericardial effusion, or thrombi at the site of ablation.

4. Discussion

Catheter ablation of left-sided accessory pathways has proven to be highly successful and has the lowest risk of recurrence; yet it seems to be associated with greater risk of complications than do right-sided accessory pathways. The overall acute success rate in our study was 96%. The attempt was unsuccessful in 1 patient with WPW syndrome.

There were 2 recurrences (8.3%, 2 out of 24 patients), 1 of which occurred immediately following the procedure. In this patient, SVT was not induced with programmed atrial or ventricular stimulations after the ablation of accessory pathway. Ventriculoatrial conduction was through the AV node upon ventricular stimulation. However, the patient developed SVT the next day and was treated with propafenone. The other patient had late recurrence of a manifest accessory pathway, which was asymptomatic for a long time. The SVT, which was atrial ectopic tachycardia, was probably induced with the use of a neurostimulant having potential chronotropic and proarrhythmic side effects. Our acute success rate and recurrence rate are comparable to other studies [2–5]. Lesh et al. [3] reported 85% successful elimination and 2.24% recurrence rate of left-sided accessory pathways. Calkins et al. [6] had an 87% success rate with a retrograde approach.

The retrograde aortic approach has the potential for complications related to arterial access and manipulation of a stiff catheter across the aortic valve [7,8]. In certain cases, close proximity of the RF catheter to the coronary arteries or the mitral valve may cause injury at these sites. However, it is a simpler and less time consuming approach in terms of access. Alternatively, the transeptal approach needs special training and has potential procedural risks including pericardial effusion and cardiac tamponade. A learning curve is associated with this technique and is inversely related to the complication rate. Katritsis et al. [9] documented 1.27% cardiac tamponade among 393 patients with the use of the transeptal access. In a study by von Alvensleben et al. [10], the incidence of pericardial effusion was 1.9% among pediatric patients undergoing transeptal ablation. Tang et al. [11] described ST-T wave elevation during 0.38% of the transeptal ablation procedures. We do not favor transeptal approach for pediatric patients in our institution mainly because of the lack of special skill in performing this technique in children.

Lesh et al. [3] reported a 6.7% complication rate during the retrograde approach, most of which were attributable to arterial access. The most serious complication was the dissection of the left main coronary artery in 1 patient. In this procedure, the ablation catheter tip had lodged briefly in the left coronary artery during an attempt to cross the aortic valve. Lesh et al. [3] found no difference in the incidence and severity of complications when they compared the retrograde and transeptal approaches. The success rate and total procedure and fluoroscopy times were similar.

In our study group, no major complications were observed; only 1 patient had groin hematoma, which recovered without any consequences. The overall minor complication rate was 12% (3 patients out of 25). Mean procedure and fluoroscopy times were shorter in our study, compared to those in the study of Lesh et al. (procedure time 71.54 ± 21.05 min, fluoroscopy time $31.42.60 \pm 19.57$ min in our study vs. 220 ± 12.8 min and 44.1 ± 4.4 min, in the study of Lesh et al.). Nevertheless, the patient with an unsuccessful procedure had very long fluoroscopy time of 86 min. Expectantly, 3-dimensional electroanatomic mapping may eliminate or reduce fluoroscopy duration in such difficult cases while performing safe and effective accessory pathway ablations.

Injury to valvular structures has occasionally been described related to left-sided ablations. The frequency of lesions has been as high as 12% for the mitral valve and 30% for the aortic valve [7]. The aortic valve may be injured either directly by the catheter tip when it is passed through the valve or by compression and stretching of the cusps by the catheter shaft during prolonged placement in the ventricle. Olsson et al. [15] studied the frequency of valvular insufficiency after the long-term follow-up of retrograde aortic RF catheter ablation procedures. They demonstrated the incidence of valvular damage as 1.9% among 179 patients (mitral regurgitation: 2 patients; aortic regurgitation: 2 patients). Injuries are likely to be related to the duration of the procedure and number of energy applications and passes through the aortic valve.

Ablation of a left-sided accessory pathway requires delivery of RF current to the tissue near the mitral valve annular ring. These lesions may potentially cause mitral injury. Sometimes a trapped leaflet or chordae underneath the tip of the catheter may cause the insufficiency [7,8,12–14]. However, approaching the mitral annulus via transeptal puncture from the atrial side or retrograde from the ventricular side does not seem to produce superior results. Studies have failed to show significant difference in these techniques in terms of success or complication rates [3,5]. We speculate that because there is variation in the anatomy of mitral annulus, some pathways may be more closely approached by one or the other method.

Although there are data indicating the small risk of valvular injury during RF procedures using the retrograde aortic approach, the use of smaller-diameter, more flexible catheters and modern RF equipment with temperature control, facilitates shorter procedures and reduces the risk of valvular damage. The operator's skill and experience are equally important. In our study, only 1 patient had mild mitral regurgitation after catheter ablation (4%); there were no new aortic regurgitations throughout the follow-up.

The retrograde approach may safely be performed in young children. Our youngest patient was 4 years old with WPW syndrome. The left lateral accessory pathway was successfully ablated in a fairly short procedure time (i.e. 45 min). No recurrence or complications were seen during the follow-up.

Cryoablation may be considered a safer alternative to RF ablation, primarily due to the potential for reversible tissue injury with cryomapping and catheter stability due to adhesion. Cryoablation was used successfully by Gist et al. [16] in the treatment of left-sided accessory pathways in pediatric patients. The procedures were performed transeptally, with an observed acute success rate of 97% and recurrence rate of 4.2%. However, by using RF ablation, we refrained from using the stiffer and thicker cryoablation catheter while passing through the aortic valve.

5. Conclusions

Our favorable experience with retrograde transaortic approach encourages utilizing this technique for left-sided accessory pathways in children beginning at 4 years of age. Since the complication rate is also reported to be comparable to that of the transeptal approach, both methods may be used as complementary procedures to reach an overall success rate close to 100%.

Conflict of interest

The authors disclose that there are no associations that pose a conflict of interest in connection with the manuscript, nor do they have any affiliations, funding sources, or financial holdings that might raise questions about possible causes of bias.

References

- [1] Van Hare GF, Lesh MD, Scheinman MM, et al. Percutaneous radiofrequency catheter ablation for supraventricular arrhythmias in children. *J Am Coll Cardiol* 1991;17:1613–20.
- [2] Etheridge SP. Radiofrequency catheter ablation of left-sided accessory pathways in pediatric patients. *Prog Pediatr Cardiol* 2001;13:11–24.
- [3] Lesh MD, Van Hare GF, Scheinman MM, et al. Comparison of the retrograde and transeptal methods for ablation of left free wall accessory pathways. *J Am Coll Cardiol* 1993;22:542–9.
- [4] Fiala M, Heinc P, Lukl J. Radiofrequency catheter ablation of left-sided atrioventricular accessory pathways. Immediate and long-term results using the trans-aortic approach. *Vnitr Lek* 2000;46:92–5.
- [5] Kobza R, Kottkamp H, Priorkowski C, et al. Radiofrequency ablation of accessory pathways. *Z Kardiol* 2005;94:193–9.
- [6] Calkins H, Langberg J, Sousa J, et al. Radiofrequency catheter ablation of accessory atrioventricular connections in 250 patients. Abbreviated therapeutic approach to Wolff Parkinson White syndrome. *Circulation* 1992;85:1337–46.
- [7] Minich LL, Snider A, Dick II M. Doppler detection of valvular regurgitation after radiofrequency ablation of accessory connections. *Am J Cardiol* 1992;70:116–8.
- [8] Seifert MJ, Morady F, Calkins HG, et al. Aortic leaflet perforation during radiofrequency ablation. *Pacing Clin Electrophysiol* 1991;14:1582–5.
- [9] Katritsis GD, Siontis GC, Gazitzoglou E, et al. Complications of transeptal catheterization for different cardiac procedures. *Int J Cardiol* 2013;168:5352–4.
- [10] von Alvensleben JC, Dick II M, Bradley DJ, et al. Transeptal access in pediatric and congenital electrophysiology procedures: defining risk. *J Interv Card Electrophysiol* 2014;41:273–7.

- [11] Tang RB, Dong JZ, Long DY, et al. Incidence and clinical characteristics of transient ST-T elevation during transeptal catheterization for atrial fibrillation ablation. *Europace* 2014 pii278.
- [12] Greene TOI, Huang SK, Wagshal AB, et al. Cardiovascular complications after radiofrequency ablation of supraventricular tachyarrhythmias. *Am J Cardiol* 1994;74:615–7.
- [13] Conti JB, Geiser E, Curetis AB. Catheter entrapment in the mitral valve apparatus during radiofrequency ablation. *Pacing Clin Electrophysiol* 1994;17:1681–5.
- [14] Pires LA, Huang SK, Wagshal AB, et al. Clinical utility of routine transthoracic echocardiographic studies after uncomplicated radiofrequency catheter ablation: a prospective multicenter study. The Atakr investigation group. *Pacing Clin Electrophysiol* 1997;19:1502–7.
- [15] Olsson A, Darpö B, Bergfeldt L, et al. Frequency and long term follow-up of valvar insufficiency caused by retrograde aortic radiofrequency catheter ablation procedures. *Heart* 1999;81:292–6.
- [16] Gist KM, Bockoven JR, Lane J, et al. Acute success of cryoablation of left sided accessory pathways: a single institution study. *J Cardiovasc Electrophysiol* 2009;20:637–42.