



OTORHINOLARYNGOLOGY

www.bjorl.org



CASE REPORT

Chorda tympani schwannoma: one new case revealed during malignant otitis externa and review of the literature[☆]

Schwannoma da corda do tímpano diagnosticado no decurso de uma otite externa maligna: relato de caso e revisão da literatura

Marion Montava^{a,b,*}, Sophie Giusiano^c, Marianne Jolibert^d, Jean-Pierre Lavieille^{a,b}

^a Aix Marseille Université, Marseille, France

^b Hôpital de la Conception, Service d'Oto-rhino-laryngologie et de Chirurgie Cervico-Faciale, Marseille, France

^c Hôpital Nord, Service d'Anatomie et Cytologie Pathologiques, Marseille, France

^d Hôpital Nord, Service de Radiologie, Marseille, France

Received 2 September 2015; accepted 9 November 2015

Introduction

Facial nerve schwannomas (FNS) are a rare entity that are poorly reported in literature. Although the estimated prevalence is extremely low, FNS are the most common primary tumor of the facial nerve. FNS occur throughout the course of the facial nerve and its branches, and chorda tympani schwannomas are quite rare. In 2010, Huoh and Cheung reported that seven additional chorda tympani schwannoma had appeared in literature since the first report by Nager in 1969.^{1,2} Most of the cases were isolated, with only two cases reporting multiple neuromas in patients with neurofibromatosis.^{1,2} The presenting symptoms of isolated chorda tympani schwannoma were conductive hearing loss, tinnitus, and facial palsy.² Interestingly, taste disturbance

was not documented in any previous case.² All of the cases showed a mass obstructing the external auditory canal (EAC) or behind an intact tympanic membrane, thereby confirming a common clinical history of this rare entity.

This report relates the case of an 89-year-old male patient who presented a chorda tympani schwannoma disclosed during the management of malignant otitis externa (MOE). To the best of the authors' knowledge, this is the first case in literature with incidental radiological finding of asymptomatic chorda tympani schwannoma.

Case report

An 89-year-old male patient, who had had hypertension and type 2 diabetes mellitus for an extended period, presented to this tertiary care center with a six-month history of right earache, otorrhoea, and hearing loss. He had received oral antibiotics (amoxicillin-clavulanate) and local antibiotic eardrops during this interval. He denied tinnitus and vertigo. Otoscopy examination of the right ear revealed otorrhoea and inflammation of the EAC. The tympanic membrane was thickened and somewhat hemorrhagic in appearance but was otherwise intact. Cranial nerve examination revealed normal facial function. The patient reported

[☆] Please cite this article as: Montava M, Giusiano S, Jolibert M, Lavieille J-P. Chorda tympani schwannoma: one new case revealed during malignant otitis externa and review of the literature. Braz J Otorhinolaryngol. 2016. <http://dx.doi.org/10.1016/j.bjorl.2015.11.011>

* Corresponding author.

E-mail: marion.montava@ap-hm.fr (M. Montava).

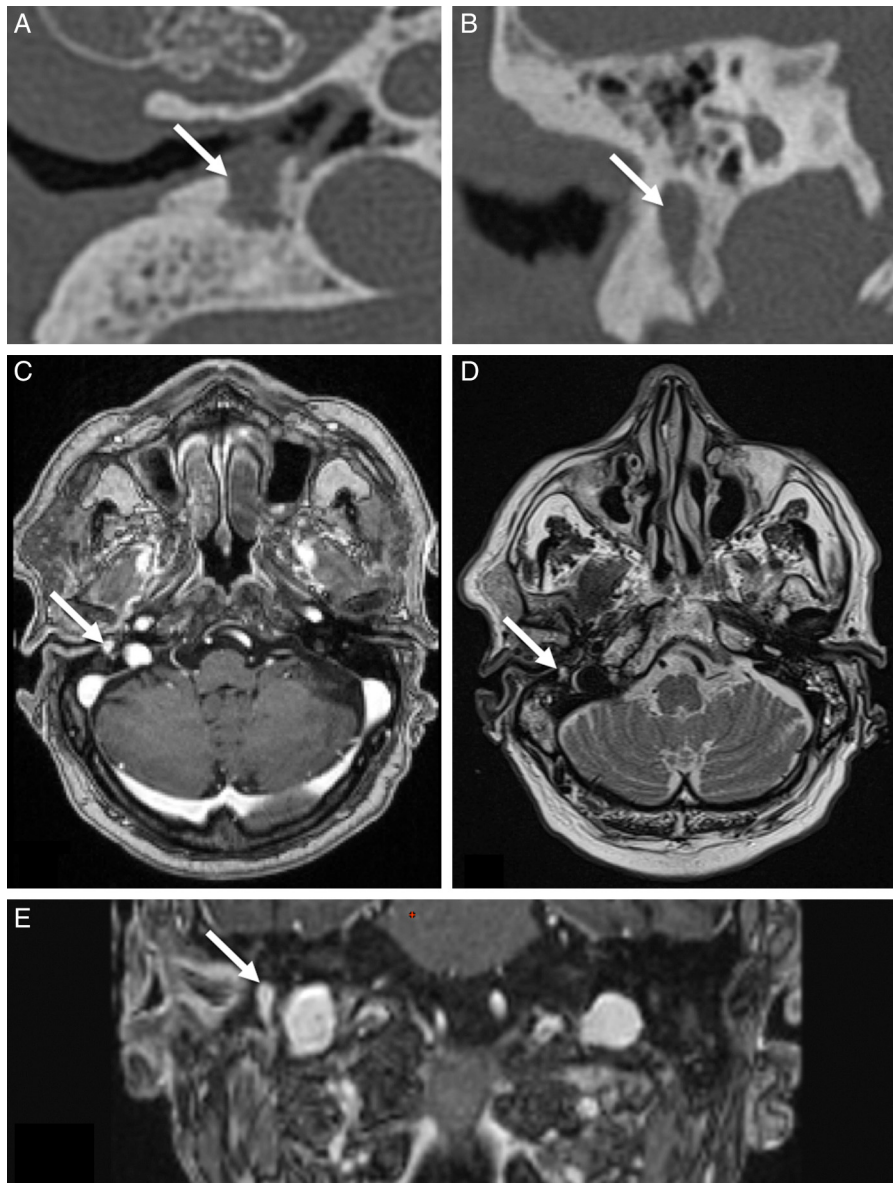


Figure 1 Radiological examination of chorda tympani schwannoma with associated MOE. (A) Axial CT scan demonstrating well-defined soft tissue lesion. (B) Reconstructed coronal CT image demonstrating above soft tissue lesion caused an osteolytic erosion of the mastoid along the vertical segment of the facial nerve. (C) T1 with gadolinium MRI image in axial projection: the chorda tympani tumor exhibits a homogenous hyper-enhancement. (D) The MRI axial T2-weighted image in axial projection shows the hyperintense schwannoma. (E) T1 with gadolinium MRI image in coronal projection: the chorda tympani tumor exhibits a homogenous hyper-enhancement. MOE, malignant otitis externa; CT, computed tomography; MRI, magnetic resonance imaging.

no complaint of taste disturbance. Pure tone audiogram showed a right mixed hearing loss with air bone gap at 15 dB and symmetric bone curve by presbycusis. Laboratory signs of inflammation or infection were absent (no elevation of blood cell count, C-reactive protein [CRP], or erythrocyte sedimentation rate). Diabetes was considered to be well controlled (HbA1c = 5.6%). Cultures of otorrhea were positive for *Pseudomonas aeruginosa*. *P. aeruginosa* was sensitive to ciprofloxacin and ceftazidime, and these systemic antibiotics were prescribed. Computed tomography (CT) and magnetic resonance imaging (MRI) of the temporal bone were performed. CT showed partial opacification of the right mastoid air cells and middle ear cavity, and thickening of the

right tympanic membrane and skin of the right EAC. CT also revealed an osteolytic lesion of the mastoid along the vertical segment of the facial nerve, involving the floor of EAC, with bone destruction, decreased bone density, and the lake of continuity and wormy appearance of the cortical bone (Fig. 1). On MRI, multiple soft tissue signals were observed in the middle ear and mastoid region, displaying equal T1 and long T2 signals, with gadolinium contrast enhancement. MRI revealed EAC inflammation and infiltration of retrocondylar fat. Although, a soft tissue lesion of 6 mm equal T1 and long T2 signals with a homogenous hyper-enhancement after intravenous contrast injection, involved the floor of EAC, and caused an osteolytic erosion of the mastoid along the

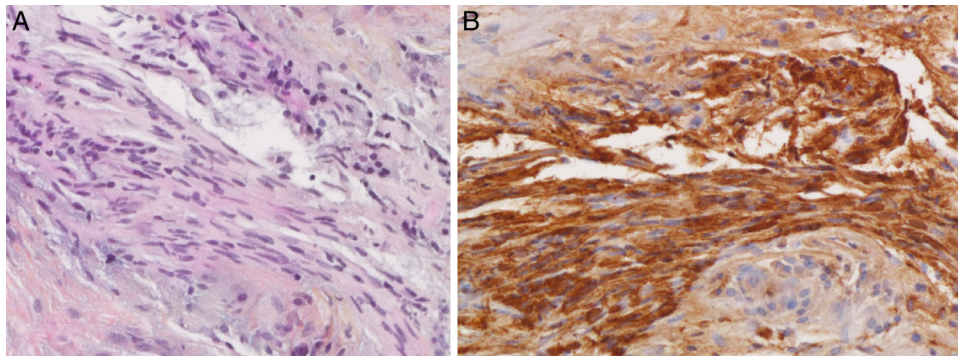


Figure 2 Histological examination of chorda tympani schwannoma with inflammatory tissue by associated MOE (200×). (A) Histological examination shows typical elongated spindle cells that tend to form palisades on hematoxylin–eosin safran (HES) coloration. (B) Spindle cells are diffusely and strongly positive for S100 protein. MOE, malignant otitis externa.

vertical segment of the facial nerve (Fig. 1). Under general anesthesia, with facial nerve neuromonitoring, the mass was accessed by the transmastoid approach to exclude a malignant tumor. A malignant tumor was first suspected, and the surgery aim was diagnostic before the therapeutic decision. Only a biopsy was performed, and the nerve was preserved during surgery. The biopsy revealed a tumor arising from the Schwann's cells (Fig. 2). Histological examination revealed a lesion composed of spindle cells with wavy appearing nuclei. The nuclei were arranged in a palisading fashion. Mitotic activity was not present. Moreover, in this particular case, inflammatory cells were associated. Spindle cells were diffusely and strongly positive for S100 protein. The postoperative period was uneventful, with well-preserved facial nerve function and no taste disturbance. Systemic antibiotics (ciprofloxacin and ceftazidime) were prescribed during six weeks for malignant external otitis, and periodic follow-ups were recommended for chorda tympani schwannoma. No attempt was made to resect the represented chorda tympani tumor because the patient was symptom-free. Follow-up at six months showed the patient in good health, without recurrent disease. Pure tone audiogram showed a stable bilateral sensorineural hearing loss.

Discussion

This report presents an additional case of chorda tympani schwannoma. To the best of the authors' knowledge, this is the first case in literature with incidental radiological finding of asymptomatic chorda tympani schwannoma.

This is a very rare benign tumor for all authors, and Huoh and Cheung in 2010 reported only seven other cases in the English literature.¹ However, a new review of the literature showed that 14 cases of chorda tympani schwannoma have been published in the English literature.^{1–9} Table 1 reports these cases, as well as this report's new case of chorda tympani schwannoma. Of the 15 patients, predominance among women was noted; six patients were males (40%) and nine were females (60%), a sex ratio of 0.6. The mean age at diagnosis was 38.5 years (range: 12–89 years). The tumor was located on the right side in nine cases (60%), the left side in four cases (27%), and this information was not reported in two cases (13%). Most of the cases were isolated chorda tympani schwannomas (87%), with only two cases reporting

multiple schwannomas (13%): one patient with neurofibromatosis Type 1 reported by Nager in 1969,² and one patient with neurofibromatosis Type 2 reported by Huoh and Cheung in 2010.¹ Presenting symptoms at diagnosis were conductive or mixed hearing loss (60%), tinnitus (27%), earache (20%), vertigo (13%), facial palsy (13%), and fullness (7%). In one case, vertigo may have been unrelated and suggested benign paroxysmal vertigo.⁸ In another case, right facial weakness was present early in childhood, possibly from birth trauma.⁸ In the present case, MOE may have caused right earache and mixed hearing loss. In all cases except the present study, otoscopic examination found a retrotympanic mass or a mass in the EAC. From the evolution of medical imaging techniques, all cases presented a soft tissue lesion along the chorda tympani. Preoperative diagnoses included cholesteatoma,^{5,8,9} glomus,^{2,9} rhabdomyosarcoma,² facial nerve schwannoma,^{1,4,9} and malignant tumor in the present case. Diagnosis is usually made by biopsy and treatment is surgical, with preservation of facial and auditory function. Two patients did not have surgical resection (13%): one patient with neurofibromatosis,¹ and one post-mortem case.³ Of the 12 patients operated on, postoperative clinical evaluation reported two cases of facial palsy (17%), one case of mixed hearing loss (8%), and one case of temporary taste disturbance (8%). The number of previous chorda tympani schwannoma cited by authors was wrong in all articles when these data were present. Review of the literature showed that 14 cases of chorda tympani schwannoma had been published in the English literature before the present case.

Taste disturbance was not documented in any previous case, which is in accordance with this patient. The slow growing nature of the neuroma is likely to allow compensatory mechanisms to occur without the patient experiencing dysgeusia.⁸ Moreover, resection of the chorda tympani often causes no subjective change in overall taste sensation. The nerve is often sacrificed in middle-ear surgery; one study noted a 31% incidence of permanent taste alteration in cases of complete nerve resection.¹⁰

To the best of the authors' knowledge, this is the first case in literature with incidental radiological finding of asymptomatic chorda tympani schwannoma. In this case, MOE may have caused right earache and mixed hearing loss. The schwannoma might be asymptomatic because the

Table 1 Literature review of patients with chorda tympani schwannoma.

Authors	Age/sex	Side	Clinical presentation	Otoscopic examination	Imaging examination	Postoperative clinical evaluation	Previous cases described
Undabetia et al. ⁹	45/F	Right	Mixed HL, vertigo	Retrotympanic mass in the posterior quadrant	Mass in the tympanic cavity	FP HBII, mixed HL	NR
Huoh and Cheung ¹	24/F	Right	HL, tinnitus, FP	Retrotympanic mass	Chorda tympani tumor	No surgery	7
Hopkins et al. ⁸	53/M	Right	Vertigo, mixed HL	Retrotympanic mass in the posterosuperior quadrant	Mass in the tympanic cavity, extending into the attic	Temporary taste disturbance	5
Biggs and Fagan ⁷	26/F	Right	Life-long ear disease	Mass retrotympanic	Tumors in the hypotympanum	Normal	4
Magliulo et al. ²	58/F	Left	Conductive HL, tinnitus	Mass in the EAC	Lesion in the EAC extending into the lower tympanic cavity, with osteolytic erosion along the vertical segment of the facial nerve	Normal, no recurrence (two-year postop)	5
Chai et al. ⁶	60/F	Left	Conductive HL	Mass retrotympanic	Lesion medial to the malleus, extending into the attic	Normal	5
Browning et al. ⁵	51/F	Right	HL, earache	Mass in the posterosuperior EAC and retrotympanic in the posterosuperior quadrant	Normal	Normal	5
Saleh et al. ²	62/F	Left	Tinnitus	Mass in the posterosuperior EAC	NR	Normal, no recurrence (seven-year postop)	NR
Lopes Filho et al. ⁴	25/M	Right	Fullness, earache	Tumor in the posterior EAC	Normal	Normal	2
Sanna et al. ²	14/F	Right	Progressive FP	NR	Normal	FP HBII (two-year postop)	NR
Wiet et al. ²	12/M	Left	Conductive HL	Mass in the posteroinferior EAC	Mass in the EAC with erosive changes of the posterior wall	Normal	NR
Babin et al. ³	18/M	NR	Asymptomatic	NR	NR	No surgery; post-mortem study	NR
Pou and Chambers ²	18/F	Right	Conductive HL, tinnitus	Mass in the EAC	Normal	Normal, no recurrence (six-month postop)	0
Nager ²	22/M	NR	NR	NR	NR	NR	NR

M, male; F, female; NR, not reported; HL, hearing loss; FP, facial palsy; EAC, external auditory canal; HB, House-Brackmann grade; postop, postoperative.

lesion was small. Otoloscopic examination showed clinical presentation of MOE and lesion was not apparent. All of the previous cases showed a mass in the EAC or behind an intact tympanic membrane. Thus, this case is the first case in literature of asymptomatic chorda tympani schwannoma with no tumorous lesion at otoscopic examination. Babin described one post mortem study of asymptomatic chorda tympani, but otoscopic and imaging examination was not reported.³ Schwannomas are easily diagnosed by imaging, which, generally speaking, is very good at delineating the extension of the lesion and orienting the surgical procedures. However, in this study, the lesion measured 6 mm and MRI analysis was more difficult for the small lesion.

In 1981, Babin described three neuromas occurring in the presence of chronic inflammatory middle ear disease.³ Histologically all three resembled traumatic (reparative) neuromas. The authors suggested that occasionally, long-term exposure of the facial nerve to chronic inflammation results in proliferation of neurofibrils, leading to neuroma formation. The present case occurred in the presence of chronic inflammatory external ear disease with a six-month history of otitis externa.

MOE, also known as necrotizing otitis externa, corresponds to osteomyelitis of the skull base, typically due to *P. aeruginosa*, initially arising in the EAC. The presence of systemic predisposing factors (diabetes), otoscopic signs, and especially resistance to topical treatment should raise the suspicion of MOE. An early clinical diagnosis confirmed by imaging and microbiology allows initiation of appropriate antibiotic therapy, which very likely will limit the extent of necrosis and the development of central nervous system complications. The clinical presentation as well as the particular diagnostic and therapeutic problem encountered. No consensus diagnostic flow diagram has been published in the literature, which frequently results in delayed diagnosis and inappropriate primary care management. In the present case, biopsy of an atypical tumorous lesion was rapidly performed because diagnosis is frequently difficult

and malignant tumor must be excluded, leading to the diagnosis of this novel case of chorda tympani schwannoma.

Conclusion

An osteolytic lesion along the chorda tympani must evoke a schwannoma. Although rare, this diagnosis should be considered in the same manner as a malignant tumor.

Conflicts of interest

The authors declare no conflicts of interest.

References

1. Huoh KC, Cheung SW. Chorda tympani neuroma. *Otol Neurotol*. 2010;31:1172–3.
2. Magliulo G, D'Amico R, Varacalli S, Ciniglio-Appiani G. Chorda tympani neuroma: diagnosis and management. *Am J Otolaryngol*. 2000;21:65–8.
3. Babin RW, Fratkin J, Harker LA. Traumatic neuromas of the facial nerve. *Arch Otolaryngol*. 1981;107:55–8.
4. Lopes Filho O, Bussoloti Filho I, Betti ET, Burlamachi JC, Eckley CA. Neuroma of the chorda tympani nerve. *Ear Nose Throat J*. 1993;72:730–2.
5. Browning ST, Phillipps JJ, Williams N. Schwannoma of the chorda tympani nerve. *J Laryngol Otol*. 2000;114:81–2.
6. Chai F, Vanopulos K, McManus T. Chorda tympani schwannoma. *Aust N Z J Surg*. 2000;70:827–8.
7. Biggs ND, Fagan PA. Schwannoma of the chorda tympani. *J Laryngol Otol*. 2001;115:50–2.
8. Hopkins C, Chau H, McGilligan JA. Chorda tympani neuroma masquerading as cholesteatoma. *J Laryngol Otol*. 2003;117:987–8.
9. Undabeitia JI, Undabeitia J, Padilla L, Municio A. Chorda tympani neuroma. *Acta Otorrinolaringol Esp*. 2014;65:263–5.
10. Yeo SB, Loy AH. Chorda tympani trauma – how much does it affect taste? *Singapore Med J*. 1997;38:329–31.