




Available online at  
 ScienceDirect  
[www.sciencedirect.com](http://www.sciencedirect.com)

Elsevier Masson France  
 EM|consulte  
[www.em-consulte.com](http://www.em-consulte.com)

  
Orthopaedics  
& Traumatology  
Surgery & Research

ORIGINAL ARTICLE

# Knee MR-arthrography in assessment of meniscal and chondral lesions

L. Mathieu<sup>a,\*</sup>, A. Bouchard<sup>a</sup>, J.-P. Marchaland<sup>a</sup>, J. Potet<sup>b</sup>,  
B. Fraboulet<sup>b</sup>, M. Danguy-des-Deserts<sup>b</sup>, G. Versier<sup>a</sup>

<sup>a</sup> Orthopaedics and Traumatology Department, Bégin Military Academic Hospital, 69, avenue de Paris, 94160 Saint-Mandé, France

<sup>b</sup> Radiology Department, Bégin Military Academic Hospital, 69, avenue de Paris, 94160 Saint-Mandé, France

Accepted: 9 September 2008

## KEYWORDS

MR-arthrography;  
Knee;  
Meniscus;  
Cartilage;  
Arthroscopy

## Summary

**Introduction.** – No study, so far in France, has investigated the diagnosis value of knee MR-arthrography since the recent approval of intra-articular gadolinium use, by this country's healthcare authorities. This study objective is to verify the MR-arthrography superiority on conventional knee MRI, in meniscus and cartilage knee lesions diagnosing accuracy both in regard to sensitivity and specificity.

**Hypothesis.** – MR-arthrography, represents in some pathologic situations, a more accurate source of information than conventional MRI.

**Materials and methods.** – Over a 27 months period, 25 patients, scheduled to undergo a knee arthroscopy volunteered, after having been fully informed of the possible interest and risk of the MR-arthrography examination, to participate in this study. Twenty-one of them were finally included since in four cases the surgical indication was not confirmed. The group consisted of 15 males and six females with an average age of 35.7 years. All of them consecutively underwent conventional MRI, MR-arthrography finally followed by arthroscopy. The MRI and MR-arthrograms results were compared to the arthroscopy findings using the nonparametric Kappa test.

**Results.** – To diagnose meniscal tears, statistical agreement measure for MRI with arthroscopy was good ( $K=0.69$ ) but not as good as the MR-arthrography/arthroscopy agreement which, by itself was excellent ( $K=0.84$ ). As a diagnosis tool, the sensitivity and specificity of MR-arthrography (respectively 100 and 89.6%) were much higher than the corresponding values observed in conventional MRI (92.3 and 82.8%, respectively) which nonetheless remain satisfactory.

\* Corresponding author.

E-mail address: [laurent.tom2@yahoo.fr](mailto:laurent.tom2@yahoo.fr) (L. Mathieu).

The meniscal tears characterization seemed to be better interpreted using MR-arthrography. As far as the chondral lesions in this series, they were predominantly located on the patellar surface and in the medial femorotibial compartment. For diagnosing the latter, the MRI/arthroscopy agreement was good ( $K=0.70$ ) but not as good as the MR-arthrography/arthroscopy agreement ( $K=0.805$ ) which can be rated excellent. The detection sensitivity thus increased by 10% with gadolinium intra-articular injection. However, assessment accuracy of the lesions depth was mediocre, with frequent errors for the intermediary stages.

*Discussion.* — Intra-articular gadolinium injection improved MRI performances for numerous reasons: filling the joint, reinforcing the synovial fluid signal, and enhancing anatomic structures contrast on the T1-weighted sequences images. In this study, MR-arthrography appeared to be superior to conventional MRI in meniscal and cartilaginous lesions diagnosis, confirming the results previously obtained in other countries. In light of these results and other data from the literature, MR-arthrography can be indicated as an alternative to CT-arthrography in various clinical situations: detection of recurrent tears on operated menisci, search for cartilaginous lesions or foreign bodies in the joint space, and preoperative assessment before chondral repair procedures. However, conventional MRI remains the reference examination for studying cartilage, because the low resolution of MR-arthrography limits its performances in quantitative assessment of lesions depth.

Level of evidence: Level III. Non randomized comparative prospective study.

© 2008 Elsevier Masson SAS. All rights reserved.

## Introduction

The first English language studies on MRI with joint injection of gadolinium were published roughly 20 years ago [1,2]. They clearly proved that this examination is valuable in the diagnosis of shoulder and hip lesions as well as knee lesions. MR-arthrography seems to be more sensitive and more specific than conventional MRI in detecting meniscal and chondral lesions and is consequently widely used in North America.

In France, the development of MR-arthrography is recent because the approval to market for intra-articular injection of gadolinium was accorded quite recently, in 2002 [3]. To our knowledge, no French study has investigated MR-arthrography of the knee, although its value is recognized principally in the analysis of lesions involving post-operated menisci and as an alternative to CT-arthrography in the preoperative assessment of osteochondritis dissecans.

This article reports the results of a prospective study whose objective was to study the diagnostic performance of MR-arthrography of the knee in ordinary meniscal and cartilaginous lesions. The role this examination can play compared to other imaging techniques is discussed by comparing these results with those in the literature.

## Materials and methods

This open, nonrandomized, prospective study was conducted from January to July 2007, in patients programmed for arthroscopy of the knee. They had initially undergone a clinical exam and frontal and lateral loaded knee X-rays, which suggested meniscal, cartilaginous, and/or ligamentary pathology. As part of the preoperative workup, these patients were proposed a conventional MRI followed by an MR-arthrography with intra-articular injection of gadolinium. All patients underwent conventional MRI, fol-

lowed by MR-arthrography with intra-articular injection of gadolinium. All received truthful, clear, and appropriate information on the principles and risks of MR-arthrography. Twenty-five patients accepted to participate in the study; the others refused MR-arthrography because of its invasiveness.

The indications for surgery were based only on the MRI data, because the surgeons had no knowledge of the MR-arthrography results. Four patients were excluded from the study because arthroscopy was not done and was indispensable to the assessment of the imaging results. In three of these patients, surgery was not retained for the following reasons: normal MRI results, grade II medial meniscal lesions, and isolated patellar chondral disease. The fourth patient excluded presented stage IV medial femoral chondral disease requiring autologous osteochondral graft, but he preferred to postpone the surgery for several months.

Twenty-one patients (84%) were included in the study after a complete MRI, MR-arthrography, and arthroscopy sequence of the knee. There were 15 men and six women. The mean age was 35.7 years (range, 23–67 years).

## MRI and MR-arthrography

The images were acquired with a 1.5T system and a surface antenna. A conventional MRI was done first with frontal, sagittal, and axial views in proton density (PD) and FatSat imaging for fat suppression. A total of 20 ml of gadoteric acid (Artirem®, Laboratoire Guerbet) was injected at a concentration of 2.5 mmol/L using a lateral parapatellar approach, after rigorous asepsis and wide prepping of the lateral side of the knee. This was preceded by the injection of a few milliliters of iodated contrast to guide the position of the needle during scope maneuvers. Finally, the MR-arthrography was done with T1-weighted FatSat views in the three spatial planes.

**Table 1** Agreement with arthroscopy in diagnosing meniscal lesions.

	Meniscus lesions: MRI versus arthroscopy	Meniscus lesions: MR-arthrography versus arthroscopy
True positive results (a)	12	13
False positive results (b)	5	3
False negative results (c)	1	0
True negative results (d)	24	26
Total	42	42
	$K=0.69$ ( $p < 0.05$ )	$K=0.84$ ( $p < 0.05$ )

The images were interpreted by experienced senior radiologists who had no knowledge of the clinical context. The data were collected on a standardized form. The meniscal lesions were described using the Cruess and Stoller classification [4]: grade I for a punctiform or intrameniscal nodular hypersignal, grade II for an intrameniscal linear hypersignal, and grade III for a linear hypersignal extended to at least one of the two articular surfaces of the meniscus. The cartilaginous lesions were evaluated using an MRI classification that could be superimposed onto the arthroscopic classification by Béguin and Locker [5] used by the French Arthroscopic Society: stage I for an abnormal signal that respected the cartilaginous surface (chondromalacia), stage II for superficial ulcerations that did not exceed 50% of the cartilage's thickness, stage III for deep ulcerations greater than 50% of the cartilage's thickness, and stage IV for total destruction of the cartilage (subchondral bone revealed in arthroscopy). The location of the lesions within the six knee joint facets and the presence of foreign bodies was noted.

## Arthroscopy

The mean time between MR-arthrography and arthroscopy was 51 days (range, 15–178 days). With two exceptions, the arthroscopies were carried out at least one month after the MR-arthrography procedures. No secondary infectious complications were observed upon gadolinium injection into the joint. The surgeons performing the arthroscopy had no knowledge of the MR-arthrography results. Each arthroscopy began by systematic, standardized exploration of the knee's different compartments. The data were completed on the specific forms by the surgeons at the end of surgery. Meniscal tears were classed according to their location and shape, independently of whether they were traumatic or degenerative lesions. The degenerative meniscal lesions with no solution for continuity were not retained. The depth of the chondral lesions was evaluated using the Béguin and Locker classification [5] and their location was noted.

## Comparison and results

The MRI and MR-arthrography results were compared to the arthroscopy results. For the menisci, the true positive results were grade III hypersignals corresponding to a meniscal tear or meniscocapsular separation on arthroscopy. The true negatives were absence of hypersignal or grade I or II hypersignals, with no meniscal lesion on arthroscopy. The false positive and false negative results corresponded to disagreement between the imaging studies and arthroscopy.

For the chondral lesions, stage I arthroscopic findings (chondromalacia) were excluded from the statistical tests. Their MRI diagnosis remains random, because even the specific sequences of the cartilage could not detect a lesion that was only palpable.

Agreement between the imaging and arthroscopy results was determined by Cohen's nonparametric Kappa test [6], which can assess the difference between two techniques based on qualitative data. The degree of agreement was judged using the criteria proposed by Landis and Koch [7]: excellent (coefficient  $K=0.81-1.00$ ), good ( $K=0.61-0.80$ ), moderate ( $K=0.21-0.60$ ), poor ( $K=0-0.2$ ), and very poor ( $K < 0$ ). The calculation of the  $K$  coefficient included the  $p$ -value ( $\alpha$  risk = 5%). The diagnosis was then evaluated by calculating the sensitivity, specificity, the positive predictive value (PPV), the negative predictive value (NPV), and the reliability of MRI and MR-arthrography [8].

## Results

### Diagnosis of meniscal lesions

In the total group of menisci ( $n=2 \times 21$ ), 17 lesions were seen on MRI (0 grade I, 0 grade II, 17 grade III) and 21 on MR-arthrography (one grade I, four grade II, 16 grade III). However, arthroscopy only demonstrated 13 meniscal tears or meniscocapsular separations: 11 on the medial meniscus and two on the lateral meniscus.

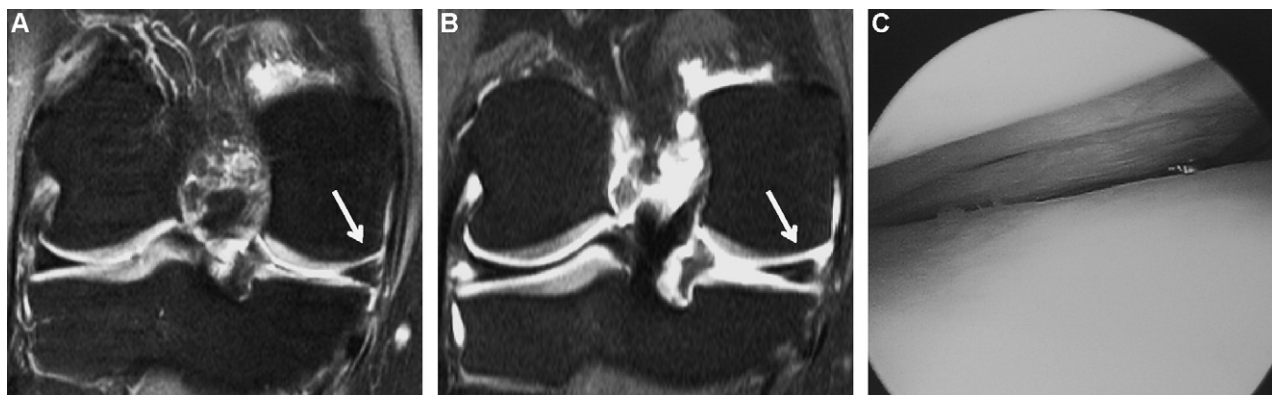
The comparison of the imaging and arthroscopic studies brought out five false positive and one false negative result on MRI versus three false positive and no false positive results on MR-arthrography (Table 1). The agreement of MRI with arthroscopy was good ( $K=0.69$ ), and the agreement of MR-arthrography with arthroscopy was excellent ( $K=0.84$ ). The sensitivity of MR-arthrography in the diagnosis of meniscal lesions reached 100% in this series, with an 81.2% PPV. Its performance was much better than MRI,

**Table 2** Diagnostic performance for meniscal lesions.

	MRI: meniscus	MR-arthrography: meniscus
Sensitivity (%)	92.3	100
Specificity (%)	82.8	89.6
PPV (%)	70.6	81.2
NPV (%)	96	100
Reliability (%)	85.7	92.9

**Table 3** Comparative evaluation of the type of meniscal lesion: displaced bucket handle tear (DBHT), broken bucket handle tears (BHT), vertical meniscal tear (VMT), horizontal cleavage (HC), or complex lesion (Cpl).

Lesion	1	2	3	4	5	6	7	8	9	10	11	12	13
MRI	DBHT	DBHT	VMT	0	VMT	VMT	VMT	CH	ASR	HC	Cpl	0	VMT
MR-arthrography	DBHT	DBHT	BBHT	VMT	VMT	VMT	VMT	FV	Cpl	HC	Cpl	VMT	VMT
Arthroscopy	DBHT	DBHT	BBHT	VMT	Cpl	VMT	HC	Cpl	Cpl	HC	Cpl	VMT	VMT



**Figure 1** Recurrent medial meniscus lesion after meniscectomy. A. Frontal MRI PD FAT SAT view. B. Frontal MR-arthrographic view, T1-weighted FAT SAT. C. Arthroscopy.

which presented satisfactory sensitivity (92.3%) and specificity (82.8%) nonetheless (Table 2).

Of the 13 lesions observed in arthroscopy, there were four vertical meniscal tears, two horizontal splits (one of which was associated with a meniscal cyst), three ruptured bucket handle tears, and four complex degenerative lesions. Table 3 presents the comparison of the lesion types. The MRI data agreed with the arthroscopic data in 46% of the cases (6/13) and with the MR-arthrography data in 77% of the cases (10/13).

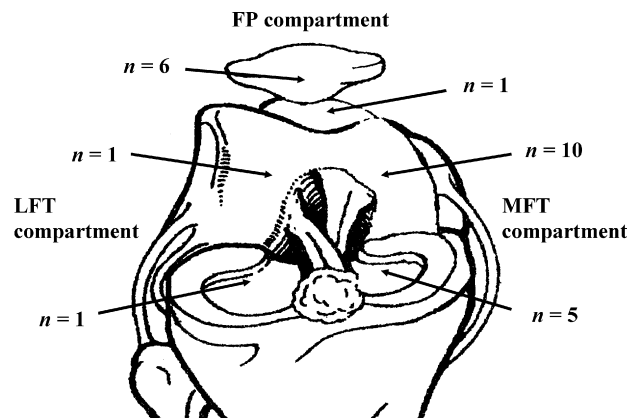
Three patients presented a recurring meniscal lesion long after a medial meniscectomy (Fig. 1). These included three vertical tears, which were all demonstrated on the MR-arthrography. However, one of the lesions had not been identified on MRI, which showed an amputated meniscus with no new distinguishable tear.

**Diagnosis of chondral lesions**

Of all of the medial femorotibial, lateral femorotibial, and femoropatellar compartments, (6 × 21 joint surfaces), 15 chondral lesions were seen on MRI (one stage I, ten stage II, two stage III, two stage IV lesions) and 16 on MR-arthrography (0 stage I, ten stage II, four stage III, two stage IV lesions). Arthroscopy demonstrated 24 chondral lesions: four stage I, 12 stage II, six stage III, two stage IV. Fig. 2 illustrates the distribution of the lesions in terms of the different knee joint surfaces. The most frequent locations were the patellar facets and the medial femorotibial compartment. The lateral femorotibial compartment was the seat of only one case of stage I chondropathy.

The arthroscopic classification of the chondral lesions was compared to the MRI and MR-arthrography classifications (Tables 4 and 5). The stage I arthroscopic lesions

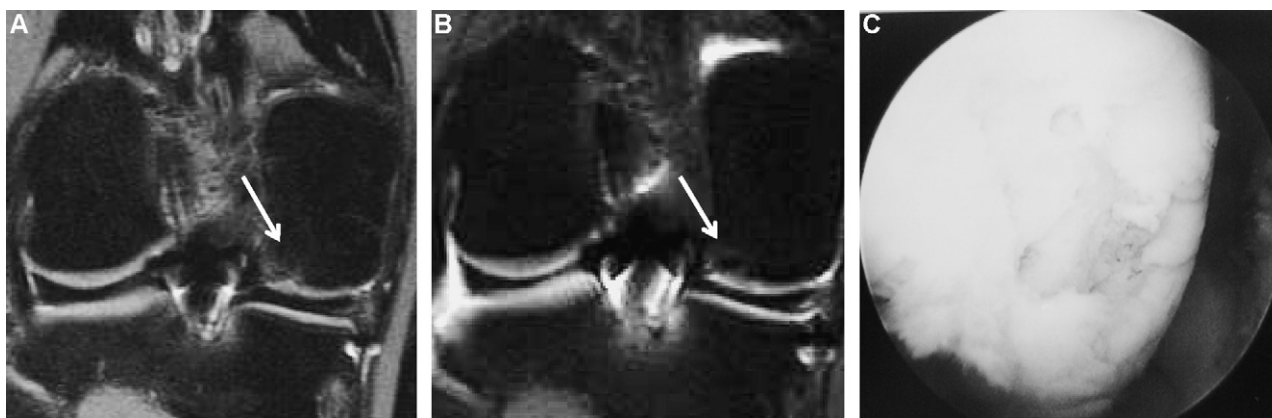
had not been diagnosed with conventional MRI or MR-arthrography. The two stage IV lesions were detected and evaluated with both techniques (Fig. 3). For the stage II and III lesions, evaluation errors were frequent. However,



**Figure 2** Topographic distribution of the 24 chondral lesions.

**Table 4** Classification of chondral lesions, MRI versus arthroscopy.

MRI stages	Arthroscopy stages			
	I	II	III	IV
0	3	2	4	0
I	1	0	0	0
II	0	10	0	0
III	0	0	2	0
IV	0	0	0	2
Total	4	12	6	2



**Figure 3** Stage IV chondral disease of the medial femoral condyle. A. Frontal MRI, DP FAT SAT view. B. Frontal view in T1-weighted FAT SAT MR-arthrography. C. Arthroscopy.

**Table 5** Classification of chondral lesions, MR-arthrography versus arthroscopy.

MR-arthrography stages	Arthroscopy stages			
	I	II	III	IV
0	4	2	2	0
I	0	0	0	0
II	0	10	0	0
III	0	0	4	0
IV	0	0	0	2
Total	4	12	6	2

MR-arthrography seemed superior to MRI in the diagnosis of stage III lesions.

Tables 6 and 7 present the statistical results obtained for the diagnosis of all 126 joint surfaces. By excluding the four stage I lesions found only during arthroscopy, the number of joint surfaces retained for the statistical analysis was 122. Agreement with arthroscopy was good for MRI ( $K=0.70$ ) and nearly excellent for MR-arthrography, with a coefficient  $K$  between 0.80 and 0.81. Sensitivity for detection of chondral lesions increased by 10% after intra-articular injection of gadolinium. However, specificity and reliability changed little.

## Discussion

MR-arthrography with intra-articular diluted gadolinium injection is called direct MR-arthrography. It improves visu-

**Table 7** Diagnostic performance for chondral lesions.

	MRI: chondral lesions	MR-arthrography: chondral lesions
Sensitivity (%)	65	75
Specificity (%)	98	99
PPV (%)	86.7	93.7
NPV (%)	93.5	95.3
Reliability (%)	92.6	95.1

alization of the joint surfaces by three combined effects: the joint is filled, the synovial fluid is increased, and T1-weighted anatomic sequences are used [3]. However, it exposes the patient to a risk of infectious complications, transient pain, or allergic reactions [9]. The alternative is indirect MR-arthrography with intravenous injection of gadolinium. It is noninvasive but does not have the advantage of filling the joint, and certain diagnostic signs lose their value [3].

## Methodology

Assessment of the performance of direct knee MR-arthrography for the diagnosis of meniscal and chondral lesions is founded on comparing imaging results with arthroscopy, which is currently considered the gold standard of lesion diagnosis. Based on the English language prospective studies, the present study's main limit is the small number of cases investigated. This is explained for the most

**Table 6** Agreement with arthroscopy for the diagnosis of chondral lesions (stage I arthroscopic results excluded).

	Chondral lesions: MRI versus arthroscopy	Chondral lesions: MR-arthrography versus arthroscopy
True positive results (a)	13	15
False positive results (b)	2	1
False negative results (c)	7	5
True negative results (d)	100	101
Total	122	122
	$K=0.70$ ( $p < 0.05$ )	$K=0.805$ ( $p < 0.05$ )

part by patients' reluctance to accept an invasive procedure for purely scientific purposes.

In addition, the method used to analyze the MRI and MR-arthrography images could be criticized in that the images were not interpreted by a single radiologist. However, all those reading the images were experienced radiologists, particularly well versed in the practice of MRI applied to the knee in sports pathology.

## Menisci

These results show that MR-arthrography performs better than MRI in the diagnosis of meniscal lesions, with higher sensitivity and specificity, but it also shows better performance in specifying the type of lesion. The MRI performance is also comparable to the data in the literature: these studies have found MRI's sensitivity to vary from 87 to 97%, its specificity from 89 to 98%, and its reliability from 88 to 95% [4,10]. The number of patients included in this series is relatively low, but the Kappa coefficients obtained were also significant and demonstrate the reproducibility of the measures taken. The agreement of MRI with arthroscopy is lower ( $K=0.69$ ) than the agreement of MR-arthrography with arthroscopy ( $K=0.84$ ), because of a higher rate of false positive results. The two additional MRI false positive results correspond to grade I or II hypersignals with MR-arthrography. This difference in interpretation is related to the better visualization of the joint surfaces of the menisci after injections of gadolinium, which lowers the number of grade III diagnoses. Other false positives are probably caused by meniscal lesion scarring, given the mean 51 days between imaging and arthroscopy. Doing the arthroscopy immediately after the MR-arthrography would have been more reliable.

Even though MR-arthrography provides better performance, the reliability of MRI nevertheless remains perfectly satisfactory for the evaluation of first-line meniscal lesions; the prescription of an invasive examination in this indication seems excessive.

Recurrent meniscal lesions seemed to be detected better with MR-arthrography, but the number of cases in this series is too low to draw conclusions. MRI is often faulted because the usual diagnostic criteria are difficult to apply to operated menisci. Several clinical studies have demonstrated the value of MR-arthrography in diagnosing repeated meniscal lesions, with reliability 10–20% higher than with conventional MRI [11,12]. After meniscectomy, a grade I or II intrameniscal hypersignal can extend to a joint surface, simulating a grade III lesion. The diagnostic strategy depends on the quantity of meniscus that has been resected (Fig. 4). When the resection is less than 25% of the meniscus surface, MRI's reliability for repeated lesions is comparable to what is obtained with MR-arthrography: approximately 90% [12,13]. When the meniscectomy exceeds 25%, Applegate et al. [12] have shown that MR-arthrography is clearly superior to MRI, with 89 and 63% reliability, respectively. Magee et al. [14] obtained similar results with 52% sensitivity for MRI and 100% for MR-arthrography. A similar problem arises after meniscal separation, because the existence of a zone with a hyperintense signal reaching the surface may correspond to a tear or to granulated

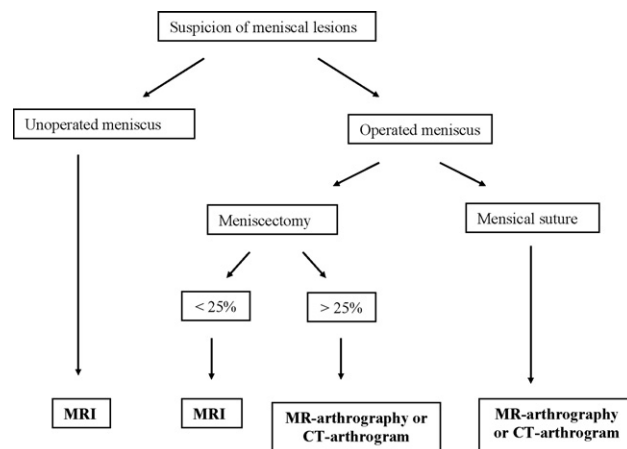


Figure 4 Diagnostic strategy for meniscal lesions.

scar tissue [3,9,15]. The English language studies therefore recommend MR-arthrography to assess meniscal repairs [12,14,16].

All in all, MR-arthrography is advantageous in the diagnosis of repeated meniscal lesions after surgery. In France, however, CT-arthrography is preferentially used in this indication. Various studies have proven its value in detecting recurring lesions after partial extended meniscectomy [17,18] and to follow up meniscus scarring [19,20]. In their review of the literature, Toms et al. [15] emphasized that CT-arthrography and MR-arthrography are comparable in terms of efficacy. CT-arthrography has the advantage of being rapid and displaying fewer artifacts, and MR-arthrography provides an analysis of the extra-articular soft tissues and bone [15].

## Cartilage

The performance of MRI in diagnosing cartilaginous lesions varies in the literature reports. Most studies that have used patellar cartilage as a model obtained highly variable results, with sensitivity ranging from 25 to 87%, specificity from 50 to 100%, and reliability from 49 to 83% [21–24]. The diagnostic performance obtained with MRI in this series is therefore within the mean found in the literature. Our results confirm MR-arthrography is superior to conventional MRI in diagnosing chondral lesions, which has already been shown by several comparative studies [21,25–27]. Even though the agreement with arthroscopy is good in both cases, the agreement of MR-arthrography is much closer to excellence ( $K=0.805$ ) than is MRI ( $K=0.70$ ). Intra-articular injection of gadolinium provides a notable gain in terms of sensitivity (75% versus 65%), but the already excellent specificity of MRI remains nearly unchanged (99% versus 98%).

However, the evaluation of the depth of cartilaginous lesions was more difficult. Stage I lesions are often poorly assessed by MRI as well as MR-arthrography because the joint surface shows no irregularity. According to Kramer et al. [21], the detection of these lesions could be facilitated by late image acquisition, during the phase when the gadolinium impregnates the cartilage. Stage II lesions are theoretically more easily visualized by MR-arthrography

because the contrast product emphasizes the superficial erosions [22,25,28]. However, we obtained similar results in MRI and MR-arthrography, with three false negative results that were not corrected by intra-articular injection of gadolinium. For stage III and IV lesions, the reliability of MRI is comparable to that of MR-arthrography according to Giovagnoni et al. [22], Engel [25], and Masciocchi et al. [28]. We observed identical results for stage IV lesions, but MR-arthrography appeared better for diagnosing stage III lesions.

All in all, MR-arthrography can be valuable in diagnosing cartilaginous lesions involving knee pain with conventional MRI or for a preoperative workup before chondral repair [21] since it also analyzes the subchondral bone and the soft tissues. However, the present study shows that MR-arthrography does not provide a fine analysis of cartilage and it is not appropriate for evaluating the depth of chondral lesions, given that its resolution is too low and unequal in the three spatial planes [29]. CT-arthrography therefore remains the reference examination for studying cartilage [29], since it provides the best performance in terms of diagnosis and evaluation of lesion depth [30].

## Conclusion

This prospective study confirms that MR-arthrography performs better than conventional MRI in diagnosing and classifying meniscal and chondral lesions of the knee. Its indications should be limited to situations in which MRI could produce erroneous results because it is an invasive and time-consuming procedure. It is valuable as an alternative to CT-arthrography in detection of recurrent or operated menisci, the search for intra-articular cartilaginous lesions or foreign bodies, and preoperative evaluation before chondral repair. However, CT-arthrography is the reference examination for studying cartilage, because the low resolution of MR-arthrography limits its performance in assessing lesion depth.

## References

- [1] Hajek PC, Baker LL, Sartoris DJ, Neumann CH, Resnick D. MR arthrography: anatomic-pathologic investigation. *Radiology* 1987;163:141–7.
- [2] Hajek PC, Sartoris DJ, Neumann CH, Resnick D. Potential contrast agents for MR arthrography: in vitro evaluation and practical observations. *Am J Roentgenol* 1987;149:97–104.
- [3] Blum A, Loeuille D, Lochum S, Kohlmann R, Grignon B, Coudane H, L'arthro-IRM. principes et applications. *J Radiol* 2003;84:639–57.
- [4] Crues 3rd JV, Mink J, Levy TL, Lotysch M, Stoller DW. Meniscal tears of the knee: accuracy of MR imaging. *Radiology* 1987;164:445–8.
- [5] Béguin J, Locker B. The SFA system for assessing articular cartilage lesions at arthroscopy of the knee. *Arthroscopy* 1994;10:69–77.
- [6] Cohen J. A coefficient of agreement for nominal scales. *Educ Psychol Meas* 1960;20:27–46.
- [7] Landis JR, Koch GG. The measurement of observer agreement for categorical data. *Biometrics* 1977;33:159–74.
- [8] Laplanche A, Com-Nougue C, Flamant R. Méthodes statistiques appliquées à la recherche clinique. Flammarion Médecine-Sciences éd, Paris 1987.
- [9] Chung CB, Isaza IL, Angulo M, Boucher R, Hughes T. MR arthrography of the knee: how, why, when. *Radiol Clin N Am* 2005;43:733–46.
- [10] McKenzie R, Palmer CR, Lomas DJ, Dixon AK. Magnetic resonance imaging of the knee: diagnostic performance statistics. *Clin Radiol* 1996;51:251–7.
- [11] Sciulli RL, Boutin RD, Brown RR, Nguyen KD, Muhle C, Lektrakul N, et al. Evaluation of the postoperative meniscus of the knee: a study comparing conventional arthrography, conventional MR imaging, MR arthrography with iodinated contrast material, and MR arthrography with Gadolinium-based contrast material. *Skeletal Radiol* 1999;28:508–14.
- [12] Appelgate GR, Flannigan BD, Tolin BS, Fox JM, Del Pizzo W. MR diagnostic of recurrent tears in the knee: value of intraarticular contrast material. *Am J Roentgenol* 1993;161:821–5.
- [13] White LM, Schweitzer ME, Weishaupt D, Kramer J, Davis A, Marks PH. Diagnostic of recurrent meniscal tears: prospective evaluation of conventional MR imaging, indirect MR arthrography, and direct MR arthrography. *Radiology* 2002;222:421–9.
- [14] Magee T, Shapiro M, Rodriguez J, Williams D. MR arthrography of postoperative knee: for which patients is it useful? *Radiology* 2003;229:159–63.
- [15] Toms AP, White LM, Marshall TJ, Donell ST. Imaging the postoperative meniscus. *Eur J Radiol* 2005;54:189–98.
- [16] Totty WG, Matava MJ. Imaging of the postoperative meniscus. *Magn Reson Imaging Clin North Am* 2000;8:271–83.
- [17] Muschler C, Vande Berg BC, Lecouvet FE, Poilvache P, Dubuc JE, Maldague B, et al. Postoperative meniscus: assessment at dual-detector row spiral CT arthrography of the knee. *Radiology* 2003;228:635–41.
- [18] Vande Berg BC, Lecouvet FE, Poilvache P, Maldague B, Malghem J. Spiral CT arthrography of the postoperative knee. *Semin Musculoskelet Radiol* 2002;6:47–55.
- [19] Lippert MJ, Paar O, Rupp N. Results of meniscus sutures in the framework of reconstruction in combined injuries of the knee joint: clinical aspects, arthrosonography, arthrography and computerized tomography. *Chirurgie* 1990;61:803–7.
- [20] Beaufile P, Cassard X, Charrois O, Ait Si Selmi T, Billot N, Hulet C, et al. Réparation méniscale. Symposium. *Rev Chir Orthop* 2004; 90:3S49-3S75.
- [21] Kramer J, Recht MP, Imhof H, Stiglbauer R, Engel A. Postcontrast. MR arthrography in assessment of cartilage lesions. *J Comput Assist Tomogr* 1994;18:218–24.
- [22] Giovagnoni A, Valeri G, Ercolani P, Paci E, Carloni S, Soccetti A. Magnetic resonance arthrography in chondral knee conditions. *Radiol Med* 1995;90:219–25.
- [23] Handelberg F, Shahabpour M, Casteleyn PP. Chondral lesions of the patella evaluated with computed tomography, magnetic resonance imaging and arthroscopy. *Arthroscopy* 1990;6:26–9.
- [24] McCauley TR, Kier R, Lynch KJ, Joki P. Chondromalacia patellae: diagnosis with MR imaging. *AJR* 1992;158:101–5.
- [25] Engel A. Magnetic resonance knee arthrography: enhanced contrast by Gadolinium complex in the rabbit and in humans. *Acta Orthop Scand* 1990;240:1–57.
- [26] Gagliardi JA, Chung EM, Chandnani VP, Kesling KL, Christensen KP, Null RN, et al. Detection and staging of chondromalacia patellae: relative efficacies of conventional MR imaging, MR arthrography, and CT arthrography. *Am J Roentgenol* 1994;163:629–36.
- [27] Palmer WE. MR arthrography: is it worthwhile? *Top Magn Reson Imaging* 1996;8:24–43.

- [28] Masciocchi C, Barile A, Lelli S, Calvisi V. Magnetic resonance imaging (MRI) and arthro-MRI in the evaluation of the chondral pathology of the knee joint. *Radiol Med* 2004;108:149–58.
- [29] Loredi R, Sanders TG. Imaging of osteochondral injuries. *Clin Sports Med* 2001;20:249–78.
- [30] Vande Berg BC, Lecouvet FE, Maldague B, Malghem J. MR appearance of cartilage defects of the knee: preliminary results of a spiral CT arthrography-guided analysis. *Eur Radiol* 2004;14:208–14.