

Neurological Phenotype in Waardenburg Syndrome Type 4 Correlates with Novel *SOX10* Truncating Mutations and Expression in Developing Brain

Renaud L. Touraine,^{1,*} Tania Attié-Bitach,^{1,*} Eric Manceau,² Eckhard Korsch,³ Pierre Sarda,⁵ Véronique Pingault,⁶ Féréchté Encha-Razavi,¹ Anna Pelet,¹ Joelle Augé,¹ Annie Nivelon-Chevallier,² Alexander Mathias Holschneider,³ Marc Munnes,⁴ Walter Doerfler,⁴ Michel Goossens,⁵ Arnold Munnich,¹ Michel Vekemans,¹ and Stanislas Lyonnet¹

¹Département de Génétique et Unité de Recherches sur les Handicaps Génétiques de l'Enfant, Hôpital Necker-Enfants Malades, Paris;

²Centre de Génétique, Hôpital d'Enfants, Dijon, France; ³Kinderkrankenhaus, Kliniken der Stadt Köln, and ⁴Institut für Genetik, Universität zu Köln, Cologne, Germany; ⁵Unité de Génétique Médicale et Foetopathologie, Hôpital Arnaud de Villeneuve, Montpellier, France; and

⁶Génétique Moléculaire et Physiopathologie, Hôpital Henri Mondor, Créteil, France

Waardenburg syndrome type 4 (WS4), also called Shah-Waardenburg syndrome, is a rare neurocristopathy that results from the absence of melanocytes and intrinsic ganglion cells of the terminal hindgut. WS4 is inherited as an autosomal recessive trait attributable to *EDN3* or *EDNRB* mutations. It is inherited as an autosomal dominant condition when *SOX10* mutations are involved. We report on three unrelated WS4 patients with growth retardation and an as-yet-unreported neurological phenotype with impairment of both the central and autonomous nervous systems and occasionally neonatal hypotonia and arthrogryposis. Each of the three patients was heterozygous for a *SOX10* truncating mutation (Y313X in two patients and S351X in one patient). The extended spectrum of the WS4 phenotype is relevant to the brain expression of *SOX10* during human embryonic and fetal development. Indeed, the expression of *SOX10* in human embryo was not restricted to neural-crest-derived cells but also involved fetal brain cells, most likely of glial origin. These data emphasize the important role of *SOX10* in early development of both neural-crest-derived tissues, namely melanocytes, autonomic and enteric nervous systems, and glial cells of the central nervous system.

Introduction

Waardenburg syndrome (WS [MIM 193500, MIM 193510, MIM 600193, and MIM 148820]) is a rare disorder (1/50,000 live births) characterized by sensorineural hearing loss and pigment anomalies. On the other hand, Hirschsprung disease (HSCR [MIM 142623]) is a common malformation (1/5,000 live births) defined by the absence of parasympathetic ganglion cells in the terminal hindgut. HSCR and WS are regarded as neurocristopathies, since both disorders result from an abnormal migration of neural-crest-derived cells. Interestingly, each of the three animal models of HSCR, namely the piebald lethal (*s^l*), lethal spotting (*ls*), and dominant megacolon (*Dom*) mutants, exhibit some

features reminiscent of WS, such as hypomelanotic spots. In humans, the WS-HSCR association (WS type 4 [WS4], also known as Shah-Waardenburg syndrome; MIM 277580) is a very rare and heterogeneous condition that follows either an autosomal recessive or an autosomal dominant pattern of inheritance (McKusick 1973; Branski et al. 1979; Omenn and McKusick 1979; Shah et al. 1981). Both the mouse mutants and the human WS4 phenotype have been ascribed to mutations of the endothelin-signaling pathway—namely, the endothelin B receptor, *EDNRB*, and the endothelin 3 gene, *EDN3* (Attié et al. 1995; Edery et al. 1996)—or of the *SOX10* gene, which encodes a transcription factor (Pingault et al. 1998). Hitherto, no additional features have been described among WS4 patients. Here, we report on three unrelated WS4 patients who presented with an as-yet-unreported progressive neurological involvement of both central and peripheral nervous systems. We show that the three patients carried a truncating *SOX10* mutation. Accordingly, analysis of data generated from in situ hybridization experiments indicated that *SOX10* is expressed early in the fetal brain, likely in glial cells. Thus, our study gives support to a possible neurological

Received June 22, 1999; accepted for publication February 16, 2000; electronically published April 4, 2000.

Address for correspondence and reprints: Stanislas Lyonnet, Département de Génétique et Unité de Recherches sur les Handicaps Génétiques de l'Enfant, INSERM U-393, Hôpital Necker-Enfants Malades, 75743 Paris. E-mail: lyonnet@necker.fr

* These two authors equally contributed to this work.

© 2000 by The American Society of Human Genetics. All rights reserved. 0002-9297/2000/6605-0004\$02.00

involvement in WS4 and to the role of SOX10 in development of both the central and the autonomous nervous systems.

Patients and Methods

Patients and Families

Histopathologic inclusion criteria for HSCR were ganglia that were absent, along with increased acetylcholinesterase histochemical staining in nerve fibers on suction biopsies of the rectal mucosa. For WS, we used the diagnostic criteria of Read and Newton (1997), and WS4 was diagnosed when at least one member of the proband's family had features of both HSCR and WS. Informed consent was obtained for all the patients in the study.

Among a total of 12 unrelated WS4 patients recruited by the Genetic Center, Necker Hospital, Paris, three presented with additional neurological symptoms. Each of them originated from white families living in Germany (family 1) and France (families 2 and 3). Their standard blood-lymphocyte karyotypes were within normal reference ranges.

Patient 1 had early delayed developmental milestones, nystagmus, myopia, reduced tear production, hypotonia, and growth deficiency (height, 104 cm; weight, 15.8 kg; and head circumference, 52 cm at age 12 years). In addition to extensive intestinal aganglionosis, deafness, iris heterochromia, and hypomelanotic skin patches consistent with WS4, patient 1 developed cerebellar ataxia, spasticity, and severe mental retardation (table 1). Several computed-tomography scans revealed only a slight cerebral atrophy. Pupillary light reflexes, optical fundus, sensitivity to pain and temperature, sense of smell, sweating, and salivation were normal. Echocardiography and 24-h electrocardiogram were unremarkable, but heart-rate variation parameters indicated an autonomic dysregulation. Similarly, there was almost no local reaction to the histamine test (flare <2 mm). Furthermore, he developed hepatosplenomegaly and portal hypertension of unknown origin. Three other boys who were members of his family had died during the first week of life; they had intestinal obstruction, and it was likely that they had WS, since the third child had patchy depigmentation of the scalp and white hair (fig. 1). Neither the mother nor any other family member had any signs of WS or HSCR.

In family 2, the proband was initially diagnosed with short-segment aganglionosis; he then presented with myoclonia at age 2 wk. Computed-tomography scans of his brain revealed no abnormalities. He responded well to phenobarbitone, but, later, he developed nystagmus, head bobbing, and paroxysmal movements of the upper

Table 1

WS4 Phenotype for Members of the Three Families Studied

FEATURE	PRESENCE OF FEATURE IN		
	Family 1	Family 2	Family 3 ^a
Colonic aganglionosis	Total	Short segment	Total
Iris heterochromia	+	+	–
Deafness	+	+	+
Mental retardation	Severe	Very mild	ND
Cerebellar ataxia	+	+	ND
Nystagmus	+	+	ND
Spasticity	+	+	+
Alacrims	+	+	ND
Asialia	–	+	ND
Reduced sweating	–	+	ND
Seizures	–	+	–
Growth failure	+	+	ND
Hypogonadism	+	–	ND

NOTE.—A plus sign (+) indicates presence, and a minus sign (–) indicates absence.

^a ND = not determined.

limbs without accompanying abnormalities (as assessed by electroencephalogram or brain magnetic-resonance imaging). On the basis of a later occurrence of torticollis and the benign course of the nystagmus, head bobbing, and paroxysmal movement, a putative diagnosis of spasmodic nutans was made, despite the early onset of symptoms and despite the presence of abnormal movements of the limbs. Later, antiepileptic drugs were withdrawn without any recurrence of seizures. Ataxia, spasticity, and reduced productions of tears, saliva, and sweat developed progressively. Growth failure occurred at age 8 years, and, at the time of the study, he was on the –2 SD curve. He had neither hypomelanotic lesions nor hepatosplenomegaly. Neither his parents nor any other family member had any signs of WS or HSCR.

The proband of family 3 was the first child of young parents. There was no history of either WS- or HSCR-affected members of the proband's family. A reduction of fetal movement was noted during the last month of pregnancy. Height, weight, and head circumference at birth were 50 cm, 2,980 g, and 35.5 cm, respectively. Severe neonatal distress required immediate resuscitation and admission to an intensive care unit. He presented with coma, arthrogryposis, meconial ileus, and a white forelock, but he did not have heterochromia irides. Analysis of intestinal biopsies led to the diagnosis of severe aganglionosis extending to the jejunum. Optical fundus were normal. Neither auditory brain stem-evoked responses nor electromyographic reactivity could be found. Electroencephalogram was abnormal, showing immaturity and discontinuity of the tracing, but paroxysmal discharges were not present. Analysis of muscle biopsy showed no specific lesions. He died on day 11 of life.

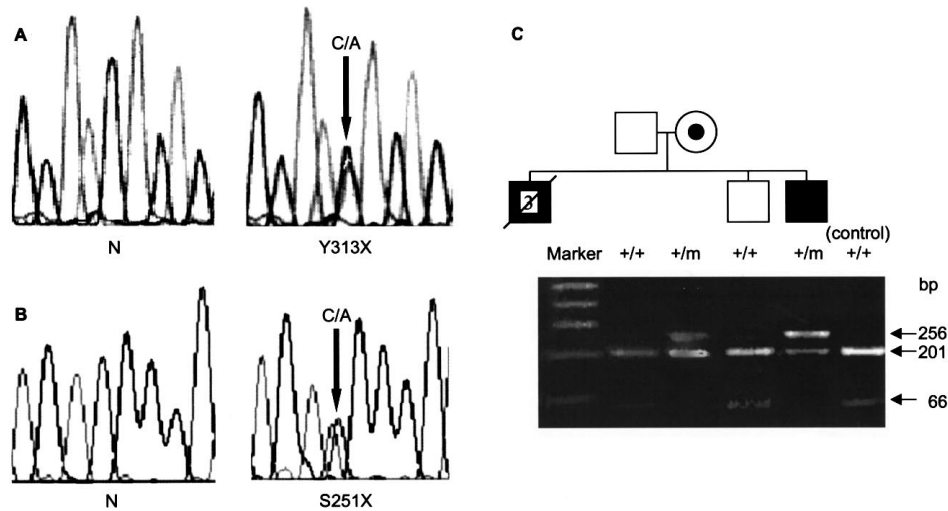


Figure 1 Y313X and S251X *SOX10* mutations. *A*, DNA sequence of *SOX10* exon 5 showing the normal sequence (N) and the Y313X heterozygous mutation (arrow) in the proband (family 1). *B*, DNA sequence of *SOX10* exon 5 showing the normal sequence (N) and the S251X heterozygous mutation in the proband (family 3). *C*, Family 1 with pedigree and PCR-amplified exon 5 of the *SOX10* gene, digested with *DdeI*: normal allele (+) = 201 + 66 bp (+32-bp fragment nonvisible), mutated allele (m) = 256 bp (+32-bp fragment nonvisible).

DNA Analysis

Mutation screening of *SOX10* coding sequence was performed by SSCP as previously described, except gel electrophoreses were performed in two different conditions: at room temperature and in a cold room (Pingault et al. 1998). In brief, PCR reactions were performed on 200 ng of DNA with *Taq* DNA polymerase (BRL). PCR products were heated for 10 min at 95°C in an equal volume of denaturing loading buffer and loaded onto an mutation-detection enhancement gel (FMC). The gels were then dried and autoradiographed for 24–72 h. PCR products that showed an abnormal SSCP pattern were directly sequenced on both strands by the fluorometric method (DyeDeoxy or BigDye Terminator Cycle sequencing kit; Applied Biosystems). When possible, mutations were confirmed by restriction-enzyme digestion on PCR amplification products.

In Situ Hybridization

Human embryos were collected from legally terminated pregnancies, in agreement with French law and the recommendations of the French Ethics Committee. Embryos were staged under a microscope according to the Carnegie classification criteria. Brain and organs of a 20-wk fetus were also studied. Tissues were fixed with 4% paraformaldehyde, embedded in paraffin blocks, and sectioned at 5 μ m. PCR amplification of human genomic DNA with *SOX10* exon 5 primers 5/2F and 5/2R (GGTAATGTCCAACATGGAGACC and GTA-GGCGATCTGTGAGGTGG, respectively) were cloned into pCR-Script Amp SK(+) (Stratagene). Sense and

antisense riboprobes were generated by either T7 or T3 RNA polymerase in the presence of α^{35} S-uridine 5'(α -thio)triphosphate (1,200 Ci/mmol; NEN). Labeled probes were purified on Sephadex G50 columns. Hybridization and posthybridization washes were carried out according to standard protocols (Wilkinson 1992). Slides were dehydrated, exposed to Biomax MR X-ray films (Amersham) for 3 d, dipped in Kodak NTB2 emulsion for 3 wk at +4°C, and then developed and counterstained with toluidine blue, coverslipped with Eukitt, and analyzed with dark- and bright-field illumination. No hybridization signal was detected with the α^{35} S-labeled sense probes, which confirmed that the in situ hybridization patterns of the α^{35} S-labeled antisense probes were specific. No cross-hybridization with *SOX9* mRNAs was observed (data not shown).

Results

DNA Analysis

Abnormal SSCP patterns were detected in the *SOX10* gene in all three WS4 patients studied. In each patient, a heterozygous mutation was located in *SOX10* exon 5, either at nucleotide 939 (TAC→TAA) or at nucleotide 752 (TCG→TAG), which predicted nonsense mutations at codon 313 (Y313X) and 251 (S251X), respectively (fig. 1A, 1B). The Y313X mutation abolished a *DdeI* restriction site and was found in families 1 (fig. 1C) and 2. In family 1, the mutation was inherited from the unaffected mother (fig. 1C), whereas, in family 2, the mutation was not inherited from the mother and the father

was not available for study. The S251X *SOX10* truncating mutation arose de novo in a boy (family 3) with hypotonia and arthrogryposis who died soon after birth. No other variation in the *SOX10* gene was found, and no abnormal SSCP pattern could be detected in the *RET* gene-coding sequence in the patients studied. The peculiar neurological phenotype, together with the similar localization of *SOX10* mutations in these WS4 patients, prompted us to look for *SOX10* expression during early human brain development.

SOX10 Expression in Developing Humans

Table 2 summarizes the expression pattern of *SOX10* in five human embryos in Carnegie stages 13–17 (days 28–43). At Carnegie 13, *SOX10* was strongly expressed in dorsal-root ganglia, otic vesicle (fig. 2A, 2B), and cells migrating around the aorta, in branchial arches, and toward the gut and tracheal bud (data not shown). At Carnegie 16, signal intensity increased in each of these areas (fig. 2C, 2D). In addition, nerve fibers originating from the anterior horn of the spinal cord expressed *SOX10* over their whole length up to the target tissues, whereas the anterior horn was negative (fig. 2D). At Carnegie 17, *SOX10* expression increased in ganglia and extended to cranial ectomesenchyme, inner ear (semi-circular canals, utricle, and saccula), and some regions of the maxilla, mandible, and tongue, consistent with the labeling of innervating fibers (fig. 2F). In the gut, expression was restricted to the outer muscular layer, where the enteric plexuses are located. Testis and developing pancreas were also *SOX10* positive (data not shown). No *SOX10* transcripts could be detected in the

central nervous system at any of the embryonic stages studied.

No *SOX10* expression in the cerebral cortex and brain nuclei was observed consistently in a 20-wk fetal brain. However, a diffuse but variable expression was seen in the other areas of the brain. High-power magnification showed that the signals were located in some strongly positive nonneuronal cells scattered in several glial-rich areas, namely pons (fig. 3A, 3B), cerebellum (fig. 3H), tectum of peduncle (fig. 3E), internal capsule (fig. 3D), and hippocampal formations (fig. 3F, 3G), consistent with *SOX10* expression in glial cells. Fetal expression of *SOX10* was also observed in the enteric and tracheal nervous systems, in pancreas acini, and in adrenal medulla (data not shown). Finally, no expression was detected in heart, kidney, thymus, spleen, or muscle. These results were in agreement with previous data (Bondurand et al. 1998).

Discussion

WS4 is a rare neurocristopathy that results in the absence of melanocytes and inner ear cells (WS) and parasympathetic enteric neurons of the terminal hindgut (HSCR; McKusick 1973; Branski et al. 1979; Omenn and McKusick 1979; Shah et al. 1981). WS4 is transmitted either as a recessive or a dominant autosomal trait, depending on whether the endothelin-signaling pathway (Puffenberger et al. 1994; Attié et al. 1995; Edery et al. 1996; Bidaud et al. 1997) or *SOX10* mutations (Pingault et al. 1998) are involved, respectively. Yet several WS4 cases are not related to *EDNRB*, *EDN3*, or *SOX10*

Table 2
SOX10 Expression in Early Human Embryogenesis

VARIABLE	EXPRESSION AT CARNEGIE STAGE ^a			
	13	14	16	17
Central nervous system	–	–	–	–
Peripheral nervous system:				
Enteric nervous system	Migrating cells	+	++	+++
Tracheal nervous system	Migrating cells	+	++	+++
Ganglia:				
Cranial	+	+	++	+++
Dorsal root	+	+	++	+++
Sympathetic	+	+	++	+++
Peripheric nerves	–	–	++	+++
Ectomesenchyme	–	+	++	Meckel ++; nasal cartilage +++
Otic vesicle	+	+	++	Internal ear +++
Testis	–	–	–	+++
Pancreas	–	–	–	+++
Lingual glands	–	–	–	+++

NOTE.—A plus sign (+) indicates presence, and a minus sign (–) indicates absence of the indicated expression. +, ++, and +++ = relative levels of expression.

^a Carnegie stage corresponds to the following ages: Carnegie 13, 28–31 d; Carnegie 14, 32 d; Carnegie 16, 37–40 d; and Carnegie 17, 41–43 d.

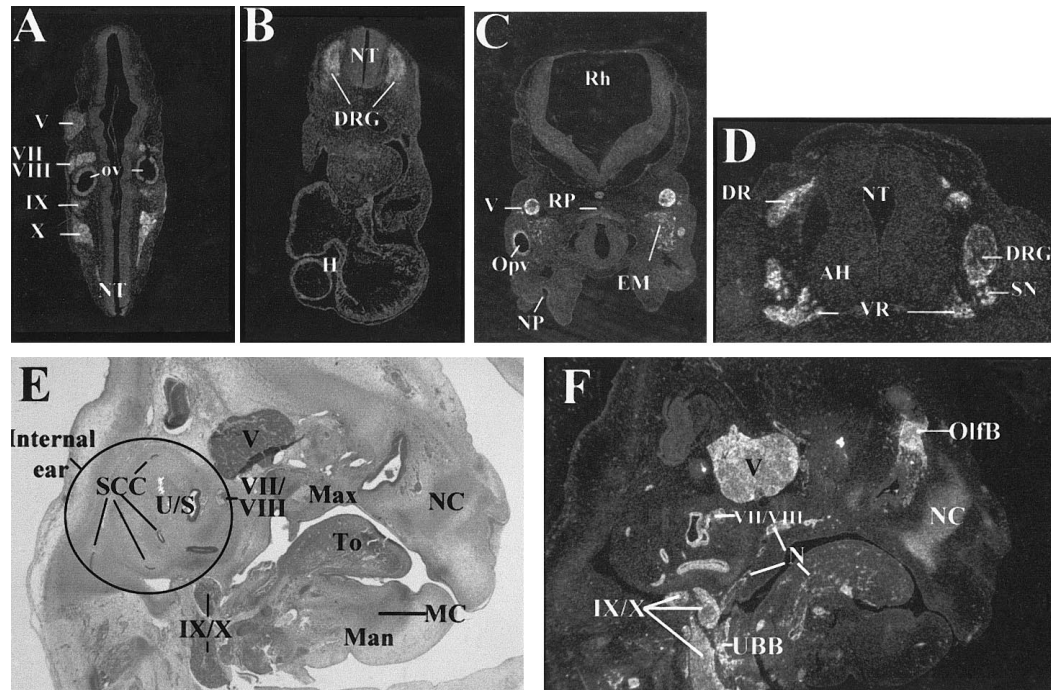


Figure 2 *SOX10* expression in transverse sections of a Carnegie 13 human embryo, under dark-field illumination. *A*, Cranial nerve ganglia (V, VII/VIII, and IX/X) and otic vesicle (OV). Also shown, neural tube (NT). *B*, Dorsal root ganglia (DRG). *SOX10* expression in transverse sections through a Carnegie 16 human embryo under dark-field illumination. Also shown, heart (H). *C*, Cranial nerve ganglia V and ectomesenchyme (EM). Also shown, nasal pits (NP), optic vesicle (Opv), rhombencephalon (Rh), and Rathke pouch (RP). *D*, Dorsal root (DR), dorsal root ganglia (DRG), spinal nerve (SN), and ventral root (VR) merging from the anterior horn (AH). Serial parasagittal sections through a Carnegie 17 human embryo, either hematoxylin and eosin-stained (*E*) or hybridized with *SOX10* riboprobe and examined under dark-field illumination (*F*), which shows *SOX10* expression in the cranial ganglia (V, VII/VIII, and IX/X), olfactory bulb (OlfB), cranial ectomesenchyme (i.e., Meckel cartilage [MC] and nasal cartilage [NC]), nerves in intercostal spaces, nerve fibers (N) in maxilla (Max), mandible (Man), and tongue (To), internal ear (semicircular canals [SCC], utricle, and saccula [U/S]), and the ultimobranchial body (UBB).

mutations. Among a total of 12 probands who presented with WS4 features (deafness, pigment anomalies, and HSCR), we have studied members of three families with a progressive neurological phenotype. There have been very few reports of WS patients with neurological involvement, including mental retardation with seizures or dystonia, muscular stiffness, and peripheral neuropathy, but none had HSCR (Kawabata et al. 1987; Cantani et al. 1989). Conversely, only two siblings have been reported with extensive digestive dysganglionosis, ataxia, peripheral neuropathy, and dysautonomic features but no feature of WS (Schuffler et al. 1978). Therefore, when we started this study, the patients presented an as-yet-unreported association. Although several hypotheses regarding the additional neurological symptoms could have been raised (such as a contiguous gene syndrome), we ascribed the disorder to truncating *SOX10* mutations in individuals in each of the three families studied. This hypothesis was further supported by two articles that describe WS4 patients with *SOX10* mutation and neurological features, published while this article was in preparation. Two siblings who harbored phenotypes

very similar to those of the patients we studied, including nystagmus and ataxic cerebral palsy (although only one of them had HSCR), were found to be heterozygous for the Q377X *SOX10* mutation (Southard-Smith et al. 1999). Furthermore, Inoue et al. (1999) described a patient with WS4, demyelinating neuropathy, and severe leukodystrophy. This patient harbored a heterozygous 1400del12 *SOX10* mutation that modified the 467 stop codon and extended the *SOX10* protein with 82 amino acids.

SOX10 is a member of the SOX family of transcription factors and local organizers of chromatin structure (Pevny and Lovell-Badge 1997). Binding of SOX-protein high-mobility group (HMG) domain to the specific DNA sequence motif A/T A/T CAA A/T G results in DNA bending. There is no evidence for target specificity, but rather there is evidence for tissue- and stage-specific expression, which delimits a specific role for each of the SOX family members. We speculate that the *SOX10* Y313X and S251X nonsense mutations are responsible for both WS4 and the additional neurological phenotype. Indeed, our data about *SOX10* expression support

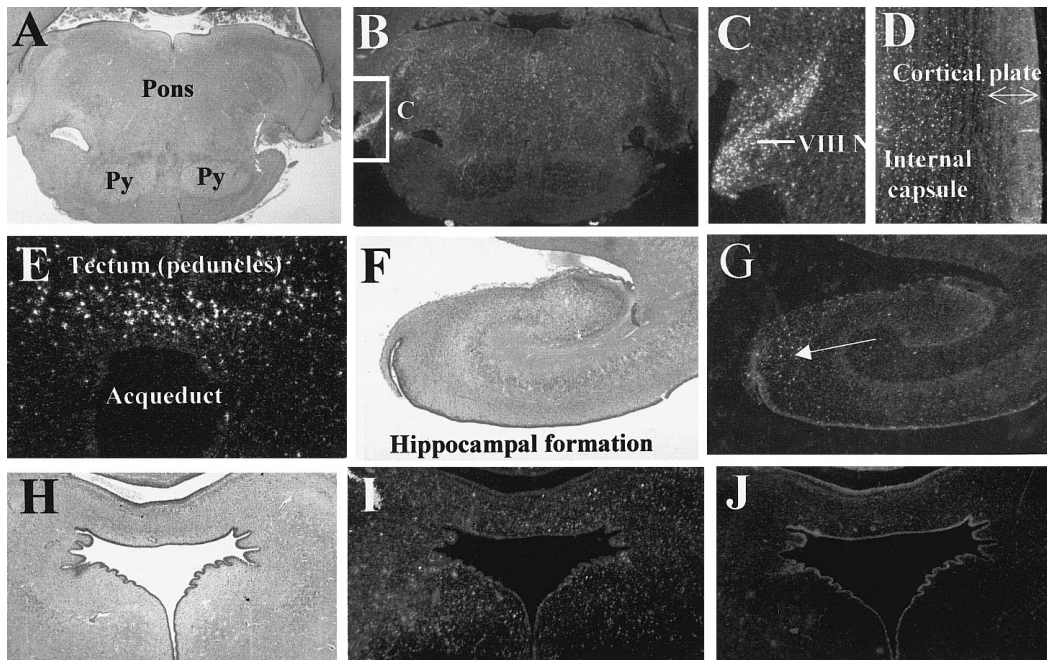


Figure 3 SOX10 expression in fetal brain. Transverse sections of the brain of a 20-wk fetus. A, E, H, hematoxylin and eosin staining. B, C, D, E, G, I, SOX10 in situ hybridization under dark-field illumination. C is a higher-magnification view of B (boxed area). A diffuse SOX10 expression is seen in many areas of the brain, located in some strongly positive cells scattered in the white matter, respecting the pyramidal tracts (A, B). Signal is more intense in pons (A–C); internal capsule (D); peduncle, especially in tectum (E); hippocampal formation (F, G); and cerebellum (H, I). J, Adjacent slide to I, hybridized with the sense (control) SOX10 probe. Cranial nerves are strongly labeled as shown for the nerve of cranial nerve ganglia VIII N (B, C). Py = pyramidal tracts.

its important role in neural-crest and brain development, especially since autonomous nervous system abnormalities are involved in the patients—namely, reduction in sweat, tear, and saliva production. Both the distribution and the morphology of the strongly positive cells scattered in fetal-brain white matter support the expression of SOX10 in glial cells—namely, oligodendrocytes, astrocytes, or immature glial cells—rather than neurons (fig. 3). Interestingly, in rodents, Sox10 is expressed in glial precursors and then in oligodendrocytes (Kuhlbrodt et al. 1998a). Although it is premature to establish the involvement of a specific subtype of glial cells in the central nervous system symptoms observed in the patients we studied, we can speculate on astrocyte impairment, according to recent data, which shows that cerebellar ataxia developed in mice after postnatal destruction of astrocytes (Delaney et al. 1996), whereas oligodendrocyte dysfunction would instead result in leukodystrophy.

The spectrum of SOX10 mutations reported to date supports the hypothesis that haploinsufficiency is the mechanism for dominance in WS4. Indeed, when we used a functional assay for SOX10 transcriptional activity, two nonsense and one frameshift SOX10 mutations resulted in loss of function, as shown in vitro (fig.

4; Kuhlbrodt et al. 1998b; Pingault et al. 1998). Since the patients with WS4 reported here also carry heterozygous mutations that truncate the last 216 and 154 amino acids residues of SOX10 for the S251X and Y313X mutations, respectively, there is no clear explanation for the phenotypic differences. However, it is worth noting that, so far, only the S251X and Y313X mutations are located between the HMG box and the

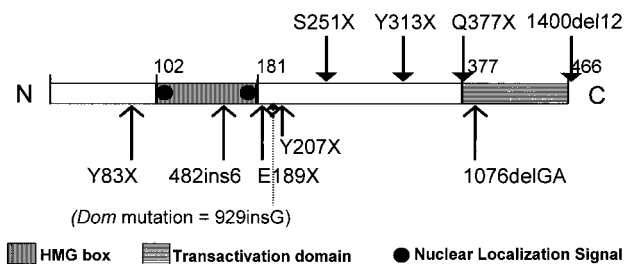


Figure 4 Representation of SOX10 protein with the transactivation domain and the HMG box, which shows the position of the seven previously reported mutations, the mutation responsible for the murine Dom mutant, and the two novel mutations. The mutations associated with an additional neurological phenotype are provided (upper part).

transactivation domain, in a *SOX10* region of unknown function (fig. 4). In addition, patients with *SOX10* mutations that result in either more proximal or more distal truncations, such as E189X, Y207X, or 1076delGA (in order, from more proximal to more distal), did not show any neurological symptoms (Pingault et al. 1998; Southard-Smith et al. 1999). The patients with nystagmus and ataxic cerebral palsy, briefly described by Southard-Smith et al. (1999), had a truncating mutation, Q377X, that removed only the transactivation domain. Conversely, the patient described by Inoue et al. (1999) had a mutation at the *SOX10* 3' end that resulted in the addition of 82 amino acids to the protein. Nevertheless, a possible hypothesis for the extended clinical spectrum in these patients would be that the S251X, Y313X, Q377X, and 1400del12 *SOX10* mutations resulted in a dominant negative effect. Indeed, such proteins with either an absent or a drastically modified transactivation domain, but that retained the HMG box, might have an enhanced DNA binding ability, blocking the promoter of *SOX10*-responding genes, without transactivation. Similar mechanisms have been demonstrated for other mutant transcription factors such as PAX6 (Singh et al. 1998) and MGF-Stat5 (Moriggl et al. 1996). Unfortunately, we failed to amplify by reverse transcriptase-PCR any *SOX10* mRNA, either normal or mutant, from lymphoblasts or leukocytes from patient 2 (data not shown). Therefore, mutant mRNA instability cannot be excluded: such a phenomenon, which has been reported several times in various genes, would preclude any dominant negative effect (Maquat 1995). Additional patients with a *SOX10* mutation are necessary to confirm the preliminary correlation between the phenotype and the location of truncating mutation. Alternatively, the wide phenotypic spectrum of *SOX10* mutations may be explained by the effect of modifier genes, such as those identified in oligogenic neurocristopathies such as nonsyndromic HSCR (Puffenberger et al. 1994; Salomon et al. 1996; Doray et al. 1998; Bolk et al. 2000), especially since the reported cases have been ascertained through the intestinal phenotype. The absence of HSCR in one of the two sibs with nystagmus and ataxic cerebral palsy, ascribed to the Q377X *SOX10* mutation (Southard-Smith et al. 1999), supports this hypothesis, but this is not sufficient to exclude the other mechanisms as far as the neurological phenotype is concerned.

Our study also emphasizes the apparently high rate of new mutations at the *SOX10* locus. Indeed, in a total of 11 informative WS4 families studied, 7 of 11 *SOX10* mutations arose de novo in the probands (Pingault et al. 1998; Inoue et al. 1999; Southard-Smith et al. 1999; this report; unpublished data). This does not seem to be related to a mutational hot spot, since most of the *SOX10* mutations are different. Along this line, there

is no clear explanation for the recurrence of the *SOX10* Y313X mutation, since it does not involve a CpG dinucleotide. It is thus possible that the high proportion of new mutations is due to an observation bias related to the severity of the WS4 phenotype, since most affected individuals are unlikely to reproduce. Of interest, in family 1, the mother of the proband did not show any symptoms, although she carried this Y313X mutation. It can be attributable either to a lack of penetrance—which would be surprising as far as a dominant negative effect of the mutation is postulated—or to somatic mosaicism. Indeed, the mutated Y313X allele in the mother had a significantly weaker intensity than the normal allele, compared with the pattern of her affected son (fig. 1). Furthermore, the DNA sequence of *SOX10* exon 5 in the mother was almost normal, with the mutant peak barely visible on the electropherogram (data not shown). Altogether, this favored the possibility of mosaicism. Unfortunately, the mother refused to allow us to further investigate her tissue samples. Mosaicism seemed to be present also in the father of the family described by Southard-Smith et al. (1999), as associated with the Q377X *SOX10* mutation.

This study highlights the role of *SOX10* as an important factor in development of both neural-crest-derived cells and glial cells of the central nervous system, which supports its involvement not only in WS4 but also in an extended progressive neurological phenotype, including growth retardation, impairment of the autonomous system (asialia, alacrima, and hypohidrosis), and central nervous system anomalies, namely neonatal hypotonia with arthrogryposis, ataxia, pyramidal signs, nystagmus, seizure, and mental retardation. Thus, these data suggest that *SOX10* might be regarded as an interesting candidate gene in other neurodegenerative disorders, especially since the penetrance for HSCR is incomplete in WS4.

Acknowledgments

We thank Dr. Peter H. Byers for interesting comments and kind attention. This study was supported by grants from the Association Française contre les Myopathies, the Ligue contre le Cancer (Comité de Paris), and the Association pour la Recherche contre le Cancer. R.L.T. is a fellow from the Société d'Etudes et de Soins pour les Enfants Paralysés et Polymalformés and the Fondation des Treilles.

Electronic-Database Information

Accession numbers and URL for data in this article are as follows:

Online Mendelian Inheritance in Man (OMIM), <http://www.ncbi.nlm.nih.gov/Omim> (for WS [MIM 193500, MIM

193510, MIM 600193, and MIM 148820], HSCR [MIM 142623], and WS4 [MIM 277580])

References

- Attie T, Till M, Pelet A, Amiel J, Edery P, Boutrand L, Munnich M, et al (1995) Mutation of the endothelin-receptor B gene in the Waardenburg-Hirschsprung disease. *Hum Mol Genet* 4:2407–2409
- Bidaud C, Salomon R, Van Camp G, Pelet A, Attie T, Eng C, Bonduelle M, et al (1997) Endothelin-3 gene mutations in isolated and syndromic Hirschsprung disease. *Eur J Hum Genet* 5:247–251
- Bolk S, Pelet A, Hofstra RMW, Angrist M, Salomon R, Croaker D, Buys CHCM, et al (2000) A human model for multigenic inheritance: phenotypic expression in Hirschsprung disease requires both the RET gene and a new 9q31 locus. *Proc Natl Acad Sci USA* 97:268–273
- Bondurand N, Kobetz A, Pingault V, Lemort N, Encha-Razavi F, Couly G, Goerich DE, et al (1998) Expression of the SOX10 gene during human development. *FEBS Lett* 432:168–172
- Branski D, Dennis NR, Neale JM, Brooks LJ (1979) Hirschsprung's disease and Waardenburg's syndrome. *Pediatrics* 63:803–805
- Cantani A, Bamonte G, Tacconi ML (1989) Mental retardation and EEG abnormalities in Waardenburg's syndrome: two case reports (EEG anomalies in Waardenburg's syndrome). *Pädiatr Pädol* 24:137–140
- Delaney CL, Brenner M, Messing A (1996) Conditional ablation of cerebellar astrocytes in postnatal transgenic mice. *J Neurosci* 16:6908–6918
- Doray B, Salomon R, Amiel J, Pelet A, Touraine R, Billaud M, Attie T, et al (1998) Mutation of the RET ligand, Neurturin, supports multigenic inheritance in Hirschsprung disease. *Hum Mol Genet* 7:1449–1452
- Edery P, Attie T, Amiel J, Pelet A, Eng C, Hofstra RM, Martelli H, et al (1996) Mutation of the endothelin-3 gene in the Waardenburg-Hirschsprung disease (Shah-Waardenburg syndrome). *Nat Genet* 12:442–444
- Inoue K, Tanabe Y, Lupski JR (1999) Myelin deficiencies in both the central and the peripheral nervous systems associated with a SOX10 mutation. *Ann Neurol* 46:313–318
- Kawabata E, Ohba N, Nakamura A, Izumo S, Osame M (1987) Waardenburg syndrome: a variant with neurological involvement. *Ophthalmic Paediatr Genet* 8:165–170
- Kuhlbrodt K, Herbarth B, Sock E, Hermans-Borgmeyer I, Wegner M (1998a) Sox10, a novel transcriptional modulator in glial cells. *J Neurosci* 18:237–250
- Kuhlbrodt K, Schmidt C, Sock E, Pingault V, Bondurand N, Goossens M, Wegner M (1998b) Functional analysis of sox10 mutations found in human Waardenburg-Hirschsprung patients. *J Biol Chem* 273:23033–23038
- Maquat LE (1995) When cells stop making sense: effects of nonsense codons on RNA metabolism in vertebrate cells. *RNA* 1:453–465
- McKusick VA (1973) Congenital deafness and Hirschsprung's disease. *N Engl J Med* 288:691
- Moriggl R, Gouilleux-Gruart V, Jahne R, Berchtold S, Gartmann C, Liu X, Hennighausen L, et al (1996) Deletion of the carboxy-terminal transactivation domain of MGF-Stat5 results in sustained DNA binding and a dominant negative phenotype. *Mol Cell Biol* 16:5691–5700
- Omenn GS, McKusick VA (1979) The association of Waardenburg syndrome and Hirschsprung megacolon. *Am J Med Genet* 3:217–223
- Pevny LH, Lovell-Badge R (1997) Sox genes find their feet. *Curr Opin Genet Dev* 7:338–344
- Pingault V, Bondurand N, Kuhlbrodt K, Goerich DE, Prehu MO, Puliti A, Herbarth B, et al (1998) SOX10 mutations in patients with Waardenburg-Hirschsprung disease. *Nat Genet* 18:171–173
- Puffenberger EG, Hosoda K, Washington SS, Nakao K, deWit D, Yanagisawa M, Chakravarti A (1994) A missense mutation of the endothelin-B receptor gene in multigenic Hirschsprung's disease. *Cell* 79:1257–1266
- Read AP, Newton VE (1997) Waardenburg syndrome. *J Med Genet* 34:656–665
- Salomon R, Attie T, Pelet A, Bidaud C, Eng C, Amiel J, Sarnacki S, et al (1996) Germline mutations of the RET ligand, GDNF, are not sufficient to cause Hirschsprung disease. *Nat Genet* 14:345–347
- Schuffler MD, Bird TD, Sumi SM, Cook A (1978) A familial neuronal disease presenting as intestinal pseudoobstruction. *Gastroenterology* 75:889–898
- Shah KN, Dalal SJ, Desai MP, Sheth PN, Joshi NC, Ambani LM (1981) White forelock, pigmentary disorder of irides, and long segment Hirschsprung disease: possible variant of Waardenburg syndrome. *J Pediatr* 99:432–435
- Singh S, Tang HK, Lee J-Y, Saunders GF (1998) Truncation mutations in the transactivation region of PAX6 result in dominant-negative mutants. *J Biol Chem* 273:21531–21541
- Southard-Smith EM, Angrist M, Ellison JS, Agarwala RR, Baxevanis AD, Chakravarti A, Pavan WJ (1999) The Sox10Dom mouse: modeling the genetic variation of Waardenburg-Shah (WS4) syndrome. *Genome Res* 9:215–225
- Wilkinson DG (1992) *In situ* hybridization. In: Rickwood D, Hames BD (eds) *The practical approach series*. Vol 109. IRL Press, Oxford