




Contents lists available at ScienceDirect

Egyptian Journal of Forensic Sciences

journal homepage: <http://www.journals.elsevier.com/egyptian-journal-of-forensic-sciences>

CASE REPORT

Cutaneous cut sign: A clue to self inflicted carving on the body by sharp object



Vipul Namdeorao Ambade ^{*,1}, Nilesh Keshav Tumram ¹, Pradeep Gangadhar Dixit ¹

Department of Forensic Medicine, Government Medical College, Nagpur 440 003, Maharashtra State, India

Received 28 May 2015; accepted 13 October 2015

Available online 15 December 2015

KEYWORDS

Suicide note;
Body writing;
Carving on body;
Cutaneous cut sign;
Sharp object;
Palm examination

Abstract Suicide notes are usually written with pen or marker on a paper, notebook, wall or mirror. However, suicide notes written on one's own body is very rare, and suicide note engraved with some metallic object on the body has not been reported yet. In the present suicidal death, the victim while carving some letters on the left arm with a razor had an incidental cut on right thumb. This incidental cut on the palm may be referred as "cutaneous cut sign" which gives a clue that the carving on the body with a sharp object was written by the victim himself. It also provides an additional importance of examination of palm for the presence of supportive evidences.

© 2015 The International Association of Law and Forensic Sciences (IALFS). Production and hosting by Elsevier B.V. This is an open access article under the CC BY-NC-ND license (<http://creativecommons.org/licenses/by-nc-nd/4.0/>).

1. Introduction

Medicolegal examination of the palm is very important in a victim of suspected suicide or homicide, often to evaluate for the presence of supportive evidences.^{1,2} Hanzlick and Ross³ also emphasize the importance of examination of the palm, where the ink marks are found on the palmer aspect of both hands while writing a suicide note on a paper by the victim before committing suicide. Usually, the notes are written with pen or marker on the paper, notebook, wall, mirror, etc.^{4,5}; and rarely on the body.⁶ But notes written with a sharp object on the body has not been reported in the literature. We present a case of suicide in which the victim while engraving some let-

ters on the body with a razor had an incidental cut on the palm, and may be referred as "cutaneous cut sign" of suicide.

2. Case report

A 40-year married man had committed suicide out of frustration due to unemployment and financial crisis. He was under depression due to the debt. His body was retrieved from the lake having parapet wall boundary and platform on one side. His footwear was found at the platform and one blood stained razor was also recovered a short distance away.

On external examination, clothes of the deceased were intact and the left sleeve of the shirt was folded up to the shoulder. Suicidal note was recovered from the wallet of the deceased. Some engraved letters spelled as "MILU" were written with a sharp object on the anterior aspect of the left arm. (Figure 1). These letters were in the form of linear cuts and were superficially subcutaneously deep. There was also a superficial skin deep cut of size 1 cm × 0.2 cm on the palmer aspect of the right thumb (Figure 2). Autopsy findings were

* Corresponding author at: 479, Godhani Road, Opposite IDBI Bank, Nagpur 441111, Maharashtra State, India. Tel.: +91 712 2669132, +91 712 2743588; fax: +91 712 2740832.

E-mail address: vipulambade@rediffmail.com (V.N. Ambade).

¹ Tel.: +91 712 2743588; fax: +91 712 2740832.

Peer review under responsibility of The International Association of Law and Forensic Sciences (IALFS).

<http://dx.doi.org/10.1016/j.ejfs.2015.10.001>

2090-536X © 2015 The International Association of Law and Forensic Sciences (IALFS). Production and hosting by Elsevier B.V.

This is an open access article under the CC BY-NC-ND license (<http://creativecommons.org/licenses/by-nc-nd/4.0/>).



Figure 1 Photograph showing letters 'MILU' engraved with a razor blade on the left arm.

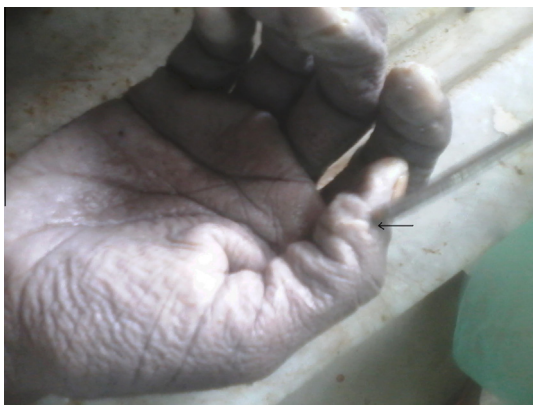

Figure 2 Superficial cut on the right thumb referred as 'cutaneous cut sign' of suicide while engraving letters on the left arm.

suggestive of death due to drowning. Toxicological analysis of the blood revealed ethyl alcohol in the concentration of 88 gm/dl.

3. Discussion

Examination of the palm of the victim is very important in medicolegal practice. In homicidal cases, the palm is examined for the presence of tissue debris under nails, and for the detection of any foreign materials like hair, fibers, buttons, cloth piece, defense wounds, etc.^{1,7} The hands are also examined for the detection of gunpowder in firearm cases.^{1,2} In certain suicidal cases, some notes or messages were found to be written by the victim on the palm.⁸ Here we present an additional finding on the hand referred as "cutaneous cut sign" of suicide while writing suicidal notes on the body with a sharp object.

A suicide note typically conveys the final words that can be a very potent message to the family and friends of the deceased.⁵ It is a document often to explain the reasons for this act and to say goodbye to loved ones. Usually the notes are written with pen or marker on the paper, notebooks, wall, mir-

ror, etc.⁵ Rarely the notes are written on the body.^{4,6} But notes written with a sharp object on the body has not been reported in the literature. Such notes by a sharp object suggest the strong intent of the victim toward the cause of action so that their message will not be overlooked. In the present case, the victim was under some depression due to the debt. Before committing suicide out of frustration, the victim had engraved the letters 'MILU' on his left arm. The first letter of this word was found to be the initial of his wife "M" to which the victim wishes a goodbye note 'ILU' for "I Love You". This note might be the parting affection of a victim toward his wife. While engraving these letters over the body with a razor, the victim had an incidental cut on the palmar aspect of the right thumb referred as "cutaneous cut sign" of suicide.

The presence of "cutaneous cut sign" indicates the contact with the sharp object while carving the letters on the body before committing suicide. Thus it gives strong evidence that the carving on the body with a sharp object was self inflicted. Moreover, the presence of cut on the palm with engraved notes on the body of an individual who had died in unexplained circumstances should arouse suspicion of suicide.

Funding

None.

Conflict of interest

None declared.

Informed consent

None declared.

Ethical approval

Necessary ethical approval was obtained from the institute ethics committee.

References

1. Adelson L. *The pathology of homicide*. 2nd ed. Springfield II: Charles C Thomas; 1974. p. 314–7.
2. Spitz WU, Fisher RS. *Medicolegal investigation of death*. 2nd ed. Springfield II: Charles C Thomas; 1980. p. 256–9.
3. Hanzlick RL, Ross WK. The cutaneous ink sign: a tippoff to suicide or suicide notes. *J Forensic Sci* 1987;**32**(2):565–6.
4. Austin A, Byard RW. Skin messages in suicide – an unusual occurrence. *J Forensic Legal Med* 2013;**20**:618–20.
5. Rothschild MA, Potente S. Abschiedsbrief per SMS. *Rechtsmedizin* 2001;**11**:94–5 in German.
6. Taylor LL, Hnilica V. Investigation of death through body writing: a case study. *J Forensic Sci* 1991;**36**(5):1607–13.
7. Reddy KSN. *The essentials of forensic medicine and toxicology*. 32nd ed. Hyderabad: Om Sai Graphics; 2013, pp. 102.
8. Behera C, Rautji R, Krishna K, Kumar A, Gupta S. Suicide note on the palm: three case reports and discussion of medico-legal aspects. *Med Sci Law* 2013.