

HOSTED BY



ELSEVIER

Contents lists available at ScienceDirect

# Turkish Journal of Emergency Medicine

journal homepage: <http://www.elsevier.com/locate/TJEM>

## Non-traumatic atlanto-axial rotatory subluxation: A rare cause of neck stiffness

Pinar Gencpinar <sup>a,\*</sup>, Mine Erkan <sup>b</sup><sup>a</sup> Akdeniz University, Department of Pediatric Neurology, Antalya, Turkey<sup>b</sup> Akdeniz University, Department of Pediatrics, Turkey

### ARTICLE INFO

#### Article history:

Received 3 January 2014  
 Received in revised form  
 17 February 2014  
 Accepted 7 March 2014  
 Available online 17 November 2015

#### Keywords:

Neck stiffness  
 Childhood  
 Subluxation

### ABSTRACT

Atlanto-axial rotatory subluxation is a rare condition in childhood. A sudden onset of pain and limitation in neck movements are the most common presenting features. Usually, a previous trauma history exists. This study presents a case of an 18-month-old male with neck stiffness and pain in neck through palpation without trauma in his history but with rotatory subluxation of 30° in atlanto-axial joint observed in his cervical imaging. With this case, the aim was to emphasize the necessity for considering the atlanto-axial subluxation in patients less than five years old diagnosed with neck stiffness in differential diagnosis even if a trauma is not available in their histories.

Copyright © 2015 The Emergency Medicine Association of Turkey. Production and hosting by Elsevier B.V. on behalf of the Owner. This is an open access article under the CC BY-NC-ND license (<http://creativecommons.org/licenses/by-nc-nd/4.0/>).

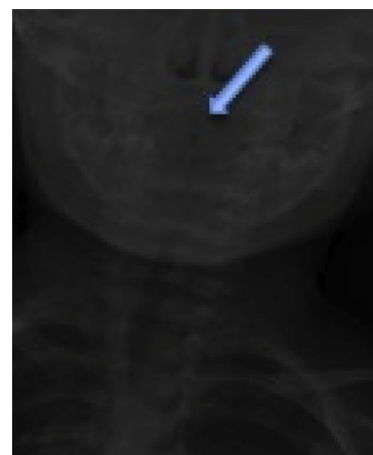
### 1. Introduction

Atlanto-axial rotatory subluxation is a rare clinical condition, which is seen in childhood because of the elasticity of connective tissue and generally after a traumatic situation. Symptoms occur suddenly and patients generally present with neck pain and limitation of neck movements.<sup>1,2</sup> There is often a history of trauma in these cases, but the same symptoms may also be seen in other non-traumatic situations like tonsillitis, pharyngitis, laryngitis and deep neck infection from Grisel's syndrome.<sup>3</sup>

### 2. Case

An 18-month-old baby boy was admitted to emergency department with complaints of restlessness and crying after waking. In his history there was no fever, upper respiratory tract infection, dysuria, vomiting, or trauma. In physical examination, the patient's neck was stiff, and there was neck pain with palpation and right-sided torticollis. Examinations of other systems were normal. Direct radiogram of the cervical region showed suspicious findings at the atlanto-axial joint. A computed tomography (CT) scan

confirmed a 30° rotatory subluxation of atlanto-axial joint (Figs. 1 and 2). The patient consulted with the neurosurgery department and was hospitalized with a cervical collar for a clinical follow-up. After five days follow-up with a cervical collar, there was no other additional clinical finding, and the patient was discharged. There was no pathologic rotation in control CT scan and no complaints after three weeks.



**Fig. 1.** Direct radiogram of our patient showed that the space between the dens and massa lateralis increased on the right side, and then the left side.

\* Corresponding author.

E-mail address: [pinargencpinar@yahoo.com.tr](mailto:pinargencpinar@yahoo.com.tr) (P. Gencpinar).

Peer review under responsibility of The Emergency Medicine Association of Turkey.

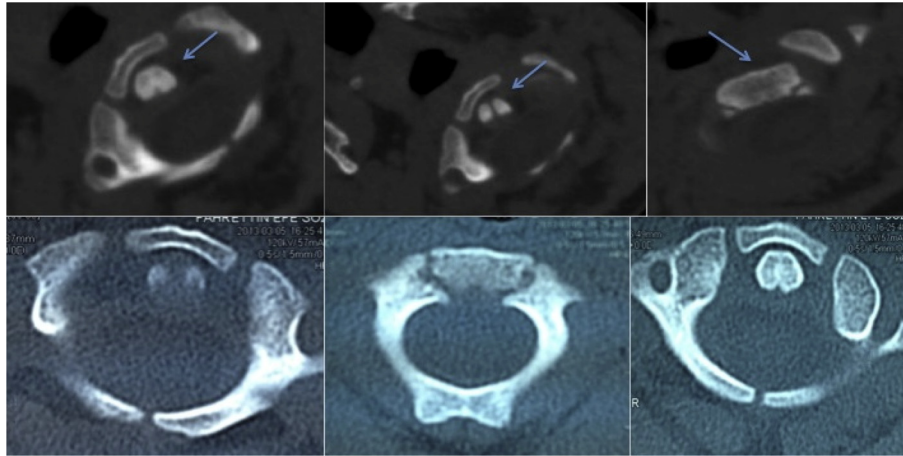


Fig. 2. The CT images (upper) showed a rotatory subluxation of 30° in atlanto-axial joint of C2 vertebra. It is observed that the rotation improved in following images.

### 3. Discussion

Neck stiffness and meningismus are resistances that occur when the patient's neck begins to flexion passively. When neck stiffness is examined in a patient, it is primarily thought to be central nerve system infections, though trauma and inflammatory and congenital causes should be kept in mind.<sup>4</sup> When the limitation of neck movements or torticollis accompanies neck stiffness, causes like dislocation, subluxation, and fracture in the cervical vertebrae should be considered and imaging modalities should be made.<sup>5,6</sup> In our case, in physical examination there was neck pain, neck stiffness, and torticollis without trauma history, so we evaluated X-ray and CT scan of cervical vertebrae. A computed tomography (CT) scan confirmed a 30° rotatory subluxation of atlanto-axial joint. Direct radiogram of cervical vertebrae is not useful at all times to determine the rotations, but sensitivity becomes 99% when open mouth odontoid plain X-ray films are combined with CT scans. It is difficult to get open mouth films in little children due to the lack of cooperation. Given the side effects of CT, such as ionizing radiation, magnetic resonance imaging (MRI) seems to be more useful, though it should not be the first choice due to its lack of cost efficiency and applicability everywhere. New imaging techniques like three-dimensional CT scan can help in difficult cases.<sup>7,8</sup>

Atlanto-axial rotatory subluxation is a condition in which C1 vertebra moves rotationally above C2 vertebra, most commonly caused by trauma.<sup>1,6</sup> It is frequently seen in children under the age of 8 due to the increased elasticity of connective tissue and anatomic variations. Upper respiratory tract infections caused by

Grisel's syndrome should be investigated in cases without a history of trauma. This rarely seen syndrome occurs following an infection neck operation and recovers spontaneously in three weeks.<sup>9</sup> In our patient's history and physical examination, there was no infection or operation causing an inflammation in the neck.

With this case, we would like to highlight that atlanto-axial subluxation should be kept in mind when neck stiffness is seen in children who are under 8 years old without histories of trauma.

### References

- Muniz AE, Belfer RA. Atlantoaxial rotary subluxation in children. *Pediatr Emerg Care*. 1999;15:25–29.
- Kawabe N, Hirotsu H, Tanaka O. Pathomechanism of atlanto-axial rotatory fixation in children. *J Pediatr Orthop*. 1989;9:569–574.
- Crook TB, Enyon CA. Traumatic atlantoaxial rotatory subluxation. *Emerg Med J*. 2005;22:671Y672.
- Kanra G, Ceyhan M, Kara A. Menenjit II: Klinik bulgular ve tanı. *Çocuk Sağlığı ve Hastalıkları Dergisi*. 2003;46:128–138.
- Subach BR, McLaughlin MR, Albright AL, Pollack IF. Current management of pediatric atlantoaxial rotatory subluxation. *Spine*. 1998;23:2174–2179.
- Martinez-Lage JF, Martinez Perez M, Fernandez Cornejo VJ, Poza M. Atlanto-axial rotatory subluxation in children: early management. *Acta Neurochir (Wien)*. 2001;143:1223–1228.
- Been HD, Kerkhoffs GM, Maas M. Suspected atlantoaxial rotatory fixation-subluxation: the value of multidetector computed tomography scanning under general anesthesia. *Spine*. 2007;32:E163YE167.
- Duan S, Huang X, Lin Q, Chen G. Clinical significance of articulating facet displacement of lateral atlantoaxial joint on 3D CT in diagnosing atlantoaxial subluxation. *J Formos Med Assoc*. 2007 Oct;106:840–846.
- Fernandez Cornejo VJ, Martinez-Lage JF, Piqueras C, Gelabert A, Poza M. Inflammatory atlanto-axial subluxation (Grisel's syndrome) in children: clinical diagnosis and management. *Childs Nerv Syst*. 2003;19:342–347.