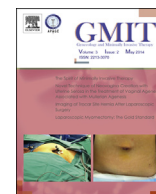

Contents lists available at ScienceDirect

Gynecology and Minimally Invasive Therapy

journal homepage: www.e-gmit.com

Short communication

Novel technique of neovagina creation with uterine serosa in the treatment of vaginal agenesis associated with mullerian agenesis

Jiah Min Lee ^{a, c}, Chen-Ying Huang ^{b, c}, Kai-Yun Wu ^b, Chih-Feng Yen ^b, Bernard Chern ^a, Chyi-Long Lee ^{b, *}^a Department of Minimally Invasive Surgery Unit, KK Women's and Children's Hospital, Singapore^b Department of Gynaecology Endoscopy Unit, Chang Gung Memorial Hospital at Linkou and Chang Gung University College of Medicine, Kwei-Shan, Taoyuan, Taiwan

ARTICLE INFO

Article history:

Received 21 February 2014

Received in revised form

22 March 2014

Accepted 28 March 2014

Available online 12 June 2014

Keywords:

Laparoscopy

Lee's neovaginoplasty

Neovagina

Uterine serosa

Vaginal agenesis

ABSTRACT

Objective: Our aim was to create a neovagina with the least surgical morbidity and the best functional outcome.**Materials and methods:** We hereby describe a new technique (Lee's neovaginoplasty) using a combined laparoscopic and vaginal approach in the creation of a neovagina using the uterine serosa layer from the rudimentary uterus and the peritoneum as a graft to line the vagina. This procedure was performed in three patients who were followed-up for a duration of 4 months to 2 years. Vaginal dilation was maintained with a vaginal mold daily for 3 months and three to four times a week thereafter.**Results:** Adequate vaginal length of 6–7 cm and width of 2.5 cm was achieved postoperatively. There were no surgical complications and postoperative recovery was fast. Vaginal examination 1 month later showed healthy vaginal tissue with no necrosis or infection. Long-term follow-up did not show any shortening or stenosis of the vagina. Patients were able to have satisfactory sexual intercourse with no pain.**Conclusion:** The laparoscopic-vaginal approach of using a uterine serosa and peritoneal graft for creation of a neovagina is a simple and effective approach with minimal surgical morbidity that can create a passageway for satisfactory intercourse.

Copyright © 2014, The Asia-Pacific Association for Gynecologic Endoscopy and Minimally Invasive Therapy. Published by Elsevier Taiwan LLC. All rights reserved.

Introduction

Mullerian agenesis, or Mayer-Rokitansky-Kuster-Hauser syndrome, has an incidence of 1 in every 4000–10,000 females.¹ It results from embryologic failure of development of the mullerian duct, which leads to agenesis or hypoplasia of the uterus and vagina. Patients normally present with primary amenorrhea but have normal secondary sexual characteristics and are genetically female. They have an absent or short blind-ending vagina. Most affected individuals have small, rudimentary uterine bulbs without functional endometrium. The ovaries are normal in

structure and function because they have a different embryologic source. There is an association with other congenital anomalies; 30% have renal anomalies and 12% have skeletal (mainly vertebral anomalies).¹

Treatment aims to create a neovagina that can provide a passageway for satisfactory intercourse with the least morbidity. Options include nonsurgical and surgical methods. The nonsurgical Frank and Ingram methods of progressive self-vaginal dilation with hand-held dilators or dilators mounted on a bicycle seat stool^{2,3} carries the least morbidity but requires a prolonged period of treatment⁴ and may cause discomfort. Surgical options for the creation of a neovagina include split-thickness skin graft (McIndoe procedure),^{5,6} or full-thickness skin graft,⁷ sigmoid vaginoplasty,^{8–10} peritoneal graft (Davydov procedure),^{11,12} Vecchiotti procedure^{13,14} (which uses an external traction device placed on the abdomen to exert continuous pressure on the vaginal dimple via a 2-cm olive bead), and amnion grafts.^{15,16} However, there is still no clear consensus on the best method.

Conflicts of interest: All authors declare that they have no conflicts of interest.

* Corresponding author. Department of Obstetrics and Gynecology, Chang Gung Memorial Hospital at Linkou and Chang Gung University College of Medicine, 5 Fu-Hsing Street, Kwei-Shan, Taoyuan 33305, Taiwan.

E-mail address: leechyilong@gmail.com (C.-L. Lee).^c These authors are co-first authors.<http://dx.doi.org/10.1016/j.gmit.2014.05.006>

2213-3070/Copyright © 2014, The Asia-Pacific Association for Gynecologic Endoscopy and Minimally Invasive Therapy. Published by Elsevier Taiwan LLC. All rights reserved.

Our aim was the creation of a neovagina with minimal surgical morbidity with characteristics that can facilitate satisfactory intercourse with natural lubrication and good sensitivity. The use of laparoscopy decreases morbidity because laparoscopic surgery has smaller wounds, less pain, and faster recovery. Minimally invasive surgery has been the trend in gynecologic surgery with an increasing spectrum of applications.^{17–19}

In this paper, we describe a novel procedure in three patients with vaginal agenesis secondary to müllerian agenesis, whereby a combined laparoscopic and vaginal approach was used to create a neovagina with the uterine serosa layer from the rudimentary uterine horns.

Case report

Three patients with vaginal agenesis underwent surgery at ages 19 years, 20 years, and 21 years. They first presented with primary amenorrhea at the age of 14–15 years. Development of secondary sexual characteristics, height, weight, and external genitalia were normal. On examination, the hymen was present but the vagina was absent or only a small dimple was present. Pelvic ultrasound showed normal ovaries and absent uterus and vagina. However magnetic resonance imaging of the pelvis revealed small unilateral or bilateral rudimentary uterine bulbs. Karyotype studies showed normal female chromosomes 46XX. Hormonal function – follicle stimulating hormone, luteinizing hormone, estradiol, prolactin, and testosterone were all in the normal range. The female chromosomes and normal testosterone levels exclude androgen insensitivity syndrome. Intravenous pyelogram was performed because there is a high incidence of associated renal abnormalities. The kidneys and ureters were normal in all three patients. One patient had a bladder diverticulum. A chest radiograph showed scoliosis in one of the patients. None of the three patients had any cyclical pelvic pain or hematometra on ultrasound excluding the possibility of functional endometrium in the rudimentary uterine bulbs. These three patients sought help because they wanted to be sexually active. They underwent a combined laparoscopic vagina surgery with uterine serosa and peritoneum as a graft for the neovagina.

The patients were placed in the lithotomy position and were catheterized. We performed laparoscopy with the closed entry technique. A Veress needle was inserted at the umbilicus because none of the patients had a previous midline laparotomy. High intra-abdominal pressures of 20–25 mm Hg were used during insufflation to minimize the risk of vascular and bowel injury during first trochar entry.²⁰ The 5-mm primary trochar was inserted through the umbilicus and three accessory ports were inserted under laparoscopic guidance. The intra-abdominal pressure was then lowered to 15 mm Hg during surgery. Intraoperative findings showed bilateral rudimentary uterine bulbs (Fig. 1) in two patients; the third patient had a left uterine bulb and an absent right uterine bulb. In all three patients, both ovaries were normal and the vagina was absent. The rudimentary uterine bulbs were first separated from the ovaries by coagulating and cutting the ovarian ligament.

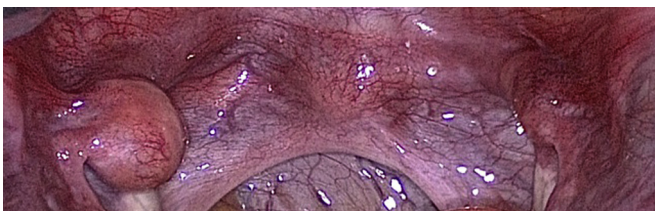


Fig. 1. Bilateral rudimentary uterine bulbs.

The anterior and posterior leaves of the broad ligament were opened from lateral to medial until the uterine arteries were reached. The ureters were traced and identified on both sides and the peritoneal incision was made above the ureters. The attached peritoneum from the anterior and posterior leaves of the broad ligament and the vesical fold peritoneum were harvested as part of the graft. The uterine arteries were preserved.

We then proceeded vaginally and a knife was used to make a vertical incision on the hymenal tissue. This space between the urethra and the rectum was developed with the closing and opening action of an artery clamp. A finger was inserted in the space created and blunt finger dissection was used to open up the space. To ensure that the dissection was in the right direction and space, another finger was placed in the rectum simultaneously during dissection of the neovagina space to ensure there was no rectal perforation. The bladder was catheterized with an indwelling catheter to minimize inadvertent cystostomy. The entire process of the creation of the neovagina space was done under laparoscopic guidance to ensure correct axis of the neovagina.

The vaginal space was then opened up with two metal retractors placed anteriorly and posteriorly. A plastic probe was then inserted into the vagina space created. The vagina vault was pushed up with the plastic probe and an incision was made with monopolar scissors on the vaginal vault laparoscopically, creating an opening between the abdominal cavity and the vagina. The two rudimentary uterine bulbs were then brought down into the vagina with the use of a ring forceps. The excess myometrium layer was trimmed away with a scissors vaginally, leaving a uterine serosa layer of about 3 mm in thickness. The peritoneal surface of the uterine serosa forms the vaginal wall surface. The two pieces of uterine serosa were then fixed at the introitus anteriorly and posteriorly with four interrupted sutures. A cylindrical silicone vaginal mold was then inserted into the vagina and stitched to the perineum to prevent vaginal adhesions. This was later removed on the 3rd postoperative day.

The vaginal vault was then closed laparoscopically, taking care to avoid occlusion of the blood supply from the uterine arteries. The completed surgery is shown laparoscopically and vaginally in Fig. 2 and Fig. 3, respectively.

Postoperatively, patients were covered with intravenous cefazolin and gentamicin for 1 day followed by 1 week of oral cefadroxil. They were started on graduated feedings to a soft diet on the 1st day and encouraged to ambulate. The cylindrical vaginal stent and bladder catheter were kept *in situ* and removed on the 3rd postoperative day. The patients were then monitored for 1–2 more days to assess wound healing and any complications after vaginal mold removal. They were discharged on the 4th or 5th postoperative day. Prior to discharge they were taught how to use a vaginal dilator and were given bacitracin ointment and premarin cream twice a day for vaginal application for 2 weeks. The vaginal mold is used

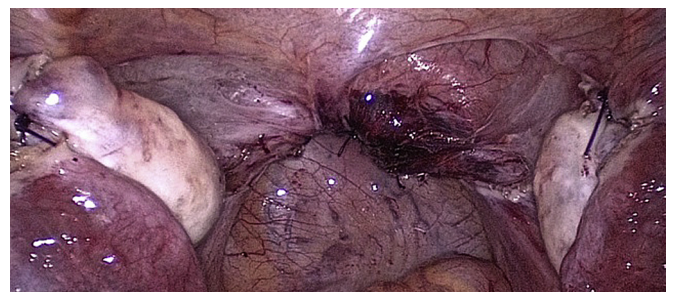

Fig. 2. Laparoscopic view after vault closure.

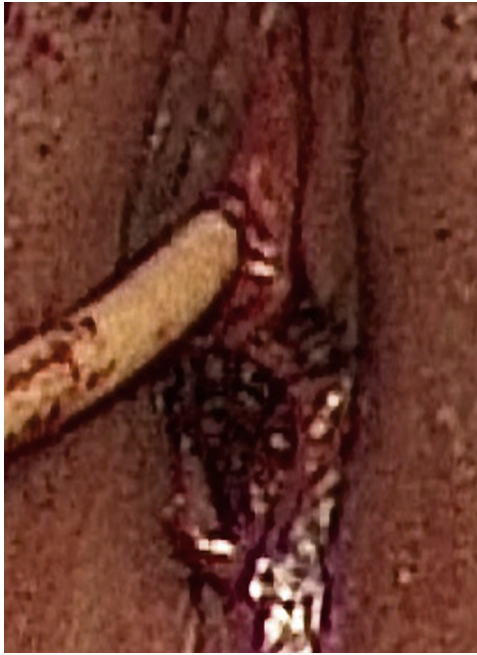

Fig. 3. Vaginal view at the conclusion of surgery.

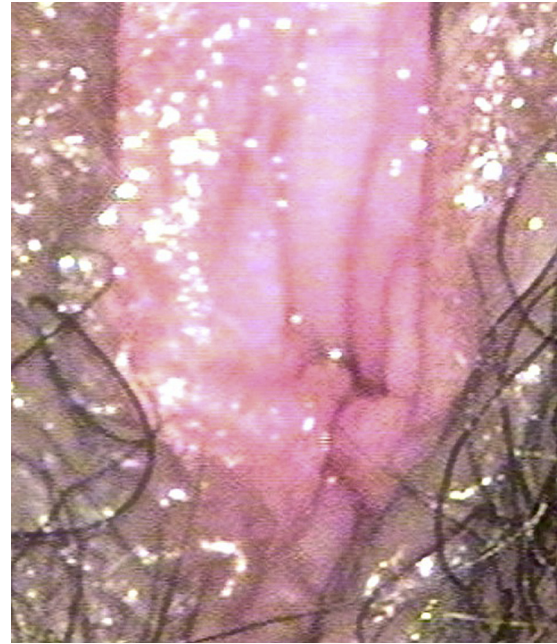

Fig. 4. Vaginal opening 6 months after surgery.

daily for 3 months and 3–4 times a week thereafter or less if there is regular sexual intercourse.

A vaginal length of 6–7 cm and a width of 2.5 cm was achieved. Follow-up was done at 2 weeks, 6 weeks, and 10 weeks postoperatively, then every 6 months for 1 year and yearly thereafter. One patient was followed-up for 4 months, the second patient for 1.5 years, and the third patient for 2 years. Initial postoperative recovery was good. Pain was minimal and managed with naproxen. Patients were able to ambulate by the 1st or 2nd postoperative day and were discharged in 5 days when the vagina wound had healed. There were no postoperative complications. Examination of the vagina 1 month after the surgery with vaginoscopy showed good epithelialization of the peritoneum and uterine serosa with healthy mucosal lining, with no necrosis or infection, good vaginal length, and no stenosis. From 3 months after surgery, patients were allowed to have intercourse because the neovagina had healed completely. They were able to have satisfactory intercourse without any pain and were able to achieve orgasm. There was natural lubrication from the uterine serosa and peritoneal surface of the neovagina. During long-term follow-up, good vaginal length (6–7 cm) was maintained with no stenosis. Fig. 4 shows the 6-month postoperative result of the vaginal opening.

Discussion

Timing for nonsurgical or surgical creation of a neovagina is critical and is best planned when the patient is emotionally mature and expresses the desire for correction. Therefore, we waited until our patients were of a mature age prior to offering treatment. This is important for success of the procedure because it requires a period of daily postoperative vaginal dilation for 3 months followed by maintenance with sexual intercourse or vaginal mold use a few times a week.

Nonsurgical creation of the vagina with self-vaginal dilators^{2,3} has the lowest morbidity but may require a long duration of vaginal mold use, high degree of self-motivation, and may be uncomfortable. In a study by Gargollo et al,⁴ of 64 patients, 88% achieved functional success at a median of 18.7 months. Success rates

depend on the frequency of vaginal mold use, sexual activity, and initial vaginal depth. Manual dilation is less likely to be successful in patients with a completely absent vagina (as in our series).

Surgery is an option for patients for whom dilators are unsuccessful or for patients who prefer surgery. Many surgical methods are available but the best option for functional outcome and sexual satisfaction with the least morbidity is still unknown. In our opinion, Lee's neovaginoplasty is currently the best method.

Using uterine serosa with peritoneum to create a neovagina is ideal because the peritoneum and uterine serosa are naturally moist and can provide lubrication for intercourse. The addition of a 3-mm layer of uterine serosa as part of the graft compared to peritoneum only (as in the Davydov procedure)^{11,12} gives added strength to the tissue, making it less friable and less likely to break down during intraoperative handling and during the postoperative healing phase. It avoids the morbidity from the use of other grafts such as skin grafts and bowel grafts. Skin grafts are associated with skin scarring and risks of infection at the donor site.⁶ Split-thickness skin grafts (McIndoe technique) have a high risk of postoperative contracture and require long-term regular use of a vaginal mold for prevention of complications.⁶ Full-thickness skin grafts⁷ have a much lower risk of neovagina skin contracture but still have risks of skin scarring from the donor site. Bowel grafts often necessitate laparotomy, although the laparoscopic approach has been described in a few studies.⁸ Bowel grafts are associated with surgical risks from major bowel surgery, for example, intestinal stenosis and obstruction, intestinal wound dehiscence, and fistula formation, and may also have neovagina complications of introital stenosis and mucosa prolapse.^{8–10} Bowel grafts also tend to have excessive mucoid discharge.

The combined laparoscopic vaginal approach in Lee's neovaginoplasty avoids the morbidity from skin and bowel grafts, avoids laparotomy, minimizes postoperative pain, and has a fast postoperative recovery. It also avoids the discomfort and prolonged use of vaginal dilators associated with manual dilation methods (Frank and Ingram)^{2,3} and discomfort from external traction methods on the vagina, like the laparoscopic Vechietti method.^{13,14}

For the success of this procedure, it is necessary to take note of a few important surgical pointers. Harvesting a wide enough area of

peritoneum together with the uterine serosa is important so that there is enough peritoneum to cover the entire neovagina surface. The two pieces of uterine serosa form the anterior and posterior walls of the vagina whereas the peritoneum is needed to cover the lateral walls. Ensuring that the entire vaginal surface is lined with peritoneum and uterine serosa facilitates the epithelialization of the neovagina walls and reduces adhesion formation, which could result in obstruction or stenosis of the neovagina. While harvesting the accompanying peritoneum, care must be taken to identify the course of the ureter and ensure that the peritoneum is taken above the ureter to prevent any ureteric injury. In the study by Dargent et al,¹² who used the laparoscopic Davydov approach to harvest the peritoneal graft, there were two ureteric injuries and one vesicovaginal fistula in 28 patients. In our three patients there were no complications because care was taken during surgical dissection.

The retention of blood supply via the uterine arteries is crucial to the success of the graft because it maintains blood supply to the uterine serosa and peritoneum and thus prevents tissue necrosis or breakdown; by contrast, an amnion graft does not have a blood supply and disintegrates as re-epithelialization takes place.¹⁶ The amnion graft is associated with foul smell and risk of infection.

Postoperatively, it is important to use a vaginal stent that is large enough to allow apposition of the uterine serosa-peritoneal graft to the vaginal walls yet not large enough to cause pressure necrosis.⁶ In our series, we used a 1.5-cm silicone stent in the initial 3–4 days postsurgery that is removed before the patient is sent home and replaced with a vaginal dilator to use for 3 months.

In conclusion, Lee's neovaginoplasty method of a combined laparoscopic and vaginal approach of using uterine serosa and peritoneum for the creation of a neovagina is a simple, effective method with good outcome and minimal morbidity to the patient. It avoids the problems associated with graft use from other sites and has good form and function to enable satisfactory intercourse.

References

1. Evans TN, Poland ML, Boving RL. Vaginal malformations. *Am J Obstet Gynecol.* 1981;141:910–920.
2. Frank RT. The formation of an artificial vagina without operation. *Am J Obstet Gynecol.* 1938;35:1053–1055.
3. Williams JK, Lake M, Ingram JM. The bicycle seat stool in the treatment of vaginal agenesis and stenosis. *J Obstet Gynecol Neonatal Nurs.* 1985;14:147–150.
4. Gargollo PC, Cannon Jr GM, Diamond DA, Thomas P, Burke V, Laufer MR. Should progressive perineal dilation be considered first line therapy for vaginal agenesis? *J Urol.* 2009;182:1882–1889.
5. McIndoe A. The treatment of congenital absence and obliterative conditions of the vagina. *Br J Plast Surg.* 1950;2:254.
6. Bastu E, Akhan SE, Mutlu MF, et al. Treatment of vaginal agenesis using a modified McIndoe technique: long-term follow-up of 23 patients and a literature review. *Can J Plast Surg.* 2012;20:241–244.
7. Lee CL, Jain S, Wang CJ, Yen CF, Soong YK. Classification for endoscopic treatment of müllerian anomalies with an obstructive cervix. *J Am Assoc Gynecol Laparosc.* 2001;8:402–408.
8. Darai E, Toullalan O, Besse O, Potiron L, Delga P. Anatomic and functional results of laparoscopic and perineal neovagina construction by sigmoid colpoplasty in women with Rokitansky's syndrome. *Hum Reprod.* 2003;18:2454–2459.
9. Louis-Sylvestre C, Haddad B, Paniel BJ. Creation of a sigmoid neovagina: technique and results in 16 cases. *Eur J Obstet Gynecol Reprod Biol.* 1997;75:225–229.
10. Parsons JK, Gearhart SL, Gearhart JP. Vaginal reconstruction utilizing sigmoid colon: complications and long-term results. *J Pediatr Surg.* 2002;37:629–633.
11. Davydov SN. Colpopoiesis from the peritoneum of the uterorectal space. *Obstet Gynecol.* 1969;12:55.
12. Dargent D, Marchiolè P, Giannesi A, Benchaïb M, Chevret-Méasson M, Mathevet P. Laparoscopic Davydov or laparoscopic transposition of the peritoneal colpopoiesis described by Davydov for the treatment of congenital vaginal agenesis: the technique and its evolution. *Gynecol Obstet Fertil.* 2004;32:1023–1030.
13. Veronikis DK, McClure GB, Nichols DH. The Vecchiotti operation for constructing a neovagina: indications, instrumentation and techniques. *Obstet Gynecol.* 1997;90:301–411.
14. Borruto F, Chasen ST, Chervenak FA, Fedele L. The Vecchiotti procedure for surgical treatment of vaginal agenesis: comparison of laparoscopy and laparotomy. *Int J Gynaecol Obstet.* 1999;64:153–158.
15. Fotopoulou C, Sehouli J, Gehrmann N, Schoenborn I, Lichtenegger W. Functional and anatomic results of amnion vaginoplasty in young women with Mayer-Rokitansky-Kuster-Hauser syndrome (MRKH). *Fertil Steril.* 2010;94:217–322.
16. Soong YK, Lai IM. Amnion graft in treatment of congenital absence of the vagina: report of 3 cases. *Taiwan Yi Xue Hui Za Zhi.* 1987;86:1232–1515.
17. Wu MP, Lee CL. The trends of minimally invasive surgery for benign gynecologic lesions, 1997–2007 in Taiwan. *Gynecol Minim Invasive Ther.* 2012;1:3–8.
18. Jarruwale P, Huang KG, Benavides DR, Su H, Lee CL. Nerve-sparing radical hysterectomy in cervical cancer. *Gynecol Minim Invasive Ther.* 2013;2:42–47.
19. Su H, Huang KG, Yen CF, Ota T, Lee CL. Laparoscopic radical trachelectomy: The choice for conservative surgery in early cervical cancer. *Gynecol Minim Invasive Ther.* 2013;2:39–41.
20. Thepsuwan J, Huang KG, Wilamarta M, Adlan AS, Manvelyan V, Lee CL. Principles of safe abdominal entry in laparoscopic gynecologic surgery. *Gynecol Minim Invasive Ther.* 2013;2:105–109.