



Post-coital vaginal cuff dehiscence with small bowel evisceration after laparoscopic type II radical hysterectomy: A case report



Ilker Kahramanoglu*, Veysel Sal, Tugan Bese (Prof.)

MD, Department of Obstetrics and Gynecology, Division of Gynecologic Oncology, Cerrahpasa Medical Faculty, Istanbul University, Turkey

ARTICLE INFO

Article history:

Received 13 June 2016

Received in revised form 27 June 2016

Accepted 20 July 2016

Available online 25 July 2016

Keywords:

Post-coital

Vaginal cuff dehiscence

Evisceration

ABSTRACT

INTRODUCTION: Vaginal cuff dehiscence after hysterectomy can be life-threatening condition. Vaginal evisceration of bowel may lead to intestinal ischemia and intraabdominal infection. Immediate recognition and surgical repair are crucial for successful management.

CASE REPORT: Herein, we report a case of vaginal cuff dehiscence with small bowel evisceration in a 32-year old woman who underwent laparoscopic type II hysterectomy for stage IA2 cervical cancer.

CONCLUSION: Patients who have undergone hysterectomy should be advised about when to restart coitus. Vaginal repair of vaginal cuff dehiscence is recommended if intestinal ischemia is excluded.

© 2016 The Author(s). Published by Elsevier Ltd on behalf of IJS Publishing Group Ltd. This is an open access article under the CC BY-NC-ND license (<http://creativecommons.org/licenses/by-nc-nd/4.0/>).

1. Introduction

A rare complication of total hysterectomy, vaginal cuff dehiscence (VCD), can be a life-threatening development, especially when bowel evisceration is present, as this may lead to intestinal ischaemia and intraabdominal infection. The probability of having evisceration of any intraperitoneal content is 67% [1]. When there are complaints of pelvic/abdominal pain or watery discharge after hysterectomy, VCD should be considered and diagnosed and managed promptly. The timing of diagnosis of VCD has been reported to be 5 days to 30 years after surgery, with a mean time of 6.1 weeks–1.6 years for open, laparoscopic and robotic hysterectomies [2,3].

More than 150 laparoscopic hysterectomies were performed for gynaecologic oncology purposes in our clinic in the last 5 years. Herein, we describe the first case of VCD with small bowel evisceration following laparoscopic type 2 hysterectomy for cervical cancer.

2. Case report

A 32-year-old woman with a diagnosis of Stage IA2, Grade 2 squamous cervical cancer underwent a laparoscopic type 2 radical hysterectomy and pelvic lymph node dissection. During hysterectomy, the anterior and posterior colpotomies were performed on the rim of the cup fitting into the cervix with a unipolar hook, and the vaginal cuff was closed with two interrupted, figure 8 sutures

(No. 1 polyglactin 910). The operation lasted in almost 3 h. The patient's postoperative findings were unremarkable, and she did not require adjuvant chemo- or radiotherapy. Her body mass index was 29.3 kg/m². She had no significant medical or family history, and she was an active smoker.

On postoperative day 45, the patient presented to our emergency department with complaints of pelvic and vaginal pain and watery and bloody vaginal discharge after intercourse. On examination, a 2 cm midline vaginal cuff defect with small bowel evisceration was seen (Fig. 1). Computed tomography (CT) of the abdomen findings were within normal limits. The cuff was repaired with interrupted No. 2-0 monofilament synthetic absorbable suture (Fig. 2). Follow up at 3 months after the second surgery showed no remarkable findings, and the well-healed vaginal cuff was palpated.

3. Discussion

The reported incidence of VCD after hysterectomy is only 0.032% [4]. Compared to abdominal or vaginal hysterectomy, laparoscopy involves a threefold higher risk of VCD [5]. If bowel evisceration is present, the mortality rate can rise to 5.6% [6].

The mode of colpotomy may have an impact on VCD. Electro-surgery has destructive effects and cause thermal tissue damage. The depth of coagulation and destruction may not be always predictable. A recent in vitro study evaluating the effect of electrode size on the depth of coagulation showed that use of a sharp point electrode is associated with more superficial coagulation [7]. As in our clinic, electrocautery is commonly used for colpotomy during laparoscopic hysterectomy, which may lead to poor blood supply to the wound [8]. The cutting mode has been thought to cause less harm than the coagulation mode; however, both can be used during colpotomy if more bleeding than expected occurs. In our case, the

* Corresponding author at: Cerrahpasa Medical Faculty, Department of Obstetrics and Gynecology, Division of Gynecologic Oncology, Fatih, Istanbul, Turkey.
E-mail address: ilkerkahramanoglu@hotmail.com (I. Kahramanoglu).

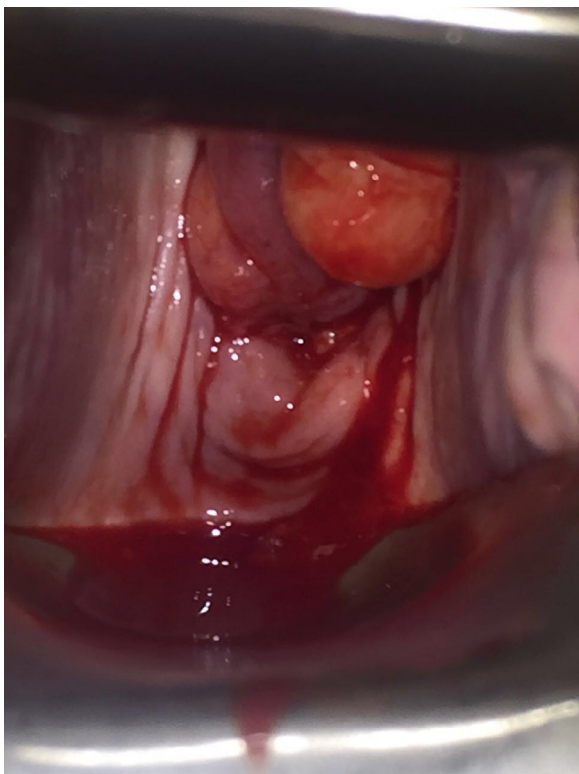


Fig. 1. Post-coital VCD in 2 cm diameter with small bowel evisceration.

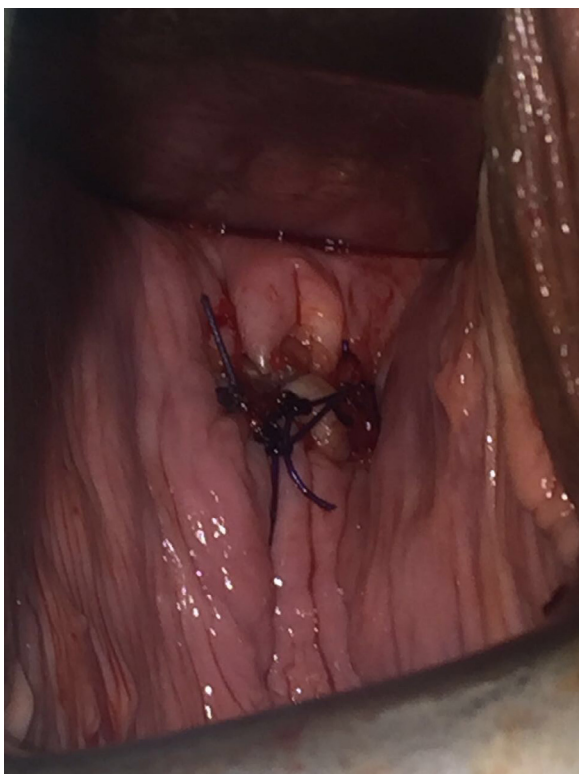

Fig. 2. Shortly after repair of VCD with interrupted No. 2-0 monofilament synthetic absorbable suture.

LigaSure vessel sealing system was ultimately used to cut paracervical ligaments. Subsequently, only a unipolar hook was used to cut the vaginal cuff in both the cutting and coagulation modes. In addition to the common use of electrocautery laparoscopic colpotomy, the magnification view may also cause suture bites to be smaller than desired [9].

The method of vaginal cuff closure can be another surgical risk factor for VCD after laparoscopic hysterectomy. While a cohort study demonstrated a VCD risk of 0.86% with endoscopic closure and 0.24% with transvaginal closure, another study from the Netherlands showed that neither the single-layer laparoscopic closure with an unknotted running suture nor the transvaginal and laparoscopic interrupted suturing techniques was superior [5,10]. However, another study evaluating 550 laparoscopic hysterectomies performed by two gynecologic oncologists found that closure of the vaginal cuff using the unidirectional barbed suture is associated with 74% less chance to develop vaginal cuff dehiscence compared to closure using interrupted Polyglactin suture (5.9% vs 1.5%, $p=0.01$) [11]. In this patient, an interrupted figure 8 vaginal cuff closure was performed using polyglactin 910 suture material.

Sexual intercourse alone is an important precipitating factor, particularly for premenopausal women [12]. As in our patient, VCD has been typically associated with coitus prior to wound healing, especially when it is considered that most cases occur in the first 3 months. There is no evidence-based recommendation regarding the time to restart coitus. At our clinic, patients who undergo open or laparoscopic hysterectomy for a gynaecological cancer are asked to avoid coitus for at least 8 weeks. However, our patient started coitus 6 weeks after surgery, and VCD occurred following the first coitus after operation.

Intraoperative and postoperative infection, hematoma formation, tobacco use, chronic steroid use, diabetes mellitus, malnutrition, a history of radiation and chronic constipation are other risk factors associated with the development of VCD [13,14]. In our patient, beyond malignancy itself as an aetiological factor, continued smoking after oncological surgery may have predisposed the patient to VCD after coitus.

If there is an evisceration of the intestine, injury from direct trauma to the exposed segment or through ischaemia secondary to tears in the small bowel mesentery or restriction with subsequent strangulation may occur [15]. Historically, immediate laparotomy was strongly recommended, and there was no role for transvaginal repair. Since cases with a successful vaginal approach have now been reported, transvaginal repair of VCD is commonly used if the eviscerated intestine looks well vascularised [15]. In our case, the ileum segment looked normal, and CT findings showed no evidence of ischaemia.

In conclusion, it should be suggested that patients restart coitus at least 8–12 weeks after gynaecologic oncologic surgery. VCD should be kept in mind as a complication after hysterectomy. If VCD is present, bowel evisceration should be ruled out or managed promptly. Vaginal repair is recommended if intestinal ischemia is excluded.

Conflict of interest

None.

Funding

None.

Ethical approval

Case report did not require ethical approval. Written consent form was obtained from patient.

Consent

Written consent form was obtained from patient.

Author contributions

I.K.: Primary surgeon of the second operation, literature search, materials, data collection, writing the paper, assistant surgeon of first operation.

V.S.: Data collection, assistant surgeon of first operation.

Guarantor

Ilker KAHRAMANOGLU.

Acknowledgements

None.

References

- [1] M. Ceccaroni, R. Berretta, M. Malzoni, M. Scioscia, G. Roviglione, E. Spagnolo, et al., Vaginal cuff dehiscence after hysterectomy: a multicenter retrospective study, *Eur. J. Obstet. Gynecol. Reprod. Biol.* 158 (2011) 308–313.
- [2] R.J. Cardosi, M.S. Hoffman, W.S. Roberts, W.N. Spellacy, Vaginal evisceration after hysterectomy in premenopausal women, *Obstet. Gynecol.* 94 (5) (1999) 859.
- [3] M.D. Moen, M. Desai, R. Sulkowski, Vaginal evisceration managed by transvaginal bowel resection and vaginal repair, *Int. Urogynecol. J.* 14 (3) (2003) 218–220.
- [4] A.J. Croak, J.B. Gebhart, C.J. Klingele, G. Schroeder, R.A. Lee, Podratz KC characteristics of patients with vaginal rupture and evisceration, *Obstet. Gynecol.* 103 (2004) 572–576.
- [5] S. Uccella, M. Ceccaroni, A. Cromi, M. Malzoni, R. Berretta, P. De Iaco, et al., Vaginal cuff dehiscence in a series of 12,398 hysterectomies: effect of different types of colpotomy and vaginal closure, *Obstet. Gynecol.* 120 (3) (2012) 516–523.
- [6] R.S. Parra, J.J. Rocha, O. Feres, Spontaneous transvaginal small bowel evisceration: a case report, *Clinics* 65 (5) (2010) 559–561.
- [7] A. Taheri, P. Mansoori, N. Bahrami, H. Alinia, C.E. Watkins, S.R. Feldman, How frequency of electrosurgical current and electrode size affect the depth of electrocoagulation, *Dermatol. Surg.* 42 (February (2)) (2016) 197–202.
- [8] P.A. Escobar, G.M. Gressel, G.L. Goldberg, D.Y. Kuo, Delayed presentation of vaginal cuff dehiscence after robotic hysterectomy for gynecologic cancer: a case series and review of the literature, *Case Rep. Obstet. Gynecol.* 2016 (2016) 5296536.
- [9] I.I.R. Cattaneo, M. Bellon, M.A. Elshaikh, Vaginal cuff dehiscence after vaginal cuff brachytherapy for uterine cancer. A case report, *J. Contemp. Brachytherapy* 5 (3) (2013) 164–166.
- [10] M.D. Blikkendaal, A.R.H. Twijnstra, S.C.L. Pacquee, J.P. Rhemrev, M.J. Smeets, C.D. de Kroon, et al., Vaginal cuff dehiscence in laparoscopic hysterectomy: influence of various suturing methods of the vaginal vault, *Gynecol. Surg.* 9 (2012) 393–400.
- [11] S.S. Fenske, E. Soto, N. Astill, V. Kolev, K. Friedman, E. Moshier, et al., Comparison of the incidence of vaginal cuff dehiscence with laparoscopic continuous unidirectional barbed suture closure versus interrupted polyglactin closure, *J. Minim. Invasive Gynecol.* 20 (6) (2013) 49.
- [12] B.L. Robinson, J.B. Liao, S.F. Adams, T.C. Randall, Vaginal cuff dehiscence after robotic total laparoscopic hysterectomy, *Obstet. Gynecol.* 114 (2) (2009) 369–3671.
- [13] P.T. Ramirez, D.P. Klemer, Vaginal evisceration after hysterectomy: a literature review, *Obstet. Gynecol. Surv.* 57 (7) (2002) 462–467.
- [14] E. Wiebe, A. Covens, G. Thomas, Vaginal vault dehiscence and increased use of vaginal vault brachytherapy: what are the implications? *Int. J. Gynecol. Cancer* 22 (9) (2012) 1611–1616.
- [15] C.A. Matthews, K. Kenton, Treatment of vaginal cuff evisceration, *Obstet. Gynecol.* 124 (2014) 705–708.

Open Access

This article is published Open Access at sciedirect.com. It is distributed under the [IJSCR Supplemental terms and conditions](#), which permits unrestricted non commercial use, distribution, and reproduction in any medium, provided the original authors and source are credited.