

# Expression of Interferon-Gamma Receptors in Normal and Psoriatic Skin

Annika Scheynius, Jessica Fransson, Catharina Johansson, Hans Hammar, Barbara Baker, Lionel Fry, and Helgi Valdimarsson

Departments of Clinical Immunology (AS, CJ) and Dermatology (JF, HH), Karolinska Hospital, Stockholm, Sweden; Department of Dermatology, St. Mary's Hospital (BB, LF), London, U.K.; and Department of Immunology, Landspítalinn (HV), Reykjavik, Iceland

Psoriatic keratinocytes have a reduced antiproliferative response to interferon (IFN)-gamma, and HLA-DR expression is usually not observed on keratinocytes in psoriatic plaques despite the presence of activated T cells. We have therefore compared the expression of IFN-gamma receptors in psoriatic skin with that of normal human skin. Using mouse monoclonal antibodies and immunoperoxidase staining on cryostat cut sections, we detected IFN-gamma receptors on keratinocytes throughout the epidermal layers except stratum corneum in normal skin (n = 11). Biopsy specimens from involved psoriatic skin (n = 17) consistently showed a staining pattern that differed from that of normal skin in that only the lower part of epidermis reacted with the antibodies to IFN-

gamma receptors, whereas the upper layers showed no or minimal staining. Expression of IFN-gamma receptors in uninvolved psoriatic skin (n = 16) did not differ from that of healthy controls. Forty-five percent of the biopsies from lesional psoriatic skin displayed ICAM-1 positive keratinocytes, and only two specimens had a limited expression of HLA-DR reactive keratinocytes. The decreased binding of antibodies against the IFN-gamma receptors in the upper part of psoriatic epidermis might be secondary to abnormal maturation of psoriatic keratinocytes or a primary defect involving abnormal modulation of IFN-gamma receptors. *J Invest Dermatol* 98:255-258, 1992

It has been suggested that psoriatic keratinocytes have an abnormal response to interferon (IFN)-gamma because HLA-DR expression by keratinocytes is seen infrequently or not at all in psoriatic plaques despite the presence of T cells [1]. It has also been reported that IFN-gamma has a reduced antiproliferative effect on psoriatic keratinocytes [2,3], and this could contribute to the increased epidermal cell proliferation that characterizes the disease.

The mechanisms whereby IFN-gamma induces the synthesis and expression of new cell-surface molecules like MHC class II antigens on keratinocytes [4-6] and of the intercellular adhesion molecule-1 (ICAM-1, CD54) [7] are still largely unknown, although evidence for involvement of protein kinase C signal transduction has been reported [8]. Cell-surface receptors for IFN-gamma ought to be a prerequisite for its biologic effects and binding of IFN-gamma to cultured human keratinocytes has previously been shown [9]. Recently a receptor for IFN-gamma was identified, different from that

shared by interferon-alpha and -beta (reviewed in [10]). The gene for the human IFN-gamma receptor is localized to the long arm of chromosome 6 [11,12] and the receptor, a glycoprotein, has an approximate molecular mass of 90 kDa [13,14].

In the present study we have investigated the expression of receptors for IFN-gamma in biopsy specimens from involved and uninvolved skin from patients with psoriasis and compared with that of normal human skin.

## MATERIALS AND METHODS

**Skin Biopsies** Normal skin biopsies (3 mm in diameter) from 11 healthy volunteers were obtained under local anesthesia. Nineteen patients with psoriasis (seven female and 12 male, ages 19-63 years) participated in the study (Table I). Fourteen patients had chronic plaque psoriasis, three had guttate psoriasis, and two had histories of guttate psoriasis. The patients were not on any treatment except for two (patients 16 and 17) who were on topical steroids although the biopsied lesions had not been treated. Biopsy specimens (3-4 mm in diameter) were obtained under local anesthesia from both involved and uninvolved skin at least 5 cm from a lesion (Table I). The specimens were snap frozen and stored at -70°C. Informed consent was obtained from each patient and the study was approved by the Ethics Committees of the Karolinska Institute, Stockholm, and of St. Mary's Hospital, London.

**Raji Cells** Raji cells, a continuous human Burkitt lymphoma cell line, obtained from the Department of Tumour Biology, Karolinska Institute, Stockholm, were grown in RPMI 1640 medium (Kebo AB, Spånga, Sweden) supplemented with 8% heat-inactivated fetal calf serum (FCS) and antibiotics. This cell line, known to contain high amounts of IFN-gamma receptors [15], was used for titrating the antibodies against the IFN-gamma receptor by the immunoperoxidase staining method and then included as a positive control. The cells were washed and suspended in phosphate-buf-

Manuscript received July 23, 1991; accepted for publication August 28, 1991.

This work was supported by grants from the Swedish Medical Research Council (projects 16X-7924 and 12X-5665), the Swedish Work Environment Fund, the Karolinska Institute, the King Gustaf V Foundation, and the Edvard Welander Foundation.

Presented partly in abstract form at the European Federation of Immunological Societies Meeting in Edinburgh, U.K., September 10-12, 1990.

Reprint requests to: Dr. Annika Scheynius, Department of Clinical Immunology, Karolinska Hospital, S-104 01 Stockholm, Sweden.

### Abbreviations:

- CD: cluster determinants
- EGF: epidermal growth factor
- ICAM: intercellular adhesion molecule
- IFN: interferon
- LDL: low-density lipoprotein (LDL)
- MoAb: monoclonal antibody (-ies)

**Table I.** Patient Data and Immunoperoxidase Findings in Skin Biopsy Specimens

Number	Patient			Dermal Cell Infiltrate <sup>a</sup>	Epidermal Expression (involved/uninvolved skin)		
	Sex	Age	Type <sup>d</sup>		IFN-Gamma Receptor <sup>b</sup>	ICAM-1 <sup>c</sup>	HLA-DR <sup>e</sup>
1	♂	22	Psc	++/-	1/3	-/-	-/-
2	♂	35	Psc	++/NP <sup>e</sup>	1/NP	-/NP	-/NP
3	♀	45	Psc	++/NP	2/NP	+K/NP	+K/NP
4	♀	46	Psc	++/-	2/3	+K/-	-/-
5	♂	61	Psc	++/-	1/3	+K/-	-/-
6	♂	46	Psc	++/-	1/3	-/-	-/-
7	♀	40	Psc	++/-	2/3	-/-	-/-
8	♂	63	Psc	+/-	2/3	+K/-	+K/-
9	♂	27	Psc	+/-	2/3	-/-	-/-
10	♂	25	Psc	++/-	2/3	-/-	-/-
11	♂	36	Psc	++/-	1/3	-/-	-/-
12	♂	43	Psc	++/-	1/3	+K/-	-/-
13	♂	36	Psc	++/-	1/3	-/-	-/-
14	♀	23	Psc	+/-	1/3	-/-	-/-
15	♀	57	Psg	++/+	2/3	+K/+K	-/-
16	♂	36	Psg	++/NP	1/NP	+K/NP	-/NP
17	♀	30	Psg	+/-	2/3	+K/-	-/-
18	♂	19	hPsg	NP/-	NP/3	NP/-	NP/-
19	♀	29	hPsg	NP/-	NP/3	NP/-	NP/-

<sup>a</sup> Estimated on H&E stained sections and graded as -, normal looking skin; +, small and ++, moderate dermal cell infiltrates.

<sup>b</sup> Expression was graded as 1, positive staining restricted to the lower and the middle part of epidermis; 2, positive staining in the lower part and weak staining in the upper part of stratum spinosum and above; 3, positive staining throughout the whole epidermis except stratum corneum.

<sup>c</sup> +K, reactivity on keratinocytes; -, no reactivity on keratinocytes.

<sup>d</sup> Psc, chronic plaque psoriasis; Psg, guttate psoriasis; hPsg, history of guttate psoriasis.

<sup>e</sup> NP, not present, material not available.

ferred saline (PBS). Twenty microliters of the cell suspension ( $10^6$ /ml) was placed on each well of multiwell microscope glass slides (Nova Kemi, Stockholm, Sweden), air-dried, and stored at  $-70^\circ\text{C}$  until stained [16]. Raji cells cultured in the presence of INF-gamma (500 U/ml of *Escherichia coli*-derived recombinant human INF-gamma, a generous gift from Dr. P van der Meide, TNO Primate Center, Rijswijk, The Netherlands) showed substantially decreased expression of INF-gamma receptors after 60 min of culture.

**Immunohistochemical Staining** Frozen sections, 6  $\mu\text{m}$  thick, were fixed in acetone for 5 min at  $4^\circ\text{C}$  and stained by the peroxidase-antiperoxidase method [17]. Endogenous peroxidase was blocked by incubation in 0.3%  $\text{H}_2\text{O}_2$  in PBS for 15 min, and the sections were then allowed to react with normal rabbit serum (diluted 1/10) for 10 min to reduce non-specific staining. Mouse monoclonal antibodies (MoAb) against the human INF-gamma receptor was a generous gift from Dr. M. Aguet, Institute for Immunology and Virology, Zurich, Switzerland. A combination of two antibodies was used: A6C5 (IgG<sub>1</sub>, diluted 1/200), which competes with receptor binding of human INF-gamma and neutralizes its biologic activity [15]; and 4D7A12 (IgG<sub>2b</sub>, diluted 1/200), which competes weakly with receptor binding and produces a marked additive signal when used together with MoAb A6C5 for indirect immunofluorescence.\* As this combination gave the best staining result on Raji cells as well as on normal and psoriatic skin, it was used throughout the study. During this study we observed the necessity of proper cold storage of cryostat sections. Thus, sections from eight skin biopsy specimens from four patients with psoriasis (involved and uninvolved skin) and five from healthy volunteers that had been stored at  $-20^\circ\text{C}$  for 8–12 months reacted very poorly with the INF-gamma receptor MoAb (data not shown). However, sections of normal skin that had been stored at  $-70^\circ\text{C}$  for up to 4 years showed a strong staining. The results presented in this study are obtained on biopsy specimens from psoriatic patients stored at  $-70^\circ\text{C}$  for less than 6 weeks.

The other MoAb used were the anti-ICAM-1 antibody (84H10, IgG<sub>1</sub>) obtained from Serotec, Oxford, England, diluted 1/80

(2.5  $\mu\text{g}/\text{ml}$ ), and the anti-HLA-DR antibody (L243, IgG<sub>2a</sub>) from Becton Dickinson and Co., Oxnard, CA, diluted 1/128 (0.2  $\mu\text{g}/\text{ml}$ ). Rabbit anti-mouse immunoglobulin (diluted 1/40) used as a secondary antibody and pre-formed complexes of horseradish peroxidase and mouse monoclonal anti-horseradish peroxidase were obtained from Dakopatts, Copenhagen, Denmark. The peroxidase reaction was developed with 3-amino-9-ethylcarbazole [18], and the sections were counterstained with Mayer's hematoxylin. Controls without the primary antibodies or with irrelevant mouse MoAb gave no staining.

**Histologic Evaluation** Each biopsy specimen was also processed for hematoxylin and eosin staining for histologic evaluation and estimation of dermal cell infiltrates. Slides were read by one investigator (HH) under coded conditions and examined for acanthosis, epidermal granulosis, parakeratosis, tortuous papillary capillaries, and Munro's microabscess.

## RESULTS

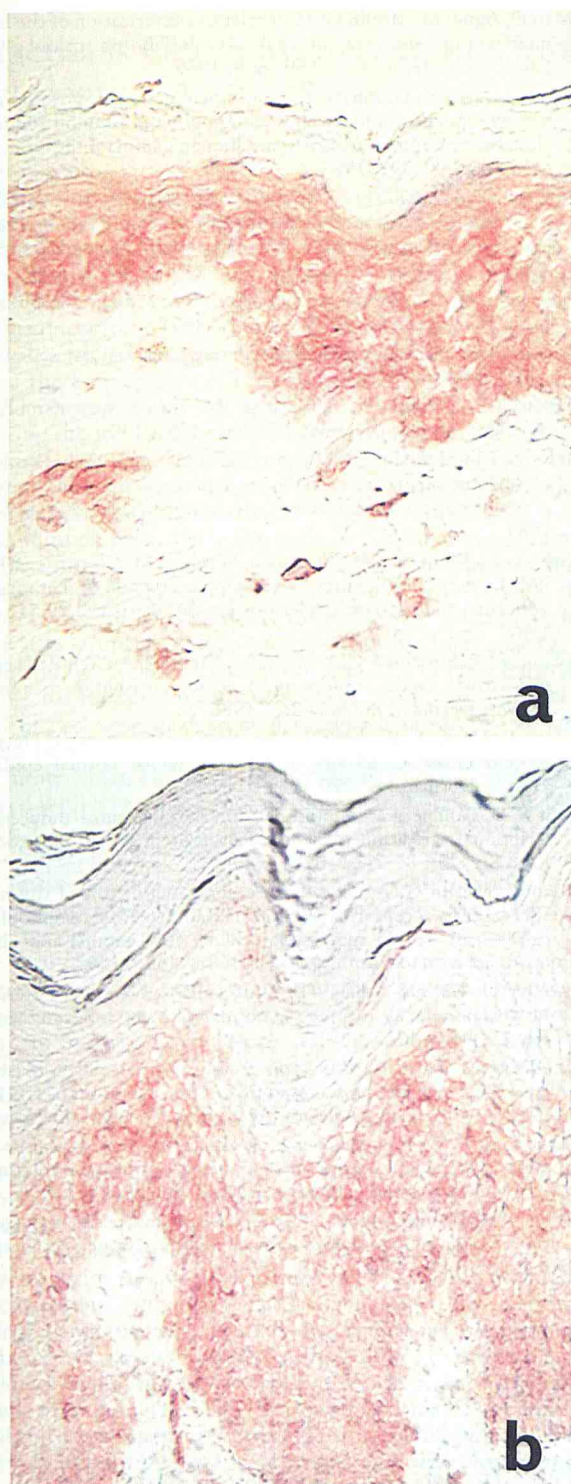
**Skin Biopsies from Normal Skin** Normal skin from 11 donors consistently bound the antibodies against the human INF-gamma receptor as seen in Fig 1a. There was an even cytoplasmic staining throughout the epidermis except stratum corneum with somewhat stronger staining of the cell membranes. Occasional dendritic epidermal cells were observed with more intense staining. Endothelial cells and a few cells in the dermis were also positive (Fig 1a).

**Skin Biopsies from Patients with Psoriasis** The 17 biopsy specimens obtained from involved psoriatic skin fulfilled the histologic criteria for psoriasis. Munro's microabscesses were present in all but three of these biopsies. There were small to moderate dermal cell infiltrates in lesional skin and also in one biopsy of uninvolved skin from a patient with guttate psoriasis (Table I).

All biopsy specimens from involved psoriatic skin displayed positive staining for INF-gamma receptors but in contrast to normal skin this was largely confined to the lower part of the epidermis (Fig 1b). Thus, the upper part of the stratum spinosum and above was negative or showed a very weak reactivity with the MoAb against the INF-gamma receptors (Table I, Fig 1b). There was no difference between chronic plaque and guttate psoriasis (Table I) and there was

\* Dr. M. Aguet (personal communication).





**Figure 1.** Expression of IFN-gamma receptors in skin biopsy specimens from (a) normal skin and (b) a patient with chronic plaque psoriasis (patient 15). Acetone-fixed cryostat sections were processed for immunoperoxidase staining and counterstained with Mayer's hematoxylin. Magnification  $\times 370$  (a) and  $\times 150$  (b).

no relationship between the number of Munro's microabscesses and the degree of IFN-gamma receptor expression. Expression of IFN-gamma receptors in uninvolved skin did not differ from that of healthy controls.

ICAM-1 and HLA-DR reactivity was not detected on keratinocytes in biopsies from uninvolved skin from patients with psoriasis

with the single exception that ICAM-1 positive keratinocytes were found in one patient with guttate psoriasis, who also had small dermal cell infiltrates (Table I, patient 15). Keratinocytes in eight of the 17 biopsies from involved psoriatic skin (three from guttate psoriasis) expressed ICAM-1. In two of these, both from chronic plaque lesions, keratinocytes also expressed HLA-DR antigens (patients 3 and 8). This staining was confined to small groups of keratinocytes found both in the basal and in the upper part of epidermis.

#### DISCUSSION

In this study IFN-gamma receptors were found to be expressed by keratinocytes throughout the epidermal layers except stratum corneum in normal skin and also by endothelial cells and a few dermal cells. This expression probably reflects potential reactivity of keratinocytes to locally produced IFN-gamma during inflammatory reactions in the skin. Nickoloff has reported that iodinated ( $^{125}$ I) recombinant IFN-gamma binds to cultured human keratinocytes and estimated about 2,000 binding sites per keratinocyte [9]. Most cell types express IFN-gamma receptors and their estimated numbers have ranged from 1,000 to 10,000 per cell, the higher numbers being found on tumor cells [10]. However, some tumor cells lack IFN-gamma receptors like lymphoid cells from patients with chronic lymphatic leukemia or hairy cell leukemia [10].

Biopsy specimens from involved psoriatic skin, chronic plaque, or guttate showed a consistent staining pattern for IFN-gamma receptors, which was different from that of normal skin. Thus, the lower part of epidermis bound the antibodies to IFN-gamma receptors to the same extent as normal epidermis, but no or minimal staining was observed in the upper lesional epidermis. This might reflect an abnormal modulation of IFN-gamma receptors or be a secondary effect due to defective maturation of psoriatic keratinocytes. These are possibilities that are currently being studied. Abnormal maturation of keratinocytes, which is a feature of this disease, and several alterations to the cell surface of psoriatic keratinocytes have been reported (reviewed in [19]). In psoriasis, different receptor systems may be diversely affected. Decrease of the  $\beta$ -adrenergic receptor has been reported [20]. In normal human skin, the receptors for low-density lipoprotein (LDL) and epidermal growth factor (EGF) are expressed mainly in the basal layer(s) and disappear during differentiation, whereas in psoriatic lesions the LDL-receptors are abundant in stratum spinosum [21] and the EGF-receptor is expressed throughout all epidermal layers [22]. Furthermore and in contrast to the IFN-gamma receptor we have recently demonstrated that the  $\beta$ -chain (p75) of the interleukin-2 receptor that is strongly expressed throughout normal epidermis can only be detected in the upper keratinocyte layers of lesional psoriatic skin.† The significance of these findings is not known. Another difference between normal and psoriatic skin is decreased protein kinase C activity in psoriatic epidermis [23]. This is of interest because IFN-gamma-induced transcriptional activation is mediated by protein kinase C [24] and phorbol myristate acetate, a potent activator of protein kinase C, can induce an increase of IFN-gamma receptor expression in a monocytic cell line low in IFN-gamma receptor expression [25].

In agreement with previous observations [1] only two of our 17 psoriatic specimens showed limited HLA-DR expression by keratinocytes. In contrast, eight (45%) of the lesional biopsies displayed ICAM-1-positive keratinocytes. An increased expression of ICAM-1 over HLA-DR in involved psoriatic skin has been reported in a previous study [7] and ICAM-1 can occasionally be seen on keratinocytes in normal skin [26,27]. Whereas HLA-DR expression is mainly induced by IFN-gamma, expression of ICAM-1 can also be induced on keratinocytes by tumor necrosis factor  $\alpha$  and  $\beta$  ([28]; reviewed in [29]).

In conclusion, the present study shows a decreased binding of MoAb against the IFN-gamma receptor in the upper part of psoriatic epidermis. This might reflect a primary defect of the keratino-

† Dr. B. Baker et al (manuscript in preparation).

cytes involving abnormal modulation of the receptors or a secondary effect associated with defective maturation of psoriatic keratinocytes.

## REFERENCES

1. Terui T, Aiba S, Kato T, Tanaka T, Tagami H: HLA-DR antigen expression on keratinocytes in highly inflamed parts of psoriatic lesions. *Br J Dermatol* 116:87-93, 1987
2. Baker BS, Powles AV, Valdimarsson H, Fry L: An altered response by psoriatic keratinocytes to gamma interferon. *Scand J Immunol* 28:735-740, 1988
3. Nickoloff BJ, Mitra RS, Elder JT, Fisher GJ, Voorhees JJ: Decreased growth inhibition by recombinant gamma interferon is associated with increased transforming growth factor- $\alpha$  production in keratinocytes cultured from psoriatic lesions. *Br J Dermatol* 121:161-174, 1989
4. Basham TY, Nickoloff BJ, Merigan TC, Morhenn VB: Recombinant gamma interferon differently regulates class II antigen expression and biosynthesis on cultured normal human keratinocytes. *J Interferon Res* 5:23-32, 1985
5. Nilsson H, Johansson C, Sandberg K, Funa K, Alm GV, Scheynius A: Induction of mRNA for HLA-DR $\beta$  in human keratinocytes cocultured with interferon-gamma. *Arch Dermatol Res* 281:260-266, 1989
6. Scheynius A, Johansson C, van der Meide PH: *In vivo* induction of Ia antigens on rat keratinocytes by gamma-interferon. *Br J Dermatol* 115:543-549, 1986
7. Griffiths CEM, Voorhees JJ, Nickoloff BJ: Characterization of intercellular adhesion molecule-1 and HLA-DR expression in normal and inflamed skin: modulation by recombinant gamma interferon and tumor necrosis factor. *J Am Acad Dermatol* 20:617-629, 1989
8. Griffiths CEM, Esmann J, Fisher GJ, Voorhees JJ, Nickoloff BJ: Differential modulation of keratinocyte intercellular adhesion molecule-1 expression by gamma interferon and phorbol ester: evidence for involvement of protein kinase C signal transduction. *Br J Dermatol* 122:333-342, 1990
9. Nickoloff BJ: Binding of  $^{125}\text{I}$ -gamma interferon to cultured human keratinocytes. *J Invest Dermatol* 89:132-135, 1987
10. Celada A: The interferon gamma receptor. *Lymphokine Res* 7:61-73, 1988
11. Rashidbaigi A, Langer JA, Jung V, Jones C, Morse HG, Tischfield JA, Trill JJ, Kung H-F, Pestka S: The gene for the human interferon receptor is located on chromosome 6. *Proc Natl Acad Sci USA* 83:384-388, 1986
12. Aguet M, Dembic Z, Merlin G: Molecular cloning and expression of the human interferon-gamma receptor. *Cell* Vol 55:273-280, 1988
13. Calderon J, Sheehan KCF, Chance C, Thomas ML, Schreiber RD: Purification and characterization of the human interferon-gamma receptor from placenta. *Proc Natl Acad Sci USA* 85:4837-4841, 1988
14. Mao C, Aguet M, Merlin G: Molecular characterization of the human interferon-gamma receptor: analysis of polymorphism and glycosylation. *J Interferon Res* 9:659-669, 1989
15. Aguet M, Merlin G: Purification of human gamma interferon receptors by sequential affinity chromatography on immobilized monoclonal antireceptor antibodies and human gamma interferon. *J Exp Med* 165:988-999, 1987
16. Karlsson-Parra A, Forsum U, Klareskog L, Sjöberg O: A simple immunoenzyme batch staining method for the enumeration of peripheral human T lymphocyte subsets. *J Immunol Methods* 64:85-90, 1983
17. Sternberger LA: Immunocytochemistry. Wiley Medical Publications, John Wiley & Sons, Inc., New York, 1979
18. Kaplow LS: Substitute for benzidine in myeloperoxidase stains. *Am J Clin Pathol* 63:451, 1975
19. DiCicco LM, Fraki JE, Mansbridge JN: The plasma membrane in psoriasis. *Internat J Dermatol* 26:631-638, 1987
20. Itami S, Kino J, Halprin KM, Adachi K: Immunohistochemical study of  $\beta$ -adrenergic receptors in the psoriatic epidermis using an anti- $\alpha$ -prenolol anti-idiotypic antibody. *Arch Dermatol Res* 279:439-443, 1987
21. Mommaas-Kienhuis AM, Grayson S, Wijsman MC, Vermeer BJ, Elias PM: Low density lipoprotein receptor expression on keratinocytes in normal and psoriatic epidermis. *J Invest Dermatol* 89:513-517, 1987
22. Nanney LB, Stoscheck CM, Magid M, King LE: Altered ( $^{125}\text{I}$ ) epidermal growth factor binding and receptor distribution in psoriasis. *J Invest Dermatol* 86:260-265, 1986
23. Horn F, Marks F, Fischer GJ, Marcelo CL, Voorhees JJ: Decreased protein kinase C activity in psoriatic versus normal epidermis. *J Invest Dermatol* 88:220-222, 1987
24. Fan X-D, Goldberg M, Bloom BR: Interferon-gamma-induced transcriptional activation is mediated by protein kinase C. *Proc Natl Acad Sci USA* 85:5122-5125, 1988
25. Mao C, Merlin G, Aguet M: Differential regulation of the human IFN-gamma receptor expression in Raji and IM9 lymphoblastoid cells versus THP-1 monocytic cells by IFN-gamma and phorbol myristate acetate. *J Immunol* 144:4688-4696, 1990
26. Konter U, Kellner I, Klein E, Kaufmann R, Mielke V, Sterry W: Adhesion molecule mapping in normal human skin. *Arch Dermatol Res* 281:454-462, 1989
27. Lindberg M, Färm G, Scheynius A: Differential effects of sodium lauryl sulphate and non-anoic acid on the expression of CD1a and ICAM-1 in human epidermis. *Acta Derm Venereol* (in press)
28. Krutmann J, Köck A, Schauer E, et al: Tumor necrosis factor  $\beta$  and ultraviolet radiation are potent regulators of human keratinocyte ICAM-1 expression. *J Invest Dermatol* 95:127-131, 1990
29. Norris DA: Cytokine modulation of adhesion molecules in the regulation of immunologic cytotoxicity of epidermal targets. *J Invest Dermatol* 95:111S-120S, 1990