

# Management of Epiphrenic Esophageal Diverticula

Mitchell J. Magee, MD, MS, FACS,\* and Joshua R. Sonett, MD, FACS†

Epiphrenic esophageal diverticula (EED) are relatively rare and accordingly both the pathophysiology associated with their development and the recommended treatment are not well defined, lacking consensus. EED are pulsion “false” diverticula, consisting of outpouchings of esophageal mucosa through the longitudinal muscle layer of the esophagus. As with Zenker’s diverticula of the proximal esophagus, EED are believed to develop secondary to pressurization of the esophagus. Essential to this pathophysiology is an underlying distal esophageal neuromuscular disorder. Symptoms are lacking with many EED, but when present are usually due to the underlying motility disorder. Patients selected to undergo surgical treatment should be symptomatic and the corrective surgery must primarily address the distal esophageal motility disorder, and the diverticulum secondarily.

EED are usually diagnosed with a barium swallow and all patients undergo preoperative flexible esophagogastroduodenoscopy to rule out other important mucosal abnormalities. We do not routinely obtain esophageal manometry or ambulatory pH monitoring, as the results usually do not influence the planned procedure. A clear liquid diet is prescribed for at least 48 hours preoperatively.

The fundamental components of the operative procedure include the following: 1) wide mobilization of the distal esophagus with careful preservation of the vagi; 2) complete circumferential dissection followed by stapled resection of the diverticulum; 3) closure of the split longitudinal muscle over the mucosal resection staple line; 4) a distal myotomy; and 5) a partial fundoplication. These can all be performed effectively through a thoracotomy, a laparotomy, a thoracoscopic, or a laparoscopic approach; occasionally a combination of approaches is needed. Currently our preferred initial approach is laparoscopic, with a low threshold to use additional thoracic techniques if the diverticulum is broad based and more proximally located. There are no absolute contraindications to initially approach a true epiphrenic diverticulum laparoscopically, as our experience with minimally invasive esophagectomy has shown that the esophagus can be mobilized easily through the hiatus to the level of the tracheal carina. Diverticula greater than 4 cm can be more challenging to dissect completely at the cephalad extent. Thus, diverticula less than 4 cm across the base and closer to the esophageal hiatus are ideally suited to the laparoscopic approach.

---

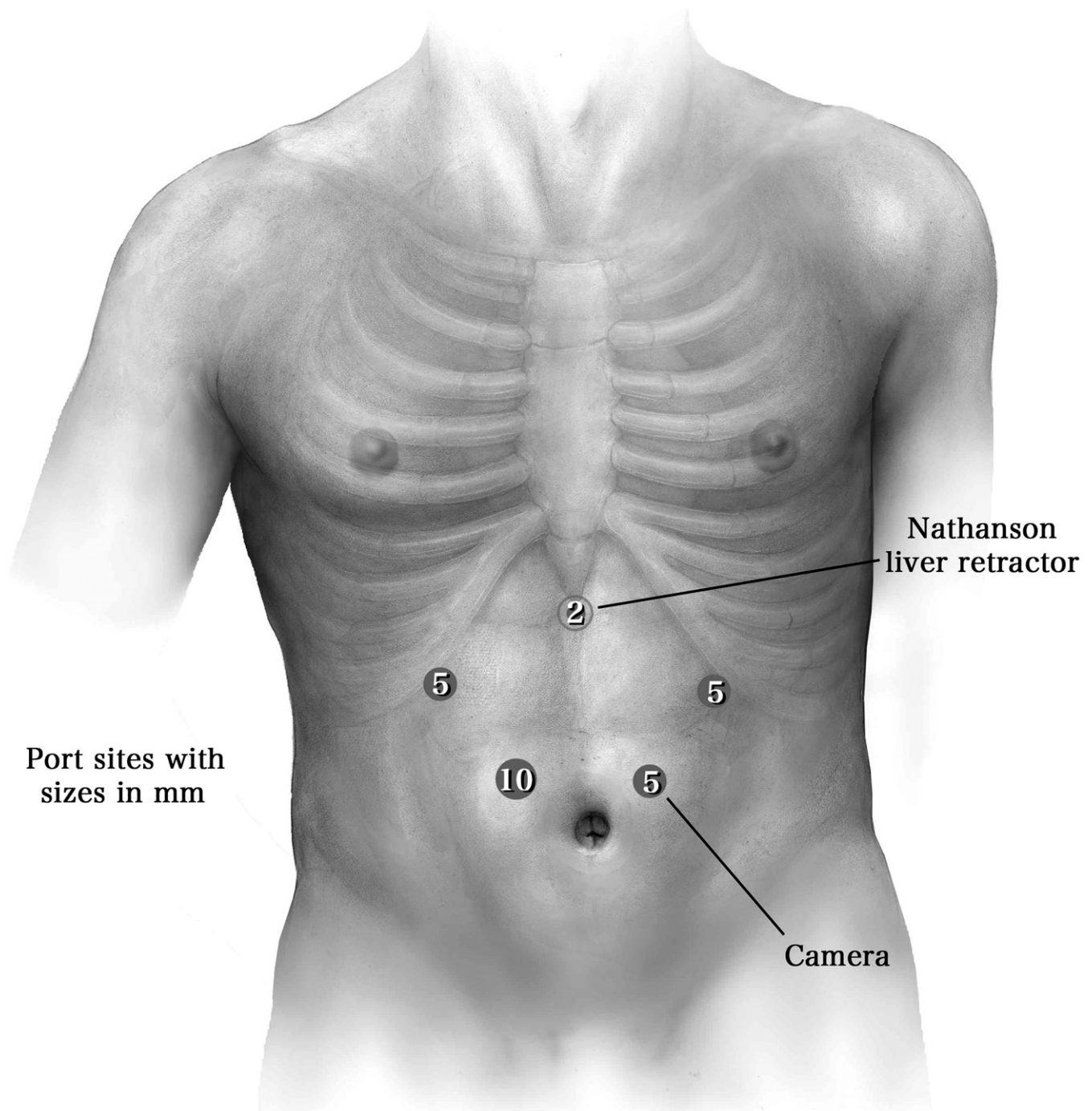
\*Department of Thoracic Surgical Oncology and Minimally Invasive Surgery, HCA North Texas Division, Medical City Dallas, Dallas, Texas.

†Section of General Thoracic Surgery, Lung Transplant Program, New York-Presbyterian Hospital/Columbia University Medical Center, New York, New York.

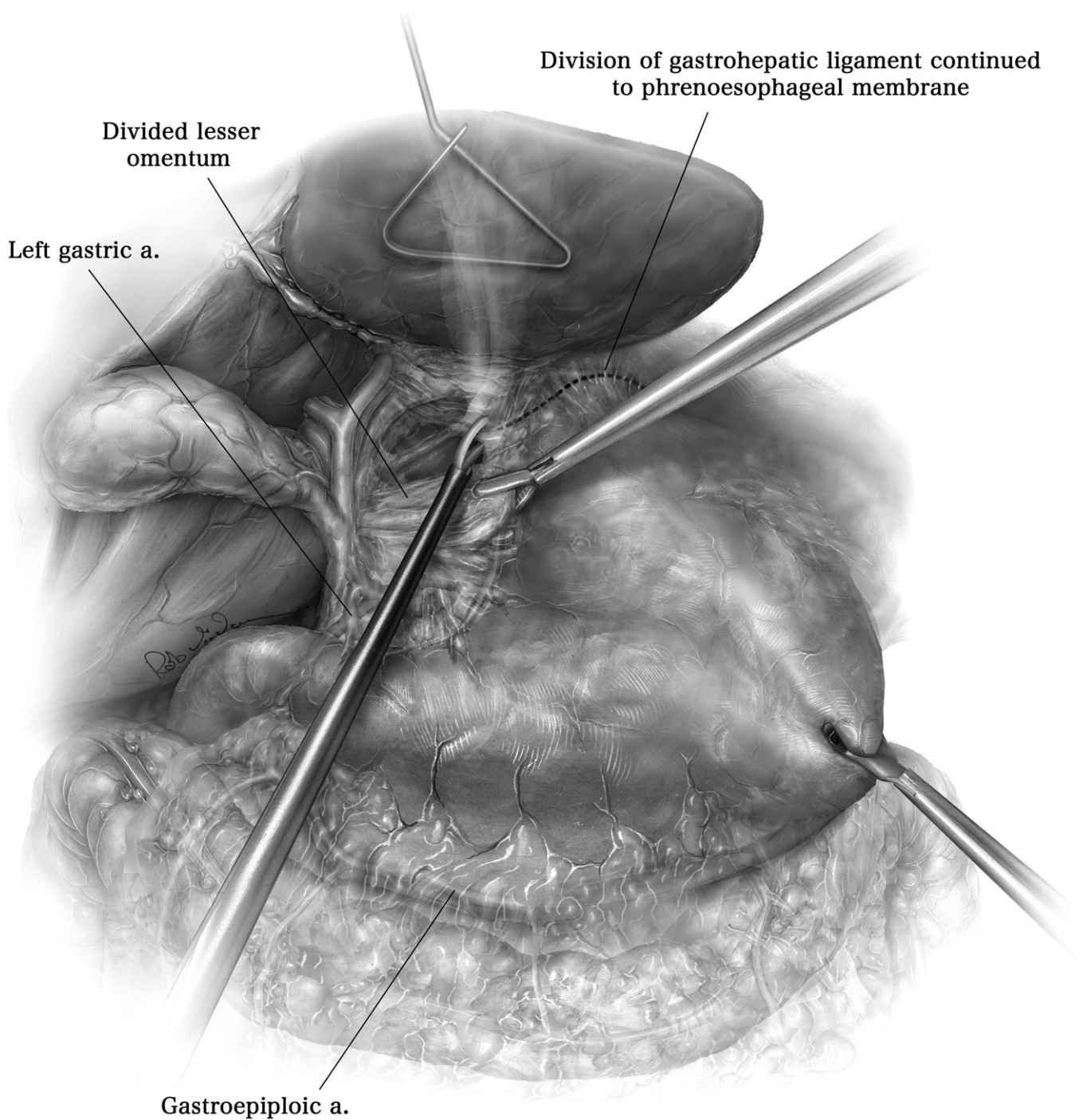
Dr. Magee reports receiving consulting fees from Covidien. Dr. Sonnett reports receiving consulting fees from Covidien.

Address reprint requests to Mitchell J. Magee, MD, MS, FACS, Director of Thoracic Surgical Oncology and Minimally Invasive Surgery, HCA North Texas Division, Medical City Dallas, 7777 Forest Lane, Suite A-323, Dallas, TX 75230. E-mail: [mitchell.magee@hcahealthcare.com](mailto:mitchell.magee@hcahealthcare.com)

## Operative Technique

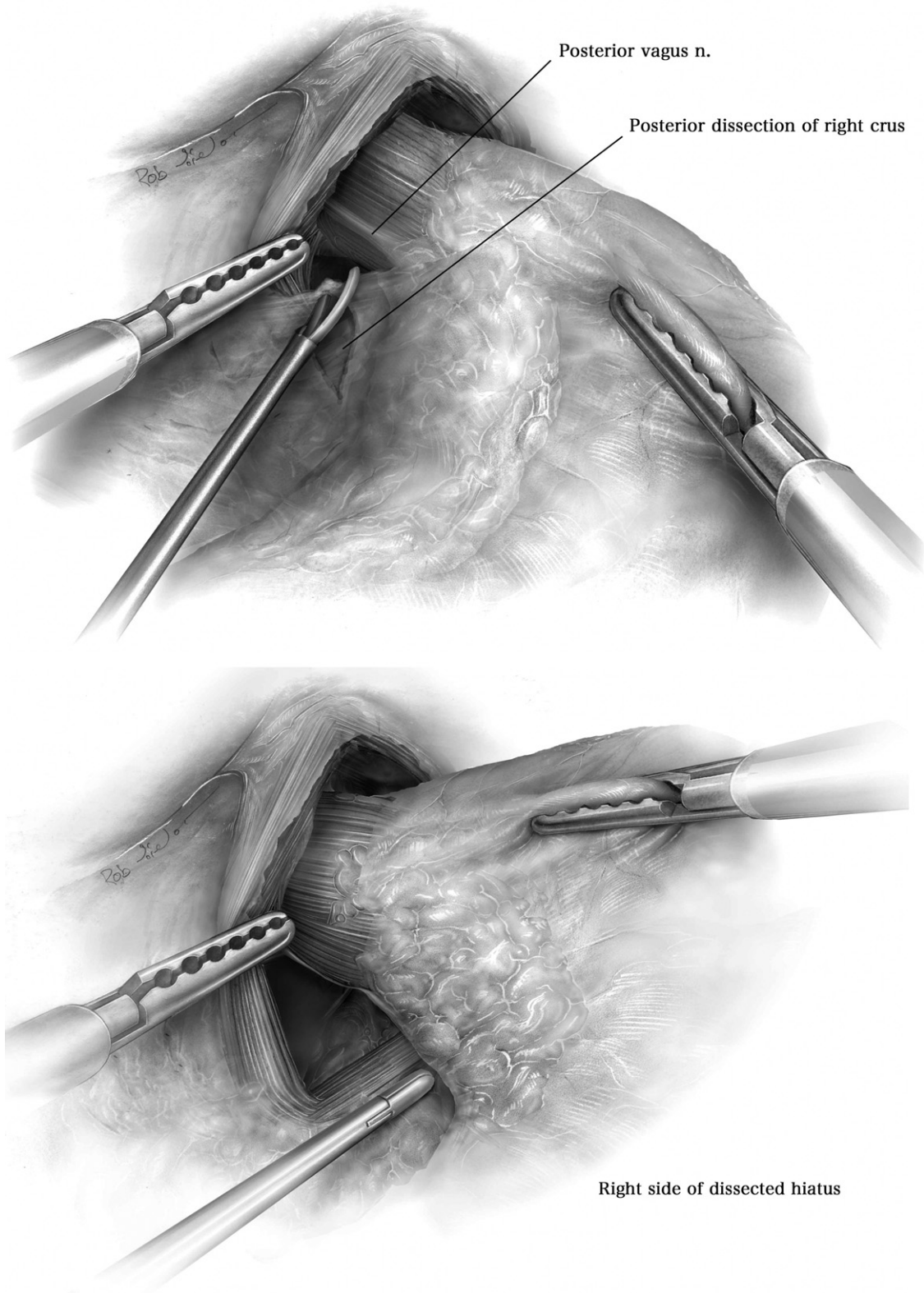


**Figure 1** A flexible esophagogastroscopy is performed again after induction of general anesthesia to confirm the absence of any retained food or particulate matter within the EED. Any retained food should be removed endoscopically to avoid stapling across a grossly contaminated diverticulum. The patient is placed supine in steep reverse Trendelenburg position with footboard support. The surgeon stands on the right side and the first assistant on the left. Three 5-mm and one 10-mm port are used in addition to the subxyphoid 2-mm port for the Nathanson liver retractor. The 10-mm port and the adjacent 5-mm port are positioned two thirds of the distance between the xiphoid and the umbilicus and centered in the respective rectus abdominus muscle. The 2 lateral 5-mm ports are positioned near the midclavicular line below the costal margin, and these 4 ports form a half-oval. A 5-mm 30° scope with an attached high definition camera is essential.

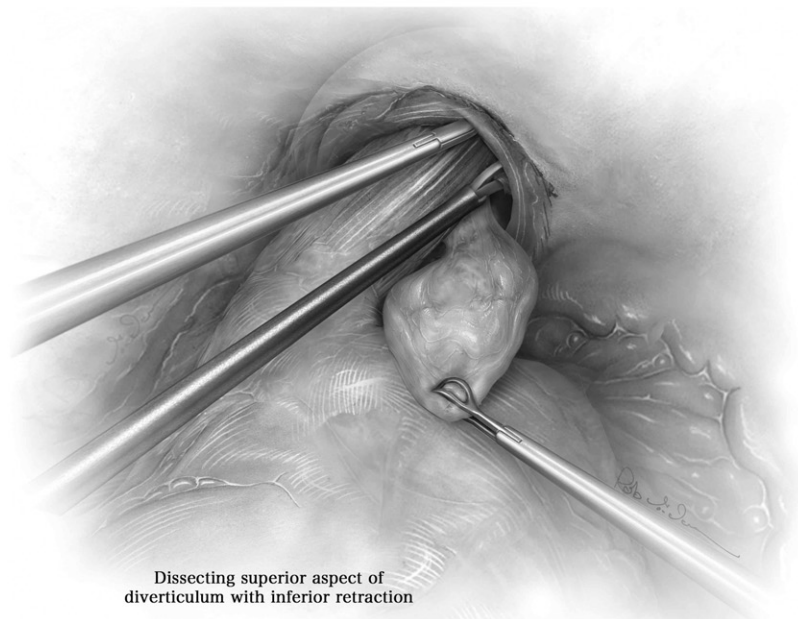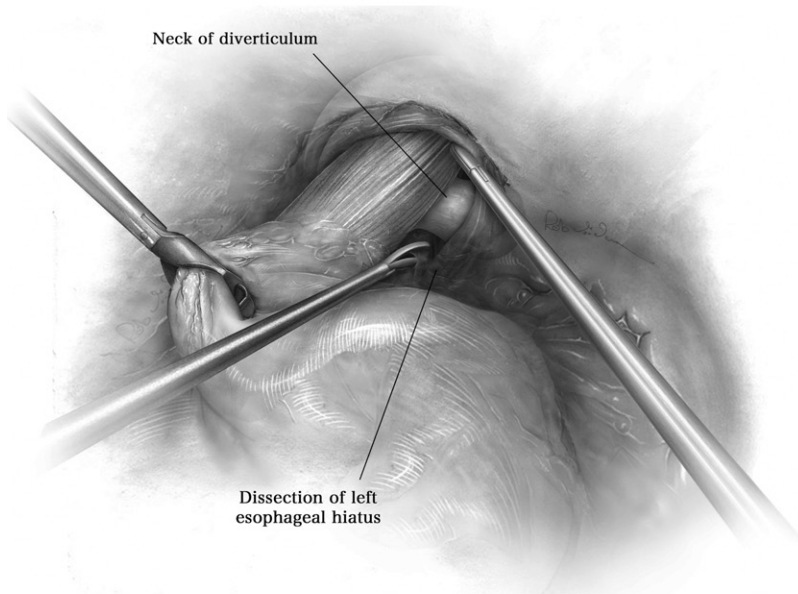
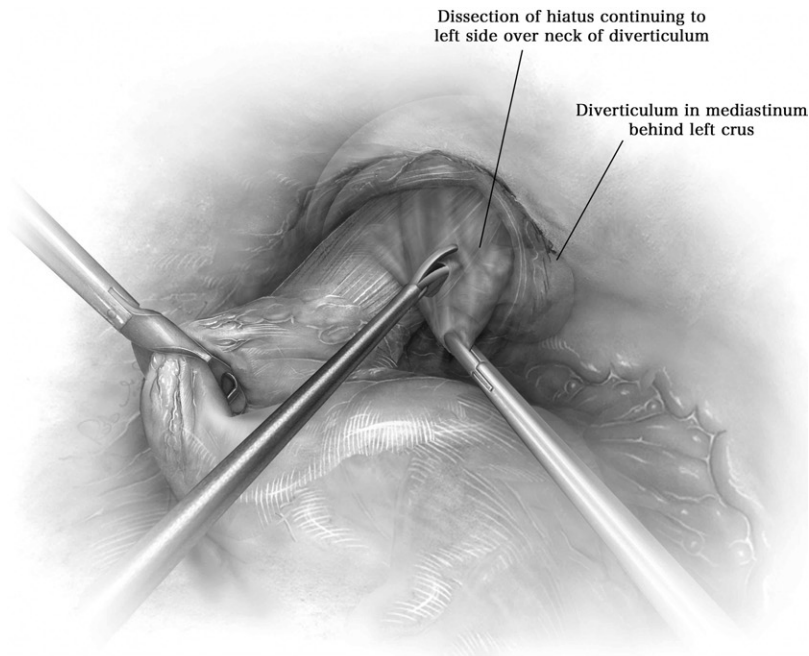


**Figure 2** Atraumatic endoscopic grasping forceps and harmonic shears are used for most of the dissection. Longer instruments and laparoscope commonly used in bariatric procedures provide the extra length often needed to assure ease of dissection high in the mediastinum. The gastrohepatic ligament or lesser omentum is divided first over the caudate lobe of the liver where it is relatively transparent and extended cephalad toward the right pillar of the diaphragm crus. It is not necessary to routinely divide the gastrosplenic ligament or the short gastric vessels. a. = artery.

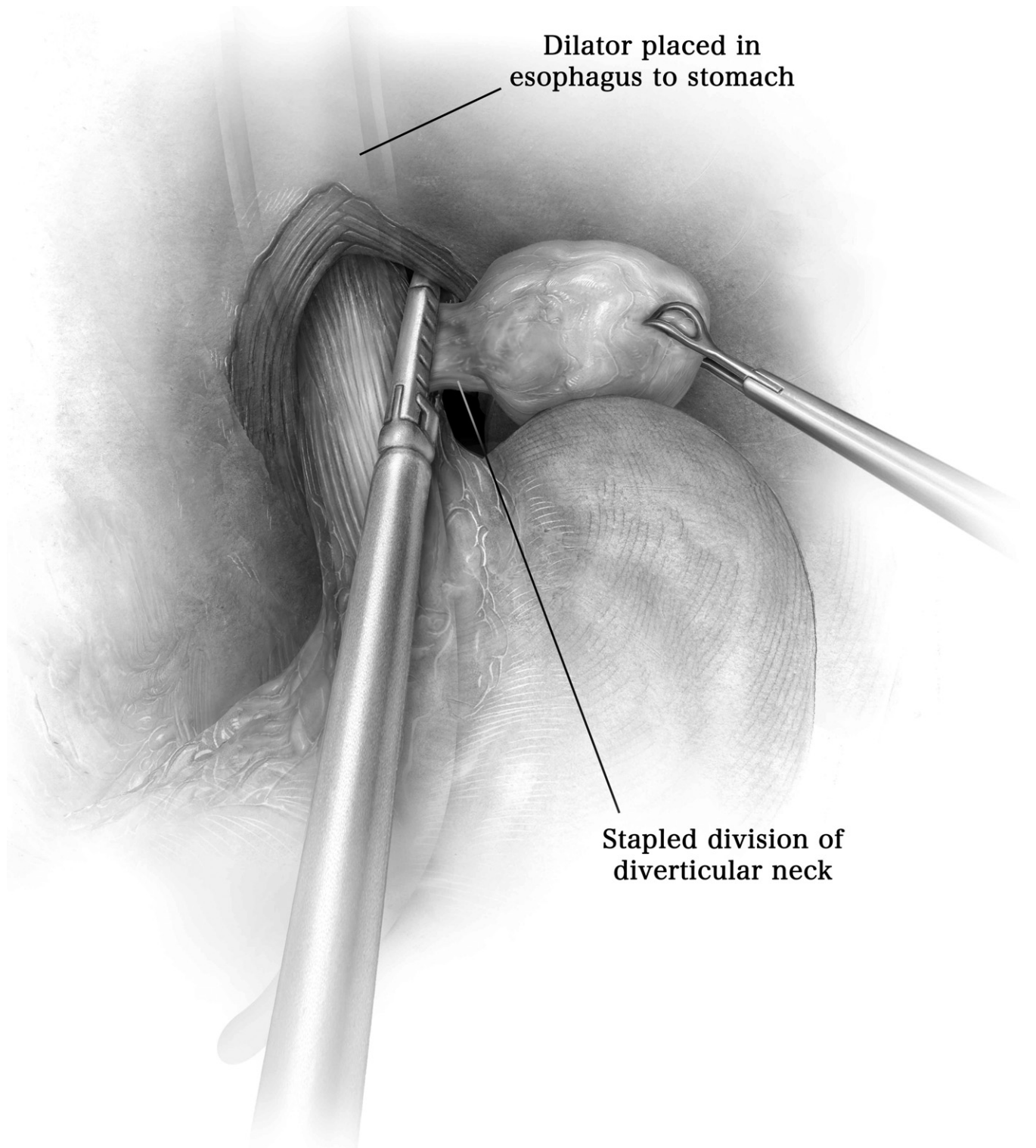




**Figure 3** The right pillar of the crus is then exposed, separating it from the esophagus, and the posterior vagus nerve is identified and carefully spared. Dissection continues anteriorly and to the left, dividing the phrenoesophageal membrane, where the anterior vagus nerve is identified and spared. The left pillar of the diaphragm crus is exposed anteriorly and separated from the esophagus. The dissection continues posteriorly along the left diaphragm crus. The esophagus is separated completely from the diaphragm circumferentially, completing the dissection at the hiatus posteriorly working from the right crus onto the left. The fat pad is removed to expose and define the gastroesophageal junction. n. = nerve.



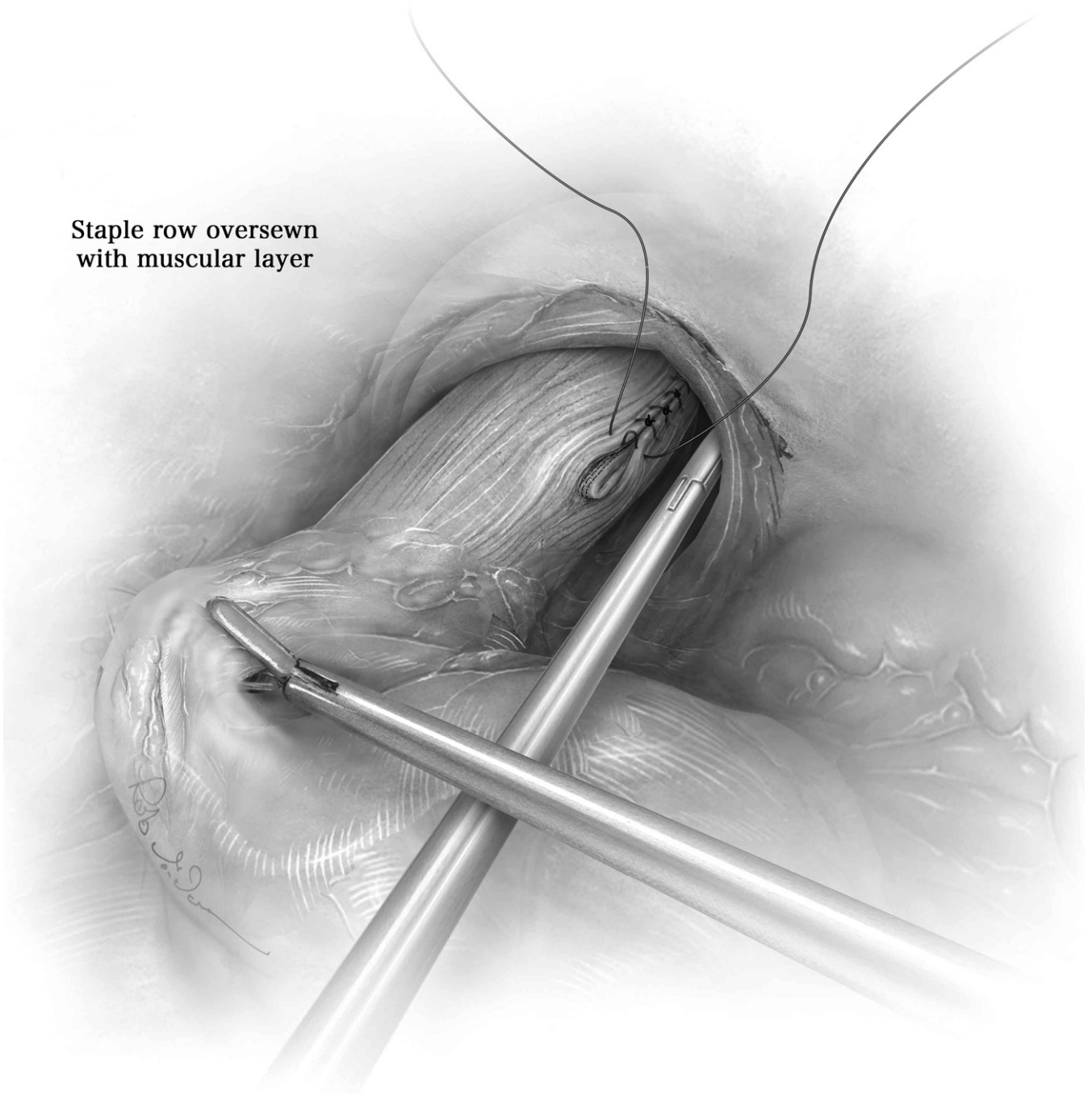
**Figure 4** Complete circumferential mobilization of the esophagus is continued through the hiatus into the mediastinum where the diverticulum is identified and for several centimeters cephalad to the diverticulum. This is facilitated by caudal retraction of the esophago-gastric junction toward the patient's right side. In our early experience, we placed a Penrose drain around the distal esophagus for retraction, but no longer find this to be a time-efficient, worthwhile exercise. It is essential to a safe and complete diverticular resection to visualize clearly the entire cephalad extent of the neck of the diverticulum, protruding through the longitudinal muscle layer of the esophagus, as the body of the diverticulum is clearly defined and dissected circumferentially. If adequate visualization of the diverticulum is not achieved from the laparoscopic approach, the diverticular resection is deferred and a mini-thoracotomy is added.



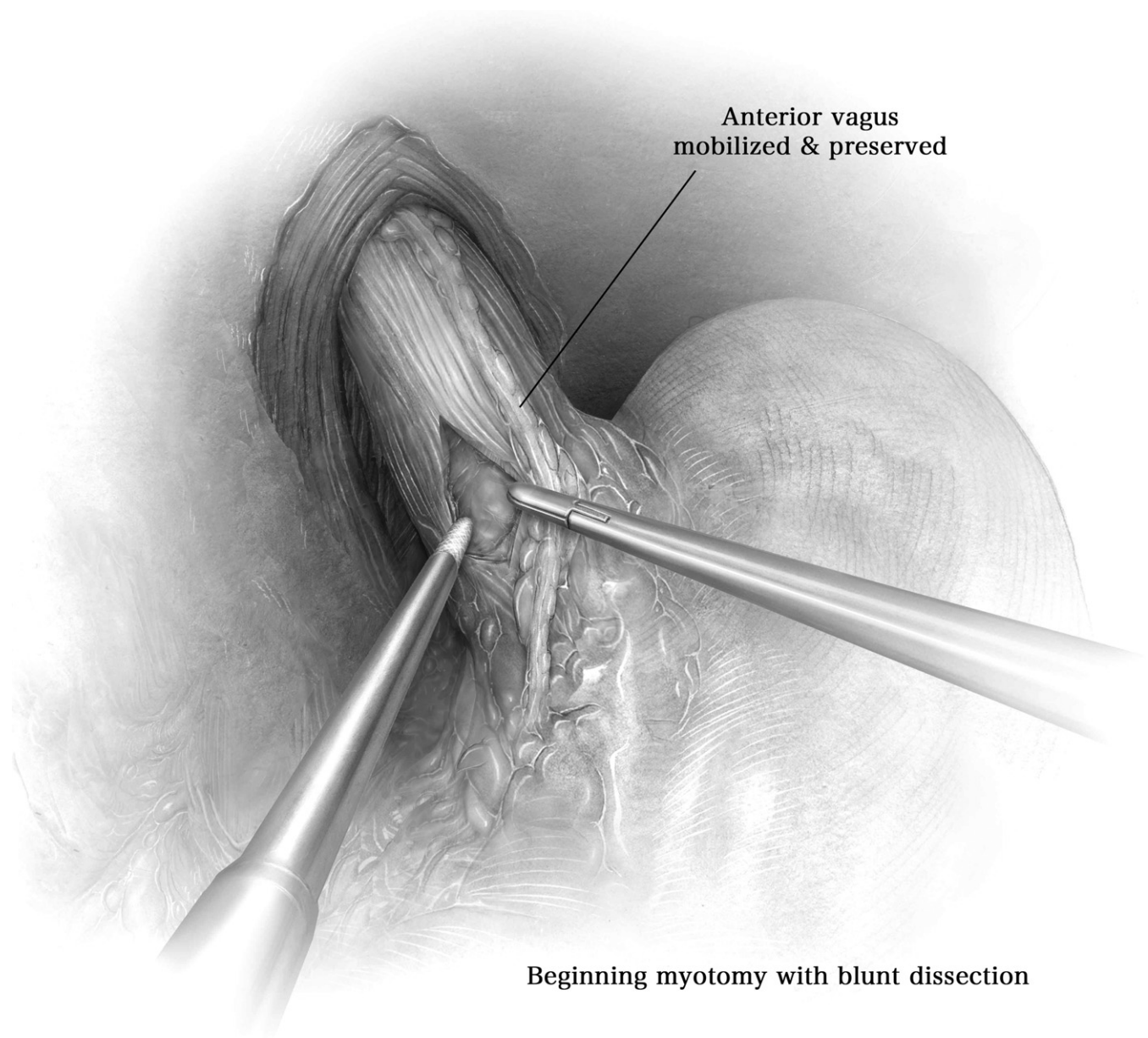
**Figure 5** A 52- or 54-French bougie dilator is then carefully placed in the lumen of the esophagus, ensuring that the tip avoids the diverticulum and passes through the gastroesophageal junction. An Endo GIA Universal stapler with a 60-mm medium-thick tissue cartridge is positioned parallel to the esophagus in the mediastinum. The stapler is then placed across and cephalad to the neck of the diverticulum, parallel to the esophagus and snug against the bougie, and deployed to resect the body of the diverticulum while stapling closed the mucosal neck.



**Staple row oversewn  
with muscular layer**

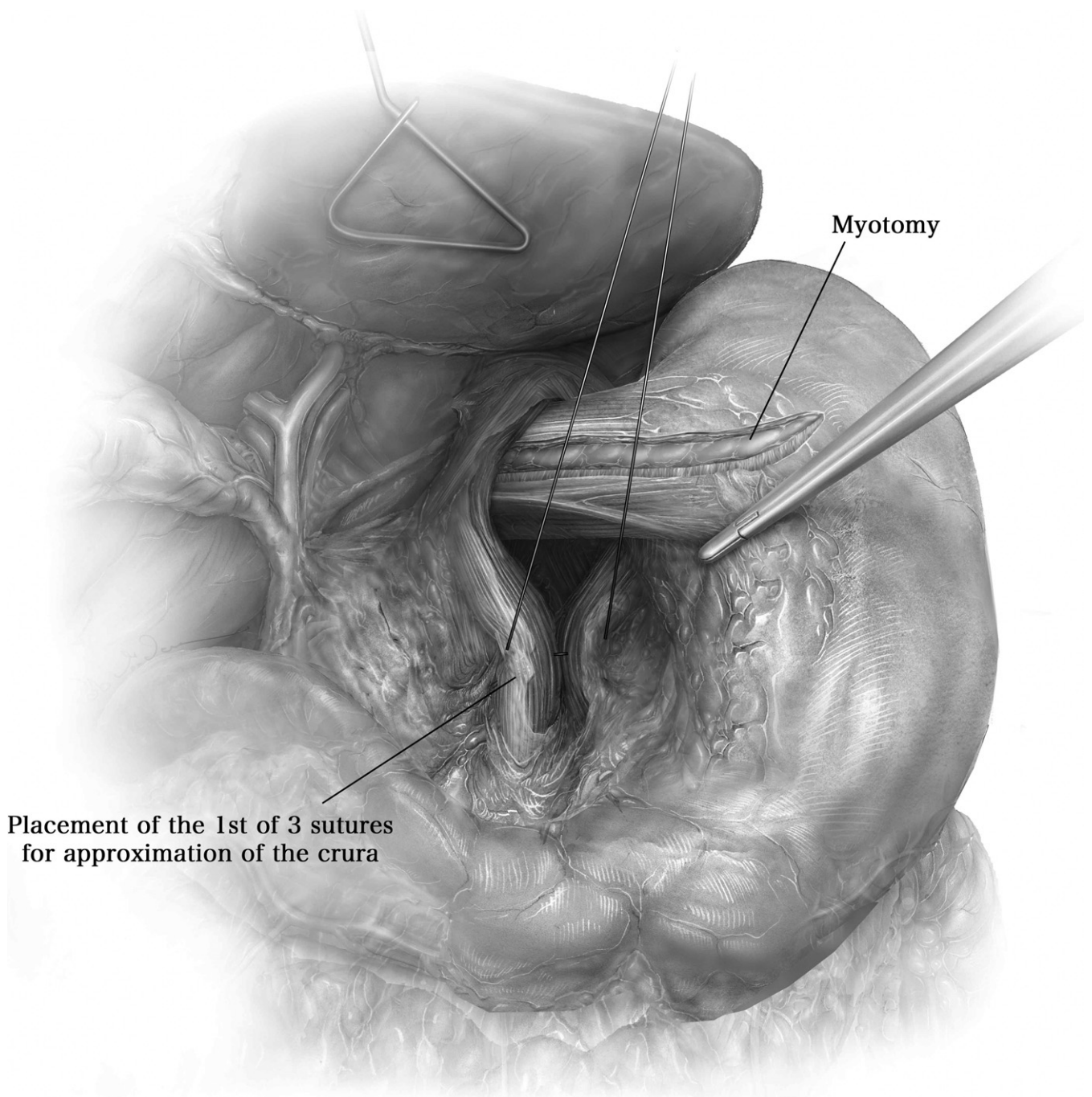


**Figure 6** The separated longitudinal muscle fibers of the esophagus are then reapproximated over the staple line with either a running or an interrupted 2-0 Ethibond suture. Our preferred method of closure is an interrupted technique utilizing the Covidien Endo Stitch suturing device. Withdrawing the bougie will facilitate downward retraction and exposure of the esophagus for suturing the most cephalad extent of the myotomy. Again, if this cannot be accomplished safely from the laparoscopic approach, we complete the procedure through a mini-thoracotomy. If a thoracotomy is required, the abdomen is closed and the patient is repositioned in a standard full lateral decubitus position, but tilted slightly more prone and prepared in the usual fashion. A left 7th or 8th intercostal space limited thoracotomy will usually provide adequate exposure.

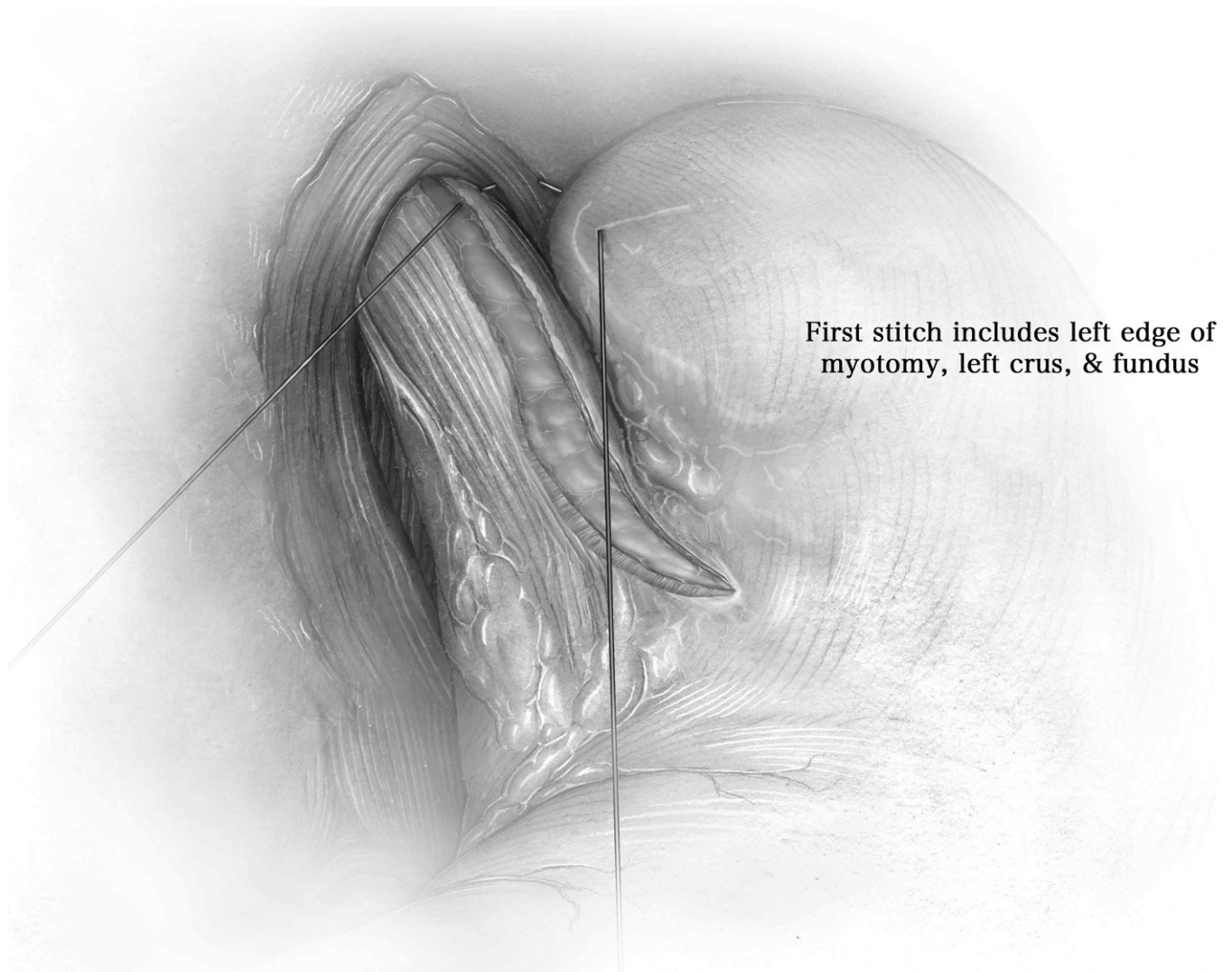


**Figure 7** The myotomy site is positioned between 45 and 180° lateral and away from the diverticulum staple line. The myotomy is begun about 2 cm proximal to the esophago-gastric (EG) junction by bluntly separating the longitudinal muscle fibers with endoscopic grasping forceps and an Endo-Kittner dissector. If an energy source is used to cut and cauterize the myotomy, great care must be taken to avoid any thermal energy transfer to the mucosa. The myotomy is extended proximally on the esophagus to the level of the most cephalad extent of the diverticulum, or approximately 6 cm from the EG junction, and extended distally 1.5 to 2 cm to include the lower esophageal sphincter and EG junction onto the cardia of the stomach. An upper endoscopy with CO<sub>2</sub> insufflation is used to assess mucosal integrity at the myotomy and diverticulectomy sites and to insure completeness of the distal myotomy.

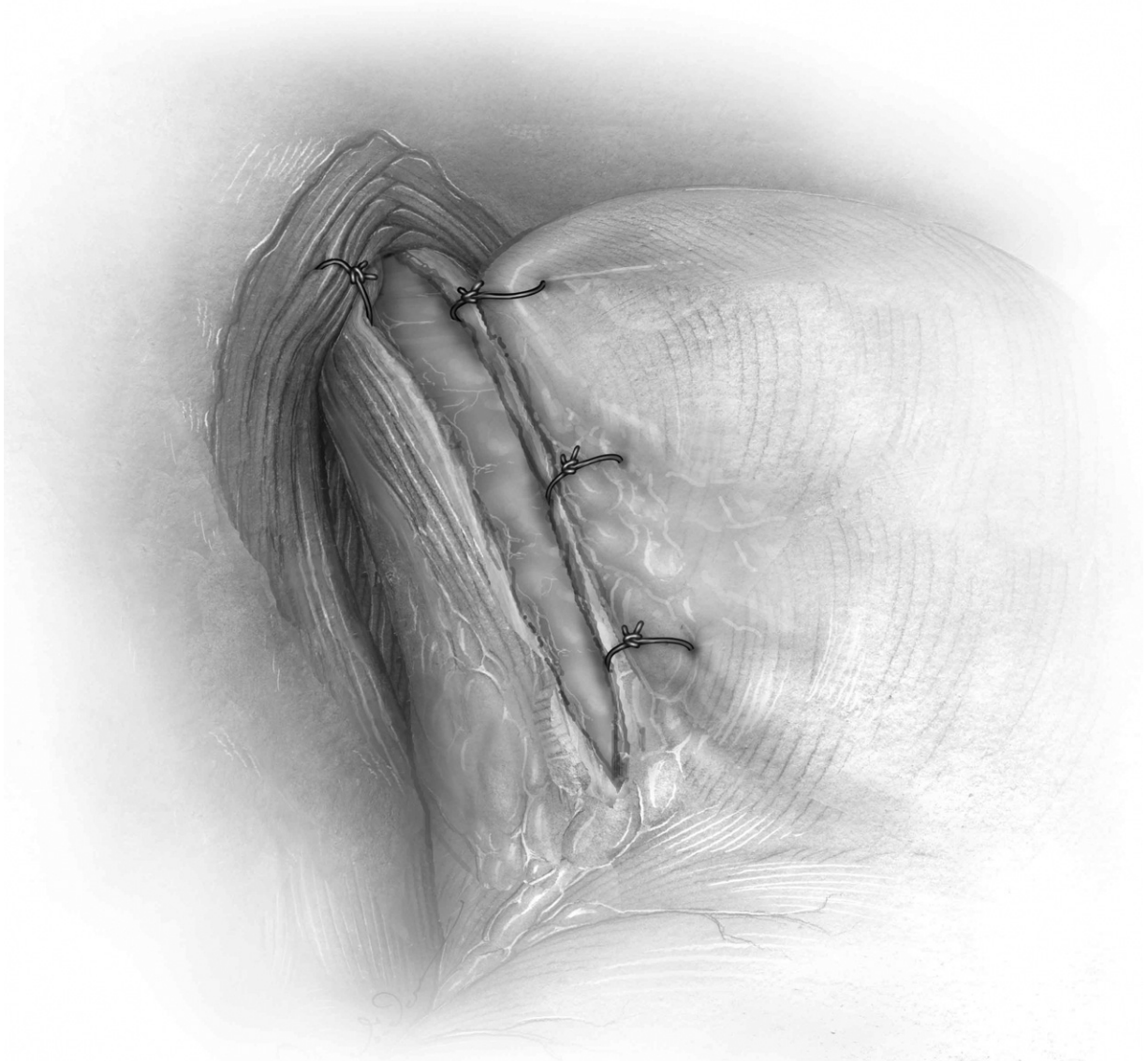




**Figure 8** Apposing the posterior crura of the diaphragm with 2 to 4 interrupted pledgeted 0-Ethibond sutures loosely closes the esophageal hiatus with the bougie positioned across the EG junction. It is extremely important that this closure not be too tight.

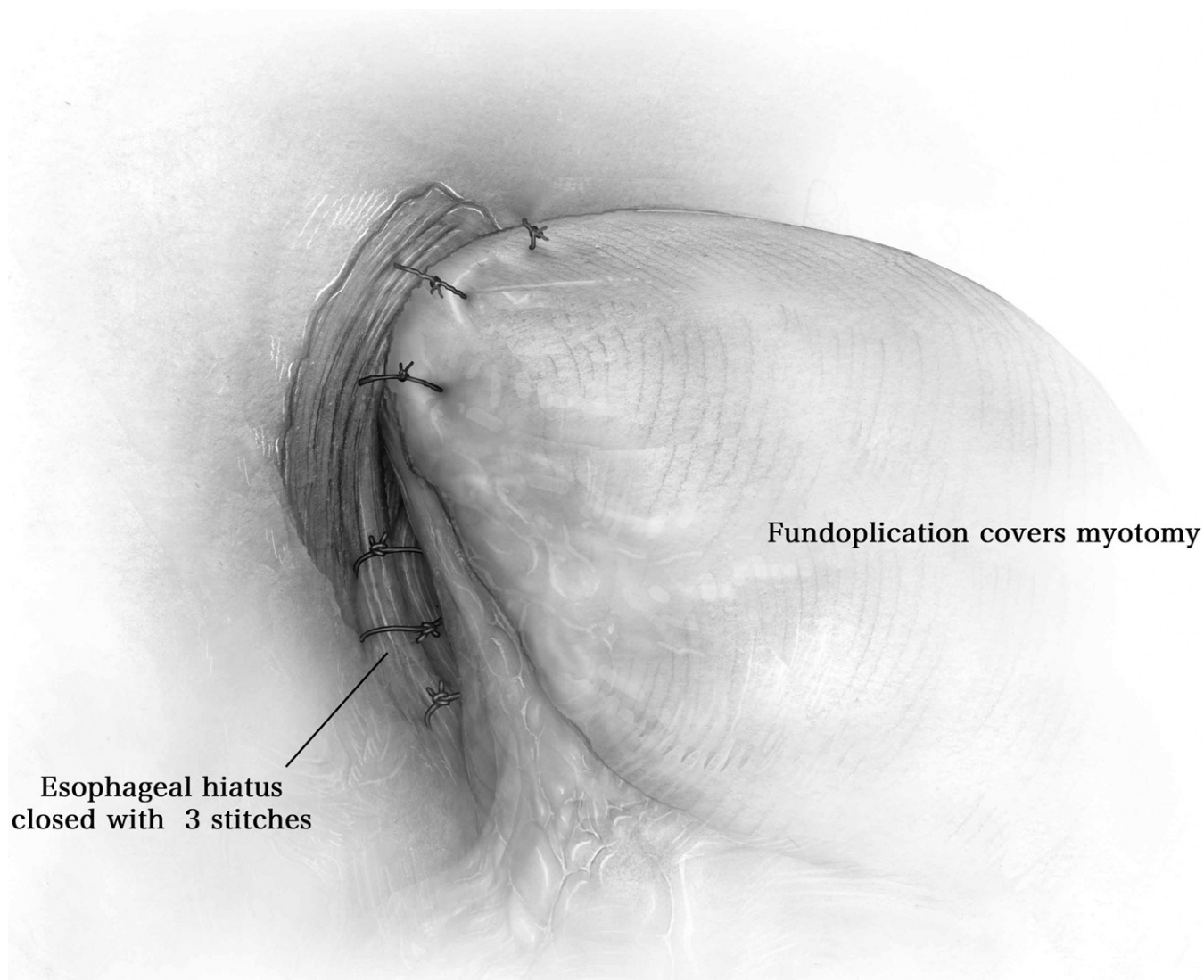


**Figure 9** Lastly, a Dor anterior partial fundoplication is performed. It is not necessary and indeed may be undesirable to divide the short gastric vessels. The fundus of the stomach is gently grasped at a point where the stomach lies anterior to the myotomy and reaches the right crus comfortably. The first suture in the fundoplication approximates the stomach, the left crus, and the left side of the split longitudinal muscle of the esophageal myotomy.



**Figure 10** Two additional sutures are then placed posterior to the first and distal on the myotomy, approximating only stomach and the left side of the split longitudinal esophageal muscle.





**Figure 11** The fundus of the stomach is then folded to the patient's right and similar sutures are placed on the right side of the myotomy. The first suture on the right side approximates the stomach, right diaphragm crus, and right side of the split longitudinal esophageal muscle of the myotomy. Two additional sutures placed posteriorly, again approximating the right crus, fundus, and the right side of the split longitudinal esophageal muscle of the myotomy, completes the anterior partial fundoplication.

## Conclusions

Following an uncomplicated procedure, a postoperative contrast esophagram is not routinely obtained and the patient is given a liquid diet on the first postoperative day. Most patients are discharged from the hospital on the first postoperative day and maintain a pureed diet for 2 weeks followed by a mechanical soft diet for an additional 2 weeks. Proton pump inhibitors are maintained indefinitely and all medications are prescribed in crushed or liquid form, avoiding pills. The optimum treatment of epiphrenic diverticula remains controversial. As this is an uncommon disorder, the majority of patients remain asymptomatic or have minimal symptoms and consequently are appropriately managed expectantly

with observation. In symptomatic patients, the symptoms are largely due to an underlying motility disorder, and the recommended treatment has traditionally been a left 7th or 8th intercostal space posterolateral thoracotomy with resection of the diverticulum and myotomy, with or without a partial fundoplication such as a Belsey Mark IV. In recent years, the preferred management has evolved to a laparoscopic approach as we have described. We have found the critical aspects of the operation to be more easily accomplished less invasively via laparoscopy rather than through a left thoracotomy or thoracoscopy. As in many procedures, appropriate patient selection and meticulous attention to the fundamentals of the procedure based on the pathophysiology will yield a satisfying outcome for patient and surgeon.