Combined endovascular and surgical approach (CESA) to thoracoabdominal aortic pathology: A 10-year experience

William Quinones-Baldrich, MD, Juan Carlos Jimenez, MD, Brian DeRubertis, MD, and **Wesley S. Moore, MD,** *Los Angeles, Calif*

Objective: **The first combined endovascular and surgical approach for thoracoabdominal aortic aneurysm was performed at our institution in 1998. We report a 10-year experience with a hybrid approach to thoracoabdominal aortic pathology.**
Methods: **Records of all patients undergoing a combined endovascular and surgical approach to thoracoabdominal aortic pathology were reviewed. Presenting symptoms, perioperative morbidity and mortality, sequence (single versus two stages), and late results were analyzed.**
Results: **From 1998 to 2008, 20 patients were treated with hybrid repairs for thoracoabdominal aneurysm (TAA) (15; four with dissection), aortic arch aneurysm (two), symptomatic supravisceral abdominal aortic aneurysm (one), contained perirenal pseudoaneurysm rupture (one), and floating aortic arch thrombus with cerebral and renal emboli in one patient. Ten patients had prior aortic grafting, one patient had a functional renal transplant, and all patients were considered high risk based on preoperative comorbidities. Aneurysm related pain (11) or aneurysm growth (eight), mesenteric ischemic symptoms (four), and peripheral embolization (one) were indications for intervention. Spinal catheter drainage was used routinely. The procedure was completed in a single stage (13), or two stages using a subcutaneous conduit constructed at the first stage (six). One patient refused the second stage and expired from aneurysm rupture five months later. There were nine major complications in six patients (32% morbidity); all recovered except one patient with complete aortic coverage from left subclavian to bifurcation in the single stage group who developed paraplegia (one of 15 patients at risk; 6.6%). There was no perioperative mortality (0-30 days or discharge). Two patients had successful re-intervention for a type I (included as a major complication) and II endoleak respectively. Two type II endoleaks without aneurysm growth continue under observation. There has been no graft thrombosis, aneurysm growth, or rupture during a mean follow-up of 16.6 months (range, 1-119 months) in 19 patients with a completed procedure (none lost to follow up). Cumulative survival at two years is 76%.**
Conclusions: **A combined endovascular and surgical approach to thoracoabdominal aortic pathology can be performed in high-risk patients with acceptable morbidity and mortality. A two-stage approach is preferable when extensive coverage of the aorta is necessary and a subcutaneous conduit simplifies the second stage. Follow-up of 10 years in our initial patient suggests that this approach can be durable. Additional experience and longer follow-up is needed before expanding current indications for this approach. (J Vasc Surg 2009;49:1125-34.)**

Endovascular aortic grafting has become an excellent alternative for management of patients with abdominal aortic aneurysms or descending thoracic aneurysms particularly when significant comorbidities are present.[1] Endovascular repair of suitable aortic aneurysms have resulted in decreased morbidity and mortality. Open surgical repair of these pathologies is now usually reserved for younger good risk patients or patients with unsuitable anatomy for an endovascular approach. Continued evolution of endovascular technology is likely to improve results and address some of the anatomic limitations that currently exist.

Patients with thoracoabdominal aortic pathology with involvement of arch or visceral vessels represent a particular challenge for endovascular repair. Efforts in developing branch endografts are underway and have seen some success in a very limited experience.[2] Combining established surgical techniques with endovascular grafting is another alternative in the management of patients with arch or visceral involvement who currently are not candidates for a complete endovascular approach. These patients frequently have significant comorbidities and can benefit from a lesser procedure using a combined technique.

In 1998, we evaluated a patient who had suffered two infrarenal abdominal aortic aneurysm ruptures, each treated successfully using a transabdominal and a retroperitoneal approach respectively. He presented with a type IV thoracoabdominal aneurysm and aneurysms of both renal arteries, the celiac artery, and the superior mesenteric artery. Using a combined endovascular and surgical approach (CESA), the type IV thoracoabdominal aneurysm and the visceral aneurysms were repaired by retrograde revascularization of the visceral vessels with individual grafts, and exclusion of the thoracoabdominal aneurysm using an endovascular graft.[3] Concerns about the durability of this approach made us hesitant to recommend it to other patients with thoracoabdominal aneurysms. After a four-year

From the Division of Vascular Surgery, University of California at Los Angeles Medical Center.
Competition of interest: none.
Reprint requests: Dr. William Quinones-Baldrich, 200 UCLA Medical Plaza, Suite 510-3, UCLA Medical Center, Los Angeles, CA 90095 (e-mail: wquinones@mednet.ucla.edu).
0741-5214/$36.00

doi:10.1016/j.jvs.2008.12.003

follow-up, and given his excellent clinical course, we began considering CESA for high-risk patients with arch and thoracoabdominal aneurysms.

This report summarizes our experience and the lessons learned with a combined endovascular and surgical (hybrid) approach in the management of high-risk patients with thoracoabdominal aortic pathology.

PATIENTS AND METHODS

Using a prospectively maintained database, the records of all patients undergoing a combined endovascular and surgical approach for repair of thoracoabdominal aortic pathology at the UCLA Medical Center were reviewed. Age at presentation, gender, indication for repair, type of aneurysm (if present), and comorbidities (coronary artery disease with or without prior myocardial infarction, congestive heart failure, hypertension, renal function, diabetes mellitus, smoking history, pulmonary disease, or other systemic condition) were recorded. American Society of Anesthesiologists (ASA) classification was determined based on these comorbidities. When the patient had four or more of these risk factors, ASA class 4 was assigned. Patients in ASA class 2 had at least two of these conditions.

Symptoms related to the presenting aneurysm, ischemic symptoms from branches arising from the affected segment, history of aortic surgery, and the presence of aortic dissection were noted. Details of the procedure were recorded. Specifically, whether the approach was a single or a two-stage procedure, use of spinal catheter drainage, specific branches revascularized, proximal and distal landing zones for the endografts, and number of endografts used, were recorded. Operative time, intraoperative blood loss, and total contrast used was noted.

The in-hospital postoperative course was reviewed noting intensive care unit (ICU) stay, and complications such as graft thrombosis, myocardial infarction, postoperative renal insufficiency, pulmonary complications, bleeding, infection, and reoperation. Postoperative mortality was defined as death within the hospital stay of the procedure, or within 30 days of operation. Postoperative renal insufficiency was considered significant when more than a 50% rise of preoperative creatinine was noted or if the patient required dialysis at any point during the postoperative course. Pulmonary complications were considered significant if the patient required respiratory assistance for longer than 72 hours after surgery, or reintubation. Postoperative bleeding was considered significant if reoperation for bleeding was necessary. Infection was considered significant if it prolonged hospital stay or required any additional intervention or readmission.

Long-term results were based on clinic notes during follow-up, surveillance computed tomography (CT) scans, hospital records if readmission occurred, and patient interview by telephone when no additional information within three months was available at the time of this review. Specifically, any complications related to the retrograde or extra-anatomic grafts were noted. The presence or absence of endoleak of any type was recorded. Aneurysm size based on surveillance CT scans and any type of reintervention related to the procedure were noted. Survival was calculated using actuarial methods.

Table 1. Demographics and risk factors in 20 patients treated with combined endovascular and surgical approach (CESA) for thoraco-abdominal aortic pathology

Demographics and risk factors	*Number (%)*
Age	51-89 years (mean, 68 years)
Male/female	11 (55%)/9 (45%)
CAD/MI	12 (60%)/8 (40%)
CHF	2 (10%)
HTN/poor control	18 (90%)/5 (25%)
COPD	12 (60%)
CRF/CRI	1 (5%)/3 (15%)
Stroke/Acute	3 (15%)/1 (5%)
CMI	4 (20%)
SLE	2 (10%)
Hyperthyroidism	1 (5%)
ASA Class 3	10 (50%)
ASA Class 4	7 (35%)
Symptomatic	13 (65%)
TAA	15 (75%)
Type II	3 (20%)
Type III	8 (53%)
Type IV	4 (27%)
Dissection	4 (27%)
Other aortic pathology	5 (25%) see text
Major surgery	14 (70%)
Aortic	12 (60%)
Other (see text)	2 (10%)

ASA, American Society of Anesthesiologists; *CAD,* coronary artery disease; *CHF,* congestive heart failure; *CMI,* chronic mesenteric ischemia; *COPD,* chronic obstructive pulmonary disease; *CRF/CRI,* chronic renal failure/insufficiency; *HTN,* hypertension; *MI,* myocardial infarction; *SLE,* systemic lupus; *TAA,* thoraco-abdominal aneurysm.

RESULTS

Between October of 1998 and September of 2008, 20 patients presenting with thoracoabdominal aneurysm, aortic arch aneurysms or other aortic process, and significant increased risk for conventional repair due to comorbidities and/or prior aortic surgery were treated with a combined endovascular and surgical repair of their pathology. Patient demographics and co-morbidities including ASA classification is presented in Table I. Their age ranged from 51 to 89 years with a mean age of 68 years. There were 11 males and 9 females. There were 12 patients with history of coronary artery disease; eight had a myocardial infarction in the past. Two of these patients had chronic congestive heart failure. Most patients (18 of 20) had history of hypertension and in five, it was poorly controlled on multiple medications. Significant chronic obstructive pulmonary disease was present in 12 patients, including one patient who was oxygen dependent. Four patients had diabetes mellitus, including one patient on chronic hemodialysis. Renal insufficiency, with creatinine greater than 1.5, was present in three patients. Three patients had suffered hemispheric strokes including one patient with an acute stroke, which represented the indication for intervention. Four patients

had symptoms of chronic mesenteric ischemia with documented stenosis or occlusion of at least two mesenteric vessels. Two patients had systemic lupus, and one patient was hyperthyroid, controlled during the same admission. Seventeen patients were ASA class 3 (10) or 4 (7).

Indications for intervention and procedure details are summarized in Tables II and III. Three patients were ASA class 2 and presented significant risk owing to prior aortic surgery (thoracic interposition graft with left heart bypass for acute type B dissection; arch replacement with elephant trunk and AAA repair) or abdominal surgery (gastrectomy and gastrojejunostomy). Two patients presented with large aortic arch aneurysms, and one patient had an exophitic ulcerated plaque with floating thrombus in the transverse aortic arch and emboli to the brain and kidney. Fifteen patients had thoracoabdominal aneurysms. There were three type II, eight type III (including one patient with a ruptured visceral patch after previous surgical repair), and four type IV thoracoabdominal aneurysms. Four of these patients had chronic aortic dissection. One patient had a ruptured juxtarenal aneurysm after a prior infrarenal aortic repair, and one patient had a perivisceral aneurysm with chronic mesenteric ischemia.

There were 13 symptomatic and seven asymptomatic patients. Symptomatic patients included four patients who presented with chronic mesenteric ischemic symptoms. One patient had a functioning renal transplant and one patient was on chronic hemodialysis. One patient (#20) presented with an acute left hemispheric stroke, left internal carotid and left subclavian artery occlusion, and a renal infarct. CT scan and transesophageal echo showed exophitic plaques with floating thrombi in the aortic arch and descending thoracic aorta. Aneurysm size varied from 5 cm to 9.3 cm with an average of 6.9 cm. Twelve patients had prior major abdominal or thoracic surgery including 10 patients with prior aortic aneurysm repair, one patient with a renal transplant, and one with a partial gastrectomy and gastrojejunostomy. One patient had a type A dissection repair, and one patient with a type II thoracoabdominal aortic aneurysm with dissection had a prior interposition graft in the proximal descending thoracic aorta via a left thoracotomy with left heart bypass.

All patients except those with arch aneurysm repairs had spinal catheter drainage during the endovascular portion of the procedure. Thirteen patients were treated in one stage including the three patients with arch pathology. Seven patients were treated in two stages. All two stage procedures were preplanned based on the anticipated extensive coverage of the thoracoabdominal aorta. One patient, intended to be treated in two stages, refused the second stage (89 years old) and ruptured the aneurysm five months after the first stage. This patient is included in this series for analysis on intent to treat basis. Trans-esophageal echocardiography was used in three of four patients with chronic aortic dissection and found to be useful in determining guide-wire location in either the true or false lumen. In one of these patients (with prior thoracic interposition graft), the endografts were purposely deployed in the false lumen to allow maximum endograft expansion (Fig 1).

Operating time averaged 8.4 hours for patients done in one stage and 8.3 hours for the first stage of patients treated in two stages. The endovascular stage of the procedure in the two-stage group took an average of two hours. The average number of devices used for the endovascular portion of the procedure was 2.8 devices. Estimated blood loss for patients treated in one stage and for the first stage of patients treated in two sessions was 920 mL. For the second stage of the procedure, the average blood loss was 400 mL. Average contrast used for the endovascular portion of the procedure in all cases was 254 mL (100-434 mL). When marker clips were used to fluoroscopically identify the origin of the retrograde or antegrade grafts, less contrast was used (160 mL vs 331 mL) All patients treated in two stages had a subcutaneous conduit placed at the first stage of the procedure and successfully used for the placement of the endovascular devices during the second stage. Marker clips placed proximal to the origin of the retrograde bypasses were found to be extremely useful during the second stage of the procedure reducing the amount of contrast necessary for accurate deployment (Fig 2). One patient on hemodialysis had revascularization of only the superior mesenteric and the celiac artery with left nephrectomy using a left retroperitoneal approach.

Complications included paraplegia in one patient (single stage group) who had coverage from the left common carotid to the right iliac bifurcation using thoracic endografts and a bifurcated AAA endograft. Retrograde revascularization to the SMA and celiac artery originated from a graft used to repair a common iliac artery aneurysm. No renal bypasses were necessary as the patient was on chronic hemodialysis. This patient became paraplegic 24 hours after the procedure during an episode of hypotension (1/15 patients at risk; 6.6% overall risk of paraplegia). In retrospect, this patient could have been treated in two stages, given the extensive aortic coverage necessary. Deterioration of renal function occurred in one patient with a preoperative creatinine of 2.2 rising to 3.6 after a one-stage procedure, who recovered without need for dialysis. One patient suffered a minor myocardial infarction without sequela and respiratory failure requiring re-intubation occurred in three patients. One patient had prolonged respiratory failure after requiring reoperation within 24 hours for a second look laparotomy and repair of an enterotomy. This patient survived the procedure but was in the intensive care unit for 92 days. Average ICU stay was 9.4 days. Excluding this patient, average stay in the intensive care unit was 4.8 days. There were no strokes associated with the procedures in either the single or two-stage group. Chylous ascites developed in the patient with prolonged respiratory failure and eventually responded to conservative measures.

Excluding patients in the two-stage approach, three patients were readmitted within 30 days of discharge. One patient was readmitted for a repair of a distal type I endoleak, which was resolved with an additional thoracic endograft. The remaining two patients were readmitted for

Table II. Combined endovascular and surgical approach performed in a single stage

Patient	*Age (years)*	*Indication*	*ASA class*	*Debranching details*	*Endograft proximal landing zone*	*Endograft distal landing zone*	*Perioperative complication (<30 days)*	*Follow up (months)*
1	62	5 cm Type IV TAA	2	Right iliac-celiac-SMA bypass; right ileo-birenal bypass	Descending thoracic aorta	Prior infrarenal aortic graft	None	119
2	63	6.7 cm Type III TAA	4	Right iliac-celiac-SMA bypass; right iliac to left renal bypass	Descending thoracic aorta	Prior infrarenal aortic graft	None	33
3	86	Contained rupture of visceral patch 12 years after repair of ruptured type III TAA	3	Retrograde aorto-celiac-SMA bypass, retrograde aorto-bi-renal bypass	Descending thoracic aortic graft	Infra-renal portion of prior aortic graft	None	31
4	70	5.7 cm Type II TAA	3	Retrograde Aorto-celiac-SMA-bi-renal bypass	Descending thoracic aorta	Distal infrarenal aorta	None	24
8	51	11 cm aortic arch and descending thoracic aneurysm with type B dissection	3	Aorto-innominate and aorto-left common carotid artery bypass; left carotid subclavian bypass, coil embolization of left subclavian artery	Proximal aortic arch	Supraceliac aorta	Reintervention on postoperative day 8 for large type I distal endoleak resolved with additional endograft	14
9	71	7.0 cm perivisceral aneurysm	3	Left iliac-celiac-SMA bypass. (Renal transplant right iliac artery)	Descending thoracic aorta	Main body of prior infrarenal endograft	None	13
12	67	7 cm Type III TAA, critical stenosis of celiac trunk and SMA	4	Left iliac-celiac-SMA bypass	Descending thoracic aorta	Juxtarenal aorta	Bilateral lower extremity paraplegia developed on postoperative day 1	6 Death due to MI
14	75	8.5 cm Type IV AAA with critical stenosis of celiac trunk and SMA, large distal aortic pseudo aneurysm	3	Resection of prior disrupted aortic tube graft, placement of aortobi-iliac bypass graft, retrograde aorto-celiac-SMA bypass, retrograde aorto-bi-renal bypass	Descending thoracic aorta	Distal main body of aortic bifurcation graft	Respiratory failure requiring prolonged ventilator dependence, chylous ascites	6 Death due to respiratory failure and CHF
15	76	6.5 cm Type III TAA	4	Retrograde aorto-celiac-SMA bypass, retrograde aorto-bi-renal bypass	Descending thoracic aorta	Infrarenal aorta	None	7

Table II. Continued.

Patient	*Age (years)*	*Indication*	*ASA class*	*Debranching details*	*Endograft proximal landing zone*	*Endograft distal landing zone*	*Perioperative complication (<30 days)*	*Follow up (months)*
16	73	9.5 cm juxtarenal aortic pseudo aneurysm	4	Left supraceliac to left renal artery bypass, right common iliac to right renal artery bypass	Juxtarenal aorta	Prior infrarenal aortic graft	Transient rise in creatinine (3.6) No dialysis	5 Death due to CHF
17	74	6.3 cm Type I TAA with Type B dissection, 3.8 cm right common iliac aneurysm	3	Right iliac-celiac-SMA bypass, resection of right common iliac aneurysm and repair with interposition Dacron graft	Descending thoracic aorta	Suprarenal aorta	None	4
19	76	5.2 cm perivisceral aneurysm with SMA, celiac stenosis	3	Retrograde right common iliac-celiac-SMA and bi-renal bypass	Descending thoracic aorta	Infra-renal aortic graft	None	1
20	67	Aortic arch plaques and floating thrombus with emboli to left ICA, occlusion left subclavian artery and renal infarct	3	Left carotid-subclavian bypass; Ascending aorta to innominate and left carotid bypass	Ascending aorta	Descending thoracic aorta	None	1

AAA, Abdominal aortic aneurysm; *ASA*, american Society of Anesthesiologists; *CHF*, congestive heart failure; *ICA*, internal carotid artery; *MI*, myocardial infarction; *SMA*, superior mesenteric artery; *TAA*, thoraco-abdominal aneurysm.

partial small bowel obstruction requiring exploratory laparotomy and lysis of adhesions. All three patients recovered without further complication. There was no mortality prior to hospital discharge or within 30 days of the completed procedure associated with the combined endovascular and surgical approach in these high-risk patients.

All patients have been followed at the UCLA Medical Center with either CT scan or magnetic resonance (MR) imaging at regular intervals. No patient has been lost to follow-up and all surviving patients were assessed within three months of this report. There have been three type II endoleaks and one type I endoleak requiring intervention as stated above. One type II endoleak occurred from a partially ligated celiac artery and was treated by placement of a covered stent through the retrograde bypass excluding flow to the splenic artery. Two type II endoleaks secondary to small lumbar arteries remain under observation without evidence of aneurysm growth.

Follow-up ranges from 1-120 months with a mean follow-up of 16.6 months. There have been five deaths during follow-up in this series. One was a patient who completed the first stage, refused to have the second stage, and had aneurysm rupture and death. Four additional patients died all within the first six months of the completed procedure. One patient had suffered prolonged respiratory failure and was recovering in a nursing home at the time of death. Two patients died of congestive heart failure or myocardial infarction at five and six months respectively after surgery. One patient died of an unrelated cause (no evidence of aneurysm rupture) at six months. There has been no bypass thrombosis or aneurysm growth or rupture in the 19 patients with a completed repair. Cumulative survival by actuarial methods is 71.1% at two years when all patients are included (intent to treat). In patients completing the procedure, cumulative survival at two years is 76.5%.

DISCUSSION

In 1998, we evaluated a patient presenting with a type IV thoracoabdominal aneurysm and aneurysms of all visceral vessels. He had history of two infrarenal aneurysm ruptures repaired using a transabdominal and a retroperitoneal approach, respectively. A combined endovascular and surgical approach was used for treatment of his thoracoabdominal aneurysm.[3] This was proposed in order to minimize the risks of conventional surgery in that particular case. We were reluctant to recommend CESA to patients with thoracoabdominal aortic pathology owing to our concerns about the durability and effectiveness of this hybrid procedure. After a four-year follow-up of our initial patient, and noting his excellent clinical course, we began considering CESA for high-risk patients presenting with thoraco-

Table III. Combined endovascular and surgical approach performed in two stages

Patient	*Age (years)*	*Indication*	*ASA class*	*Debranching details*	*Endograft proximal landing zone*	*Endograft distal landing zone*	*Perioperative complication (<30 days)*	*Follow up (months)*
5	68	6.7 cm Type III TAA	3	Resection of infrarenal AAA, placement of aortobi-iliac bypass graft, Right iliac-celiac-SMA bypass; right ileo-birenal bypass	Descending thoracic aorta	Distal infrarenal aortic graft	Small bowel obstruction requiring laparotomy; respiratory failure requiring reintubation	20
6	75	5 cm perivisceral AAA with symptomatic SMA stenosis	3	Right iliac-celiac-SMA bypass; right ileo-birenal bypass	Descending thoracic aorta	Prior infrarenal aortic graft	None	16
7	60	Type A + B aortic dissection with multiple aneurysmal aortic segments; maximal diameter 6.1 cm	2	Left iliac-celiac-SMA bypass; left ileo-birenal bypass	Descending thoracic aorta	Prior infrarenal aortic graft	None	6 Death – cause unknown No evidence of TAA rupture
10	89	7.1 cm Type III TAA, occlusion of celiac trunk and SMA, right common iliac aneurysm	3	Resection of infrarenal AAA; Placement of aortobi-iliac bypass graft, Right iliac-celiac-SMA bypass; right iliac-bi-renal bypass	N/A	N/A	None (Stage 1 only)	5 Death 5 mo after stage 1; stage 2 not done
11	59	7 cm aortic arch and descending thoracic aneurysm, infrarenal AAA, type B dissection	4	Right common carotid to left subclavian bypass; Division left CCA with proximal ligation and implantation to side of carotid to subclavian bypass Resection of infrarenal AAA, right iliac-celiac-SMA bypass, right ileo-birenal bypass	Aortic arch between innominate and left common carotid artery	Distal infrarenal aortic graft	Segmental iliac resection for intraoperative enterotomy during debranching procedure	11
13	51	6.0 cm Type III TAA with type B dissection	2	Resection of infrarenal aorta, placement of aortic tube graft, retrograde aorto-celiac-SMA bypass, retrograde aorto-bi-renal bypass, aorto-lumbar bypass	Descending thoracic aorta Endograft placed in false lumen	Distal prior aortic tube graft *Endograft placed in false lumen	Small bowel obstruction requiring laparotomy on postoperative day 17	6
18	59	6.5 cm Type II TAA	4	Retrograde aorto-celiac-SMA-Left renal artery bypass; right common iliac to right renal artery bypass	Aortic arch proximal to left subclavian artery	Distal infrarenal aorta	None	3

AAA, Abdominal aortic aneurysm; *ASA,* American Society of Anesthesiologists; *CCA,* common carotid artery; *CHF,* congestive heart failure; *ICA,* internal carotid artery; *MI,* myocardial infarction; *SMA,* superior mesenteric artery; *TAA,* thoraco-abdominal aneurysm.
*See Figure 1.

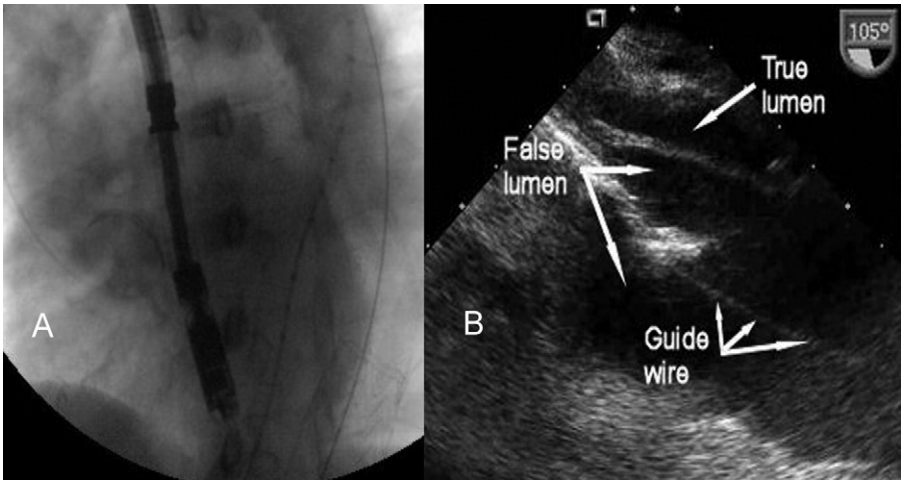

Fig 1. A, transesophageal echocardiography used during the second stage deployment of the endovascular grafts. **B**, in this particular case, the endograft was deployed in the false lumen as identified by the transesophageal echo, between the previously placed proximal descending thoracic aortic graft, and an infrarenal aortic graft placed during the first stage of the procedure.

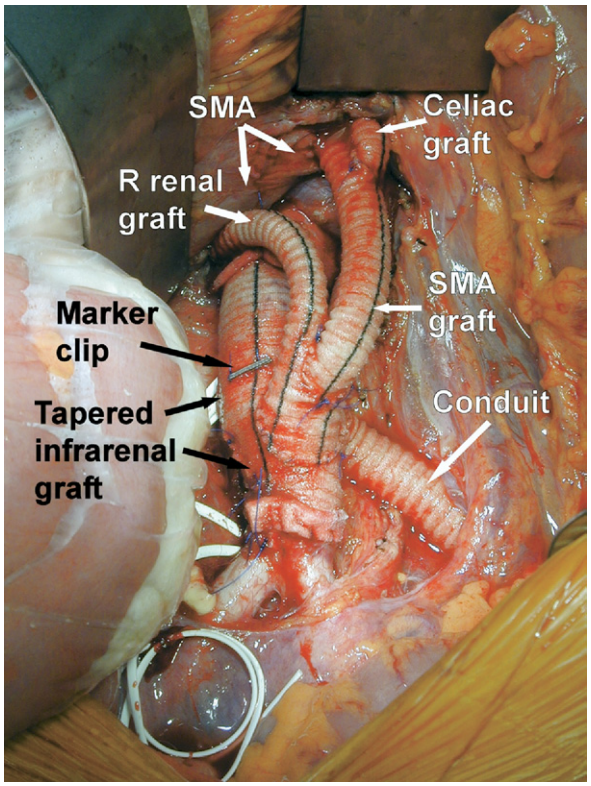

Fig 2. Intraoperative picture of a first stage procedure with retrograde grafts to both renal arteries, the superior mesenteric artery, and the celiac artery. Note the placement of a conduit that was left in the subcutaneous tissue and successfully used during the second stage. Marker clips are placed to help fluoroscopically identify the most distal landing site for the endografts during the second stage of the procedure. R, right; SMA, superior mesenteric artery.

abdominal aortic aneurysms. Our results with conventional surgery were acceptable,[4] and therefore we limited CESA for patients with significant comorbidities in whom conventional surgery would represent an unacceptable risk. Our results, to date, support using a combined approach for patients at high risk for conventional surgery.

Since 2004, there have been several series with 10 or more patients reported using a combined endovascular and surgical approach to thoracoabdominal aortic pathology. These are summarized in Table IV. In the series reported by Lee and colleagues, the first stage of the procedure was associated with significant morbidity and mortality (25%, 24%).[5] They noted, however, that for the entire series, there was no incidence of paraplegia. In patients completing both procedures, there were no deaths and the primary patency for the visceral grafts was 96% at a mean follow-up of eight months. Resch and associates reported that most of the morbidity and mortality of the hybrid procedures for thoracoabdominal aortic pathology in high-risk patients were associated with those who presented with rupture.[6] Black and coworkers reported a similar experience in patients who were operated urgently or emergently secondary to symptomatic or ruptured aneurysms.[7] Mortality for elective cases was 13%. None of the patients treated for ruptured aneurysms with a hybrid procedure survived. Based on this experience, the role of a hybrid approach for treatment of ruptured thoracoabdominal aneurysms seems limited.

Zhou and associates treated 31 patients using a hybrid approach for complex thoracoabdominal aneurysms in high risk patients.[8] Sixteen ascending and arch aneurysms and 15 thoracoabdominal aneurysms were successfully managed with a mortality of 3.2% and no incidence of paraplegia or stroke. At a mean follow-up of 16 months, there were two patients who died of unrelated causes, but there was no aneurysm enlargement and all remaining patients were

Table IV. Reported series of a combined endovascular and surgical approach to thoracoabdominal aortic pathology (10 or more patients)

Author (reference)	*Year*	*Patients*	*TAAA/arch*	*Mortality 30 days*	*Permanent paraplegia*	*Overall morbidity*	*Median follow up (months)*	*Survival*
Lee[5]	2005	17*	17/0	24%	0	25%	8	100%
Resch[6]	2006	13	13/0	23%	30%	46%	NA	NA
Black[7]	2006	22	22/0	13%	0	54%	8	NA
Zhou[8]	2006	31	15/16	3.2%	0	9.6%	16	90%
Chiesa[9]	2007	13#	13/0	23%	0	31%	14.9	76.9%
Bockler[10]	2008	28	28/0	14.3%	11%	59%	22	70%
Quinones	2008	20	17/3	0	6.6%	32%	16.6	76%+

*All staged procedures.
#Seven patients with aortic dissection.
+Cumulative survival.

asymptomatic. These results parallel our experience and support a hybrid approach in selected high-risk patients.

Chiesa and colleagues reported thirteen high-risk patients (all ASA class 3 or 4; all had prior aortic surgery) treated with a single-stage hybrid repair.[9] The authors compared the results in this group with a "similar" group of 29 patients within their series of patients having surgical treatment of thoracoabdominal aneurysms. Morbidity was slightly higher in the surgical group (44.8%) with three patients suffering paraplegia (10%) compared with one in the hybrid group (7%). Mortality was higher in the hybrid group (23% versus 17.2%), given that these patients were in a higher risk category. The authors concluded that the hybrid repair did not lead to significant improvement in outcome and that further follow-up and larger series were needed to evaluate this approach. The lower incidence of spinal cord complications in the hybrid group however, is encouraging. Given higher comorbidities in the hybrid group, these results suggest that a combined endovascular and surgical approach should be considered in selected patients.

Bockler and colleagues recently reported their experience on 28 patients treated with a hybrid approach for thoracoabdominal aortic aneurysm.[10] There were seven patients with concomitant aortic dissection. Elective mortality was 14.3% with an overall morbidity of 59%. Three patients suffered paraplegia. Graft patency at mean follow-up of 13 months was 86% and they found no significant difference between patients approached in a single stage and those undergoing a two-stage procedure. There was a significant difference in mortality noted between cases done on an emergency basis (28%) and those done on an elective basis (12%). Overall survival at three years was 70%. The authors were encouraged by their results and continue to recommend a hybrid approach for high-risk patients.

Given these mixed results reported in the literature, the role of a combined endovascular and surgical approach to thoracoabdominal aortic pathology remains ill defined. We have found that there are significant advantages to a hybrid approach in high-risk patients. Avoidance of a thoracotomy for repair of the thoracic component of the pathology is a significant benefit. The ability to stage the procedure in selected cases may reduce the overall morbidity.

Patients who become unstable or experience hypotension during the debranching portion of the procedure may be better off postponing the endovascular portion as a second stage. This will allow the system to recover, and normalize to the new flow pattern. The single case of paraplegia in our series was a patient with extensive thoracoabdominal aortic coverage performed in a single stage. In retrospect, a two-stage approach may have avoided this complication. An additional benefit of CESA may be related to limiting the visceral ischemia to one organ at that time. Avoidance of high aortic cross-clamping, and global visceral ischemia as is necessary during surgical repair, may contribute to a lower incidence of paraplegia and organ failure. In our series, there was no incidence of visceral organ failure during either single or a two-stage procedure.

When patients are approached in two stages, placement of a subcutaneous conduit to be used at the second stage simplifies the approach. We now routinely place the conduit at the first stage, which allows insertion of the endovascular graft with a simple cutdown. It is important to place the distal end of the conduit in a way that will not interfere with visceral flow during introduction of the endovascular graft. In addition, if the conduit is placed at the hood of the origin graft for visceral revascularization, care must be taken to observe sterile technique, as infection of this conduit would lead to serious consequences. Alternatively, the conduit may be placed in the contralateral common iliac artery, which would avoid this potential complications altogether. In a single stage approach, the conduit is ligated flush to its origin.

Placement of a marker clip proximal to the origin of visceral grafts, or distal to the origin of ascending aortic grafts has proven helpful during the endovascular component of the procedure. This will limit the amount of contrast needed, particularly in the single stage approach. Retrograde visceral graft coverage is also a key component of the hybrid approach. Care must be taken to avoid contact with intestines to prevent the potential long-term complications of graft enteric erosion. We routinely cover these grafts with surrounding retroperitoneal tissue or in some cases with an omental flap.

One of the potential drawbacks on the durability of a combined endovascular and surgical approach may relate to

the use of retrograde bypasses for visceral revascularization. Kansal and associates reported a retrospective review comparing antegrade and retrograde mesenteric bypasses.[11] The combined experience of two major vascular centers showed no difference in the long-term durability of these two options. In fact, they noted a lower mortality for the retrograde approach, probably related to the avoidance of supraceliac aorta cross clamping. In a review of published series of a combined endovascular and surgical approach for thoracoabdominal aortic pathology, long-term graft patency has been reported between 86% and 100%.[12] In our own series, we have not seen any complication related to the use of retrograde grafts for visceral revascularization, or antegrade grafts for cerebrovascular revascularization.

Our experience with CESA for arch aneurysms is limited. The largest experience reported to date is from Zhou and colleagues, with 16 patients having a hybrid approach for repair of aneurysms that included the ascending aorta and or aortic arch.[8] In eight patients, the endograft was placed in an antegrade fashion upon completion of the cerebrovascular debranching. There were no deaths, neurologic deficits, or significant morbidity associated with this approach. An additional eight patients had their grafts placed in a retrograde fashion as the aneurysms also involve the thoracoabdominal aorta. We have found that antegrade placement is better for aneurysms that involve landing the proximal end of the endograft in the ascending aorta. This is particularly important in patients with unfavorable curvature of the aortic arch. Using a conduit placed at the hood of the origin of the extra-anatomic bypasses, and a marker clip just distal to this origin, the endograft can be introduced and deployed with minimal contrast.

Patients presenting with chronic aortic dissection present particular challenges. We have found transesophageal echocardiography (TEE) very useful during the endovascular component of the repair. This helps identify the location of the guide wire in the true or false lumen so that appropriate deployment can be performed. An experienced anesthesiologist with TEE is important in the interpretation of the images. Intravascular ultrasound can also be used for this purpose. One of the advantages of TEE is that none of the access sites is used as it is when using intravascular ultrasound. No exchanges are necessary and therefore real-time views of the procedure and deployment are possible. In one of our cases, the endovascular graft was purposely deployed in the false lumen to allow maximum expansion of the endograft. This was a patient with a prior interposition graft in the proximal descending thoracic aorta, and an infrarenal aortic graft placed at the first stage of the procedure. The endovascular repair at the second stage had the proximal landing zone in the previously placed thoracic interposition graft and distally, in the recently placed infrarenal graft. In most instances, however, deployment in the true lumen is mandatory.

The mid- and long-term results in our experience with CESA have been encouraging, recognizing that most of the patients have relatively short follow-up. Overall survival at two years by cumulative methods in patients completing the procedure was 76%. This compares well with survival after surgical repair.[13,14] Importantly, there has been no aneurysm-related death, and graft patency has not been an issue. Our longest survivor has been followed for 10 years with no aneurysm growth or procedure related complication (Fig 3). This suggests that a combined endovascular and surgical approach to thoracoabdominal aortic pathology can be durable. All deaths have occurred within six months of the procedure. One patient died from aneurysm rupture after refusing to undergo the second stage of the procedure. It is imperative that patients, in whom a two-stage approach is planned, are informed that the first stage of the procedure is a major surgical intervention and can expect a much easier recovery after the second stage. Three of the four deaths occurred in patients that had major complications following the procedure. Two of these patients had history of congestive heart failure (two) and renal insufficiency (one), and the third had severe chronic obstructive pulmonary disease (COPD) and was oxygen-dependent. One could question the judgment of proceeding with any type of repair in patients with such comorbidities. The reality is that, faced with an individual patient, this is an extremely difficult decision to make. The last patient died of unknown causes but the history surrounding the death suggests that it was not aneurysm or procedure related.

Fig 3. Computed tomography (CT) scan with three-dimensional reconstruction 10 years after endovascular and surgical repair of a type IV thoracoabdominal aneurysm performed in 1998 and reported in 1999 (see text).

In conclusion, a combined endovascular and surgical approach to thoracoabdominal aortic pathology can be performed with acceptable results in high-risk patients. We prefer a two-stage approach for patients that require extensive aortic coverage, or who become unstable during the debranching stage of the procedure. In a two-stage approach, placement of a subcutaneous conduit and marker clips facilitates the endovascular portion of the procedure. Transesophageal echocardiography is a useful tool during the endovascular component in patients with aortic dissection. Our experience to date suggests that the hybrid approach can be a durable repair. Given the limited follow-up available, however, younger patients with acceptable risk should continue to be treated with conventional surgery. Our results support the continued use of a combined endovascular surgical approach to thoracoabdominal aortic pathology in high-risk patients.

AUTHOR CONTRIBUTIONS

Conception and design: WQ
Analysis and interpretation: WQ
Data collection: JJ
Writing the article: WQ
Critical revision of the article: WQ
Final approval of the article: WQ
Statistical analysis: WQ
Obtained funding: WQ
Overall responsibility: WQ

REFERENCES

1. Walsh SR, Tang TY, Sadat U, Naik J, Gaunt ME, Boyle JR, et al. Endovascular stenting versus open surgery for thoracic aortic disease: systematic review and meta-analysis of perioperative results. J Vasc Surg 2008;47:1094-8.
2. Chuter TA. Branched and fenestrated stent grafts for endovascular repair of thoracic aortic aneurysms. J Vasc Surg 2006;43:111A-5A.
3. Quinones-Baldrich WJ, Panetta TF, Vescera CL, Kashyap VS. Repair of type IV thoracoabdominal aneurysm with a combined endovascular and surgical approach. J Vasc Surg 1999;30:555-60.
4. Quinones-Baldrich WJ. Descending thoracic and thoracoabdominal aortic aneurysm repair: 15-year results using a uniform approach. Ann Vasc Surg 2004;18:335-42.
5. Lee WA, Brown MP, Martin TD, Seeger JM. Early results after staged hybrid repair of thoracoabdominal aortic aneurysms. J Am Coll Surg 2007;2005:420-31.
6. Resch TA, Greenburg RK, Lyden SP, Clair DG, Krajewski L, Kashyap VS, et al. Combined staged procedures for the treatment of thoracoabdominal aneurysms. J Endovasc Ther 2006;13:481-9.
7. Black SA, Wolfe JH, Clark M, Hamady M, Cheshire NJ, Jenkins MP. Complex thoracoabdominal aortic aneurysms: endovascular exclusion with visceral revascularization. J Vasc Surg 2006;43:1081-9.
8. Zhou W, Reardon M, Peden EK, Lin PH, Lumsden AB. Hybrid approach to complex thoracic aortic aneurysms in high-risk patients: surgical challenges and clinical outcomes. J Vasc Surg 2006;44:688-93.
9. Chiesa R, Melissano G, Civilini E, Setacci F, Tshomba Y, Anzuini A. Two-stage combined endovascular and surgical approach for recurrent thoracoabdominal aortic aneurysm. J Endovasc Ther 2004;11:330-3.
10. Bockler D, Kotelis D, Geisbusch P, Hyhlik-Durr A, Klemm K, Tengg-Kobligk HV, et al. Hybrid procedures for thoracoabdominal aortic aneurysms and chronic aortic dissections - A single center experience in 28 patients. J Vasc Surg 2008;47:724-32.
11. Kansal N, LoGerfo FW, Belfield AK, Pomposelli FB, Hamdan AD, Angle N, et al. A comparison of antegrade and retrograde mesenteric bypass. Ann Vasc Surg 2002;16:591-6.
12. Donas KP, Czerny M, Guber I, Teufelsbauer H, Nanobachvili J. Hybrid open endovascular repair for thoracoabdominal aortic aneurysms: Current status and level of evidence. Eur J Vasc Endovasc Surg 2007;34:528-33.
13. Coselli JS, Conklin LD, LeMaire SA. Thoracoabdominal aortic aneurysm repair: Review and update of current strategies. Ann Thorac Surg 2002;74:S1881.
14. Safi HJ, Miller CC 3rd, Huynh TT, Estrera AL, Porat EE, Winnerkvist AN, et al. Distal aortic perfusion and cerebrospinal fluid drainage for thoracoabdominal and descending thoracic aortic repair: Ten years of organ protection. Ann Surg 2003;238:372-80.

Submitted Sep 9, 2008; accepted Dec 2, 2008.