

## CASE REPORT

# Urogynecologic complications in Stevens-Johnson syndrome and toxic epidermal necrolysis: Presentation of a case and recommendations for management



Tatyana A. Petukhova, MD, MS, Emanuel Maverakis, MD, Baran Ho, MD, and Victoria R. Sharon, MD, DTMH  
Sacramento, California

**Key words:** Stevens-Johnson syndrome; topical corticosteroids; toxic epidermal necrolysis; vulvovaginal disease.

## CASE REPORT

A 28-year-old gravida 2, para 1 female presented at 10 weeks' gestation to the burn unit with 30% body surface area of full-thickness erosions and flaccid bullae on the face, trunk, extremities, and mucosal surfaces including the eyes, mouth, and vagina (Fig 1, A and B). Her symptoms began 2 days prior with stinging and swelling of the eyes and lips that quickly progressed to generalized erythema and subsequent blister formation and desquamation. Associated symptoms included headache, malaise, and fever up to 39.4°C.

Skin biopsy found vacuolar alteration and necrotic keratinocytes along the dermal-epidermal junction and sparse lymphocytic infiltrate, confirming the suspected diagnosis of toxic epidermal necrolysis (TEN) (Fig 1, C).

Her medical history was significant for culture-positive group A  $\beta$ -hemolytic streptococcal pharyngitis that was treated with a 10-day course of penicillin V potassium (500 mg twice daily) approximately 1 month before to the onset of her rash. At the time of presentation, she was taking a multivitamin and fish oil. Her laboratory serology results were negative for herpes simplex virus, human immunodeficiency virus, and mycoplasma pneumonia. Although her symptoms were potentially attributed to penicillin, it is unusual for TEN to occur 4 weeks after discontinuation of a medication with a short half-life. Thus, an altered immunologic state owing to pregnancy was

### Abbreviations used:

SCORTEN: severity-of-illness score for toxic epidermal necrolysis  
SJS: Stevens-Johnson syndrome  
TEN: toxic epidermal necrolysis

also considered as a potential trigger for her Stevens-Johnson syndrome (SJS)/TEN.<sup>1</sup>

Upon admission, she received a 1-time administration of methylprednisolone (125 mg) and intravenous immunoglobulin (1 mg/kg). Her severity-of-illness score for toxic epidermal necrolysis (SCORTEN)-based mortality risk was 3.2% (SCORTEN: 1 for >10% detached or compromised body surface), and further treatment consisted of supportive therapy with fluid resuscitation, opioid pain control, and topical wound care with bacitracin ointment. On the third day of hospitalization, the ophthalmology department transplanted amniotic membranes to prevent scarring of the ocular surfaces.

One week after admission, she was noted to have extensive desquamation and erosions of the perineum. Two weeks after admission, she was complaining of increased perineal pain and burning sensation. Pelvic examination found horizontal perineal strictures, fusion of the labia majora, minora, and clitoral hood, and a complete circumferential transverse vaginal stricture 2 cm from the introitus

From the Department of Dermatology, University of California, Davis.

Funding sources: None.

Conflicts of interest: None declared.

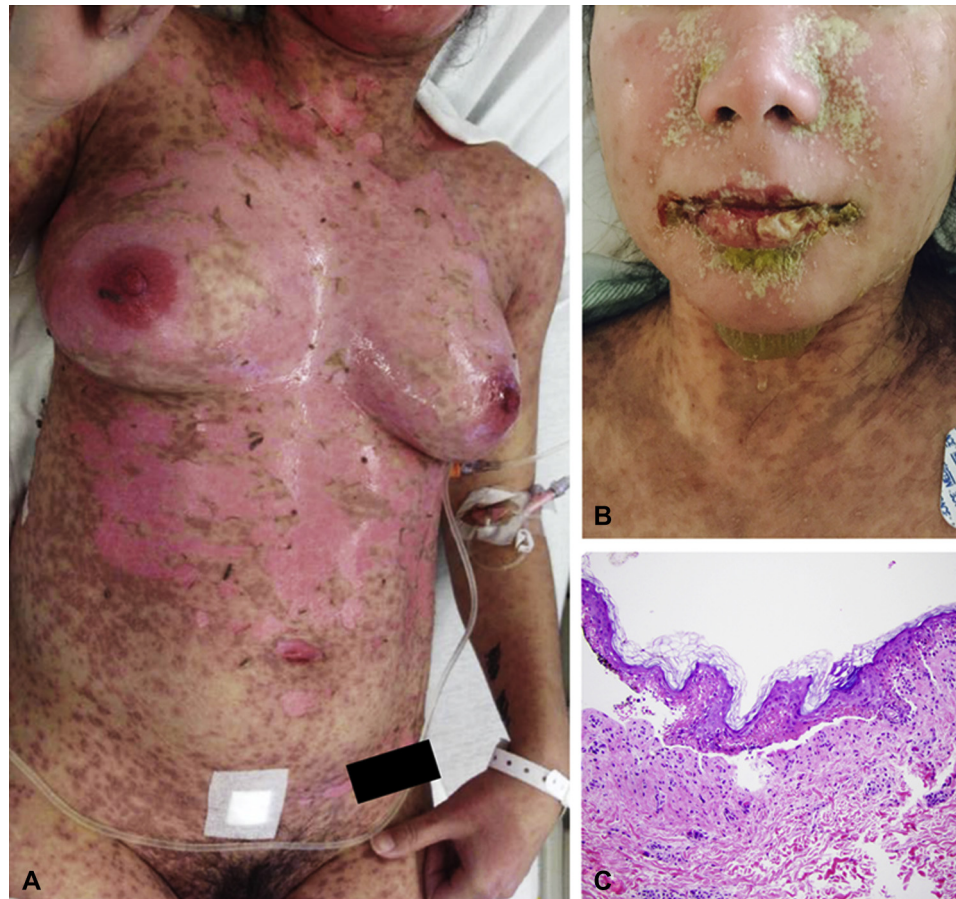Correspondence to: Victoria R. Sharon, MD, DTMH, Director, Dermatology Inpatient Consultation, Assistant Professor of Dermatology & Dermatologic Surgery, Department of Dermatology, University of California Davis Health System, 3301 C Street, Suite 1400, Sacramento, CA 95816. E-mail: [VRS2001@gmail.com](mailto:VRS2001@gmail.com).

JAAD Case Reports 2016;2:202-5.

2352-5126

© 2016 by the American Academy of Dermatology, Inc. Published by Elsevier, Inc. This is an open access article under the CC BY-NC-ND license (<http://creativecommons.org/licenses/by-nc-nd/4.0/>).

<http://dx.doi.org/10.1016/j.jidcr.2016.03.006>



**Fig 1.** **A** and **B**, A 28-year-old woman on presentation with greater than 30% body surface area of full-thickness erosions and flaccid bullae on the face, trunk, extremities, and mucosal surfaces including the eyes, mouth, and groin. **C**, Hematoxylin-eosin–stained biopsy from the lower abdomen with vacuolar interface dermatitis, prominent keratinocyte necrosis, and preservation of the cornified layer consistent with TEN.

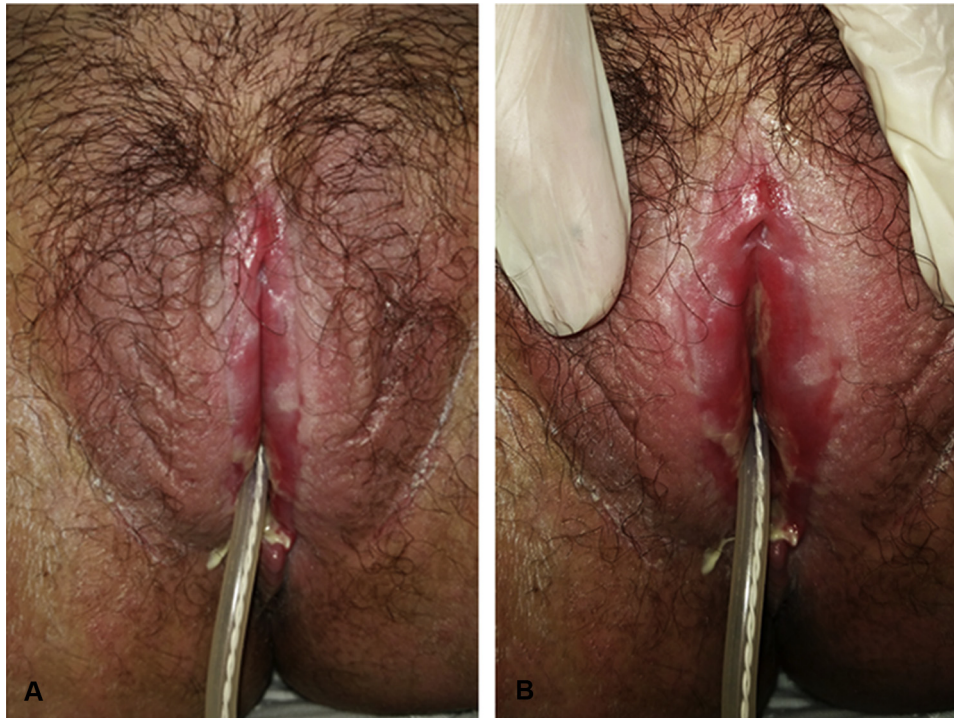
that precluded further digital and speculum examinations (Fig 2, A and B).

To prevent complete fusion of the vagina, vaginal packing and dilators were commenced with zinc oxide application to erosions in the perineum. She had significant pain with dilator insertion that was improved with topical lidocaine jelly. Because of clitoral hood involvement and concern for adhesion formation near the urethra, her Foley catheter remained in place until the perineal area was fully re-epithelialized.

She was discharged from the hospital after 4 weeks of supportive therapy. Additional sequelae noted after discharge included progressive shortness of breath with obstructive lung disease, dysphagia with esophageal stenosis, and trichiasis with associated epiphora. Her pulmonary symptoms gradually improved with inhaled corticosteroids. She continued to have perineal discomfort and used vaginal dilators 2 times daily as tolerated.

Her pregnancy progressed without fetal complications and she delivered a healthy boy by cesarean section at 39 weeks' gestation. Her intrapartum vaginal examination found a foreshortened vagina approximately 2 cm from the introitus, similar to an imperforate hymen. A Hagar dilator was inserted into the vagina, and the adhesions were lysed.

She discontinued the use of vaginal dilators 1 week postpartum and recurrent symptomatic vaginal stenosis and persistent vaginal discharge developed. She has since undergone several procedures including blunt dissection and surgical excision of adhesions. At 4 months postpartum, current management consists of continuous intravaginal Foley catheterization to maintain patency of the vaginal opening, nightly use of a vaginal stent with estrogen cream, and daily placement of a vaginal dilator with lidocaine jelly as tolerated.



**Fig 2. A and B,** Two weeks after admission, the patient had horizontal perineal strictures, agglutination of the labia and clitoral hood, and a complete circumferential transverse vaginal stricture 2 cm from the introitus.

## DISCUSSION

SJS and TEN are overlapping cutaneous drug reactions differing in extent of body surface area of epidermal detachment. The clinical presentation is characterized by potentially fatal mucocutaneous erythema, tenderness, and exfoliation caused by a dermal-epidermal interface dermatitis with resulting apoptosis of keratinocytes. Erythema of the oral, ocular, and genital mucosa is present in greater than 90% of cases. In one retrospective case series of female TEN patients, 70% of women had vulvovaginal lesions ranging from superficial vulvar erosions to extensive vaginitis with ulceration and bullae formation. Up to 28% of those women suffered from long-term symptomatic sequelae of the lower genital tract including burning sensation, dyspareunia, and postcoital bleeding resulting from varying degrees of vaginal adhesions and stenosis.<sup>2</sup> Pediatric cases of SJS/TEN have also been reported in which patients likely had severe vulvar scarring and labial agglutination early in the course of recovery.<sup>3</sup> However, gynecologic sequelae of SJS/TEN are often not detected until after the acute phase of disease has ended, thus, limiting treatment options of complications to primarily surgical interventions.<sup>3</sup> The mechanism for mucosal scarring is likely related to denuded surfaces adhering during the healing

phase, resulting in loss of normal vaginal structure and formation of scars. Thus, there is potential for improvement with early intervention. Importantly, scars can continue to mature for up to a year after injury,<sup>4</sup> so a successful treatment plan should include long-term follow-up and longitudinal management strategies.

Several measures have been proposed to protect vaginal function and prevent adhesion formation. Given their documented success in other inflammatory vaginal disorders (eg, erosive lichen planus and Sjögren's syndrome), prophylactic vaginal dilation and topical corticosteroids have been promoted as first-line therapy at time of initial presentation and then daily until complete re-epithelialization.<sup>5,6</sup> Administration of topical corticosteroids in ophthalmology has shown a decrease in the incidence of ocular cicatrization and vision loss.<sup>7</sup> Topical corticosteroids have not been prospectively studied specifically for mucosal involvement of the genital tract in SJS/TEN; however, there is a current ongoing randomized, controlled clinical trial evaluating the safety and efficacy of topical clobetasol 0.05% ointment for cutaneous involvement.<sup>8</sup>

In our experience, once-formed, significant vulvovaginal scarring and stenosis are difficult to manage, even with appropriate surgical intervention.

As highlighted by this case report, long-term daily use of a vaginal dilator may be required to prevent recurrences. Given the high morbidity associated with gynecologic adhesions and the relatively low risk of complications associated with topical steroid application and mechanical vaginal dilator insertion, we recommend early initiation of these interventions. Gynecologic examination of all individuals with SJS/TEN, including the pediatric population, is imperative to facilitate early identification of genital ulcerations and adhesions. This may require a pelvic examination under anesthesia, which would also facilitate immediate adhesiolysis. Specifically, if genital mucosal exfoliation is evident, we recommend twice-daily application of a high potency corticosteroid ointment to the perineum externally followed by petroleum gauze to prevent contact between adjacent eroded mucosal surfaces. In addition, soft silicone vaginal molds (ie, Milex dilator) or inflatable vaginal dilators coated with high-potency corticosteroids can be inserted daily for up to 24 hours to prevent fibrous band formation until complete re-epithelialization of ulcerated surfaces.<sup>6</sup>

The morbidity associated with TEN-associated gynecologic scarring is extreme and may include difficulties with menstruation, intercourse, and labor later in life.<sup>4</sup> A multidisciplinary cooperative effort focused on preventative measures used early in the acute

phase of SJS/TEN by dermatologic, gynecologic, ophthalmologic, and burn unit staff will likely yield the best treatment outcomes in female patients with SJS/TEN.

#### REFERENCES

1. Struck MF, Illert T, Liss Y, Bosbach ID, Reichelt B, Steen M. Toxic epidermal necrolysis in pregnancy: case report and review of the literature. *J Burn Care Res.* 2010;31:816-821.
2. Meneux E, Wolkenstein P, Haddad B, Roujeau JC, Revuz J, Paniel BJ. Vulvovaginal involvement in toxic epidermal necrolysis: a retrospective study of 40 cases. *Obstet Gynecol.* 1998;91:283-287.
3. Hart R, Minto C, Creighton S. Vaginal adhesions caused by Stevens-Johnson syndrome. *J Pediatr Adolesc Gynecol.* 2002;15:151-152.
4. Pliskow S. Severe gynecologic sequelae of Stevens-Johnson syndrome and toxic epidermal necrolysis caused by ibuprofen: a case report. *J Reprod Med.* 2013;58:354-356.
5. Amankwah YA, Haefner HK, Brincat CA. Management of vulvovaginal strictures/shortened vagina. *Clin Obstet Gynecol.* 2010;53:125-133.
6. Kaser DJ, Reichman DE, Laufer MR. Prevention of vulvovaginal sequelae in stevens-johnson syndrome and toxic epidermal necrolysis. *Rev Obstet Gynecol.* 2011;4:81-85.
7. Araki Y, Sotozono C, Inatomi T, et al. Successful treatment of Stevens-Johnson syndrome with steroid pulse therapy at disease onset. *Am J Ophthalmol.* 2009;147:1004-1011, 1011.e1.
8. Wilken R, Li CS, Sharon VR, et al. Topical clobetasol for the treatment of toxic epidermal necrolysis: study protocol for a randomized controlled trial. *Trials.* 2015;16:374.