


Available online at
 ScienceDirect
 www.sciencedirect.com

Elsevier Masson France
 EM|consulte
 www.em-consulte.com



SURGICAL TECHNIQUES

Acute compartment syndrome of the leg: Pressure measurement and fasciotomy

A.-C. Masquelet

Orthopedics-Traumatology Dept, Avicenne Hospital, 125, route de Stalingrad, 93000 Bobigny, France

Accepted: 21 June 2010

KEYWORDS

Compartment syndrome;
 Intracompartmental pressure;
 Fasciotomy

Summary Compartment syndrome involves a conflicting situation between an unyielding space, the compartment, and its increasing tissue content secondary to traumatic ischemia. Rapidly irreversible damages occur without treatment. Although the diagnosis approach to leg compartment syndrome is clinical in priority, pressure measurements should be systematically produced: first to confirm the presence of this condition and define optimal surgical strategies and second to provide the only objective available criteria in case of a debatable diagnosis. In practice, two schematic situations can be distinguished, which do not cover the many different cases: leg compartment syndrome without a fracture in which the four leg compartments are affected and which requires a fasciotomy using two surgical approaches, the lateral and the medial; leg compartment syndrome associated with a fracture: fasciotomy of the four compartments may be performed by a single lateral approach distant from the fracture site and its fixation hardware. It should be noted that this approach is easy, effective and safe.

© 2010 Published by Elsevier Masson SAS.

Introduction

Leg compartment syndrome consists in the conflict between a non-extendable container, the compartment, and contents increasing in volume secondary to injury of ischemic origin.

Any trauma, including simple surgery, induces hyperpressure exerted on the compartment's contents by edema and bleeding, however slight. In the vast majority of cases, this will not reach the threshold in terms of duration and intensity for a compartment syndrome characterized by lesions, which rapidly become irreversible in the absence of appropriate treatment. The difficulty of diagnosis, indeed, lies precisely in the fact that there are countless situations in

which transitory hyperpressure shows spontaneous regression. The only way to be sure of avoiding a missed diagnosis is to bear in mind that any trauma or surgery to the extremities causes local hyperpressure that may culminate in a true compartment syndrome. This is all the more true of the leg, the compartments of which are anatomically and functionally clearly defined (Fig. 1A, B).

Diagnosis is based on the following cardinal signs:

- unusually strong patient complaint;
- tension and pain on palpation of the compartment;
- positive passive muscle-stretching maneuver;
- and paresis in an appropriate territory.

Pressure should be systematically measured, for three reasons:

E-mail address: alain-charles.masquelet@avc.aphp.fr.

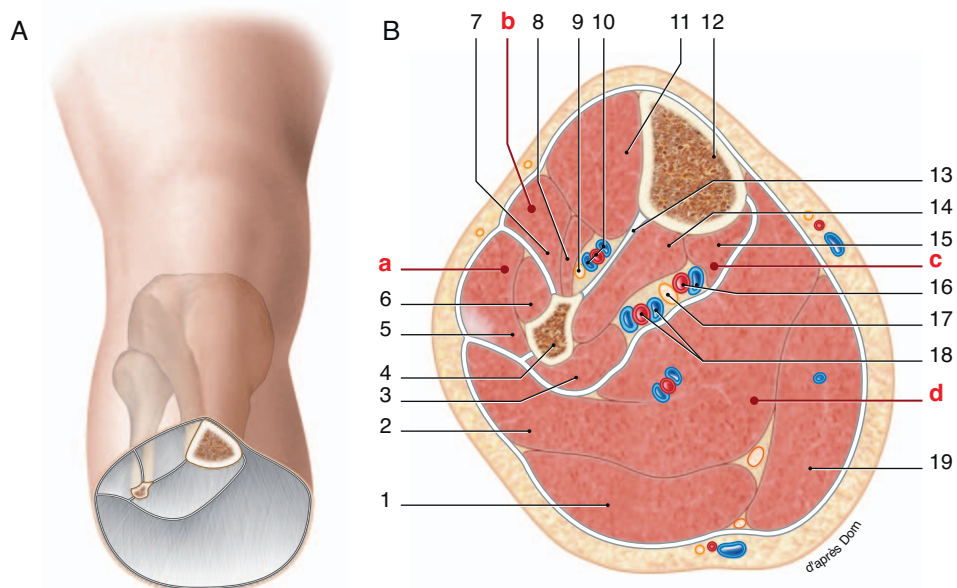


Figure 1 A. The four-muscle compartments of the leg. B. Contents of the four compartments: 1: gastrocnemius medialis muscle; 2: soleus muscle; 3: flexor hallucis longus; 4: fibula; 5: peroneus longus; 6: peroneus brevis; 7: extensor digitorum longus; 8: extensor hallucis longus; 9: anterior tibial nerve; 10: anterior tibial artery and veins; 11: anterior tibialis muscle; 12: tibia; 13: Interosseous membrane; 14: posterior tibialis muscle; 15: flexor digitorum longus; 16: posterior tibial artery and veins; 17: posterior tibial nerve; 18: peroneal artery and veins; 19: gastrocnemius lateralis; a: lateral compartment; b: anterior compartment; c: deep posterior compartment; d: superficial posterior compartment.

- to confirm clinical diagnosis, by differential rather than intratissue pressure: when diastolic P minus tissue P is less than 30 mmHg, there is a compartment syndrome and indication for surgery;
- pressure reading is the sole objective element and, as such, is essential in from a legal point of view;
- pressure reading initiates treatment, as much as it identifies the affected compartments. Frequently, critical hyperpressure does not involve all four-leg compartments simultaneously; pressure reading in each compartment refines indications for localized fasciotomy and, particularly, defines the surgical approach – which is an essential point in case of associated fracture.

In case of fracture, the anterior and deep posterior compartments (DPC) are the most subject to hyperpressure, being in direct contact with the fracture site.

Intracompartment pressure reading

Pressure is read using a dedicated meter; the old 3-tube set-up, which used to be widely employed, is no longer recommended, being inexact and difficult to use.

The pressure meter consists of a recording box with battery, switch and numerical display, and a single-use set comprising a syringe of physiological saline with needle and a pressure transmitter (Fig. 2A, B).

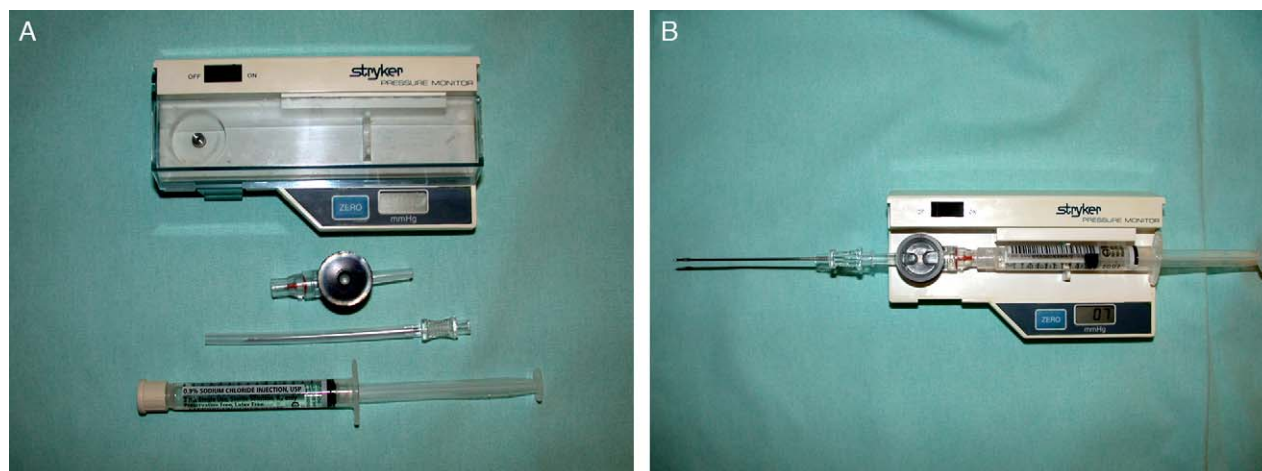


Figure 2 Pressure meter. A. The two meter components: box and sterile single-use kit. B. Meter ready for use.

The procedure consists in inserting the needle into a muscle compartment, taking care to penetrate the fascia, and injecting 1–2 cm³ of saline. In a normal compartment, the pressure shown will be less than 10 mmHg. In case of hyper-pressure, the operator can feel resistance against the piston of the syringe, and the pressure displayed will be above 30 mmHg.

A basic understanding of anatomy is enough to be able to guide the needle into the anterior, lateral or superficial posterior compartments; the DPC, on the other hand, is less readily accessible. Isolated or associated DPC syndrome is still too often overlooked, and its specific sequelae wrongly attributed to prolonged immobilization or insufficient rehabilitation. DPC pressure is read by inserting the needle strictly frontally in the lower third of the limb at the posteromedial tibial crest, avoiding the posterior tibial vasculo-nervous axis.

In practice, two situations can be distinguished, without exhausting all of the possible cases:

- leg compartment syndrome without fracture;
- leg compartment syndrome, either primarily associated with fracture or identified during fracture surgery.

Skin status is an essential consideration in tracing the incisions. The severity of the lesions associated with the trauma and their prognosis are to be assessed, as well as the degree of suffering caused by the compartment syndrome as such and the residual suppleness of the skin covering which will be relevant to closure.

Compartment syndrome without fracture

This situation is generally associated with upstream arterial ischemia or crushing trauma. All four compartments are involved (Fig. 3). The most reliable technique uses two approaches:

The lateral approach is traced vertically halfway between the anterior tibial and lateral fibular crests, so as to be approximately in front of the intermuscular septum along the entire leg segment. The skin incision extends from the proximal knee joint to the dorsal retinacular ligament of the ankle (Fig. 4). Limited suprafascial detachment enables the septum separating the lateral and anterior compartments to be located, in the form of a whitish line with fatty lobules above; it can also be palpated by the finger. Once the two compartments have been located, fasciotomy is performed on the whole of each. Certain precautions are to be observed. A lancet knife should be used rather than scissors, which risk increasing the muscle segment by accidental sectioning of some fibers (Fig. 5). In the lower third of the limb, it is important to keep the superficial peroneal nerve, which crosses the fascia at a variable height, becoming subcutaneous in the lower part of the leg and in the foot.

The medial approach is vertical, to the side of the posteromedial tibial crest. In the lower third of the limb, incision is halfway between the posterior edge of the tibia and the Achilles tendon, and may be extended by a medial retromalleolar incision to release the tarsal canal in case of posterior tibial nerve involvement (Fig. 6).

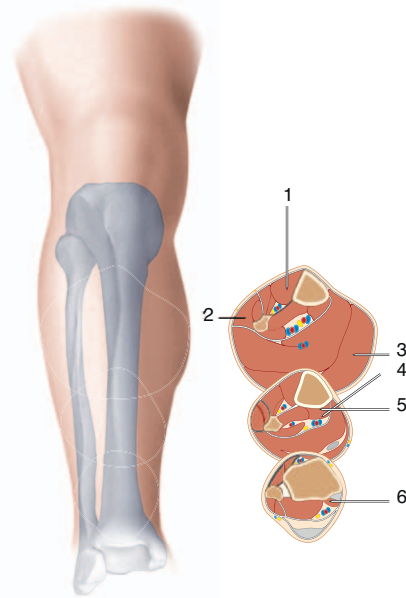


Figure 3 Needle position in each compartment. 1: anterior compartment; 2: lateral compartment; 3: superficial posterior compartment; 4 and 5: faulty DPC positioning, threatening the posterior tibial bundle; 6: needle position in DPC in mid-third and distal third of the leg.

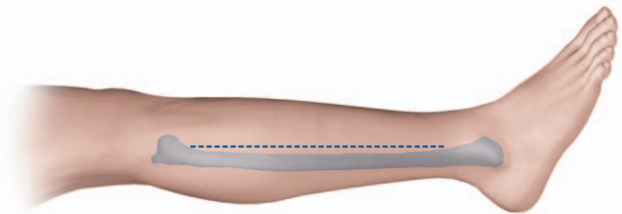


Figure 4 Lateral incision.

Fasciotomy begins with the crural fascia of the superficial posterior compartment. Then, in the distal two-thirds of the incision, the Achilles tendon and lower part of the soleus are drawn back to expose the deep septum partitioning the DPC

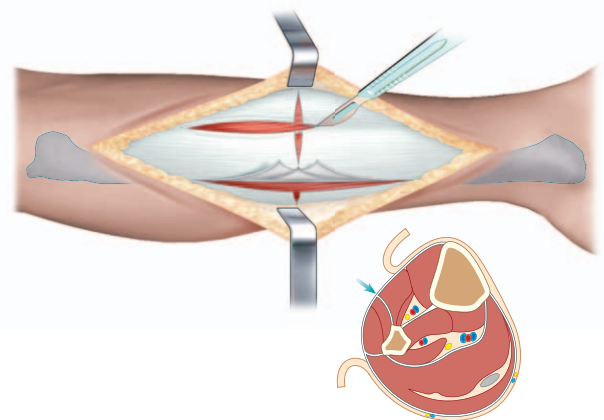


Figure 5 Location of septum between anterior and lateral compartments. Fasciotomies.

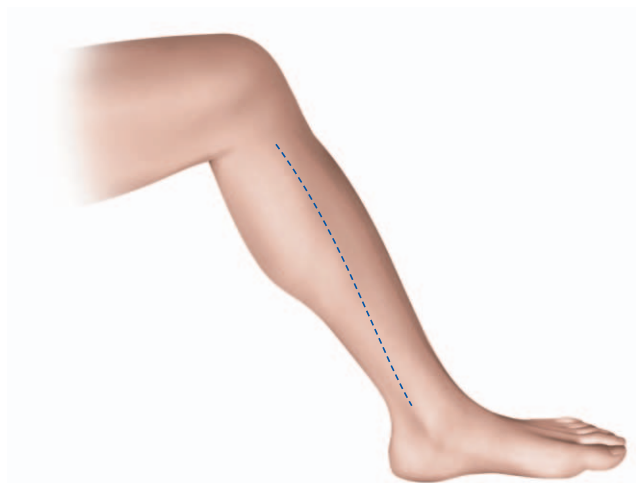

Figure 6 Medial incision.

(Fig. 7). DPC fasciotomy should use a lancet knife, under careful visual control due to the proximity of the posterior tibial vasculo-nervous bundle. The risk is of accidental sectioning of an arteriole feeding the distal soleus. DPC fasciotomy extends from the malleolus to the union of the proximal third and distal two-thirds of the leg.

Skin closure is generally impossible and not to be attempted. As compartment volume decreases postoperatively, the most straightforward means of progressive closure is continuous suture over skin staples (Fig. 8).

Compartment syndrome with associated fracture

Whether fracture fixation is internal or external, the key point in managing compartment syndrome is to avoid exposure of the fracture site and material. Fasciotomy of the four

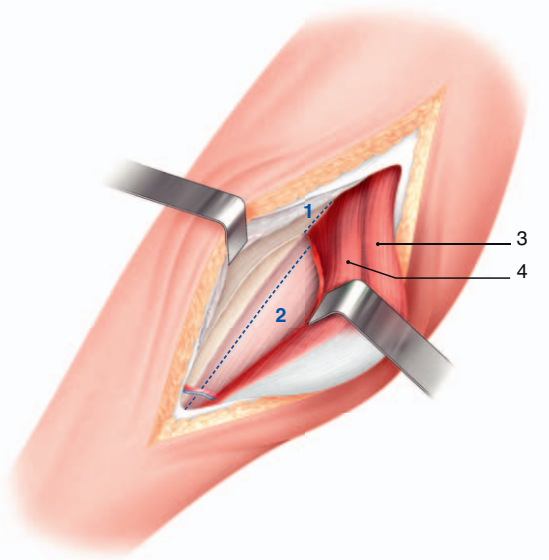


Figure 7 Superficial posterior fasciotomy completed. With-drawal of the soleus enables DPC fasciotomy.

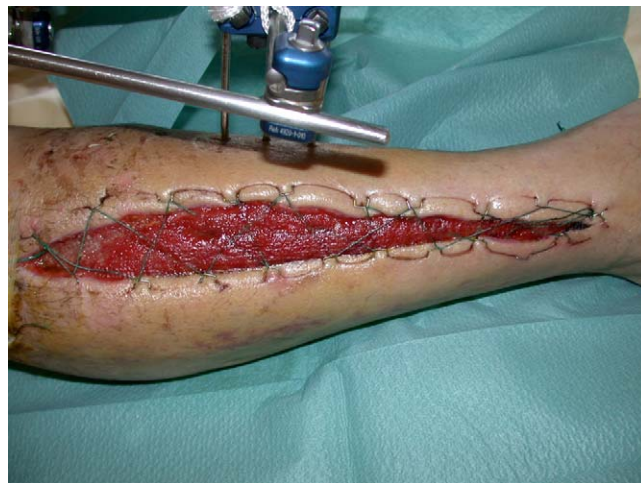

Figure 8 Progressive skin closure by continuous sutures on staples.

compartments may therefore use a single lateral approach, remote from the fracture site and material.

The approach is traced facing the anterior edge of the fibula, extending from the neck of the fibula to the flare of the lateral malleolus (Fig. 9). The anterior side of the incision is detached at the fascia to

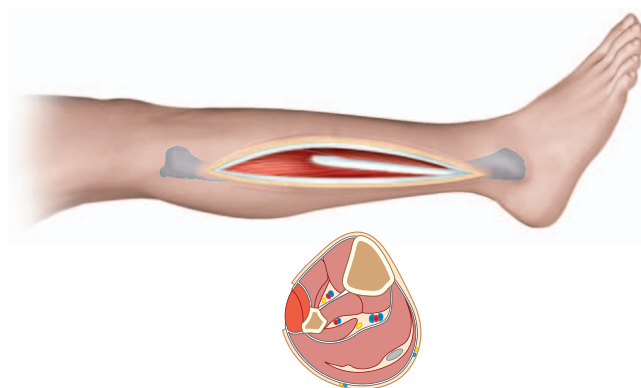


Figure 9 Single lateral incision exposing lateral compartment.

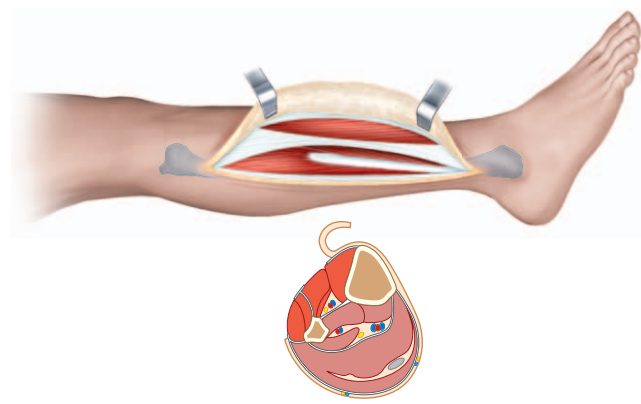


Figure 10 Anterior edge of incision is detached to expose the anterior compartment; anterior and lateral compartment fasciotomy is performed.

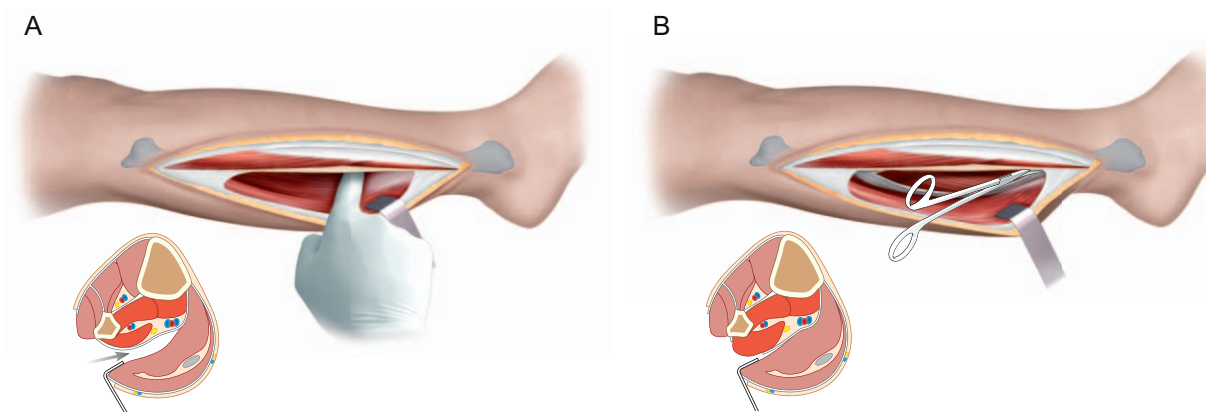


Figure 11 Detachment of posterior skin border, exposing the superficial posterior compartment (A) for fasciotomy. Then the lateral edge of the soleus is drawn back to expose the DPC (B) for the final fasciotomy.

expose the anterior compartment. The septum between the two compartments is located as above. Anterior and lateral compartment fasciotomy is performed, respecting the superficial peroneal nerve in the distal part of the incision (Fig. 10).

The posterior side of the incision is then detached behind the fibula, exposing the more lateral part of the superficial posterior compartment, which here includes the soleus. Extensive superficial posterior compartment fasciotomy is then performed (Fig. 11).

The DPC is exposed by dividing the space between the soleus and peroneal muscles, drawing the soleus back. DPC fasciotomy is performed using a lancet knife, respecting the tibial nerve, which is the most lateral element in the vasculo-nervous bundle. The peroneal vessels are protected by the flexor hallucis longus. The fibular fracture site is covered by approximating the two muscle masses; the cutaneous edges are progressively brought together by continuous suture over staples.

Special case

Compartment syndrome associated with primary fracture, not involving all leg compartments.

The problem in this case is to succeed in combining fracture site osteosynthesis, fasciotomy or fasciotomies, and postoperative cover of the fracture site and osteosynthesis material. Here, pressure reading enables approaches and elective fasciotomies to be specified. The two compartments most likely to be involved are the anterior and DPC. A long, slightly curved incision centered on the tibia enables, in a single operation:

- fracture site reduction;
- plate osteosynthesis;
- elective anterior compartment fasciotomy, detaching the anterior side of the incision. The fascia is incised on the anterior gastrocnemius relief, just at the lateral side of the tibia, to avoid lesion of the cutaneous pedicles of the anterior tibial artery;
- elective DPC fasciotomy, after dividing the space between the DPC and the distal soleus. The key point in this technique is mandatory skin closure, which entails rigorous preoperative assessment of skin cover; if the skin proves too tight for direct closure, a lateral release incision can be made on the anterior side of the fibula, but must be purely cutaneous, enabling the edges of the main incision to be approximated.

Conclusion

Leg compartment syndrome shows more varied symptomatology than described in the textbooks, and special attention should be paid to DPC syndrome, especially when isolated. Clinical examination is certainly of prime importance to diagnosis, but systematic pressure reading serves as confirmation, determines the surgical approach and provides the only objective data in case of conflict. Technically, a single lateral approach is to be recommended for its simplicity, efficacy and safety, avoiding any threat to the fracture site and internal osteosynthesis material.

Conflict of interest statement

The author has no conflict of interest.