



# Malignant nerve sheath tumor involving glossopharyngeal, vagus and spinal nerve with intracranial-extracranial extension and systemic metastases in a patient with type 1 neurofibromatosis: A case report



José Raúl Guerra-Mora<sup>a,b,\*</sup>, Juan D. Del Castillo-Calcáneo<sup>a,b</sup>,  
María Elena Córdoba-Mosqueda<sup>a,b</sup>, Jorge Yáñez-Castro<sup>a,b</sup>, Ulises García-González<sup>a,b</sup>,  
Eduardo Soriano-Navarro<sup>d</sup>, Leticia Llamas-Ceras<sup>c</sup>, Rosa María Vicuña-González<sup>c</sup>

<sup>a</sup> Neurosurgery, National Autonomous University of Mexico (UNAM), Mexico City, Mexico

<sup>b</sup> Neurosurgery Department, Mexican Oil Company (Pemex) High Specialty Hospital, Mexico City, Mexico

<sup>c</sup> Pathology Department, Mexican Oil Company (Pemex) High Specialty Hospital, Mexico City, Mexico

<sup>d</sup> Mexican School of Medicine, La Salle University, Mexico City, Mexico

## ARTICLE INFO

### Article history:

Received 27 September 2016

Accepted 27 October 2016

Available online 5 November 2016

### Keywords:

Malignant peripheral nerve sheath tumor

Neurofibromatosis

Glossopharyngeal

Vagus

Spinal

Villaret's syndrome

## ABSTRACT

**INTRODUCTION:** Intracranial malignant peripheral nerve sheath tumors are an extremely rare pathology with a high morbidity and mortality. Epidemiological, clinical and prognostic data are scarce and with little certainty in the literature. The aim of this paper is to report for first time in English literature, the case of a patient with type 1 neurofibromatosis, who presented a malignant peripheral nerve sheath tumor that involved the left glossopharyngeal, vagus and spinal nerves with intracranial and extracranial extension through jugular foramen and systemic metastases.

**PRESENTATION OF CASE:** A 37 years-old female patient with malnutrition and Villaret's syndrome. It was confirmed by brain magnetic resonance imaging and PET-CT the presence of a neoplastic lesion which was radiologically compatible with malignant peripheral nerve sheath tumor with systemic metastases. Partial surgical resection was performed; the patient postoperative course was without significant clinical improvement but with added peripheral facial palsy. The patient did not accept adjuvant management because of personal reasons.

**DISCUSSION AND CONCLUSION:** Behavior therapy is unclear due to the low frequency of the disease and the lack of case series, representing a challenge for the physician in its approach and a poor prognosis for the patient.

© 2016 The Authors. Published by Elsevier Ltd on behalf of IJS Publishing Group Ltd. This is an open access article under the CC BY-NC-ND license (<http://creativecommons.org/licenses/by-nc-nd/4.0/>).

## 1. Introduction

Peripheral nerve sheath tumors (PNST) are histologically benign and slow growing lesions with an incidence of 0.001% in general population [1]. Schwannomas and neurofibromas represent the vast majority, being up to 10–12% of this benign neoplasm of connective tissue [2]. There is an increased risk of malignant transformation in genetically susceptible patients such as patients with type 1 neurofibromatosis (NF1), resulting in a malignant peripheral nerve sheath tumor (MPNST), which can occur rarely at any nerve root including cranial nerves. Current literature reports about 40 cases in the English-written journals and periodicals, the most frequently affected cranial nerves are in decreasing order of frequency

the trigeminal and vestibulocochlear – facial complex [1,3–5] and in one case the lower cranial nerves complex through jugular foramen in a pediatric patient [6].

The objective of this manuscript is to report for the first time in the English-written literature the case of an adult female patient with NF1 who presented a MPNST involving the glossopharyngeal, vagus and spinal left nerves which extended from the left cerebello-pontine cistern to C4–C5 levels via the jugular foramen, along with this primary lesion the patient presented systemic metastases.

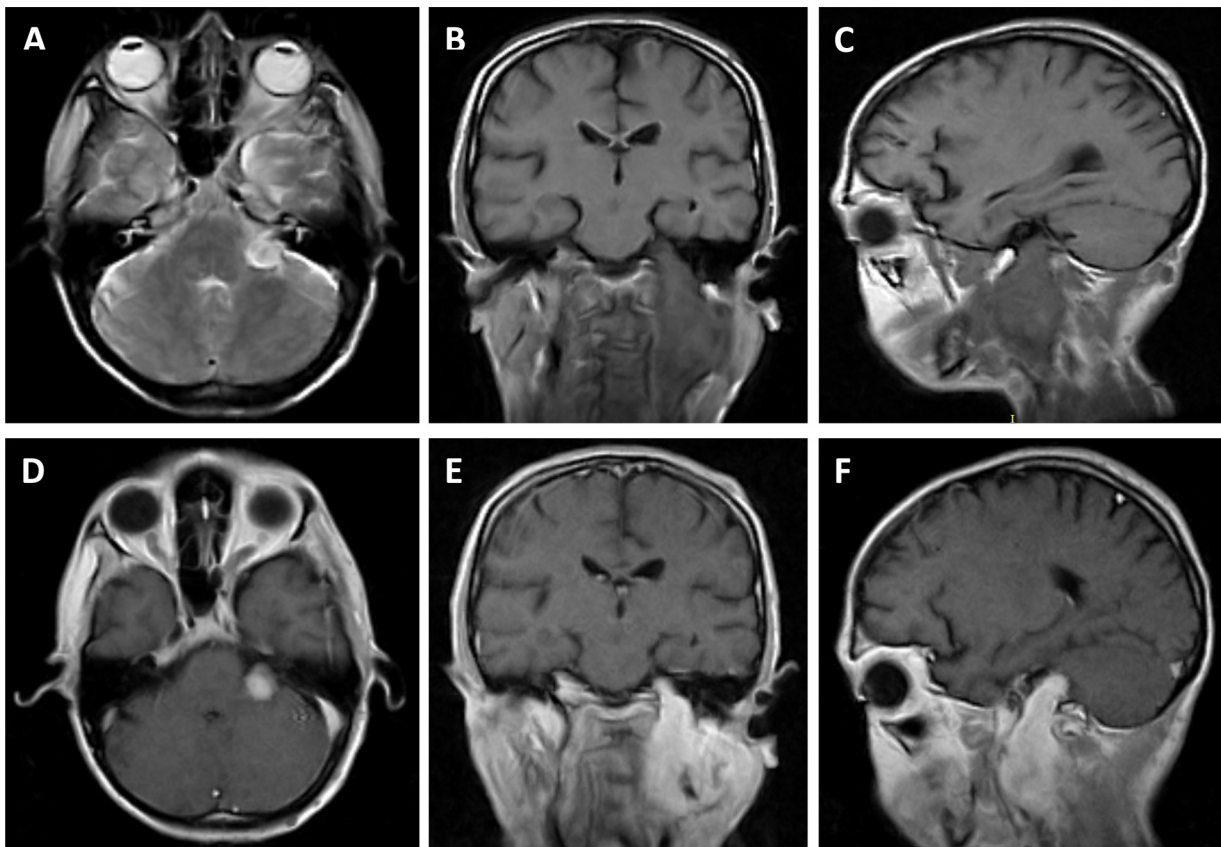
## 2. Case report

### 2.1. Clinical history, physical examination and image

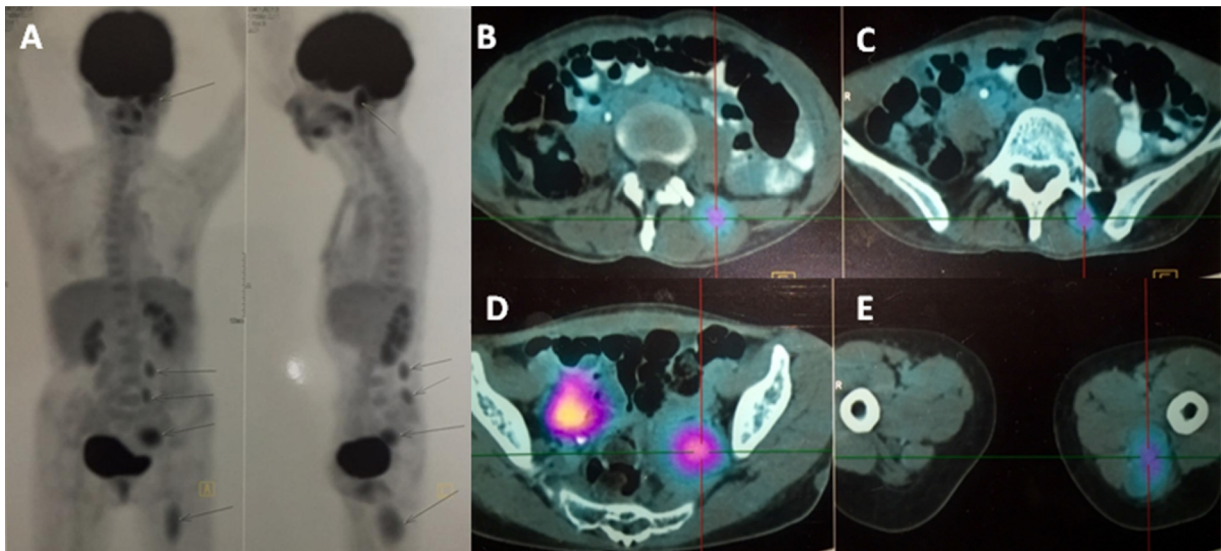
A 37-year-old female presented with the following relevant prior medical history: NF1 diagnosed eight years ago, neurofibroma resection at first left metacarpophalangeal joint six years ago.

\* Corresponding author at: Periferico Sur 4091, Fuentes del pedregal, PC 14140, Tlalpan, Mexico city, Mexico.

E-mail address: [drjrgm@hotmail.com](mailto:drjrgm@hotmail.com) (J.R. Guerra-Mora).



**Fig. 1.** Preoperative brain MRI showing a hyperintense neoplastic lesion on T2 sequence at left cerebellopontine cistern (A) with extension to C4-C5 level through jugular foramen (B and C), it enhances at gadolinium administration (D–F) and shows a low signal intensity in the center (E and F).

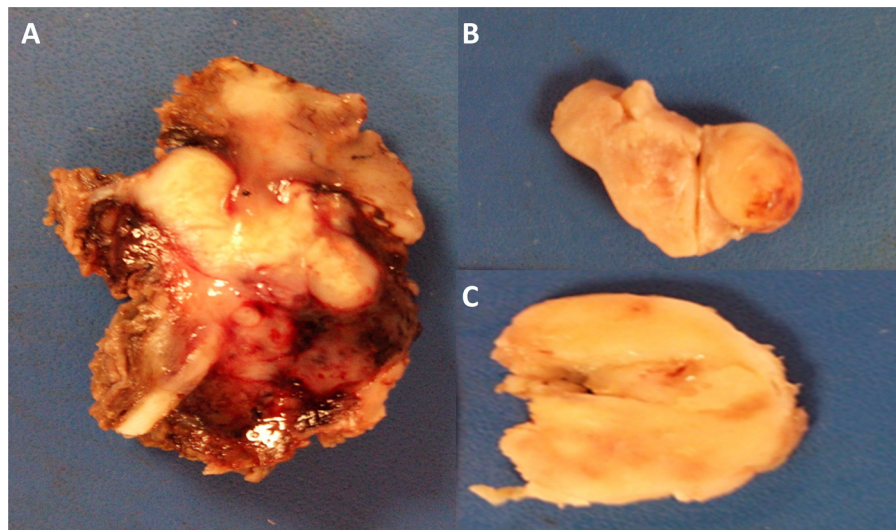


**Fig. 2.** PET-CT. Coronal, sagittal and axial sections showing metastatic lesions (arrows) at paravertebral (A–C), pelvic (A and D) and left thigh levels (A and E) with increased metabolism of 5-fluorodeoxyglucose.

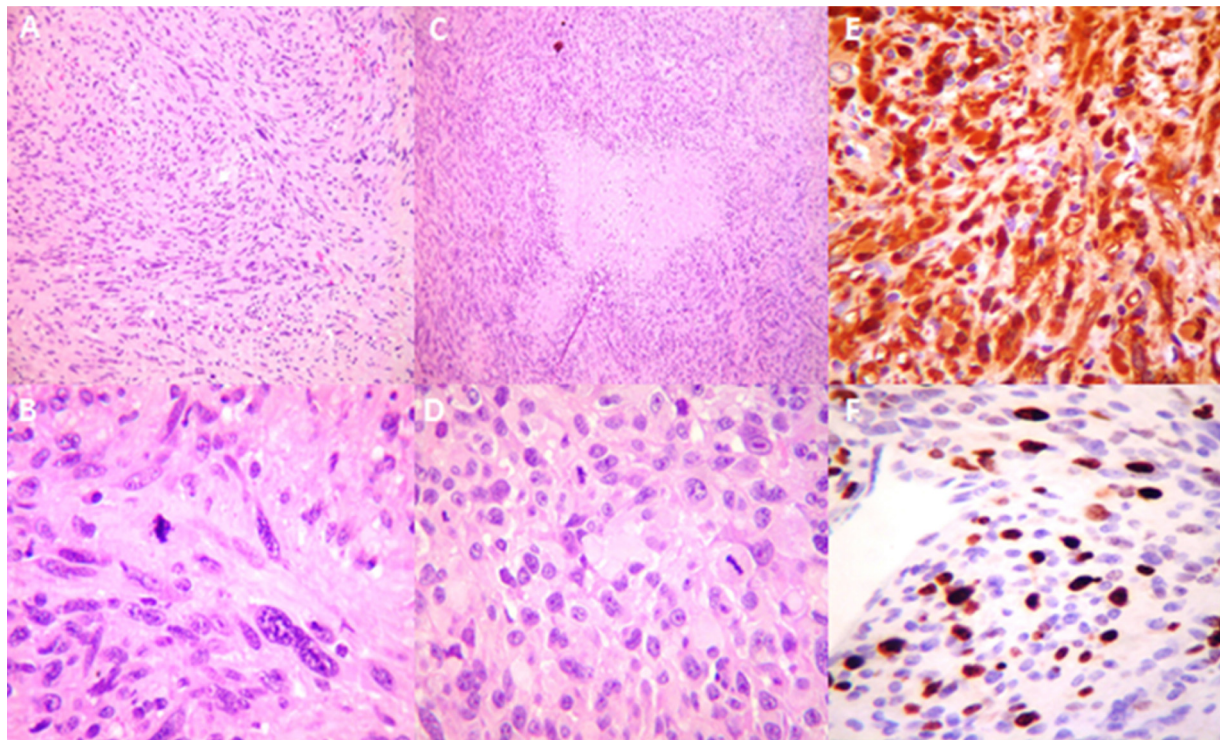
The patient sought medical attention through his primary care physician (PCP) with a chief complaint of one-month history of hoarseness accompanied with nonproductive cough, she was treated with a 7-day antibiotic course with no successful results, reason why the PCP referred the patient to otolaryngology where she was diagnosed as chronic pharyngitis and put on a 2-month antibiotic course without improvement, further analysis of the case

was done by the otolaryngologist, including laryngoscopy which revealed a left vocal cord paralysis. Magnetic resonance imaging (MRI) of the brain and cervical spine were ordered and the patient was ultimately referred to the neurology and neurosurgery department of our hospital.

At hospital admission she referred a history of fatigue, weakness, dysphagia to solids and weight loss of 8 kg in the last 6 months.



**Fig. 3.** Macroscopic appearance. The specimen has an irregular shape, measuring  $7.3 \times 1.3 \times 7$  cm. It is solid, heterogenous, yellowish brown with areas of necrosis and hemorrhage and rubbery consistency (A). Small specimens with homogeneous solid appearance, whitish, yellow and soft rubbery consistencies were observed (B and C).



**Fig. 4.** Histopathology. High cellularity (A), pleomorphic spindled cells, abnormal mitotic figures (B), geographical necrotic areas (C), epithelioid cells aspect (D) are observed. Immunohistochemistry for protein S-100 was strongly positive in neoplastic cells (E), and marker Ki67 was positive in 30% of neoplastic cells (F).

physical examination revealed a cachectic patient with a body mass index of  $16.4 \text{ kg/m}^2$  [2], along the skin there were multiple *café au lait* spots wider than 1.5 cm in diameter, as well as widely disseminated ephelides with axillary and scapular predominance and multiple cutaneous neurofibromas; the main finding during physical examination was a solid mass, mobile and painless about  $5 \times 5 \times 3$  cm, traversing the left carotid and occipital neck triangle. At neurological examination positive findings were left ptosis, right uvula deviation, left soft palate veil drop, limitation for lifting left shoulder and head rotation to the right, hypotrofia of left portion of the tongue and shift to the left at protrusion.

In MRI a neoplastic aspect lesion was observed, which extended from the left cerebellopontine cistern to C4-C5 levels through the jugular foramen (Fig. 1). Positron emission tomography combined with computed tomography (PET-CT) with 18-fludeoxyglucose revealed increased uptake at paravertebral levels, pelvic cavity and left thigh (Fig. 2). In addition to the known diagnoses of type 1 neurofibromatosis and malnutrition, Villaretis syndrome was diagnosed secondary to neoplastic lesion at left jugular foramen, compatible with MPNST.

## 2.2. Surgery

Due to disease stage and nutritional status, it was decided only resection of the cervical portion for diagnostic purposes. Left anterior cervical approach was performed; a round mass, with greyish color combined with some red areas, and a stone-like aspect was found and resected.

Glossopharyngeal, vagus and spinal nerves were surrounded entirely by the tumor and dissection was deemed impossible; the exact tumor origin could not be established. Tumor and the inner nerves were sectioned at its rostral and caudal extremes (Fig. 3). There were no incidents during surgery.

## 2.3. Histopathology

Histopathology reported a MPNST of the glossopharyngeal, vagus and spinal nerves with proliferation index Ki-67 30% (Fig. 4).

## 2.4. Follow-up

After surgery, the patient was admitted immediately to the intensive care unit for airway protection and was withdrawn from mechanical ventilation within the first 24 h without complications. Dysphagia and left peripheral (House Brackmann 4) facial palsy presented immediately after surgery. In the course of 6 months the patient presented a slight improvement in facial movement (House Brackmann 3) with left ptosis and tongue palsy. With the aim to treat residual tumor and spread disease, chemotherapy and radiation were offered to the patient, who rejected the offered treatment for undisclosed reasons.

## 3. Discussion

MPNST are a rare variety of origin ectomesenchymatous sarcoma [3], currently known under this term [7], formerly subsumed into different groups: neurofibrosarcoma, malignant neurilemoma, malignant schwannoma, neurogenic sarcoma, malignant neurofibroma. It accounts for about 5–10% of soft tissue sarcomas [8], most commonly affecting patients between 20 and 50 years old, predominantly in males, about 80% [9]. Frequency of localization in decreasing order are in limbs, trunk and retroperitoneum, rarely at intracranial level with about 40 cases reported in the English-written literature [1,10–16], of these, 31% may be presented as malignant progression of a schwannoma [1,17]. About 66% of patients with these tumors are associated with NF 1 [3] and have a risk from 8 to 13% of presenting a MPNST over the life [1], as happened in our patient.

In our case the patient was referred with an approximate delay in diagnosis of 4 months, since she first sought CPC attention. When admitted to hospitalization by the neurosurgery and neurology service, the following diagnosis were made: NF1, malnutrition, left Villaretis syndrome (Horner syndrome and glossopharyngeal, vagus, spinal, hypoglossal nerves palsy); diagnostics that indicate the presence of a malignant lesion at parotid space with jugular foramen and paravertebral extension as observed in imaging studies, specifically in PET-CT.

It was decided to make a partial resection in order to alleviate some of the symptoms caused by mass effect and taking into consideration her poor nutritional state and the stage of disease (Fig. 2) it was deemed that total resection probably would not have benefited quality of life and mortality in our patient, even if radiation therapy and chemotherapy had been accepted [1].

Section of glossopharyngeal, vagus and spinal nerves at its rostral and caudal portions was considered necessary since there were no identifiable differentiation of tumor and nerves under the microscope.

Ki-67 was expressed in 30% of tumor cells, which is associated with a poor prognosis [19]. The use of chemotherapy could improve survival [8]; however, the patient decided for personal reasons to refuse treatment.

There are few data in the literature about management of MPNST of cranial nerves, so it is debatable, based on the experience of the neurosurgeon and whenever it is possible, trying to get complete resections and free margins [1], which is why we advocate for individualization of each case according to disease extension and patient desires. The prognosis in patients with NF1 is poor with 23% survival at 5 years [5], linked to the frequency of metastasis.

The patient showed metastases in multiple locations outside of the central nervous system, this phenomenon has not been reported in literature before [1]. This remains the importance of systemic extension studies like PET-CT in this kind of patients [20].

In a study that analyzed the factors that were associated with prognosis, it was found that a previous radiation and positive margins status of resection site were associated with a shorter survival when the disease was localized; likewise, the size, grade and histologic subtype were related to poor prognosis when there was metastatic disease [17].

There are few reports in the literature of MPNST involving the lower cranial nerves in the cervical level with intracranial and extracranial components [10], one in a pediatric patient [6], and another in an adult patient in Japanese literature [16].

## 4. Conclusion

We report the first case in English-written literature of an adult patient with NF1 and a MPNST with intracranial and extracranial extension through the jugular foramen and systemic metastasis.

Through this case we can ascertain there is mandatory to discard systemic disease extension at time of diagnosis in these patients.

Treatment strategies for this particular pathology are still unclear due to the low frequency of the disease and a lack of number of cases, making them a challenge for the neurosurgeon.

## Author contribution

José Raúl Guerra-Mora: Design, intellectual, diagnostic, writing, edition, surgical collaboration.

Juan D Del Castillo-Calcano: Intellectual, writing, edition, surgical collaboration.

María Elena Córdoba Mosqueda: Intellectual, writing, edition, collaboration.

Jorge Yáñez: Intellectual, writing, edition, collaboration.

Ulises García-González: Intellectual, edition, surgical collaboration.

Eduardo Soriano-Navarro: Intellectual, writing, edition, collaboration.

Rosa María Vicuña González: Intellectual, histopathology, collaboration.

Leticia Llamas: Intellectual, histopathology, collaboration.

## Funding

The authors of this manuscript confirm that there is no use of funding resources to disclose.

## Ethical approval

For this type of study, formal consent is not required.

## Consent

In this work we don't mention about any personal information of the patient and it is maintained in anonymity. There are no photographs or images that discloses the private information of the patient.

## Guarantor

José Raúl Guerra-Mora.

## Conflicts of interest

The authors of this manuscript confirm that there are no conflicts of interest to disclose.

## References

- [1] A. Ziadi, I. Saliba, Malignant peripheral nerve sheath tumor of intracranial nerve: a case series review, *Auris Nasus Larynx* 37 (5) (2010) 539–545.
- [2] M.D. Murphey, M.J. Kransdorf, S.E. Smith, Imaging of soft tissue neoplasms in the adult: malignant tumors, *Semin. Musculoskelet. Radiol.* 3 (1) (1999) 39–58.
- [3] L. Chen, Y. Mao, H. Chen, L.F. Zhou, Diagnosis and management of intracranial malignant peripheral nerve sheath tumors, *Neurosurgery* 62 (4) (2008) 825–832.
- [4] W.J. Levy, L. Ansbacher, J. Byer, A. Nutkiewicz, J. Fratkin, Primary malignant nerve sheath tumor of the gasserian ganglion: a report of two cases, *Neurosurgery* 13 (5) (1983) 572–576.
- [5] M.S. Muhlbauer, W.C. Clark, J.H. Robertson, L.G. Gardner, F.C. Dohan Jr., Malignant nerve sheath tumor of the facial nerve: case report and discussion, *Neurosurgery* 21 (1) (1987) 68–73.
- [6] C. Balasubramaniam, A case of malignant tumour of the jugular foramen in a young infant, *Childs Nerv. Syst.* 15 (6–7) (1999) 347–350.
- [7] D.N. Louis, H. Ohgaki, O.D. Wiestler, W.K. Cavenee, P.C. Burger, A. Jouvett, et al., The 2007 WHO classification of tumours of the central nervous system, *Acta Neuropathol.* 114 (2) (2007) 97–109.
- [8] J.E. Wanebo, J.M. Malik, S.R. VandenBerg, H.J. Wanebo, N. Driesen, J.A. Persing, Malignant peripheral nerve sheath tumors: a clinicopathologic study of 28 cases, *Cancer* 71 (4) (1993) 1247–1253.
- [9] M.J. Kransdorf, Malignant soft-tissue tumors in a large referral population: distribution of diagnoses by age, sex, and location, *AJR Am. J. Roentgenol.* 164 (1) (1995) 129–134.
- [10] A.R. Molina, H. Brasch, S.T. Tan, Malignant peripheral nerve sheath tumour of the cervical vagus nerve in a neurofibromatosis type 1 patient, *J. Plast Reconstr. Aesthet. Surg.* 59 (12) (2006) 1458–1462.
- [11] R.C. Ramanathan, J.M. Thomas, Malignant peripheral nerve sheath tumours associated with von Recklinghausen's neurofibromatosis, *Eur. J. Surg. Oncol.* 25 (2) (1999) 190–193.
- [12] A.A. King, M.R. Debaun, V.M. Riccardi, D.H. Gutmann, Malignant peripheral nerve sheath tumors in neurofibromatosis 1, *Am. J. Med. Genet.* 93 (5) (2000) 388–392.
- [13] H.S. Gilmer-Hill, D.G. Kline, Neurogenic tumors of the cervical vagus nerve: report of four cases and review of the literature, *Neurosurgery* 46 (6) (2000) 1498–1503.
- [14] M. Sandoval, E. Gil Garces, G. Arias, E. Amilibia, M. Dicenta, Malignant peripheral nerve sheath tumor: vagus nerve sarcoma, *Acta Otorrinolaringol. Esp.* 49 (5) (1998) 418–421.
- [15] J. Ilgner, W. Rojas, S. Biesterfeld, K. Schurmann, M. Zimny, M. Westhofen, Low-grade malignant peripheral nerve sheath tumor of the neck soft tissues, *Laryngorhinootologie* 80 (1) (2001) 39–42.
- [16] Y. Kuzu, T. Beppu, K. Sibanai, K. Ogasawara, A. Ogawa, A. Kurose, A case of malignant peripheral nerve sheath tumor originating from the cervical vagus nerve, *No Shinkei Geka* 30 (5) (2002) 523–526.
- [17] W.W. Wong, T. Hirose, B.W. Scheithauer, S.E. Schild, L.L. Gunderson, Malignant peripheral nerve sheath tumor: analysis of treatment outcome, *Int. J. Radiat. Oncol. Biol. Phys.* 42 (2) (1998) 351–360.
- [18] H. Zhou, C.M. Coffin, S.L. Perkins, S.R. Tripp, M. Liew, D.H. Viskochil, Malignant peripheral nerve sheath tumor: a comparison of grade, immunophenotype, and cell cycle/growth activation marker expression in sporadic and neurofibromatosis 1-related lesions, *Am. J. Surg. Pathol.* 27 (10) (2003) 1337–1345.
- [19] G. Gupta, A. Mammis, A. Maniker, Malignant peripheral nerve sheath tumors, *Neurosurg. Clin. North Am.* 19 (4) (2008) 533–543.

## Open Access

This article is published Open Access at [sciedirect.com](http://sciedirect.com). It is distributed under the [IJSCR Supplemental terms and conditions](#), which permits unrestricted non commercial use, distribution, and reproduction in any medium, provided the original authors and source are credited.