



REVISTA BRASILEIRA DE ANESTESIOLOGIA

Official Publication of the Brazilian Society of Anesthesiology
www.sba.com.br



SCIENTIFIC ARTICLE

Rectal dexmedetomidine in rats: evaluation of sedative and mucosal effects

Volkan Hanci^{a,*}, Kanat Gülle^b, Kemal Karakaya^c, Serhan Yurtlu^a, Meryem Akpolat^b, Mehmet Fatih Yüce^d, Fatma Zehra Yüce^b, Işıl Özkoçak Turan^d

^a Department of Anesthesiology and Reanimation, Dokuz Eylül University, School of Medicine, Izmir, Turkey

^b Department of Histology and Embryology, Zonguldak Bulent Ecevit University, School of Medicine, Zonguldak, Turkey

^c Department of General Surgery, Zonguldak Bulent Ecevit University, School of Medicine, Zonguldak, Turkey

^d Department of Anesthesiology and Reanimation, Zonguldak Bulent Ecevit University, School of Medicine, Zonguldak, Turkey

Received 1 July 2013; accepted 9 September 2013

Available online 5 November 2013

KEYWORDS

Dexmedetomidine;
Rectum;
Rat;
Anesthesia;
Mucosa

Abstract

Background and objectives: In this study, we investigated the anesthetic and mucosal effects of the rectal application of dexmedetomidine to rats.

Methods: Male Wistar albino rats weighing 250–300 g were divided into four groups: Group S ($n=8$) was a sham group that served as a baseline for the normal basal values; Group C ($n=8$) consisted of rats that received the rectal application of saline alone; Group IPDex ($n=8$) included rats that received the intraperitoneal application of dexmedetomidine ($100 \mu\text{g kg}^{-1}$); and Group RecDex ($n=8$) included rats that received the rectal application of dexmedetomidine ($100 \mu\text{g kg}^{-1}$). For the rectal drug administration, we used 22 G intravenous cannulas with the stylets removed. We administered the drugs by advancing the cannula 1 cm into the rectum, and the rectal administration volume was 1 mL for all the rats. The latency and anesthesia time (min) were measured. Two hours after rectal administration, 75 mg kg^{-1} ketamine was administered for intraperitoneal anesthesia in all the groups, followed by the removal of the rats' rectums to a distal distance of 3 cm via an abdominoperineal surgical procedure. We histopathologically examined and scored the rectums.

Results: Anesthesia was achieved in all the rats in the Group RecDex following the administration of dexmedetomidine. The onset of anesthesia in the Group RecDex was significantly later and of a shorter duration than in the Group IPDex ($p < 0.05$). In the Group RecDex, the administration of dexmedetomidine induced mild–moderate losses of mucosal architecture in the colon and rectum, 2 h after rectal inoculation.

Conclusion: Although $100 \mu\text{g kg}^{-1}$ dexmedetomidine administered rectally to rats achieved a significantly longer duration of anesthesia compared with the rectal administration of saline, our

* Corresponding author.

E-mails: vhanci@gmail.com, volkanhanci@yahoo.com (V. Hanci).

PALAVRAS-CHAVE

Dexmedetomidina;
 Reto;
 Rato;
 Anestesia;
 Mucosa

histopathological evaluations showed that the rectal administration of $100 \mu\text{g kg}^{-1}$ dexmedetomidine led to mild–moderate damage to the mucosal structure of the rectum.

© 2013 Sociedade Brasileira de Anestesiologia. Published by Elsevier Editora Ltda.

Este é um artigo Open Access sob a licença de [CC BY-NC-ND](#)

Dexmedetomidina retal em ratos: avaliação dos efeitos sedativos e sobre a mucosa**Resumo**

Justificativa e objetivos: Neste estudo nós investigamos os efeitos anestésicos e sobre a mucosa da aplicação retal de dexmedetomidina a ratos.

Métodos: Ratos machos albinos Wistar, pesando 250–300 g, foram divididos em quatro grupos: Grupo S ($n=8$) foi um grupo sham que serviu de base para os valores basais normais; Grupo C ($n=8$) consistiu em ratos que receberam a aplicação retal apenas de soro fisiológico; Grupo IPDex ($n=8$) consistiu em ratos que receberam aplicação intraperitoneal de dexmedetomidina ($100 \mu\text{g kg}^{-1}$) e Grupo RecDex ($n=8$) consistiu em ratos que receberam a aplicação retal de dexmedetomidina ($100 \mu\text{g kg}^{-1}$). Para a administração dos fármacos por via retal, usamos cânulas intravenosas de calibre 22, com os estiletos removidos. A administração consistiu em avançar a cânula 1 cm no reto, e o volume de administração retal foi de 1 mL para todos os ratos. Os tempos (min) de latência e de anestesia foram registrados. Duas horas após a administração por via retal, 75 mg kg^{-1} de cetamina foram administrados a todos os grupos para anestesia intraperitoneal, seguido por remoção dos retos dos ratos a uma distância 3 cm distal por meio de procedimento cirúrgico abdominoperineal. Os retos foram histopatologicamente examinados e classificados.

Resultados: A anestesia foi realizada em todos os ratos do grupo RecDex após a administração de dexmedetomidina. O tempo de início da anestesia no Grupo RecDex foi significativamente mais longo e com uma duração mais curta que no Grupo IPDex ($p < 0,05$). No Grupo RecDex, a administração de dexmedetomidina induziu perdas leves a moderadas da arquitetura da mucosa do cólon e reto 2 h após a inoculação retal.

Conclusão: Embora a administração de $100 \mu\text{g kg}^{-1}$ de dexmedetomidina por via retal em ratos tenha resultado em uma duração significativamente maior da anestesia, em comparação com a administração retal de soro fisiológico, nossas avaliações histopatológicas mostraram que a administração retal de $100 \mu\text{g kg}^{-1}$ de dexmedetomidina ocasionou danos leves a moderados à estrutura da mucosa retal.

© 2013 Sociedade Brasileira de Anestesiologia. Publicado por Elsevier Editora Ltda.

Este é um artigo Open Access sob a licença de [CC BY-NC-ND](#)

Introduction

Premedication is the preoperative nasal, oral, rectal, intramuscular or intravenous administration of sedative drugs to lower the patient's fear of surgical intervention, achieve sedation and anxiolysis, and decrease the amount of anesthetics needed.^{1–6} In addition to benzodiazepines such as midazolam, which are commonly used for this purpose, the use of alpha 2 agonists such as clonidine and dexmedetomidine is becoming popular.^{3–8} For pediatric patients, it is essential that premedication agents are administered non-invasively, i.e., transmucosally, nasally or orally.^{3–5,7,8} Rectal administration is also preferred, particularly for the premedication of young children.^{2,3,9–11} Previous studies have shown that, similar to midazolam and ketamine, clonidine can be administered rectally for premedication.^{2,9–14}

Dexmedetomidine is an alpha adrenergic agonist with high levels of specificity and selectivity to alpha 2 receptors. Dexmedetomidine can be used for sedation, analgesia and anesthesia in intensive care settings, as well as for local and regional anesthesia applications.^{8,15–17} Research

has also shown that dexmedetomidine can be administered orally, nasally, transmucosally or intramuscularly for premedication.^{4,8,18–24} However, there are no published studies concerning the rectal application of dexmedetomidine for premedication.

Our hypothesis was that dexmedetomidine administered rectally to rats would produce a sedative effect with no damage to the rectal mucosa.

To test this hypothesis, we compared the anesthetic effects of equal doses of dexmedetomidine administered rectally or intraperitoneally to rats. In addition, we compared the histopathological effects on rectal mucosa of rectally administered dexmedetomidine.

Materials and methods

This study was approved by the Animal Ethics Committee of the Bulent Ecevit University (formerly Zonguldak Karaelmas University) Medical School. All the animals were treated humanely and in compliance with the recommendations of

the university's animal care committee and the principles of laboratory animal care (NIH publication no. 85-23, revised in 1985). The rats were housed in a temperature-controlled room ($24 \pm 1^\circ\text{C}$) on a 12-h light–12-h dark cycle, and they were fed standard rat chow and water until 12 h before the experimental protocol.

Thirty-two male Wistar albino rats weighing between 250 and 300 g were randomly divided into four groups of eight rats. Group S ($n=8$) was a sham group served as a baseline for the normal basal values; Group C ($n=8$) consisted of rats that received the rectal application of saline alone; Group IPDex ($n=8$) included rats that received the intraperitoneal application of dexmedetomidine; and Group RecDex ($n=8$) included rats that received the rectal application of dexmedetomidine.

The rats' weights were measured prior to the experiment. For rectal drug administration, we used 22 G intravenous cannulas with the stylets removed. We administered the drugs by advancing the cannula 1 cm into the rectum, and the rectal administration volume was 1 mL for all the rats.²⁵

We identified the onset and duration of anesthesia in all the groups by observing the righting reflex.²⁶ We measured the latency of anesthesia (the time required to lose the righting reflex) and the anesthesia time (the duration of the loss of the righting reflex) in minutes (min).²⁶ Two hours after rectal study drug's administration; 75 mg kg⁻¹ ketamine was used in all the groups for intraperitoneal anesthesia, followed by the removal of the rats' rectums to a distal distance of 3 cm via an abdominoperineal surgical procedure.²⁵ We histopathologically examined and scored the rectums.²⁷

Preliminary study

Before the experiment, we evaluated the effectiveness of different doses of rectally administered dexmedetomidine from previous studies.^{16,17,28} We administered 1 $\mu\text{g kg}^{-1}$, 10 $\mu\text{g kg}^{-1}$, 50 $\mu\text{g kg}^{-1}$ and 100 $\mu\text{g kg}^{-1}$ dexmedetomidine rectally to the two rats in each group.²⁵ In the preliminary study, anesthesia was not achieved with the rectal administration of 1 or 10 $\mu\text{g kg}^{-1}$ dexmedetomidine; however, anesthesia was obtained in one of the rats that received 50 $\mu\text{g kg}^{-1}$ dexmedetomidine rectally and in both rats that received 100 $\mu\text{g kg}^{-1}$ dexmedetomidine rectally. Therefore, 100 $\mu\text{g kg}^{-1}$ was chosen as the dose of dexmedetomidine to be used rectally and intraperitoneally.

Groups

The rats in the sham group ($n=8$) did not receive the rectal administration of any substances. These rats were used as controls for the histopathological examination of the rectum. They were administered 75 mg kg⁻¹ i.p. ketamine, followed by the removal of the rectum to a distal distance of 3 cm via abdominoperineal surgery.²⁵ We examined the rats' rectums and scored them histopathologically.²⁷

The rats in the control group ($n=8$) received 1 mL of saline by the advancement of a 22 G intravenous cannula with no stylet 1 cm into the rectum. After the saline administration, we measured the anesthesia duration in the rats.²⁶

We removed their rectums to a distal distance of 3 cm via abdominoperineal surgery.²⁶ We examined the rectums and scored them histopathologically.²⁷

We administered 100 $\mu\text{g kg}^{-1}$ dexmedetomidine intraperitoneally to the rats in group IPDex (intraperitoneal dexmedetomidine group, $n=8$). We established the proper dosage of dexmedetomidine with the help of the preliminary study and previous research.^{16,17,28} After the administration of dexmedetomidine, we measured the anesthesia duration in the rats.²⁶

In the rectal dexmedetomidine group (Group RecDex, $n=8$), saline was added to 100 $\mu\text{g kg}^{-1}$ dexmedetomidine to a total volume of 1 mL and was administered rectally by advancing a 22 G intravenous cannula with no stylet 1 cm into the rectum. After administering the dexmedetomidine, we measured the anesthesia duration in the rats.²⁶ The rectums of the rats were removed to a distal distance of 3 cm via abdominoperineal surgery.²⁵ The rectums were examined histopathologically and scored.²⁷

Histologic assessment of colonic mucosal damage

For the light microscopic observation, distal colon specimens were embedded in paraffin blocks after being fixed in a 10% formalin solution. Five-micrometer (5- μm) sections were obtained and stained with hematoxylin–eosin and Masson's trichrome using standard methods. A histologist graded the colonic pathological changes in a blinded manner using the histologic injury scale previously developed by Leung et al.²⁷ Briefly, mucosal damage was graded from 0 to 4 according to the following criteria: grade 0, normal mucosa; grade 1, damage to the surface epithelium only; grade 2, damage to the epithelium of the upper half of the gland; grade 3, damage to the majority of the glandular epithelium that did not extend to the base of the gland; and grade 4, the destruction of the epithelium of the entire gland.

Statistical analysis

We performed the statistical analysis using the Statistical Package for the Social Sciences (SPSS) version 16.0 for Windows (SPSS, Chicago, IL). For the scores and non-normally distributed variables, we compared the groups using the Mann–Whitney *U* and Kruskal–Wallis tests. The results were expressed as medians (25th–75th percentiles). A *p* value < 0.05 was considered statistically significant.

Results

Results concerning the duration of anesthesia and the rectal histopathological evaluations were obtained.

Duration of anesthesia

We achieved anesthesia in all the rats in the intraperitoneal and rectal dexmedetomidine groups following the administration of dexmedetomidine ($p < 0.001$). In both of these groups, the duration of anesthesia was significantly longer than in the sham and control groups ($p < 0.001$). In the Group IPDex, the onset of anesthesia occurred significantly more

Table 1 Latency of anesthesia and anesthesia time values according to group (median [25th–75th percentiles]).

	Group S (n=8)	Group C (n=8)	Group RecDex (n=8)	Group IPDex (n=8)	p
Latency of anesthesia (min)	0 (0-0)	0 (0-0)	13.50 (11.25–15.75) ^{a,b,c}	8.5 (5–9.75) ^{a,b}	0.001
Anesthesia time (min)	0 (0-0)	0 (0-0)	62.50 (47.00–79.00) ^{a,b,c}	111.5 (96–115.0) ^{a,b}	0.001

Min: minute.

^a $p < 0.001$ compared to Group S; Mann–Whitney *U* test.

^b $p < 0.001$ compared to Group C; Mann–Whitney *U* test.

^c $p < 0.001$ compared to Group IPDex; Mann–Whitney *U* test.

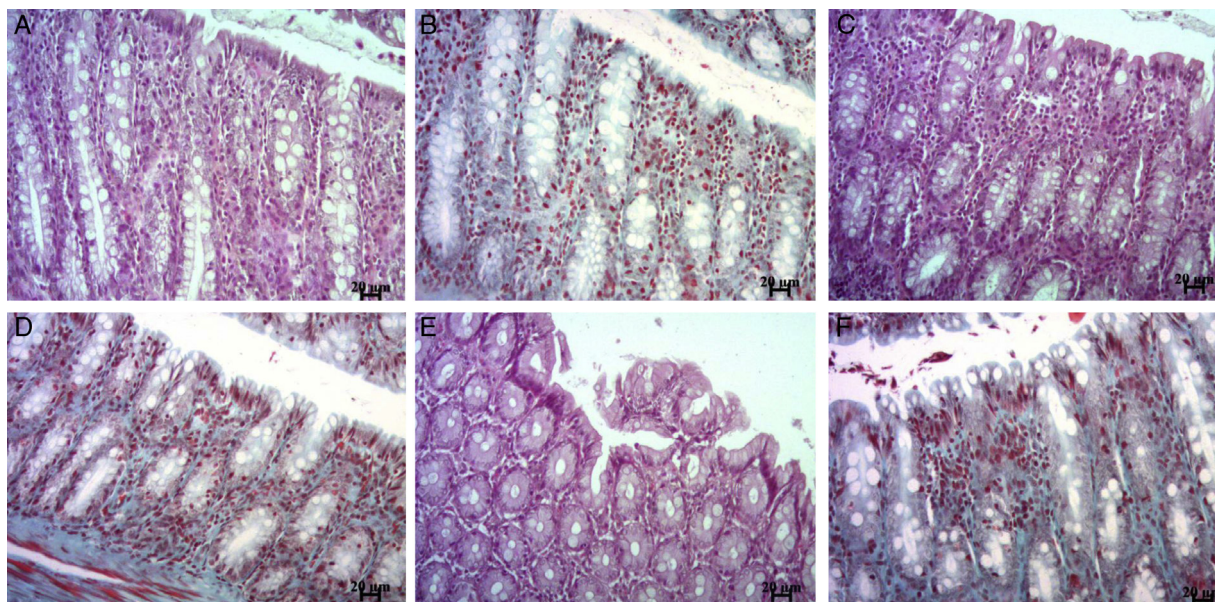


Figure 1 Representative micrographs of rat colon sections stained with hematoxylin–eosin (A, C, E) or Masson's trichrome (B, D, F). Normal colonic mucosa of Group S and Group C rats (A–D). Rats treated with rectal dexmedetomidine, showing the mild to moderate loss of surface and glandular epithelial cells (E, F). Scale bar = 20 μ m.

rapidly than in the Group RecDex ($p < 0.001$). In contrast, the duration of anesthesia in the Group IPDex was significantly longer than in the Group RecDex ($p < 0.001$) (Table 1).

Histopathological findings

The histologic features of the colonic and rectal walls of the Sham and Control groups were determined to be normal (Fig. 1A–D). In the Group RecDex, the drug induced mild and moderate losses of the mucosal architecture in the colon and rectum, 2 h after rectal inoculation (Fig. 1E–F). The histological examinations demonstrated the presence of mucosal damage with the loss of surface and glandular epithelial cells. As shown in Table 1, the microscopic score

(2 [2–2]) of the colons from the Group RecDex was significantly higher than that of the colon and rectum segments from the sham and control rats ($p < 0.001$) (Table 2).

Discussion

In this study, rectal dexmedetomidine administration was shown to have anesthetic activity but to also cause significant mucosal damage to rat rectal mucosa compared with the sham and control groups.

Alpha 2 agonists constitute a group of drugs commonly used in anesthesia for the purposes of sedation, analgesia and anesthesia.^{11–14,18–24} Clonidine, a member of this group, can also be used for premedication.^{11–14} Rectal

Table 2 Histopathological evaluation scores according to group (median [25th–75th percentiles]).

	Group S (n=8)	Group C (n=8)	Group RecDex (n=8)	p
Microscopic score	0 (0-0)	0 (0-0)	2 (2-2) ^{a,b}	0.001

^a $p < 0.001$ compared to Group S; Mann–Whitney *U* test.

^b $p < 0.001$ compared to Group C; Mann–Whitney *U* test.

premedication administration is particularly preferred for young children due to the ease of administration.^{2,3,9-11}

Previous studies have reported that clonidine can be used effectively rectally.¹¹⁻¹⁴ Comparing the effectiveness of rectally administered clonidine to that of midazolam, Bergendahl et al.¹¹ found that the use of the former as premedication resulted in lower pain scores than midazolam in the early postoperative stage. The authors also reported that children who were rectally administered ketamine were more sedated in first 24 postoperative hours than those who received midazolam.¹¹ In a study comparing the rectal administration of $2.5 \mu\text{g kg}^{-1}$ clonidine and $300 \mu\text{g kg}^{-1}$ midazolam to prevent the increase in neuroepithelial Y caused by tracheal intubation in children, Bergendahl et al.¹³ concluded that there was no significant difference between the two groups. A study that investigated the pharmacokinetic characteristics of rectally administered clonidine demonstrated that its maximum plasma concentration was 0.77 ng mL^{-1} and that the time required to reach this concentration was 51 min.¹⁴ The same study found that the half-life of rectal clonidine was 12.5 h and the bioavailability was 95%. The authors reported that the plasma concentration of clonidine reached clinically effective levels 10 min after rectal administration.¹⁴ They stated that $2.5 \mu\text{g kg}^{-1}$ clonidine rectally administered to children approximately 20 min before anesthesia induction could achieve a clinically effective plasma concentration.¹⁴

Dexmedetomidine is a highly specific and sensitive alpha adrenergic agonist, and it can be administered orally, nasally, transmucosally or intramuscularly for premedication.^{4,8,18-24}

Özcengiz et al.²⁰ showed that oral dexmedetomidine could prevent post-sevoflurane agitation in children. Yuen et al.⁴ reported that $1 \mu\text{g kg}^{-1}$ intranasal dexmedetomidine produced significantly higher sedation in children aged 2-12 years compared with oral midazolam. The authors emphasized that dexmedetomidine and midazolam created similar premedication conditions and that both were acceptable.⁴ In another study, Yuen et al.²⁹ found that sedation began an average of 25 min after intranasal dexmedetomidine and that the mean duration of sedation was 85 min. Sakurai et al.²¹ reported that $3-4 \mu\text{g kg}^{-1}$ dexmedetomidine administered to children buccally 1 h before surgery was reliable and effective.

In a comparison of the effects of $2 \mu\text{g kg}^{-1}$ intranasal dexmedetomidine and 0.5 mg kg^{-1} midazolam for premedication in pediatric patients, Talon et al.²² found that the two drugs had similar anesthesia induction and recovery characteristics. However, the authors reported that dexmedetomidine was more effective in inducing sleep and that it was a useful alternative to oral midazolam.²²

Although the rectal use of clonidine and the oral, nasal and transmucosal use of dexmedetomidine for premedication have been defined, there is no literature on the rectal use of dexmedetomidine.

In our study, the rectal administration of $100 \mu\text{g kg}^{-1}$ dexmedetomidine achieved anesthesia in all the rats in that group. The duration of anesthesia in both the groups that received intraperitoneal and rectal dexmedetomidine was significantly longer than in the sham and control groups. However, the onset of anesthesia was significantly later in the rectal dexmedetomidine group than in the

intraperitoneal dexmedetomidine group, and the duration of anesthesia was significantly shorter than in the intraperitoneal group.

Rectal administration is an alternative method of premedication, particularly for young children. The absorption mechanisms of rectally administered drugs resemble the upper gastrointestinal system. Passive transport is the main mechanism of rectal drug absorption. The absorption speed of rectally administered drugs is influenced by factors such as the molecular weight, lipid solubility and ionization degree of the drug. However, the rectal administration of drugs has been reported to cause side effects such as local inflammation, rectal mucosal damage, rectal ulceration, rectal bleeding and pain.³⁰

The rectal administration of anesthetic agents may also cause rectal mucosal damage.²⁵ Previous studies have shown that rectally administered 10% methohexitone causes rectal mucosal damage in rats that begins within minutes, becomes noticeable at 60 min, and continues 24 h.²⁵

However, there have been only a few studies of the rectal mucosal effects of alpha 2 agonists.^{31,32} Maxson et al.³¹ reported clonidine administration to rats to decrease mucus production in an intestinal ischemia/reperfusion model. In a case study, the long-term use of clonidine was reported to cause cicatricial pemphigoid in the anus, vulva mucosa and perianal skin.³² In that case, the direct immunofluorescent examination of the lesions indicated the possibility of complement-mediated tissue damage between epidermal basal cells and the basal membrane.³²

In our literature review, we were not able to find a study that evaluated the effects of rectally administered clonidine on rectal mucosa cells. We found in our study that rectally administered $100 \mu\text{g kg}^{-1}$ dexmedetomidine caused the moderate loss of the rectal mucosal surface and glandular epithelial cells. We are of the opinion that the mucosal damage caused by dexmedetomidine may have a mechanism similar to that of clonidine.^{31,32} However, we did not investigate the mechanisms of mucosal damage formation in the present study. These preliminary findings in rats may not be observed in rectal mucosa of humans due to the high dose and resulting high concentration applied to the rectal mucosa in this study. We believe that future studies should investigate the effects of dexmedetomidine on rectal mucosa and the reversibility of the damage.

The dexmedetomidine dosage used in our study was identified as the most effective in rectal use in the preliminary study. Several other studies have demonstrated neuroprotective effects of dexmedetomidine, albeit only at higher doses (up to $100 \mu\text{g kg}^{-1}$).³³⁻³⁵

In conclusion, although the rectal administration of dexmedetomidine to rats achieved a significantly longer duration of anesthesia compared with saline, our histopathological evaluation showed that the former treatment led to moderate damage in the mucosal structure of the rectum. Therefore, for the rectally safe use of dexmedetomidine as premedication, we believe that future studies are needed to reveal the effects of the drug on rectal mucosa.

Conflicts of interest

The authors declare no conflicts of interest.

References

1. Yousaf F, Seet E, Venkatraghavan L, et al. Efficacy and safety of melatonin as an anxiolytic and analgesic in the perioperative period: a qualitative systematic review of randomized trials. *Anesthesiology*. 2010;113:968–76.
2. Zanette G, Micaglio M, Zanette L, et al. Comparison between ketamine and fentanyl–droperidol for rectal premedication in children: a randomized placebo controlled trial. *J Anesth*. 2010;2:197–203.
3. Bozkurt P. Premedication of the pediatric patient – anesthesia for the uncooperative child. *Curr Opin Anaesthesiol*. 2007;20:211–5.
4. Yuen VM, Hui TW, Irwin MG, et al. A comparison of intranasal dexmedetomidine and oral midazolam for premedication in pediatric anesthesia: a double-blinded randomized controlled trial. *Anesth Analg*. 2008;106:1715–21.
5. Hosey MT, Asbury AJ, Bowman AW, et al. The effect of transmucosal 0.2 mg/kg midazolam premedication on dental anxiety, anaesthetic induction and psychological morbidity in children undergoing general anaesthesia for tooth extraction. *Br Dent J*. 2009;207:E2 (discussion 32–33).
6. Cruz JR, Cruz DF, Branco BC, et al. Clonidine as pre-anesthetic medication in cataract extraction: comparison between 100 microg and 200 microg. *Rev Bras Anesthesiol*. 2009;59:694–703.
7. Almenrader N, Passariello M, Coccetti B, et al. Premedication in children: a comparison of oral midazolam and oral clonidine. *Paediatr Anaesth*. 2007;17:1143–9.
8. Yuen VM. Dexmedetomidine: perioperative applications in children. *Paediatr Anaesth*. 2010;20:256–64.
9. Wang X, Zhou ZJ, Zhang XF, et al. A comparison of two different doses of rectal ketamine added to 0.5 mg × kg(–1) midazolam and 0.02 mg × kg(–1) atropine in infants and young children. *Anaesth Intensive Care*. 2010;38:900–4.
10. Sayin MM, Mercan A, Ture H, et al. The effect of 2 different concentrations of rectal ketamine on its premedicant features in children. *J Saudi Med*. 2008;29:683–7.
11. Bergendahl HT, Lönnqvist PA, Eksborg S, et al. Clonidine vs. midazolam as premedication in children undergoing adenotonsillectomy: a prospective, randomized, controlled clinical trial. *Acta Anaesthesiol Scand*. 2004;48:1292–300.
12. Constant I, Lepout Y, Richard P, et al. Agitation and changes of Bispectral Index and electroencephalographic-derived variables during sevoflurane induction in children: clonidine premedication reduces agitation compared with midazolam. *Br J Anaesth*. 2004;92:504–11.
13. Bergendahl HT, Eksborg S, Kogner P, et al. Neuropeptide Y response to tracheal intubation in anaesthetized children: effects of clonidine vs midazolam as premedication. *Br J Anaesth*. 1999;82:391–4.
14. Lönnqvist PA, Bergendahl HT, Eksborg S. Pharmacokinetics of clonidine after rectal administration in children. *Anesthesiology*. 1994;81:1097–101.
15. Hanci V, Erdoğan G, Okyay RD, et al. Effects of fentanyl–lidocaine–propofol and dexmedetomidine–lidocaine–propofol on tracheal intubation without use of muscle relaxants. *Kaohsiung J Med Sci*. 2010;26:244–50.
16. Hanci V, Erol B, Bektaş S, et al. Effect of dexmedetomidine on testicular torsion/detorsion damage in rats. *Urol Int*. 2010;84:105–11.
17. Hanci V, Karakaya K, Yurtlu S, et al. Effects of dexmedetomidine pretreatment on bupivacaine cardiotoxicity in rats. *Reg Anesth Pain Med*. 2009;34:565–8.
18. Ghali AM, Mahfouz AK, Al-Bahrani M. Preanesthetic medication in children: a comparison of intranasal dexmedetomidine versus oral midazolam. *Saudi J Anaesth*. 2011;5:387–91.
19. Mizrak A, Gul R, Ganidagli S, et al. Dexmedetomidine premedication of outpatients under IVRA. *Middle East J Anesthesiol*. 2011;21:53–60.
20. Özcengiz D, Gunes Y, Ozmete O. Oral melatonin, dexmedetomidine, and midazolam for prevention of postoperative agitation in children. *J Anesth*. 2011;25:184–8.
21. Sakurai Y, Obata T, Odaka A, et al. Buccal administration of dexmedetomidine as a preanesthetic in children. *J Anesth*. 2010;24:49–53.
22. Talon MD, Woodson LC, Sherwood ER, et al. Intranasal dexmedetomidine premedication is comparable with midazolam in burn children undergoing reconstructive surgery. *J Burn Care Res*. 2009;30:599–605.
23. Zub D, Berkenbosch JW, Tobias JD. Preliminary experience with oral dexmedetomidine for procedural and anesthetic premedication. *Paediatr Anaesth*. 2005;15:932–8.
24. Erkola O, Korttila K, Aho M, et al. Comparison of intramuscular dexmedetomidine and midazolam premedication for elective abdominal hysterectomy. *Anesth Analg*. 1994;79:646–53.
25. Hinkle AJ, Weinlander CM. The effects of 10% methohexital on the rectal mucosa in mice. *Anesthesiology*. 1989;71:550–3.
26. Ozbakis-Dengiz G, Bakirci A. Anticonvulsant and hypnotic effects of amiodarone. *J Zhejiang Univ Sci B*. 2009;10:317–22.
27. Leung FW, Su KC, Pique JM, et al. Superior mesenteric artery is more important than inferior mesenteric artery in maintaining colonic mucosal perfusion and integrity in rats. *Dig Dis Sci*. 1992;37:1329–35.
28. Guneli E, Karabay Yavasoglu NU, Apaydin S, et al. Analysis of the antinociceptive effect of systemic administration of tramadol and dexmedetomidine combination on rat models of acute and neuropathic pain. *Pharmacol Biochem Behav*. 2007;88:9–17.
29. Yuen VM, Hui TW, Irwin MG, et al. Optimal timing for the administration of intranasal dexmedetomidine for premedication in children. *Anaesthesia*. 2010;65:922–9.
30. Bergogne-Bérézin E, Bryskier A. The suppository form of antibiotic administration: pharmacokinetics and clinical application. *J Antimicrob Chemother*. 1999;43:177–85.
31. Maxson RT, Dunlap JP, Tryka F, et al. The role of the mucus gel layer in intestinal bacterial translocation. *J Surg Res*. 1994;57:682–6.
32. van Joost T, Faber WR, Manuel HR. Drug-induced anogenital cicatricial pemphigoid. *Br J Dermatol*. 1980;102:715–8.
33. Engelhard K, Werner C, Eberspächer E, et al. The effect of the α 2-agonist dexmedetomidine and the N-methyl-daspartate antagonist S+ ketamine on the expression of apoptosis-regulating proteins after incomplete cerebral ischemia and reperfusion in rats. *Anesth Analg*. 2003;96:524–31.
34. Jolkkonen J, Puurunen K, Koistinaho J, et al. Neuroprotection by the α -adrenoceptor agonist, dexmedetomidine, in rat focal cerebral ischemia. *Eur J Pharmacol*. 1999;372:31–6.
35. Maier C, Steinberg GK, Sun GH, et al. Neuroprotection by the α 2-adrenoreceptor agonist dexmedetomidine in a focal model of cerebral ischemia. *Anesthesiology*. 1993;79:1–7.