

## Case Report

## Toe metastasis: A rare pattern of cervical cancer spread

Marcia A. Ciccone<sup>b</sup>, Charlotte L. Conturie<sup>b</sup>, Cassie M. Lee<sup>c</sup>, Koji Matsuo<sup>a,d,\*</sup><sup>a</sup> Division of Gynecologic Oncology, University of Southern California, Los Angeles, CA 90033, USA<sup>b</sup> Department of Obstetrics and Gynecology, University of Southern California, Los Angeles, CA 90033, USA<sup>c</sup> Department of Pathology, Los Angeles County Medical Center, University of Southern California, Los Angeles, CA 90033, USA<sup>d</sup> Norris Comprehensive Cancer Center, University of Southern California, Los Angeles, CA 90033, USA

## ARTICLE INFO

## Article history:

Received 17 November 2013

Accepted 31 December 2013

Available online 8 January 2014

## Keywords:

Cervical cancer

Bone metastasis

Toe

Case report

## Background

Cervical cancer is locally invasive, spreading primarily through direct extension. Lymphatic spread to regional pelvic nodes is less common, and hematogenous spread occurs even less frequently, often occurring in advanced stages of cervical cancer with high grade tumors that is responsible for metastases to lungs, liver, spleen, brain, and bone (Agarwal et al., 2002). Accordingly, bone metastases most commonly involve direct and lymphatic spread to the pelvis and lumbar spine (Dewdney and Selvarajah, 2010). Distal appendicular skeletal metastases, attributable to hematogenous disease dissemination, are rare.

Here, we report two cases of squamous cell carcinoma of the cervix metastatic to the toe, causing pain, edema, and erythema, symptoms which can mimic infectious etiology. Because toe metastases are rare, both cases were initially thought to be of infectious origin, highlighting the importance of awareness of this site of metastases.

## Case 1

A 41-year-old female with known stage IVB moderately differentiated squamous cell carcinoma of the cervix presented with one month of progressive pain and swelling of her left fourth metatarsal. She was initially diagnosed five months prior, symptomatic with four months of persistent cough, decreased appetite, weight loss, and night sweats. She denied abnormal bleeding or discharge and had never received cervical cancer screening. On physical examination, her cervix was obliterated by a large irregular mass involving the anterior and upper vagina, recto-vaginal septum, and bilateral pelvic sidewalls. Biopsy of the mass confirmed moderately differentiated squamous cell carcinoma of the cervix. Systemic computed tomography imaging revealed extensive metastases to the chest, abdomen, and pelvis, including bilateral pulmonary nodules, mediastinal and retroperitoneal lymphadenopathy, and a lytic lesion of the pubic symphysis. Due to the distant metastases, she received nine total cycles of systemic cytotoxic chemotherapy (a combination of cisplatin and gemcitabine) with temporal response and symptomatic improvement after the first six cycles.

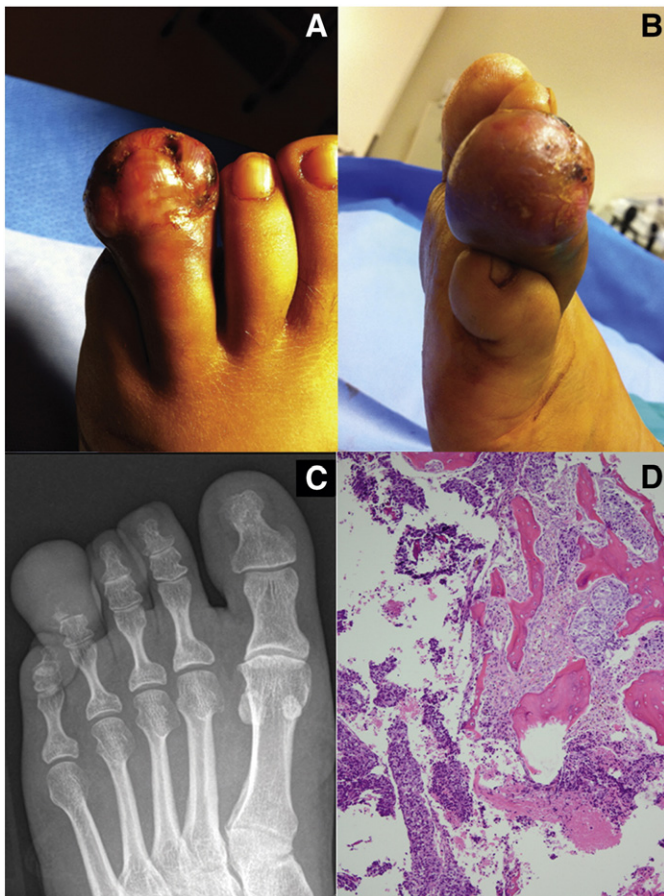During the course of chemotherapy, she reported approximately a month of pain and swelling in her left fourth toe, which she noticed while trimming her nails. She denied traumatic injury or insect bites to her feet or toes. On physical examination, the distal portion of her left fourth toe was erythematous, enlarged, and tender to palpation, without proximal extension (Fig. 1A–B). There was no open wound, fluctuation, or drainage, and she was afebrile without leukocytosis (white blood cell count, 4,400/m<sup>3</sup>). Her symptoms were initially thought to be attributed to infection, and she was treated with trimethoprim and sulfamethoxazole.

On return visit four weeks later, her symptoms had not abated. She was also found to have hypercalcemia (14.0 mg/dL), and repeat systemic imaging following cycle nine showed increasing size of her primary mass and metastatic disease. She was admitted for treatment of hypercalcemia and workup of her podiatric symptoms. Incision and drainage was attempted and failed to demonstrate evidence of an infectious source. Radiographic evaluation of the foot revealed erosion and resorption in the fourth distal phalanx with extensive soft tissue edema (Fig. 1C).

The patient desired toe amputation due to pain and inability to wear shoes. She underwent an uncomplicated toe amputation, and histological evaluation revealed metastatic squamous cell carcinoma to the distal phalanx (Fig. 1D). One week later, the patient's status deteriorated, and

\* Corresponding author at: Division of Gynecologic Oncology, Department of Obstetrics and Gynecology, Los Angeles County Medical Center, University of Southern California, 2020 Zonal Avenue, IRD 520, Los Angeles, CA 90033, USA. Fax: +1 323 226 3427.

E-mail address: [koji.matsuo@gmail.com](mailto:koji.matsuo@gmail.com) (K. Matsuo).



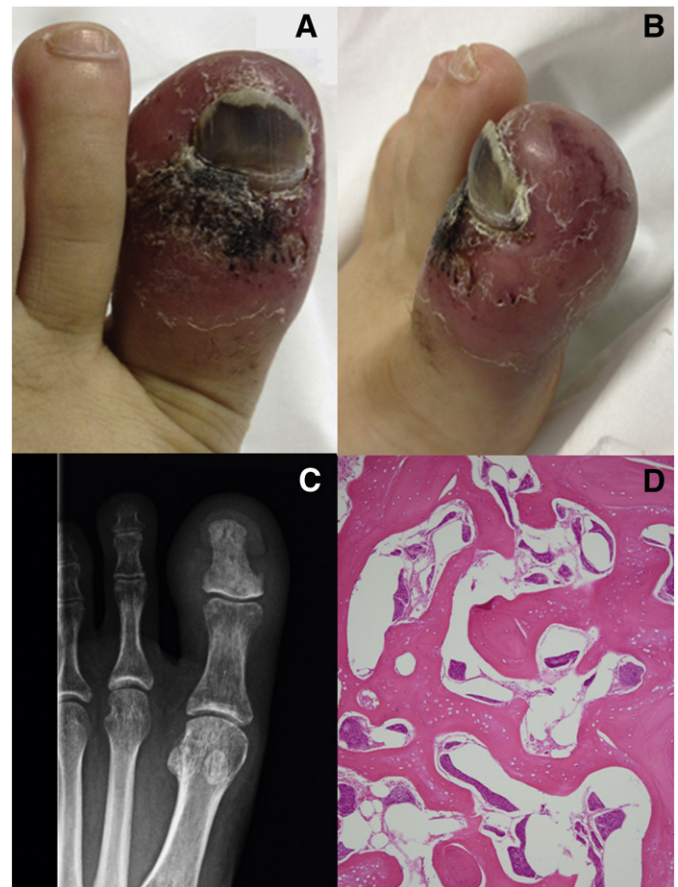
**Fig. 1.** Images of cervical cancer toe metastasis in Case 1. A) Dorsum of left fourth toe, notable for profuse swelling, erythema, and necrosis of the distal phalanx. B) Lateral view of the same toe. C) Plain film of the left foot, showing soft tissue swelling with erosion and resorption of the fourth distal phalanx. D) Hematoxylin and eosin staining of the toe following amputation, showing nests of metastatic squamous carcinoma, with necrosis, in a fibrous stroma, infiltrating the marrow space of the distal phalanx.

CT revealed progressive lung, liver and spleen metastases. She expired seven months after initial diagnosis of cervical cancer, and two months after presenting with toe metastasis.

## Case 2

A 27-year-old female with history of stage IB2 poorly differentiated squamous cell carcinoma of the cervix presented to the emergency room with symptoms of pneumonia accompanied by progressive pain, swelling, and erythema of the left first metatarsal. She was diagnosed with cancer two years prior, presenting with heavy vaginal bleeding, anemia, and a 6 cm cervical mass. Biopsy of the mass showed poorly differentiated squamous cell carcinoma. She received concurrent whole pelvis chemo-radiotherapy but prior to completing treatment (37.8 out of 50.4 Gy received) was lost to follow-up for 9 months. Upon resumption of care, systemic imaging showed nodal and pancreatic metastases. After further systemic chemotherapy with six cycles of cisplatin and gemcitabine and resolution of extra-uterine disease, the patient underwent a type III radical hysterectomy, bilateral salpingo-oophorectomy and pelvic lymphadenectomy. Pathology workup showed tumor infiltration to the parametria and a close vaginal margin. She was then lost to follow up again, foregoing planned brachytherapy.

Eight months later, she re-presented with the aforementioned respiratory and podiatric symptoms. On examination, she was febrile (38.2 °C), hypoxic, tachypneic, and tachycardic, but had no leukocytosis (white blood cell count, 5,800/m<sup>3</sup>). Chest imaging revealed areas of consolidation with extensive mediastinal and hilar adenopathy, compressing the



**Fig. 2.** Images of cervical cancer toe metastasis in Case 2. A) Dorsum of the left first toe, showing diffuse erythema, scaling, and necrosis. B) Lateral view of the same toe. C) X-ray of the left foot, showing diffuse sclerosis of the first distal phalanx with soft tissue swelling. D) Hematoxylin and eosin staining of the toe following amputation, showing nests of tumor cells occupying the marrow space of the distal phalanx and invading into the bone trabeculae.

left bronchial tree and resulting in post-obstructive pneumonia, which subsequently resolved with broad-spectrum antibiotics.

Regarding her toe, she reported two months of progressive redness and discoloration beginning at the proximal nail fold, and an inability to bear weight on the involved toe. On physical examination, her left hallux was erythematous, enlarged, and necrotic-appearing, with areas of purple and black discoloration around the nail (Fig. 2A–B). It was extremely tender to palpation, but without fluctuation. Also noted were hyperpigmented, plaque-like areas of thickened skin along the left pre-tibial surface, measuring 1–2 cm in diameter. Radiographic imaging showed increased soft tissue density and swelling with sclerosis around the distal phalanx (Fig. 2C). Trans-dermal punch biopsy of the toe revealed metastatic squamous cell carcinoma. She underwent palliative amputation of the left first toe, and histology confirmed metastatic cervical cancer with invasion into the bone, soft tissue, and dermis (Fig. 2D). Prior to discharge, she was found to have brain metastasis and expired one month after admission.

## Discussion

Our cases highlight a key feature of the spreading pattern of cervical cancer. Clinicians need to be aware that cervical cancer dissemination sites include the toes. The rate of osseous metastases in cervical cancer has been quoted to be between 0.8 and 23%, usually occurring in poorly differentiated tumors, at advanced stage, and with recurrent disease (Matsuyama et al., 1989; Ratanatharathorn et al., 1994). Variations in

rates between studies may be attributable to the diagnostic method, with higher rates cited in studies utilizing autopsy findings than those detected during routine symptom-based workup. In one study of cervical cancer patients, 69% of bone metastases were only detected at autopsy (Abdul-Karim et al., 1990). Furthermore, when spread to bone was detected, patients often had extensive metastatic disease, as in our cases.

The most common sites of bony metastases include the vertebral column, specifically the lumbar spine, followed by the pelvic bones, with the distal appendicular skeleton being a distant third. Metatarsal metastases are so uncommon that only one other source mentions them (Blythe et al., 1975). Our experienced cases are valuable because they show the natural course of cervical cancer in patients with toe metastases. Spread to bone is thought to occur *via* four different methods: (i) direct extension from the primary or recurrent tumor mass in the pelvis, often accounting for spread to pelvic bones; (ii) direct extension from parenchymal and lymph node metastases, such as from the para-aortic nodes to the spine or from lungs metastases to the ribs or sternum; (iii) regional hematogenous metastases, classically spinal metastases arising from spread through Batson plexus; and (iv) systemic hematogenous metastases, accounting for metastases to distant bones, and likely the mechanism of spread in our cases (Dewdney and Selvarajah, 2010; Ratanatharathorn et al., 1994). The universal presenting symptom of these osteolytic lesions is bone pain, with occasionally associated pathologic fracture (Blythe et al., 1975). Imaging with X-ray and magnetic resonance imaging show osteolytic lesions, often adding osteomyelitis to the differential diagnosis (Dewdney and Selvarajah, 2010; Pasricha et al., 2006). Biopsy or amputation, however, proves otherwise. If any of these symptoms present, providers should have a high suspicion for bony metastases and a low threshold to order plain X-ray imaging. More systemic imaging such as bone scan or PET-CT will follow if plain imaging suspects bony metastases.

Both of the two patients received suboptimal treatment for the primary cervical tumor. For Case 1, palliative pelvic radiotherapy was not given due to distant metastases and absence of pelvic symptoms. For Case 2, the patient did not follow the radiotherapy plan and received only 75% of the scheduled dose. Therefore, these suboptimal treatments for the primary cervical tumor may contribute to more extensive metastatic disease as experienced in these cases. In addition, both of the patients received cisplatin and gemcitabine for the treatment of metastatic cervical cancer with squamous histology. Given the results of a recent clinical trial, cisplatin and paclitaxel is an alternative regimen of chemotherapy treatment (Monk et al., 2009).

Treatment options for toe metastases include palliative resection, radiation, and systemic chemotherapy, but it is important to assess the patient's prognosis prior to offering further treatment. Distant bone

metastases are frequently seen in conjunction with multiple soft tissue metastases, likely representing diffuse hematogenous spread (Blythe et al., 1975). Since the lungs are the most common site of blood-borne metastases, they are often already involved by the time metastases to distal bones are discovered, frequently resulting in death from pulmonary insufficiency (Matsuyama et al., 1989). Furthermore, 75–80% of patients die within one year of diagnosis with osseous metastases (Matsuyama et al., 1989; Ratanatharathorn et al., 1994). The cases presented above corroborate these results, as both patients underwent rapid decompensation and death within a few months of podiatric symptom onset. Both suffered from pulmonary involvement and one from brain metastases. In our literature review, only one case study described a cervical cancer patient with over four years of disease-free survival following resection of an isolated fibular metastasis (Pasricha et al., 2006). The role of radiotherapy to treat toe metastasis has not yet been proven. There were only a few cases reported in the literature, and all cases including ours underwent surgical resection. However, radiotherapy may be a possible option if an early diagnosis could be made without amputation. We conclude that metatarsal metastases in cervical cancer are usually a symptom of widespread hematogenous dissemination and thus exceedingly poor prognostic indicators. Treatment should be directed at maximizing quality of life and at providing palliation for pain using the aforementioned treatment modalities.

#### Conflict of interest statement

The authors declare that there are no conflicts.

#### References

- Abdul-Karim, F.W., Kida, M., Wentz, W.B., Carter, J.R., Sorensen, K., Macfee, M., Zika, J., Makley, J.T., 1990. Bone metastasis from gynecologic carcinomas: a clinicopathologic study. *Gynecol. Oncol.* 39, 108–114.
- Agarwal, U., Dahiya, P., Chauhan, A., Sangwan, K., Purwar, P., 2002. Scalp metastasis in carcinoma of the uterine cervix—a rare entity. *Gynecol. Oncol.* 87, 310–312.
- Blythe, J.G., Cohen, M.H., Buchsbaum, H.J., Latourette, H.B., 1975. Bony metastases from carcinoma of cervix. Occurrence, diagnosis, and treatment. *Cancer* 36, 475–484.
- Dewdney, A., Selvarajah, U., 2010. A 'hot' leg: a rare case of isolated long bone metastases from cervical cancer. *Anticancer Res.* 30, 2949–2951.
- Matsuyama, T., Tsukamoto, N., Imachi, M., Nakano, H., 1989. Bone metastasis from cervix cancer. *Gynecol. Oncol.* 32, 72–75.
- Monk, B.J., Sill, M.W., McMeekin, D.S., Cohn, D.E., Ramondetta, L.M., Boardman, C.H., Benda, J., Cella, D., 2009. Phase III trial of four cisplatin-containing doublet combinations in stage IVB, recurrent, or persistent cervical carcinoma: a Gynecologic Oncology Group study. *J Clin Oncol* 27, 4649–4655.
- Pasricha, R., Tiwari, A., Aggarwal, T., Lal, P., 2006. Carcinoma of uterine cervix with isolated metastasis to fibula and its unusual behavior: report of a case and review of literature. *J. Cancer Res. Ther.* 2, 79–81.
- Ratanatharathorn, V., Powers, W.E., Steverson, N., Han, I., Ahmad, K., Grimm, J., 1994. Bone metastasis from cervical cancer. *Cancer* 73, 2372–2379.