



Available online at
SciVerse ScienceDirect
www.sciencedirect.com

Elsevier Masson France
EM|consulte
www.em-consulte.com/en



ORIGINAL ARTICLE

Osteoid osteoma of the acetabular fossa: Five cases treated with percutaneous resection

S. Raux^a, R. Kohler^{a,*}, I. Canterino^b, F. Chotel^a, K. Abelin-Genevois^a

^a Paediatric Orthopaedics Department, Children's Hospital, Lyon Civilian Hospital Group, Lyon 1 University, Lyon, France

^b Paediatric Imaging Department, Children's Hospital, Lyon Civilian Hospital Group, Lyon 1 University, Lyon, France

Accepted: 28 January 2013

KEYWORDS

Osteoid osteoma;
Percutaneous
resection;
Acetabular fossa

Summary

Background: Osteoid osteoma is a painful benign osteogenic tumour for which the treatment objective is surgical resection of the nidus. The acetabular fossa is an uncommon site of involvement where surgical access can prove challenging.

Materials and methods: We report a case-series composed of five patients with osteoid osteoma of the acetabular fossa treated with percutaneous bone resection and drilling under computed tomography guidance.

Results: All five patients had an uneventful postoperative course with immediate pain relief that was sustained over time.

Discussion: The outcomes achieved using our percutaneous technique compare favourably with those of other percutaneous methods, most notably regarding pain relief and patient tolerance of the procedure.

Conclusion: Percutaneous bone resection and drilling under computed tomography guidance proved effective for the treatment of osteoid osteoma involving the acetabular fossa.

Level of evidence: Level IV.

© 2013 Elsevier Masson SAS. All rights reserved.

Introduction

Osteoid osteoma accounts for about 10% of all benign bone tumours. The most common location is the femur, with 40% of cases [1], but many other sites can be involved. The

acetabular fossa is one of the uncommon locations, with three of 448 cases according to Campanacci [2]. Pain is the presenting symptom. The pain is often nocturnal and usually responds to anti-inflammatory drugs such as aspirin. Osteoid osteoma selectively develops in adolescents and young adults and exhibits a distinctive tempo of evolution [3]. Irreversible joint damage may occur if the tumour develops near a joint [4]. Surgery is the main treatment. Over the past two decades, percutaneous surgical methods (resection or thermal ablation) have superseded open en-bloc resection.

* Corresponding author. Paediatric Orthopaedics Department, Mother-Child Hospital, 59, boulevard Pinel, 69677 Bron cedex, France. Tel.: +33 427 869 208.

E-mail address: remi.kohler@chu-lyon.fr (R. Kohler).

Table 1 Main features in our five patients.

Patient	Age at surgery (years)	Sex	Radiological nidus size (mm)	Operative time (min), incision to closure	Histology	Time to re-evaluation (years)	Outcome
#1	16.5	M	11	80	Not interpretable	1	Full recovery
#2	13	F	11	50	Nidus lesion	1	Full recovery
2 failed thermal ablation attempts							
#3	11	F	6	60	Not interpretable	1.5	Full recovery
#4	27	M	8	80	Not sent	1	Full recovery
#5	17	F	7	75	Not interpretable	3	Full recovery
2 failed thermal ablation attempts							

We studied a series of five patients with osteoid osteoma of the acetabular fossa. All five patients were treated with percutaneous bone resection and drilling (PBRD) under computed tomography (CT) guidance. This method developed in our centre since 1987 [5] has the advantage of being minimally invasive. It has proved useful for osteoid osteomas at deep sites such as the femoral neck [6].

The objective of this study was to describe the postoperative course in patients with acetabular osteoid osteomas treated with PBRD and to evaluate the efficacy of this treatment method.

Material and methods

Between July 1991 and December 2011, five of the 103 patients who underwent PBRD at our centre had osteoid osteomas of the acetabular fossa. The symptoms consisted of groin pain and a moderate limp. The diagnosis was consistently established by performing bone scintigraphy followed by CT, in compliance with published recommendations [2]. Table 1 reports the main features in the five patients. In all five cases, the nidus was located in the acetabular fossa, i.e., in the Y cartilage (which was closed or undergoing closure). All five patients reported groin pain on the side of the tumour, four patients out of five had insomnia due to nocturnal pain, and three patients out of five responded to anti-inflammatory drugs. Two attempts at thermal ablation were performed in each of two patients before the use of PBRD: laser ablation was performed 8 and 9 months after pain onset in patient #2, followed by PBRD 3 months later; and radiofrequency thermal ablation was performed 8 and 10 months after symptom onset in patient #5, who finally underwent PBRD 18 months after symptom onset.

Surgery was performed under general anaesthesia, in the CT suite, under CT-guidance allowing the acquisition of well-defined views at each stage of the procedure. Thus, close collaboration between the surgeon and radiologist was crucial. Mean operative time (identification and excision of the tumour) was 75 minutes. Mean radiation doses delivered during the procedure were 270 mGy.cm [190–360 mGy.cm] to the patient and 0.02 μ Sv to the surgeon.

The principles of PBRD are simple and well standardised [7]. The acetabular lesions were treated via a posterior approach with the patient in the prone position. After identification of the nidus, the best CT slice for introduction of the instruments was selected. A 2-cm incision was made and a wire was aimed at the nidus. The orientation of the wire was checked in the selected CT slice. The wire was then used to guide the introduction of the various specific ancillary instruments: drill bit, 9-mm trephine, and burr (Fig. 1). The wire, which was the first instrument inserted into the bone, was introduced via the same posterior approach through the gluteus maximus muscle between the pudendal nerve medially and the sciatic nerve laterally, (Fig. 2) then through the body of the pubis into the nidus. Progression of the various instruments towards the osteoid osteoma was painstakingly controlled on the selected CT slice. The nidus was removed within a bone cylinder about 1 cm in diameter (Fig. 3), which was sent to the pathology laboratory for examination. Burring of the nidus site was the last step of the resection phase. Mean hospital stay length, counting the day of the surgical procedure, was 3 days (3 days in four patients and 2 days in one patient). For the first few days, weight bearing was partial with crutches to avoid pain. In all five patients, the time without participation in sports was 1 month.

Results

All five patients were re-evaluated at least 1 year after surgery, which is the interval needed to assess outcomes and rule out a recurrence [1]. No complications were recorded during follow-up. The clinical outcome was favourable in all five patients, with prompt or immediate resolution of the pain, no recurrence, and a return to normal activities. The physical examination performed during the postoperative follow-up visit showed normal range of motion of the hip. Histological confirmation of the diagnosis was not obtained consistently (Table 1). No vascular or nervous complications were recorded. Follow-up CT confirmed the full recovery 1 year after surgery.



Figure 1 Ancillary equipment needed for percutaneous bone resection and drilling.

Discussion

PBRD under CT-guidance provides highly satisfactory outcomes in patients with osteoid osteomas of the acetabular fossa. The procedure is simple when performed by an experienced operator. The posterior approach carries little risk

of injury to the blood vessels or sciatic nerve. The instruments are readily introduced along the body of the pubis, at a 20° angle from the vertical, despite the depth of the lesion.

The acetabular fossa is a rare location of osteoid osteoma. Thus, Campanacci identified three cases among

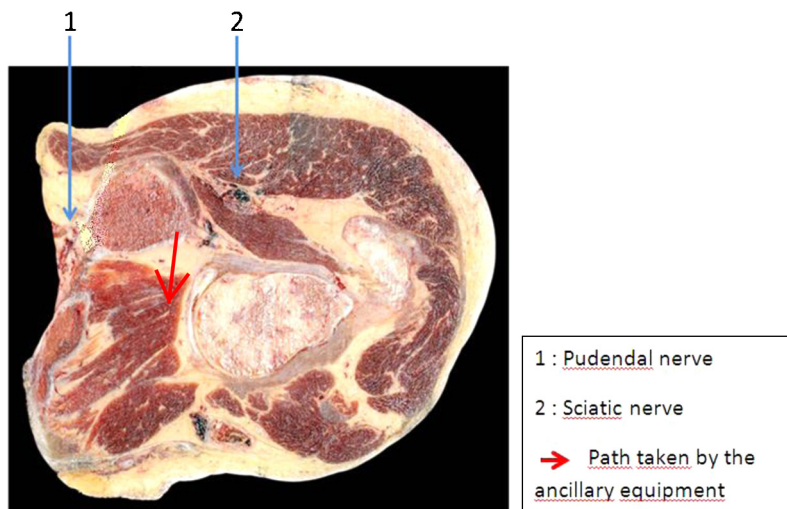


Figure 2 Anatomic section showing the trajectory of the instruments used to remove an osteoid osteoma of the acetabular fossa (posterior approach).

With permission from the Nantes pathology laboratory (Prof. Geffroy).

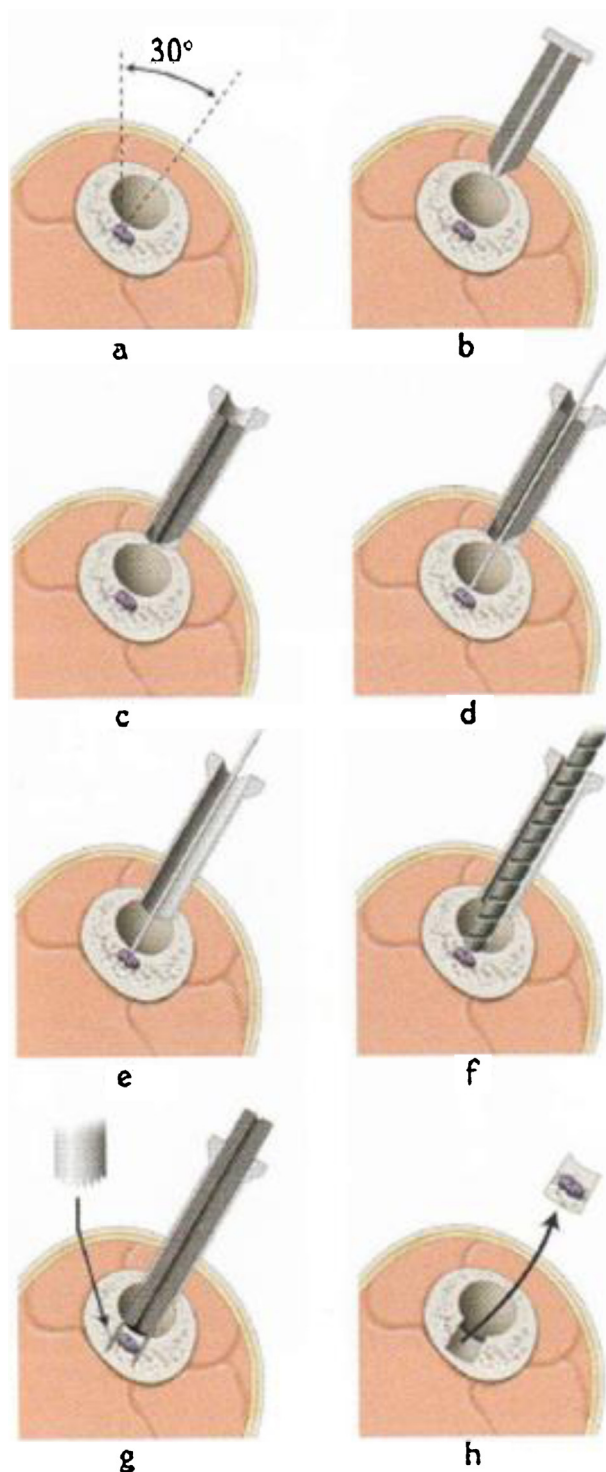


Figure 3 Steps of the PBRD procedure: a: evaluation of the aiming angle and penetration point on the scout view; b: introduction of the trocar with its obturator; c: introduction of the sheath over the trocar (the serrated edge bites into the bone); d: the wire with a threaded tip is aimed at the nidus then inserted into or even beyond the nidus; e: the trocar is removed; f: a bit is introduced along the wire, which now serves as a guide, until contact with the nidus is achieved; g: the wire is then used to guide the trephine, which serves to remove the nidus; h: and the cylinder is removed and sent to the pathology laboratory.

448 patients with osteoid osteoma, a rate of only 0.67%. We found a higher rate of 5/103, i.e., 4.85%. The low rate of acetabular osteoid osteomas is among the challenges to optimal management, as it results in limited surgeon experience with the therapeutic procedure, particularly as the depth of the lesion constitutes a major obstacle to accurate access. The conventional surgical method for acetabular lesions described by several authors [8,9] is a complex procedure that involves hip dislocation, a long operative time, an extensive surgical approach, and a more difficult postoperative course with a risk of necrosis.

The histological examination of PBRD specimens was frequently negative, because of the mechanical lesions to the bone cylinder. The absence of histological documentation deprives the surgeon of important information. However, analysis of the CT images during the procedure shows whether complete resection is achieved [10]. Thus, in patient #5 of our case-series, the initial trajectory was immediately recognised as suboptimal by the operator, as the nidus remained visible on the infra-jacent CT slice (Fig. 4). The high degree of accuracy of the intraoperative CT images indicates whether resection is complete or incomplete. Our results are comparable to those obtained by Xu et al. [11] in four patients with osteoid osteomas of the acetabular fossa treated with PBRD under CT-guidance. In both studies, the sample sizes are too small for statistical analyses.

We believe it is of interest to compare our results with those obtained using another minimally invasive technique, thermal ablation (which never provides histological confirmation of the diagnosis). Radiofrequency thermal ablation has produced good results in case-series of osteoid osteomas in a range of locations, with variations across studies: Neuman et al. reported 97% of good results [12] and Hoffman et al. [13] 92%. Of 21 patients with osteoid osteomas in atypical locations studied by Akhlagpoor et al. [14], three had lesions in the acetabular fossa. All three patients achieved a full recovery after radiofrequency thermal ablation, indicating that this method is also effective at this location. Nevertheless, one of our patients required PBRD after two failed attempts at radiofrequency thermal ablation. The temperature increase during radiofrequency thermal ablation cannot be fully controlled by the operator and is a potential source of damage to adjacent structures such as the bone or cartilage near the hip joint.

Laser ablation also produces good results. However, Roqueplan et al. [15] and Gangi et al. [16] reported higher failure rates with laser ablation in patients younger than 18 years of age and in those with osteoid osteomas larger than 12 mm in diameter. Gangi et al. [16] reported pain recurrence in six patients among a heterogeneous population of 114 patients with osteoid osteomas in a variety of locations; two of these recurrences are described as occurring within the hip joint (possible involvement of the

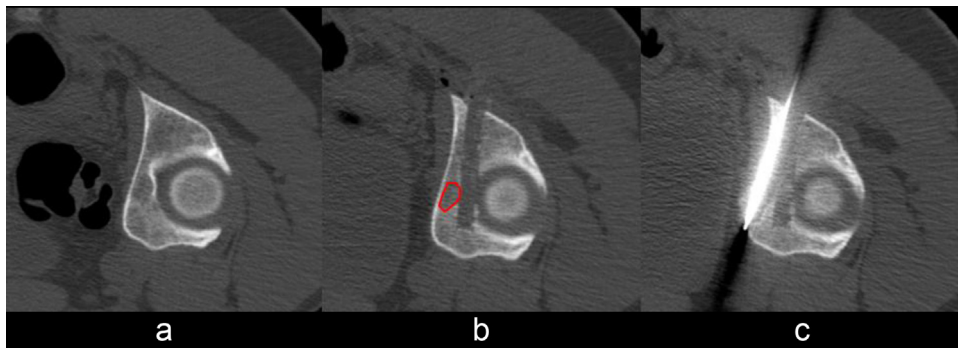


Figure 4 Computed tomography slices illustrating the various steps of the PBRD procedure in patient #5; a: nidus located in the deep acetabulum; b: the initial trajectory was not accurate, missing the nidus, which was located more medially (highlighted in red); c: the operator corrected the trajectory under computed tomography guidance and removed the nidus.

acetabular fossa?). We believe that the choice of PBRD in our case-series instead of laser ablation was appropriate, as four of our five patients were younger than 18 years of age. Mean nidus size as evaluated radiologically was 8.6 mm [6–11 mm]. Nidus size is not always easy to evaluate, as the nidus contours may not be clearly visible within the surrounding bone sclerosis. As with radiofrequency thermal ablation, two attempts at laser ablation were performed in one of our patients before PBRD.

Several cases of arthroscopic resection of acetabular osteoid osteomas have been reported [17–19]. We have no experience with this technique, which we believe raises technical challenges. Indeed, removal of the tumour via an intra-articular approach requires penetration of the acetabular cartilage, which is preserved during PBRD. In addition, postero-inferior lesions are difficult to access by hip arthroscopy [18].

Finally, computer-assisted navigation can be used for osteoid osteoma resection. Wang et al. used this method successfully in 26 patients with osteoid osteomas in various locations, including two in the acetabular fossa [20]. We have no experience with this method, which we feel has the major disadvantage of not providing intraoperative CT confirmation that resection is complete.

In conclusion, the specific challenges raised by management of acetabular osteoid osteomas are very satisfactorily met by PBRD under CT-guidance. The immediate postoperative course was uneventful in all five of our patients, who achieved primary intention healing and experienced no recurrences. Nevertheless, considerable expertise with the PBRD technique is required.

Disclosure of interest

The authors declare that they have no conflicts of interest concerning this article.

References

- [1] Kohler R. Ostéome ostéοide. In: Lascombes P, Lefort G, editors. *Tumeurs osseuses bénignes de l'enfant*. Montpellier: Sauramp medical; 1996. p. 15–28 [In French].
- [2] Campanacci M. Osteoid osteoma. In: *Bone and soft tissue tumors*. New York: Springer Ed; 1990, p. 355–73.
- [3] Chotel F, Franck F, Solla F, et al. Osteoid osteoma transformation into osteoblastoma: fact or fiction? *Orthop Traumatol Surg Res* 2012;98:98–104.
- [4] Graham HK, Laverick M, Cosgrove A, Crone M. Minimally invasive surgery for osteoid osteoma of the proximal femur. *J Bone Joint Surg* 1993;75:115–8.
- [5] Kohler R, Joffre P. Treatment of osteoid osteoma by percutaneous drill resection with computed tomography control: a study of 12 cases. *J Pediatr Orthop* 1993;2:78–82.
- [6] Muscolo DL, Velan O, Pineda Acero G, Ayerza MA, Calabrese ME, Santini Araujo E. Osteoid osteoma of the hip. *Clin Orthop Relat Res* 1995;310:170–5.
- [7] Kohler R, Dohin B. Forage résection osseux percutané (FROP) d'un ostéome ostéοide du tibia. In: Carlioz H, Kohler R, editors. *Orthopédie pédiatrique—Membre inférieur et bassin*. Paris: Ed. Masson; 2005. p. 215–8 [In French].
- [8] Morin O, Carlioz H. Ostéome ostéοide du fond du cotyle chez l'enfant. À propos d'une observation. *Rev Chir Orthop* 1986;72:501–4 [In French].
- [9] Karray S, Zlitni M, Karray M, et al. Osteoid osteoma of the acetabulum. *Int Orthop* 1993;17:54–6.
- [10] Parlier-Cuau C, Nizard R, Champsaur P, Hamze B, Quillard A, Laredo JD. Osteoid osteoma of the acetabulum. *Clin Orthop Relat Res* 1999;365:167–74.
- [11] Xu JQ, Zhang WB, Shen CW, Ding XY, Lu Y. CT-guided percutaneous removal of osteoid osteoma. *Zhonghua Wai Ke Za Zhi* 2005;43:1063–5.
- [12] Neumann D, Berka H, Dorn U, Neureiter D, Thaler C. Follow-up of thirty-three computed-tomography-guided percutaneous radiofrequency thermoablations of osteoid osteoma. *Int Orthop* 2012;36:811–5.
- [13] Hoffmann RT, Jakobs TF, Kubisch CH, et al. Radiofrequency ablation in the treatment of Osteoid Osteoma—5 years experience. *Eur J Radiol* 2010;73:374–9.
- [14] Akhlaghpour S, Ahari AA, Shabestari AA, Alinaghizadeh MR. Radiofrequency ablation of osteoid osteoma in atypical locations. *Clin Orthop Relat Res* 2010;468:1963–70.
- [15] Roqueplan F, Porcher R, Hamzé B, et al. Long-term results of percutaneous resection and interstitial laser ablation of osteoid osteomas. *Eur Radiol* 2010;20:209–17.
- [16] Gangi A, Alizadeh H, Wong L, Buy X, Dietemann JL, Roy C. Osteoid osteoma: percutaneous laser ablation and follow-up in 114 patients. *Radiology* 2007;242:293–301.

- [17] Alvarez MS, Moneo PR, Palacios JA. Arthroscopic extirpation of an osteoid osteoma of the acetabulum. *Arthroscopy* 2001;17:768–71.
- [18] Chang BK, Ha YC, Lee YK, Hwang DS, Koo KH. Arthroscopic excision of osteoid osteoma in the posteroinferior portion of the acetabulum. *Knee Surg Sports Traumatol Arthrosc* 2010;18:1685–7.
- [19] Barnhard R, Raven EE. Arthroscopic removal of an osteoid osteoma of the acetabulum. *Knee Surg Sports Traumatol Arthrosc* 2011;19:1521–3.
- [20] Wang T, Zhang Q, Niu XH, et al. Computer navigation-guided excision of osteoid osteomas. *Zhonghua Wai Ke Za Zhi* 2011;49:808–11.