

Emboic Potential, Prevention and Management of Mural Thrombus Complicating Anterior Myocardial Infarction: A Meta-Analysis

PAUL T. VAITKUS, MD, *ELLIOT S. BARNATHAN, MD, FACC

Burlington, Vermont and Philadelphia, Pennsylvania

Objectives. The management of mural thrombus complicating acute anterior myocardial infarction remains controversial in part because of the small size of studies on this topic. We performed a meta-analysis of published studies to address three questions: 1) What is the embolic risk of mural thrombi after myocardial infarction? 2) What is the impact of systemic anticoagulation in reducing the embolic risk of mural thrombi? 3) What is the impact of systemic anticoagulation, thrombolytic therapy and antiplatelet therapy in preventing mural thrombus formation?

Methods. Studies were identified by a computerized and manual search and were included if they were published in manuscript form in the English-language literature. Pooling of data was performed by calculating the Mantel-Haenszel odds ratio and an event rate difference by the method of DerSimonian and Laird.

Results. The odds ratio for increased risk of emboli in the presence of echocardiographically demonstrated mural thrombus (11 studies, 856 patients) was 5.45 (95% confidence interval [CI] 3.02 to 9.83), and the event rate difference was 0.09 (95% CI 0.03 to 0.14). The odds ratio of anticoagulation versus no anticoagulation in preventing embolization (seven studies, 270 patients) was

0.14 (95% CI 0.04 to 0.52) with an event rate difference of -0.33 (95% CI -0.50 to -0.16). The odds ratio of anticoagulation versus control in preventing mural thrombus formation (four studies, 307 patients) was 0.32 (95% CI 0.20 to 0.52), and the event rate difference was -0.19 (95% CI -0.09 to -0.28). The odds ratio for thrombolytic therapy in preventing mural thrombus (six studies, 390 patients) was 0.48 (95% CI 0.29 to 0.79) with an event rate difference of -0.16 (95% CI 0.10 to -0.42), whereas for antiplatelet agents (two studies, 112 patients) the odds ratio was 1.43 (95% CI 0.04 to 56.8) with an event rate difference of 0.16 (95% CI -0.20 to 0.52).

Conclusions. This analysis supports the hypotheses that 1) mural thrombus after myocardial infarction poses a significantly increased risk of embolization, 2) the risk of embolization is reduced by systemic anticoagulation, and 3) anticoagulation can prevent mural thrombus formation. Thrombolytic therapy may prevent mural thrombus formation, but evidence for a similar benefit of antiplatelet therapy is lacking.

(*J Am Coll Cardiol* 1993;22:1004-9)

Left ventricular mural thrombus has been frequently identified at autopsy (1-5) and by two-dimensional echocardiography (6-16) in patients with acute anterior myocardial infarction. However, mural thrombus formation in inferior myocardial infarctions is rare (6,7). Overall, 1.5% to 3.6% of patients with acute myocardial infarction have a complicating stroke, often thought to be embolic from a mural thrombus (17,18). Despite much recent investigation (19,20), there is no consensus on appropriate strategies for screening and treating mural thrombi. Much of the controversy arises from apparently divergent estimates of the frequency of embolic complications from mural thrombi and on the effects of antithrombotic treatment in preventing the formation or the embolization of mural thrombi. The contradictory results arise, in part, from the small size of the individual studies.

From the Cardiology Unit, Medical Center Hospital of Vermont, University of Vermont, Burlington, Vermont and the *Cardiovascular Division, Department of Medicine, University of Pennsylvania School of Medicine, Philadelphia, Pennsylvania.

Manuscript received October 2, 1992; revised manuscript received February 8, 1993; accepted April 7, 1993.

Address for correspondence: Paul T. Vaitkus, MD, Cardiology Unit, Medical Center Hospital of Vermont, Burlington, Vermont 05401.

We therefore performed a meta-analysis to reconcile the apparently conflicting data for the following three questions:

1) What is the relative risk of embolic events in patients with echocardiographically demonstrated mural thrombus after an acute anterior myocardial infarction compared with those without thrombus? 2) What is the effect of systemic anticoagulation in reducing embolic complications of mural thrombi? 3) What is the impact of systemic anticoagulation, thrombolytic therapy and antiplatelet therapy in preventing mural thrombus formation?

Methods

Studies were identified by means of a computerized literature search (MEDLINE, BRS Colleague) supplemented by a manual review of references cited in the bibliographies of these studies. Studies were included for analysis if they were published in manuscript form in English-language peer-reviewed journals and either included only patients with acute anterior Q wave myocardial infarction or presented data in a manner that permitted separation of patients with anterior versus inferior myocardial infarction. Only data on patients with anterior myocardial infar-

tion were included in the analyses. Furthermore, studies were required to use two-dimensional echocardiography to identify left ventricular thrombus. In the therapeutic trials we required studies to simultaneously evaluate treated and control groups. Studies published only in abstract form or in books or monographs not subject to peer review, studies using historical controls and studies combining anterior and inferior infarctions were excluded.

For each study we constructed a 2 × 2 contingency table, allowing us to calculate an event rate difference, an odds ratio, and a 95% confidence interval for each of these variables. Pooling of data was undertaken by calculating the Mantel-Haenszel odds ratio with the Robins, Greenland and Breslow estimator of variance (21). We also calculated a pooled event rate difference by the method of DerSimonian and Laird (22). Besides differing in units of measure, in the presence of heterogeneity, the DerSimonian and Laird method yields more conservative statistical tests of the pooled treatment effect with relatively wider confidence intervals than does the Mantel-Haenszel method. As a test of heterogeneity, we calculated a Q statistic (22). A statistically significant result of the Q statistic suggests statistical heterogeneity among the studies included for analysis.

The trials included for analysis were reported over a span of 11 years. We examined whether improvements in echocardiographic technology during these years affected the reported outcomes by studying the temporal trends of two variables: the reported incidence rate of mural thrombi and the reported treatment effect.

Results

The embolic risk of mural thrombus (Fig. 1). Eleven studies (6-16) enrolling a total of 856 patients were included in the analysis. Individually, 10 of the 11 studies reported that patients with echocardiographically demonstrated mural thrombus were at higher risk of embolic events than patients without mural thrombi. However, nine of the studies were sufficiently small that their 95% confidence intervals (CI) were consistent with either an increased or decreased risk of embolization. The pooled odds ratio for increased risk of embolization for the 11 studies was 5.45 (95% CI: 3.02 to 9.83), and the pooled event rate difference was 0.09 (95% confidence interval: 0.03 to 0.14). Both of the pooling methods were consistent with the hypothesis that mural thrombus poses an increased risk for embolic complications after a myocardial infarction. The Q statistic was 18.6 (p < 0.01), suggesting heterogeneity among the studies included for analysis.

Does anticoagulation reduce the embolic risk of mural thrombi? (Fig. 2). Seven studies (6-8,16,23-25) enrolling a total of 270 patients were pooled in this analysis. Although all seven studies presented data suggesting that systemic anticoagulation of patients with mural thrombi reduces embolic complications, this trend reached statistical significance in only three of the trials. The odds ratio was 0.14

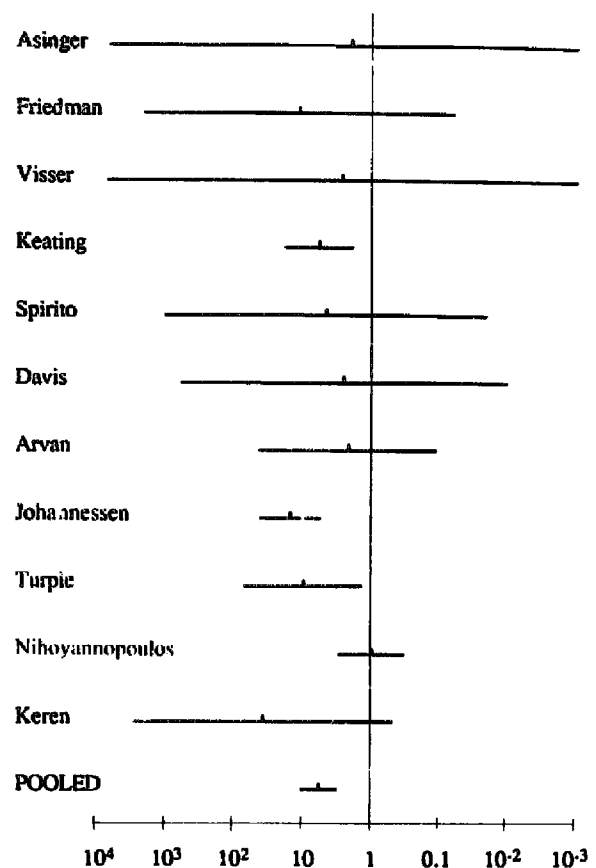


Figure 1. Odds ratios (dots) and 95% confidence intervals (bars) for 11 studies (6-16) addressing the embolic risk of echocardiographically demonstrated mural thrombus after anterior myocardial infarction. An odds ratio >1.0 indicates an increased risk of embolism with mural thrombi.

(95% CI 0.04 to 0.52), and the pooled event rate difference was -0.33 (95% CI -0.50 to -0.16), supporting the hypothesis that anticoagulation reduces embolic events. The Q statistic was 18.8 (p < 0.01).

Does antithrombotic therapy prevent mural thrombus formation? (Fig. 3 to 5). *Anticoagulant therapy.* Four studies (11,12,14,26) enrolling 307 patients were included in this analysis. Three of the four studies revealed a trend in favor of anticoagulation. In one of these studies the trend was statistically significant (Fig. 3). The odds ratio was 0.32 (95% CI 0.20 to 0.52), and the pooled event rate difference was -0.19 (95% CI -0.09 to -0.28), both suggesting a significant decrease in mural thrombus formation with anticoagulation. The Q statistic was 3.4 (p = NS).

Thrombolytic therapy (Fig. 4). Six studies (16,27-31) enrolling 390 patients were pooled. Five of the six studies reported a trend in favor of thrombolysis, with one achieving statistical significance. However, the confidence intervals of all six studies encompassed the possibility that thrombolytic therapy was associated with a reduction of risk of mural thrombus formation. The pooled odds ratio was 0.48 (95% CI 0.29 to 0.79), suggesting a significant decrease in the inci-

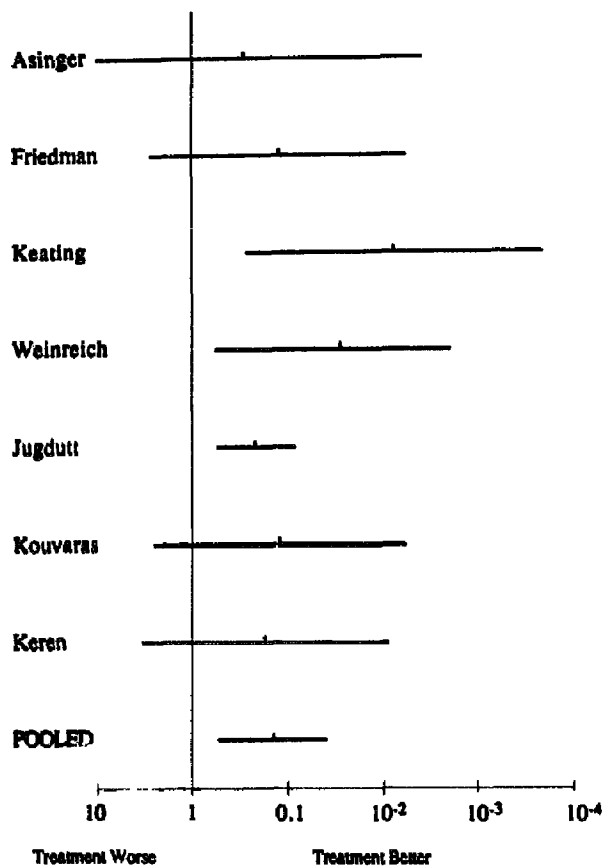


Figure 2. Odds ratios (dots) and 95% confidence intervals (bars) for seven studies (6-8,16,23-25) addressing the efficacy of systemic anticoagulation in reducing the embolic risk of mural thrombi after anterior myocardial infarction.

ence of mural thrombi. The event rate difference was -0.16 (95% CI 0.10 to -0.42). This result is compatible with the hypothesis that thrombolytic agents reduce the incidence of mural thrombus but does not achieve statistical significance. The Q statistic was 15.1 ($p < 0.01$).

Antiplatelet therapy (Fig. 5). Two studies (32,33) enrolling 112 patients were pooled with an odds ratio of 1.43 (95% CI 0.04 to 56.8) and an event rate difference of 0.16 (95% CI -0.20 to 0.52), both failing to demonstrate a significant decrease in mural thrombus with antiplatelet therapy. The Q statistic was 2.8 ($p = \text{NS}$).

Temporal trends. Neither the reported incidence of mural thrombi in untreated control subjects (mean $38 \pm 12\%$, range 19% to 68%) nor any of the treatment effects outlined earlier demonstrated a significant relation to the year of publication of the report.

Discussion

A randomized controlled, blinded, prospective clinical trial is widely regarded as the most appropriate means of addressing a specific clinical question. However, when relatively small studies are undertaken, their small size leads to

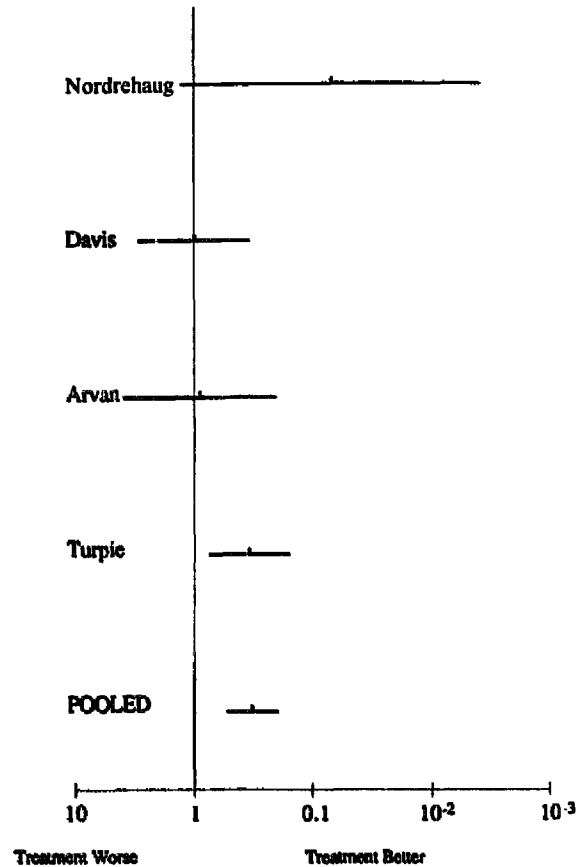


Figure 3. Odds ratios (dots) and 95% confidence intervals (bars) for four studies (11,12,14,26) addressing the efficacy of systemic anticoagulation in reducing the incidence of mural thrombi after anterior myocardial infarction.

a low statistical power to detect differences between groups of patients. This limitation can result in apparently conflicting results among a group of small studies addressing the same question. By pooling data from a number of studies, a meta-analysis may allow these conflicting results to be resolved in a formal, quantitative manner. In the presence of statistical heterogeneity, as in the case of several of the present analyses, the results of a meta-analysis need to be interpreted cautiously.

Our meta-analysis demonstrated that the risk of embolic complications in patients with echocardiographically demonstrated mural thrombus after acute anterior myocardial infarction is increased fivefold over that in patients without mural thrombus. The absolute increase in risk is approximately 9% (2% risk in patients without thrombus, 11% risk in patients with thrombus). Of the 11 studies included in our analysis, only 1 suggested that mural thrombus posed no added risk of embolization and concluded that anticoagulation in these patients is not justified (15). However, the confidence interval of this study included the possibility that mural thrombus does pose an excess risk. The apparent lack of excess risk in this one small study may be attributable to a beta error. By pooling the 11 studies, the power is increased, so that the increased embolic risk becomes evident.

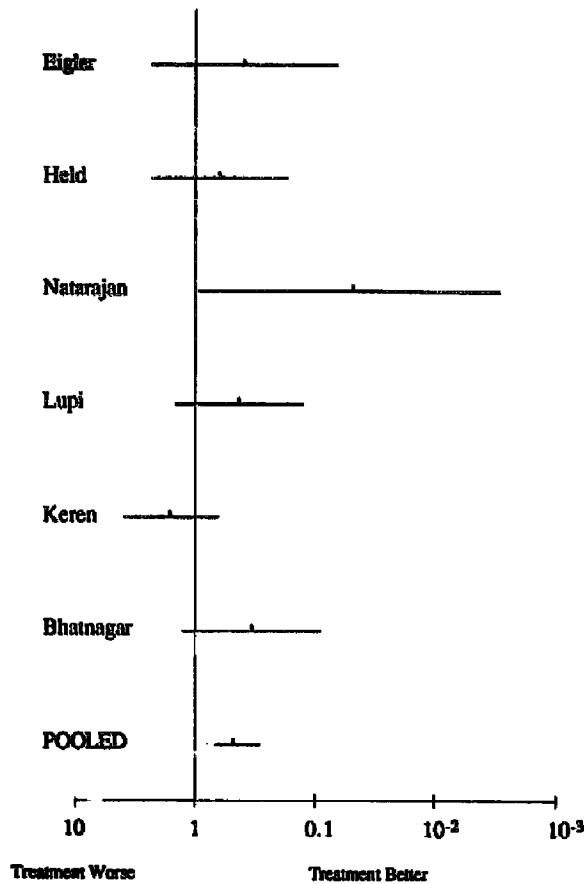


Figure 4. Odds ratios (dots) and 95% confidence intervals (bars) for six studies (16,27-31) addressing the efficacy of thrombolytic therapy in reducing the incidence of mural thrombi after anterior myocardial infarction.

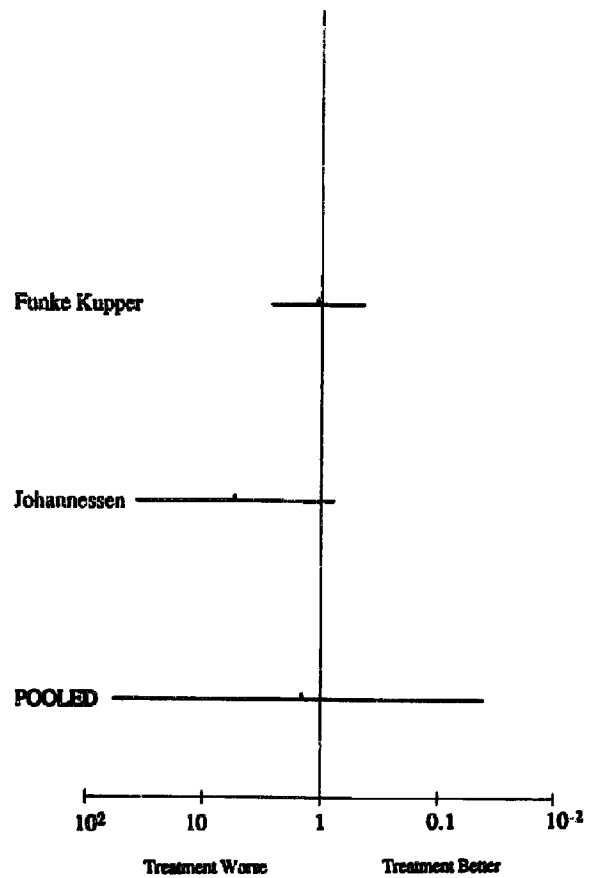


Figure 5. Odds ratios (dots) and 95% confidence intervals (bars) for two studies (32,33) addressing the efficacy of antiplatelet agents in reducing the incidence of mural thrombi after anterior myocardial infarction.

A meta-analysis of anticoagulation administered indiscriminately to all patients with a diagnosis of acute myocardial infarction has shown a reduced incidence of stroke (17). Because patients with acute anterior myocardial infarction have been identified as being at greatest risk of mural thrombus formation (6,7), it would seem logical that anticoagulation in this setting would prove particularly beneficial. The results of our current meta-analysis support the hypothesis that systemic anticoagulation in patients with echocardiographically demonstrated mural thrombus reduces the incidence of embolic events. Embolism occurred eight times more frequently in untreated patients, resulting in an absolute risk difference of 33%.

In devising a strategy of screening for and treating mural thrombus, one is confronted with a dilemma of timing of diagnostic and therapeutic maneuvers. Mural thrombi can form as late as 8 to 10 days after myocardial infarction (19,32,34). Thus, maximal sensitivity for echocardiography would be achieved by delaying this study until the 10th day after myocardial infarction. However, because the risk of embolism is greatest in the 1st week after infarction (18,19,34), a strategy of delaying therapy until the echocardiographic study is performed may prove futile. Further-

more, the absence of an echocardiographically demonstrated thrombus does not confer absolute protection against embolism. In our pooled analysis, 24% of instances of embolism occurred in patients without mural thrombi and, conversely, 2.2% of patients without mural thrombi had embolism. Therefore, any strategy relying on the echocardiographic identification of mural thrombi cannot be uniformly effective in preventing embolism. Recently, Delemarre et al. (35) demonstrated that abnormal apical flow patterns identified by Doppler echocardiography within the 1st 24 h after myocardial infarction accurately identified patients at risk of subsequent mural thrombus formation with no cases of false negative examinations. If these findings are confirmed by additional investigations, Doppler flow studies may emerge as an effective means of early identification of patients who should receive anticoagulation. To further refine the risk stratification of patients with mural thrombi, several studies (13,36-39) have examined the relation between the morphologic characteristics of the mural thrombus and embolic risk. Although thrombus protuberance and mobility identify a group of patients at particularly high risk of embolism, the absence of these characteristics does not preclude the need for anticoagulation. Up to 40% of instances of embolism

occur in patients whose thrombi are neither protuberant nor mobile (13). In addition, no study has examined whether a strategy of providing selective anticoagulation only for patients with mobile or protuberant thrombi is effective. At present it seems prudent to treat all patients with identifiable mural thrombi with anticoagulation.

Our meta-analysis supports a role for systemic anticoagulation in preventing mural thrombus formation after an acute anterior myocardial infarction. Evidence for a similar benefit of antiplatelet agents is lacking at present. Thrombolytic agents could be expected to prevent mural thrombi through direct antithrombotic effects and by preserving the viability of myocardium and preventing wall motion abnormalities.

Our analysis of the impact of thrombolysis revealed a statistically significant result in terms of the odds ratio calculation, but the trend favoring thrombolysis by the method of DerSimonian and Laird (22) failed to reach statistical significance. However, scrutiny of the data on thrombolytic therapy reveals that the failure of the trend in favor of thrombolysis to reach statistical significance is largely due to a single outlier study. Pragmatically, this issue may not be of major importance. Thrombolysis is undertaken with the primary goal of achieving coronary artery patency, rather than preventing mural thrombi. Furthermore, current practice usually involves the administration of systemic anticoagulation after thrombolysis to prevent reocclusion of the coronary artery. Several studies (40,41) of examining the duration of anticoagulation after thrombolytic therapy for myocardial infarction have suggested that 24-h regimens of anticoagulation are as effective as longer regimens in preventing recurrent myocardial ischemia. However, on the basis of considerations of the salutary effects of anticoagulation in preventing mural thrombus formation and embolic events, a longer regimen may be advocated.

Limitations of the study. Pooling of data from different trials may obscure important differences in the designs of the trials. Assessment of heterogeneity with methods such as the calculation of the *Q* statistic addresses the issue of statistical heterogeneity among the studies pooled but not methodologic heterogeneity. Ideally, reported treatment outcome could be analyzed as a function of a given methodologic variable, such as intensity of treatment, to examine whether the differences in methodology have a material impact on the treatment result (42). However, for most of the methodologic variables that could conceivably influence the treatment outcomes in our meta-analysis, insufficient data were provided in the individual reports to undertake such an analysis.

During the 1980s, significant improvements in echocardiographic technology may have affected the results of the trials included in the present analysis. However, all of the studies utilized two-dimensional echocardiography, and we were unable to demonstrate a temporal trend either for the reported incidence of mural thrombus or for the reported therapeutic effect.

Another important methodologic difference was in the timing of echocardiography. As previously discussed, mural

thrombi can form at various times during the 1st 10 days after myocardial infarction. Thus, the maximal sensitivity for detecting mural thrombus would be achieved by performing serial echocardiographic studies throughout this period. Few of the studies incorporated this strategy, and details of the timing of echocardiography were absent in several reports.

Differences in the assessment of anticoagulation could also have affected the reported results, including differences in the assays used to assess anticoagulation, as well as the degree of anticoagulation that was pursued. None of the trials reported data on the frequency of adequate or inadequate anticoagulation among treated patients. Although the importance of the standardized International Normalized Ratio method for reporting prothrombin times has been advocated for nearly a decade (43), this has achieved widespread attention only recently (44) and was not incorporated by any of the trials included in our analysis.

Another source of heterogeneity among the thrombolytic trials and antiplatelet trials was the use of different therapeutic agents in the various trials. However, a recent study from the GISSI-2 investigators (45) revealed no difference in risk of mural thrombus between patients receiving streptokinase or tissue plasminogen activator.

The morphologic characteristics predicting a high embolic risk were only rarely described in the studies included in our analysis. Therefore, we could not analyze the impact of this variable on outcome. However, as mentioned, this issue may not be of clinical importance because there are no available data to support the hypothesis that withholding anticoagulant therapy from patients with nonprotuberant, nonmobile thrombi is a sound strategy.

One limitation in our analysis of antiplatelet therapy was the possibility of a beta-error. To achieve 90% certainty of detecting a 50% reduction in mural thrombus formation by antiplatelet agents (a treatment effect similar in magnitude to those of anticoagulation and thrombolysis), there would need to be 254 patients in the pooled analysis or approximately double the number we had. Therefore, we cannot confidently conclude that antiplatelet therapy is with or without benefit.

Conclusions. The results of this meta-analysis support the hypothesis that the presence of an echocardiographically demonstrated mural thrombus after an acute anterior myocardial infarction poses a significantly increased risk of embolization. They also support a role for systemic anticoagulation in reducing both the incidence of mural thrombi after acute myocardial infarction and the risk of embolization. Thrombolytic agents may be effective in reducing the incidence of mural thrombi, but evidence for a similar benefit of antiplatelet agents is lacking.

References

1. Tulloch JA, Gilchrist AR. Anticoagulants in treatment of coronary thrombosis. *Br Med J* 1950;2:965-71.
2. Burton CR. Anticoagulant therapy of recent cardiac infarction. *Can Med Assoc J* 1954;70:404-8.

3. Drapkin A, Merskey C. Anticoagulant therapy after acute myocardial infarction. *JAMA* 1972;222:541-8.
4. Anticoagulants in acute myocardial infarction. *JAMA* 1973;225:724-9.
5. Davies MJ, Woolf N, Robertson WB. Pathology of acute myocardial infarction with particular reference to occlusive coronary thrombi. *Br Heart J* 1976;38:659-64.
6. Asinger RW, Mikell FL, Elsperger J, Hodges M. Incidence of left ventricular thrombosis after acute transmural myocardial infarction. *N Engl J Med* 1981;305:297-302.
7. Friedman MJ, Carlson K, Marcus FI, Woolfenden JM. Clinical correlations in patients with acute myocardial infarction and left ventricular thrombus detected by two-dimensional echocardiography. *Am J Med* 1982;72:894-8.
8. Keating EC, Gross SA, Schlamowitz RA, et al. Mural thrombi in myocardial infarctions. *Am J Med* 1983;74:989-95.
9. Visser CA, Kan G, Lie KI, Durrer D. Left ventricular thrombus following acute myocardial infarction: a prospective serial echocardiographic study of 96 patients. *Eur Heart J* 1983;4:333-7.
10. Spirito P, Bellotti P, Chiarella F, Domenicucci S, Sementa A, Vecchio C. Prognostic significance and natural history of left ventricular thrombi in patients with acute anterior myocardial infarction: a two-dimensional echocardiographic study. *Circulation* 1985;72:774-80.
11. Davis MJ, Ireland MA. Effect of early anticoagulation on the frequency of left ventricular thrombi after anterior wall acute myocardial infarction. *Am J Cardiol* 1986;57:1244-7.
12. Arvan S, Boscha K. Prophylactic anticoagulation for left ventricular thrombi after acute myocardial infarction: a prospective randomized trial. *Am Heart J* 1987;113:688-93.
13. Johannessen KA, Nordrehaug JE, von der Lippe G, Vollset SE. Risk factors for embolisation in patients with left ventricular thrombi and acute myocardial infarction. *Br Heart J* 1988;60:104-10.
14. Turpie AG, Robinson JG, Doyle DJ, et al. Comparison of high-dose with low-dose subcutaneous heparin to prevent left ventricular mural thrombosis in patients with acute transmural anterior myocardial infarction. *N Engl J Med* 1989;320:352-7.
15. Nihoyannopoulos P, Smith GC, Maseri A, Foale RA. The natural history of left ventricular thrombus in myocardial infarction: a rationale in support of masterly inactivity. *J Am Coll Cardiol* 1989;14:903-11.
16. Keren A, Goldberg S, Gottlieb S, et al. Natural history of left ventricular thrombi: their appearance and resolution in the posthospitalization period of acute myocardial infarction. *J Am Coll Cardiol* 1990;15:790-800.
17. Vaitkus PT, Berlin JA, Schwartz JS, Barnathan ES. Stroke complicating acute myocardial infarction: a meta-analysis of risk modification by anticoagulation and thrombolytic therapy. *Arch Intern Med* 1992;152:2020-4.
18. Konrad MS, Coffey CE, Coffey KS, McKinnis R, Massey EW, Califf RM. Myocardial infarction and stroke. *Neurology* 1984;34:1403-9.
19. Ezekowitz MD, Azrin MA. Should patients with large anterior wall myocardial infarction have echocardiography to identify left ventricular thrombus and should they be anticoagulated? *Cardiovasc Clin* 1990;21:105-20.
20. Weintraub WS, Ba'Albaki HA. Decision analysis concerning the application of echocardiography to the diagnosis and treatment of mural thrombi after anterior myocardial infarction. *Am J Cardiol* 1989;64:708-16.
21. Robins J, Greenland S, Breslow NE. A general estimator for the variance of the Mantel-Haenszel odds ratio. *Am J Epidemiol* 1986;124:719-23.
22. DerSimonian R, Laird N. Meta-analysis in clinical trials. *Controlled Clin Trials* 1986;7:177-88.
23. Weinreich DJ, Burke JF, Pualetto FJ. Left ventricular mural thrombi complicating acute myocardial infarction. *Ann Intern Med* 1984;100:789-94.
24. Jugdutt BI, Sivaram CA, with the technical assistance of Wortman C, Trudell C, Penner P. Prospective two-dimensional echocardiographic evaluation of left ventricular thrombus and embolism after acute myocardial infarction. *J Am Coll Cardiol* 1989;13:554-64.
25. Kouvaras G, Chronopoulos G, Soufras G, et al. The effects of long-term antithrombotic treatment on left ventricular thrombi in patients after an acute myocardial infarction. *Am Heart J* 1990;119:73-8.
26. Nordrehaug JE, Johannessen K-A, von der Lippe G. Usefulness of high-dose anticoagulants in preventing left ventricular thrombus in acute myocardial infarction. *Am J Cardiol* 1985;55:1491-3.
27. Eigler N, Maurer G, Shah PK. Effect of early systemic thrombolytic therapy on left ventricular mural thrombus formation in acute anterior myocardial infarction. *Am J Cardiol* 1984;54:261-3.
28. Held AC, Gore JM, Paraskos J, et al. Impact of thrombolytic therapy on left ventricular mural thrombi in acute myocardial infarction. *Am J Cardiol* 1988;62:310-1.
29. Natarajan D, Hotchandani RK, Nigam PD. Reduced incidence of left ventricular thrombi with intravenous streptokinase in acute anterior myocardial infarction: prospective evaluation by cross-sectional echocardiography. *Int J Cardiol* 1988;20:201-7.
30. Lupi G, Domenicucci S, Chiarella F, Bellotti P, Vecchio C. Influence of thrombolytic treatment followed by full dose anticoagulation on the frequency of left ventricular thrombi in acute myocardial infarction. *Am J Cardiol* 1989;64:588-90.
31. Bhatnagar SK, Al-Yusuf AR. Effects of intravenous recombinant tissue-type plasminogen activator therapy on the incidence and associations of left ventricular thrombus in patients with a first acute Q wave anterior myocardial infarction. *Am Heart J* 1991;122:1251-6.
32. Funke Kupper AJ, Verheugt FW, Peels CH, Galema TW, den Hollander W, Roos JP. Effect of low dose acetylsalicylic acid on the frequency and hematologic activity of left ventricular thrombus in anterior wall acute myocardial infarction. *Am J Cardiol* 1989;63:917-20.
33. Johannessen KA, Stratton JR, Taulow E, Osterud B, von der Lippe G. Usefulness of aspirin plus dipyridamole in reducing left ventricular thrombus formation in anterior wall acute myocardial infarction. *Am J Cardiol* 1989;63:101-2.
34. Vaitkus PT. Usefulness of echocardiography in managing left ventricular thrombi after acute myocardial infarction. *Am J Cardiol* 1990;66:387.
35. Delemarre BJ, Visser CA, Bot H, Dunning AJ, with the technical assistance of de Koning H. Prediction of apical thrombus formation in acute myocardial infarction based on left ventricular spatial flow pattern. *J Am Coll Cardiol* 1990;15:355-60.
36. Haugland JM, Asinger RW, Mikell FL, Elsperger J, Hodges M. Embolic potential of left ventricular thrombi detected by two-dimensional echocardiography. *Circulation* 1984;70:588-98.
37. Lloret RL, Cortada X, Bradford J, Metz MN, Kinney EL. Classification of left ventricular thrombi by their history of systemic embolization using pattern recognition of two-dimensional echocardiograms. *Am Heart J* 1985;110:761-5.
38. Stratton JR, Resnick AD. Increased embolic risk in patients with left ventricular thrombi. *Circulation* 1987;75:1004-11.
39. Visser CA, Kan G, Meltzer RS, et al. Embolic potential of left ventricular thrombus after myocardial infarction: a two-dimensional echocardiographic study of 119 patients. *J Am Coll Cardiol* 1985;5:1276-80.
40. Kander NH, Holland KJ, Pitt B, Topol EJ. A randomized pilot trial of brief versus prolonged heparin after successful reperfusion in acute myocardial infarction. *Am J Cardiol* 1990;65:139-42.
41. Thompson PL, Aylward PE, Federman J, et al. A randomized comparison of intravenous heparin with oral aspirin and dipyridamole 24 hours after recombinant tissue-type plasminogen activator for acute myocardial infarction. *Circulation* 1991;83:534-42.
42. L'Abbe KA, Detsky AS, O'Rourke K. Meta-analysis in clinical research. *Ann Intern Med* 1987;107:224-33.
43. Kirkwood TB. Calibration of reference thromboplastins and standardization of the prothrombin time ratio. *Thromb Haemost* 1983;49:238-44.
44. Hirsh J. Oral anticoagulant therapy: urgent need for standardization. *Circulation* 1992;86:1332-5.
45. Vecchio C, Chiarella F, Lupi G, Bellotti P, Domenicucci S. Left ventricular thrombus in anterior acute myocardial infarction after thrombolysis: a GISSI-2 connected study. *Circulation* 1991;84:512-9.