

Immunization With Homologous Oxidized Low Density Lipoprotein Reduces Neointimal Formation After Balloon Injury in Hypercholesterolemic Rabbits

JAN NILSSON, MD, PhD, FEDERICO CALARA, MA, JAN REGNSTROM, MD, PhD,
ANNA HULTGARDH-NILSSON, PhD,* SEAN AMELI, MD,† BOJAN CERCEK, MD, PhD, FACC,†
PREDIMAN K. SHAH, MD, FACC†

Stockholm, Sweden and Los Angeles, California

Objectives. In this study we tested the hypothesis that immunization with homologous oxidized low density lipoprotein (oxLDL) would inhibit the neointimal response to balloon injury in hypercholesterolemic rabbits.

Background. Immunization with homologous oxLDL has been shown to markedly reduce aortic atherosclerosis in LDL receptor-deficient as well as cholesterol-fed rabbits; however, the effect of this strategy on the balloon injury-induced neointimal lesion is unknown.

Methods. New Zealand White rabbits were immunized with 280 μ g of homologous native LDL (n = 5), copper-oxidized LDL (n = 5) or phosphate buffer as control (n = 5) and fed a 1% cholesterol diet. Rabbits were reimmunized after 3 weeks, and balloon injury of the right ileofemoral artery was performed 1 week later. Four weeks after balloon injury, rabbits were killed, and the neointimal lesion area was measured by computerized morphometry after perfusion fixation of the arteries. Circulating antibodies against oxLDL were measured by enzyme-linked immunosorbent assay.

Results. In comparison with the control animals, those immunized with oxLDL had a 58% reduction in the neointimal area (0.53 ± 0.13 vs. 1.27 ± 0.26 mm²; p = 0.01). The group immunized with native LDL had a 19% reduction in the neointimal area compared with the control group (p = NS). Circulating cholesterol levels and antibody titers against oxLDL were comparable in the three groups. There was a trend toward reduced immunoreactivity for T cells and oxLDL in the neointima of oxLDL-immunized animals.

Conclusions. Hypercholesterolemic rabbits immunized with homologous oxLDL have a markedly reduced neointimal area after balloon injury despite severe hypercholesterolemia. Together with previous work, these data suggest that an immunization strategy (vaccination) against atherosclerosis and restenosis warrants further investigation.

(J Am Coll Cardiol 1997;30:1886-91)

©1997 by the American College of Cardiology

The presence of activated T cells and human leukocyte antigen, DR type-expressing macrophages, smooth muscle cells (SMC) and endothelial cells in atherosclerotic plaques have suggested the involvement of the immune system in atherosclerosis (1-3). An enhanced plaque formation has generally been observed in animals immunized with foreign antigen (4) and after allograft transplantation (5), suggesting that activa-

tion of the immune system promotes intimal inflammation and fibrosis, which characterize the development of atherosclerosis. However, this concept has recently been challenged by studies showing that suppression of T cell function by cyclosporin A enhances the development of atherosclerosis in hypercholesterolemic mice (6) and rabbits (7) and that class I-deficient mice have an increased susceptibility to atherosclerosis (8). The vascular wall response to mechanical injury may also be modulated by the immune system. Thus, T cell-deficient rats develop larger neointimal lesions in response to balloon catheter injury than do rats with normal T cell function (9). Similar observations have also been made in rabbits after T cell suppression by cyclosporin A (10), adding further support to the notion that cell-mediated immune reactions may modulate arterial response to injury.

Several lines of evidence implicate low density lipoprotein

From the King Gustaf V Research Institute, Department of Medicine, Karolinska Hospital and *Department of Cell and Molecular Biology, Karolinska Institutet, Stockholm, Sweden; and †Atherosclerosis Research Center, Division of Cardiology; and Burns and Allen Research Institute, Cedars-Sinai Medical Center; and University of California Los Angeles School of Medicine, Los Angeles, California. This study was supported by grants from the American Heart Association, Dallas, Texas; the Swedish Medical Research Council (8311), the Swedish Heart and Lung Foundation, the Tore Nilssons Fund, the Swedish Society of Medicine and King Gustaf V's 80th Birthday Fund, Stockholm, and the Grand Foundation of Los Angeles and the United Hostesses of Los Angeles.

Manuscript received April 3, 1997; revised manuscript received August 7, 1997, accepted August 21, 1997.

Address for correspondence: Dr. Prediman K. Shah, Cedars-Sinai Medical Center, Room 5347, 8700 Beverly Boulevard, Los Angeles, California 90048. E-mail: shahp@csmc.edu.

To discuss this article on-line, visit the ACC Home Page at www.acc.org/members and click on the JACC Forum

Abbreviations and Acronyms

BHT	=	butylated hydroxytoluene
BSA	=	bovine serum albumin
ELISA	=	enzyme-linked immunosorbent assay
IgG	=	immunoglobulin G
LDL	=	low density lipoprotein
oxLDL	=	oxidized low density lipoprotein
PBS	=	phosphate-buffered saline
SMC	=	smooth muscle cells

(LDL) oxidation in atherogenesis in experimental animals and in humans (11,12). Oxidized LDL (oxLDL) modulates activation of plaque T cells (13) through a macrophage-dependent process (13,14). Oxidized LDL has been proposed as one possible target for the immune response in atherosclerosis. Antibodies against epitopes of oxLDL are present both in the circulation and in atherosclerotic plaques (12,15,16). However, until recently, the role of the immune response against oxLDL in the pathophysiology of atherosclerosis has remained obscure. Recently, the role of the immune response to oxLDL in the formation of early atherosclerotic lesions in the aortas of rabbits has been evaluated. Reduced plaque formation after immunization with homologous oxLDL was observed both in genetically hypercholesterolemic rabbits (17) and in rabbits with diet-induced hypercholesterolemia (18). However, the effect of the immune response to oxLDL on neointimal lesion formation after balloon injury has not been previously studied. Therefore, the goal of this study was to test the hypothesis that immunization with oxLDL would reduce neointimal formation after balloon injury in the hypercholesterolemic rabbit.

Methods

Preparation of native and oxLDL. New Zealand White rabbits with diet-induced hypercholesterolemia (total serum cholesterol levels of 800 to 1,200 mg/dl) were killed by an intravenous overdose of fluanizone and penthanyl. Blood was drawn into precooled vacutainer tubes containing Na₂EDTA (1.4 mg/ml) from a catheter placed in the carotid artery. Plasma was then recovered by centrifugation at 1400 × *g* for 20 min at 1°C. The isolated plasma was adjusted to a density of 1.10 kg/liter by addition of NaCl. A density gradient consisting of 3 ml of 1.065-, 1.020- and 1,006-kg/liter NaCl solutions, respectively, was then formed in cellulose nitrate tubes (Ultra-clear tubes, Beckman) and centrifuged (Beckman L8-55 Ultracentrifuge, 40,000 rpm) in a Beckman SW 40 swinging bucket rotor at 20°C overnight (19). The very low density lipoprotein fraction was aspirated from the top 3 ml and intermediate density lipoprotein and LDL were harvested from the next 3 ml of the tube. The EDTA was subsequently removed by dialysis against EDTA-free phosphate-buffered saline (PBS). The protein content of the LDL preparation was determined by the method described by Lowry et al. (20). The LDL was oxidized by incubation in 5.0 μmol/liter CuSO₄/PBS for 18 h at 37°C,

and the oxidative modification was determined by agarose gel electrophoresis.

Animals and immunizations. Young male New Zealand White rabbits with an average weight of 3.5 kg were housed individually under conditions of 12-h light/dark periods. The animals were fed standard rabbit pellets supplemented with 1% cholesterol and 3% peanut oil for the entire duration of the study. On the first day of initiation of a high cholesterol diet, rabbits were immunized with native LDL (n = 5), oxLDL (n = 5) or PBS as control (n = 5). Each animal was given 280 μg of respective lipoprotein emulsified in 700 μg of AdjuPrime (Pierce) or AdjuPrime/PBS alone by subcutaneous injections at multiple sites. Reimmunization using an identical protocol was performed 3 weeks later. The decision to use AdjuPrime rather than Freund's complete adjuvans was based on earlier reports that the immune reaction against heat shock protein present in Freund's complete adjuvans produces severe atherosclerosis in hypercholesterolemic rabbits (21).

One week after the second immunization all animals were subjected to balloon injury of the right femoral artery. The animals were anesthetized using ketamine (35 mg/kg body weight) and xylazine (5 mg/kg). Using standard sterile technique, a right carotid artery cutdown was performed and a 2.5-mm angioplasty catheter was introduced with a guide wire (high torque-floppy 0.014). Under fluoroscopic guidance, the catheter was advanced through the aorta to the right femoral artery. The balloon was then inflated to a constant pressure of 8 atm for 1 min. This step was repeated with a 1-min interval, at the end of which the inflated balloon was retracted to the bifurcation of the common iliac arteries and deflated. The catheter and wire were removed, the right carotid artery ligated and the overlying skin sutured. All animals were returned to their housing fully awake, and routine postoperative care and follow-up were instituted. Four weeks after the injury, the animals were anesthetized, as described, and exsanguinated while being perfused with 0.9% normal saline followed by 4% paraformaldehyde in 0.1 mol/liter PBS (pH 7.2) under constant pressure of 100 ml of water for 20 min. The ileofemoral arteries were removed and placed in 4% formaldehyde with 0.2 mmol/liter EDTA and 20 μmol/liter butylated hydroxytoluene (BHT) for 3 h and then transferred to a solution containing 15% sucrose with 0.2 mmol/liter EDTA and 20 μM BHT and kept overnight at 4°C. The protocol for animal use was approved by Cedars-Sinai Institutional Animal Care and Use Committee.

Serum cholesterol levels were determined by enzymatic technique (Sigma) at the start of the study, at the time of injury and at the time of death.

ELISA for antibodies against oxLDL. Ninety-six-well ELISA microtiter plates (Costar) were coated with buffer (0.2 mol/liter sodium bicarbonate buffer, pH 9.4) containing 10 μg/ml of native or oxidized human LDL for 2 h at 20°C. Human LDL was isolated from healthy control subjects by the same technique as described earlier for isolation of rabbit LDL. The coated wells were rinsed in washing buffer (PBS/0.1% bovine serum albumin [BSA]/0.05% Tween 20) and

incubated with blocking buffer (PBS/1% BSA) for 1 h at 20°C. The test sera were serially diluted in blocking buffer and added to the wells for overnight incubation at 20°C. The wells were then washed extensively with washing buffer and incubated with peroxidase-labeled goat antihuman immunoglobulin G (IgG) antibodies (diluted 1/4,000 in blocking buffer) for 2 h at 20°C. After repeated rinsing in washing buffer, the plates were developed by incubation with 2,2'-azino-bis-(3-ethylbenzothiazoline sulfonate) (ABTS) for 30 min at 20°C and read in an ELISA reader at 405 nm. Oxidized LDL specific antibody titers were expressed as units (oxLDL absorbance \times 100).

Immunohistochemical and morphometric analysis. Three 1-mm long segments of arterial tissue were taken at 5-mm intervals starting 10 mm below the bifurcation. All tissue specimens were mounted in optimal cutting temperature medium for cryosectioning. Sections 10 μ m thick were mounted on polysialynated glass slides, rinsed in PBS and incubated with blocking serum for 1 h. They were then incubated with antibodies against rabbit macrophages (RAM 11, Dako), rabbit lymphocytes (L 11/129, courtesy of Prof. Goran Hansson, Stockholm, Sweden), oxLDL (courtesy of Prof. Joseph Witztum, San Diego, California), rabbit class II antigen (2C4) or SMC-specific alpha-actin (Dako) dissolved in PBS/0.1% Triton X-100 for 18 h in a humidifying chamber. Control specimens included an irrelevant antibody as well as omission of the primary antibody. The sections were subsequently rinsed in PBS, incubated with biotinylated antimouse IgG for 60 min, rinsed in PBS and incubated with alkaline phosphatase-labeled biotin streptavidin complexes for 2 h. The cells were finally incubated with alkaline phosphatase substrate solution for 30 min in darkness and counterstained with hematoxylin. Sections for morphometric analysis were stained with hematoxylin. Neointimal area was determined using the Optimas image analysis as described (22). The interobserver and intraobserver variabilities of the measurements were $<5\%$. A mean value of intimal lesion area was calculated based on measurements of three sections taken at 5-mm intervals starting 10 mm below the bifurcation. Semiquantitative analysis of the immunohistochemistry staining was performed using a modified version of the technique described by Galis et al. (23). Consistent positive staining covering $>50\%$ of the intima was recorded as 3; consistent positive staining covering $<50\%$ of the intima as 2; variable or weak staining as 1; and no staining as 0. Results are presented as the average score.

Statistical analysis. Results are presented as mean value \pm SD if not otherwise indicated. The nonparametric Wilcoxon signed-rank test was used for intergroup analysis. A p value <0.05 was considered significant.

Results

The mean serum cholesterol level before dieting was ≤ 40 mg/dl. After 4 weeks of a high cholesterol diet, cholesterol levels had increased to ~ 600 to 700 mg/dl. At the time of death, cholesterol levels were $>1,000$ mg/dl. There were no

Table 1. Total Serum Cholesterol Levels (mg/dl)

	Adjuvant Group (n = 5)	LDL Group (n = 5)	oxLDL Group (n = 5)
Pretreatment	28 \pm 8	30 \pm 10	37 \pm 15
4 weeks	659 \pm 423	727 \pm 301	591 \pm 324
8 weeks	1,181 \pm 322	1,321 \pm 159	1,022 \pm 481

Data presented are mean value \pm SD. LDL = low density lipoprotein; oxLDL = oxidized low density lipoprotein.

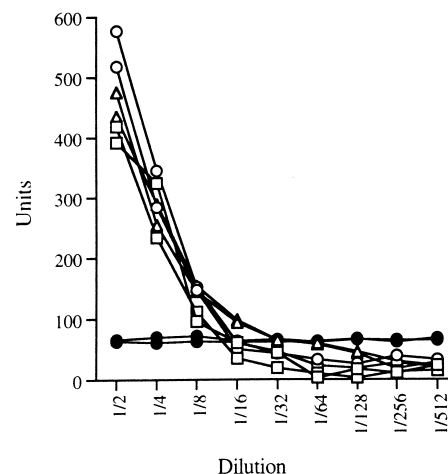
significant differences in serum cholesterol levels between the three treatment groups (Table 1). No antibodies against oxLDL were detected in sera taken before immunization and initiation of the cholesterol-rich diet. At the time of death, antibodies against oxLDL were present in the sera of all three groups of animals (Fig. 1).

Neointimal lesion formation in response to balloon injury.

All animals developed concentric intimal lesions in response to the injury. The mean neointimal area of animals immunized with adjuvant/PBS alone was 1.27 ± 0.26 mm². Immunization with oxLDL reduced the intimal lesion area by 58.2% (p = 0.01), as compared with adjuvant alone, whereas immunization with LDL reduced the intimal lesion area by 19% (p = NS) (Fig. 2).

Immunohistochemical analysis. Immunohistochemical analysis demonstrated abundant SMC immunoreactivity in all neointimal lesions, as well as in the underlying media. Macrophage immunostaining was also seen in the entire neointima but was particularly prominent in the deeper regions close to the internal elastic lamina (Fig. 3, A and D). Areas with visible lipid accumulation and necrosis were always associated with intense macrophage staining. The immunohistochemical analysis also revealed abundant T cell infiltration in the deeper regions of the lesions, whereas few T cells appeared to be

Figure 1. Antibodies to oxLDL. These antibodies were determined by ELISA before immunization (solid circles) and at the end of the study in animals immunized with native (open squares) or oxidized (open circles) LDL and in control rabbits (open triangles). Antibody titers were analyzed in two animals from each group.



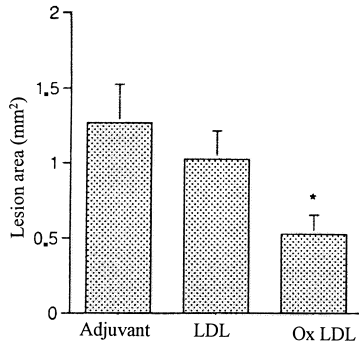


Figure 2. Effect of immunization on neointimal development after balloon injury. Balloon injury to the right iliofemoral artery was performed 1 week after the reimmunization, and the animals were killed 4 weeks later. The mean neointimal lesion area for each animal was determined by image analysis of three sections taken at 5-mm intervals starting 10 mm below the bifurcation. Data are presented as mean value \pm SD for each group. * $p = 0.01$ versus the PBS control group.

present in the superficial region (Fig. 3, B and E). Epitopes specific for oxLDL were also primarily present in the deeper regions of the lesions (Fig. 3, C and F). Most of the oxLDL immunoreactivity was associated with foam cells. Accumulation of lipids, necrosis and oxLDL, T cell and macrophage immunoreactivity were also seen in some parts of the media. Generally, larger lesions had more lipid accumulation, necrosis and inflammatory cell infiltrates.

To compare the immunohistochemical staining between the three different treatment groups, we performed a semiquantitative analysis of staining intensity. The overall intensity of the macrophage stain appeared to be weaker in animals immunized with oxLDL, but there was no difference in the area stained. There were fewer T cells in lesions from animals immunized with LDL and to a lesser extent in animals immunized with oxLDL (Table 2).

Table 2. Semiquantitative Analysis of Immunohistochemical Staining

	Adjuvant Group (n = 5)	LDL Group (n = 5)	oxLDL Group (n = 5)
SMC (HHF35)	3.0 \pm 0.0	3.0 \pm 0.0	3.0 \pm 0.0
Macrophage (RAM-11)	3.0 \pm 0.0	3.0 \pm 0.0	3.0 \pm 0.0
T cells (L11/135)	2.4 \pm 0.5	1.4 \pm 0.5*	1.8 \pm 0.5
Class II antigen (2C4)	1.5 \pm 0.6	1.4 \pm 0.5	1.0 \pm 1.4
oxLDL (NA 59)	2.8 \pm 0.5	3.0 \pm 0.0	1.8 \pm 1.5

* $p < 0.05$ compared with the adjuvant group. Results are presented as mean value \pm SD of the average score. Consistent positive staining covering $>50\%$ of the intima was scored as 3; covering $<50\%$ of the intima as 2; variable or weak staining as 1; and no staining as 0. SMC = smooth muscle cells; other abbreviations as in Table 1.

Discussion

This study demonstrates, for the first time, that immunization of cholesterol-fed rabbits with homologous oxLDL markedly reduces neointimal formation in the balloon-injured iliac artery despite persistent severe hypercholesterolemia. Furthermore, these favorable effects were observed without any difference in the magnitude of humoral immune response, as measured by circulating antibodies against oxLDL, between control animals and immunized animals, suggesting that cell-

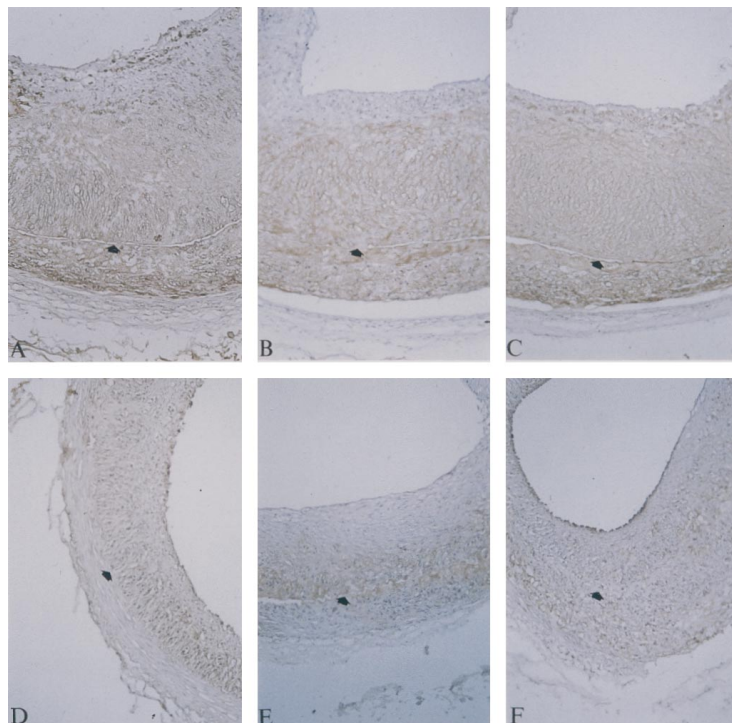


Figure 3. Immunohistochemical analysis of neointimal lesions. RAM-11 macrophage staining in (A) a femoral artery from a rabbit given adjuvant/PBS and (D) a rabbit immunized with oxLDL. L11/135 T lymphocyte staining in (B) a femoral artery from a rabbit given adjuvant/PBS and (E) an artery from a rabbit immunized with oxLDL. (C) Staining for oxLDL (NA 59) in an artery from a rabbit given adjuvant/PBS and (F) the same staining in an artery from a rabbit immunized with oxLDL. Arrows indicate the internal elastic lamina. $\times 100$, reduced by 30%.

mediated rather than humoral immunity may be involved. Taken together with previously reported results in hypercholesterolemic rabbits, these data further suggest a beneficial effect of immune response in atherosclerosis (17,18).

Arterial accumulation of LDL is a key factor in the development of atherosclerotic plaques (24). The LDL particles, trapped in the extracellular matrix of the vascular wall, are known to undergo substantial structural and chemical modifications in response to oxidative stress, enzymes and/or other unknown factors (25-27). These modifications include oxidation of fatty acids into lipid hydroperoxides, which are then decomposed into a variety of products including reactive aldehydes. Interactions between these aldehydes and lysine residues on apolipoprotein B 100 results in formation of epitopes that are recognized by the immune system (28,29). Atherosclerotic plaques contain both antibodies against oxLDL (16) and T cells that specifically recognize epitopes in oxLDL (13), suggesting involvement of humoral as well as cell-mediated immune responses. An immune response against autologous modified lipoproteins could represent an underlying mechanism for the chronic intimal inflammatory process seen in atherosclerosis. However, we and another group of investigators have recently demonstrated decreased formation of fatty streaks and early atherosclerotic lesions in hypercholesterolemic rabbits immunized with homologous oxLDL (17,18). The present observation that immunization with homologous oxLDL inhibits neointimal formation after balloon injury of the iliofemoral artery in hypercholesterolemic rabbits adds further support to the notion that immune reactions against oxLDL serves to limit the atherosclerotic process.

Possible mechanisms involved in antiatherogenic effect of immune reactions against oxLDL. The mechanisms responsible for the protective effect of immunization against homologous oxLDL remain to be clarified. Although the level of antibodies against oxLDL increased significantly in animals immunized with oxLDL, a similar increase in antibodies was observed in response to diet-induced hypercholesterolemia alone, demonstrating that mechanisms other than humoral immunity may be involved. Similarly, it has been shown that diet-induced hypercholesterolemia in LDL-deficient mice results in induction of a humoral immune response against oxLDL (30). Thus, it appears that hypercholesterolemia, in itself, is associated with the formation of oxidized epitopes on LDL and activation of a humoral immune response toward these epitopes. Previous immunization with oxLDL may have stimulated the onset of this response, but did not appear to influence its final magnitude. However, we cannot definitively rule out the role of humoral immunity, because epitopes other than the ones identified in this study could be involved. Nevertheless, these findings are in keeping with the observations of Roselaar et al. (7), who found that suppression of T cell function by cyclosporin A in rabbits with diet-induced hypercholesterolemia resulted in enhanced development of atherosclerosis without affecting serum levels of antibodies against malondialdehyde-modified LDL. Of note is the finding in this study that there was neither decreased T cell infiltration

nor any detectable change in T lymphocyte subtype expression in the lesion of the treated animals. Further evidence for a role of cell-mediated immunity in atherosclerosis has come from studies on class I major histocompatibility complex-deficient C57BL/6 mice (8). These animals lack cytolytic T cells, have an impaired natural killer cell activity and have an increased tendency to develop aortic lesions in response to a high cholesterol diet. Semiquantitative analysis of neointimal lesions in animals immunized with oxLDL showed a trend toward reduced immunoreactivity for T cells (Table 2). This is unlikely to explain the difference in neointimal area, because T cell immunoreactivity was also reduced in animals immunized with native LDL who only had a 19% reduction in neointimal area compared with a 58% reduction observed with immunization with oxLDL. Although in this study we did not evaluate T cell function, other studies suggest altered T cell function could be involved in modulating the severity of diet-induced atherosclerosis (10). Activation of a cell-mediated immune response against oxLDL may facilitate the removal of oxLDL from the intima, thereby limiting the inflammatory reaction. The trend toward a reduced immunoreactivity for oxLDL in the neointima of animals immunized with oxLDL (Table 2) is consistent with this hypothesis.

Immune reactions may lead to a more efficient removal of proinflammatory and mitogenic lipid oxidation products. Another possibility is that an enhanced clearance of oxLDL results in a decreased proliferation of SMC. Oxidized LDL has been shown to activate the monocyte release of tumor necrosis factor- α , a potent growth factor for SMC (31). Lysophosphatidylcholine, which is formed in large quantities during oxidative modification of LDL, also has a direct stimulatory effect on the rate of SMC DNA synthesis (32). Several studies demonstrating that antioxidants inhibit neointimal formation after arterial balloon injury in hypercholesterolemic animals (33,34) have supported the idea that oxidation products enhance the proliferative response after mechanical injury. The proliferative response may also be modulated by factors released by activated T cells. Inhibition of T cell function by treatment with cyclosporin A results in increased neointimal formation in response to mechanical injury in normocholesterolemic rabbits (10). Moreover, removal of T cells with monoclonal antibodies has been shown to enhance neointimal formation after balloon injury of rat aortas (9). A similar effect was also obtained by treatment with interferon- γ (35), which in cell culture has been identified as a potent inhibitor of SMC proliferation (36). Stimulation of interferon- γ release by T cells may thus be another possible explanation for the decreased neointimal formation observed in animals immunized with oxLDL. Although one may speculate that activation of a cell-mediated immune reaction against oxLDL, leading to enhanced clearance of proinflammatory and mitogenic lipid oxidation products, are responsible for the effects observed in the present study, further studies are clearly needed to identify the precise mechanism(s) involved.

Conclusions. The present findings add further support to the hypothesis that immune reactions against modified li-

poproteins inhibit the formation of intimal plaques. Whether this mechanism has implications for the development of atherosclerosis and restenosis after balloon angioplasty in humans remains to be determined. Nonetheless, this and previously reported beneficial effects of immunization with homologous oxLDL suggest that further investigation into the development and validation of an immunization-based strategy (vaccination) against atherosclerosis is warranted.

Study limitations. The major limitation of this study is the fact that it does not provide a mechanistic insight into how immunization with oxLDL reduces neointimal thickening after balloon injury. Our laboratory is currently engaged in studies designed to answer this important question.

We thank Professor Goran Hansson from the Karolinska Institutet for helpful discussions related to this study.

References

1. Jonasson L, Holm J, Skalli O, Gabbiani G, Hansson GK. Expression of class II transplantation antigen on vascular smooth muscle cells in human atherosclerosis. *J Clin Invest* 1985;76:125-31.
2. Jonasson L, Holm J, Skalli O, Bondjers G, Hansson GK. Regional accumulations of T cells, macrophages, and smooth muscle cells in the human atherosclerotic plaque. *Arteriosclerosis* 1986;6:131-8.
3. Libby P, Hansson GK. Involvement of the immune system in human atherogenesis: current knowledge and unanswered questions. *Lab Invest* 1991;64:5-15.
4. Minick CR, Murphy GE. Experimental induction of atheroarteriosclerosis by the synergy of allergic injury to arteries and lipid-rich diet: II. Effect of repeatedly injected foreign protein in rabbits fed a lipid-rich, cholesterol-poor diet. *Am J Pathol* 1973;73:265-92.
5. Tanaka H, Sukhova GK, Libby P. Interaction of the allogenic state and hypercholesterolemia in arterial lesion formation in experimental cardiac allografts. *Arterioscler Thromb Vasc Biol* 1994;14:734-45.
6. Emson EE, Shen M-L. Accelerated atherosclerosis in hyperlipidemic C57BL/6 mice-treated with cyclosporin A. *Am J Pathol* 1993;142:1906-15.
7. Roselaar SE, Schonfeld G, Daugherty A. Enhanced development of atherosclerosis in cholesterol-fed rabbits by suppression of cell-mediated immunity. *J Clin Invest* 1995;96:1389-94.
8. Fyfe AI, Qiao JH, Lusic AJ. Immune-deficient mice develop typical atherosclerotic fatty streaks when fed an atherogenic diet. *J Clin Invest* 1994;94:2516-20.
9. Hansson G, Holm J, Holm S, Fotev Z, Hedric JH, Fingerle J. T lymphocytes inhibit the vascular response to injury. *Proc Natl Acad Sci USA* 1991;88:10530-4.
10. Ferns G, Reidy M, Ross R. Vascular effects of cyclosporin A in vivo and in vitro. *Am J Pathol* 1990;137:403-13.
11. Witztum JL, Steinberg D. Role of oxidized low density lipoprotein in atherogenesis. *J Clin Invest* 1991;88:1785-92.
12. Palinski W, Rosenfeld ME, Yla-Herttuala, et al. Low density lipoprotein undergoes modification in vivo. *Proc Natl Acad Sci USA* 1989;86:1372-6.
13. Stemme S, Faber B, Holm J, Wiklund O, Witztum J, Hansson GK. T lymphocytes from human atherosclerotic plaques recognize oxidized low density lipoprotein. *Proc Natl Acad Sci USA* 1995;92:3893-7.
14. Frostegard J, Wu R, Giscombe R, Holm G, Lefvert AK, Nilsson J. Induction of T cell activation by oxidized low density lipoprotein. *Arterioscler Thromb Vasc Biol* 1992;12:461-7.
15. Salonen JT, Yla-Herttuala S, Yamamoto R, et al. Autoantibody against oxidized LDL and progression of carotid atherosclerosis. *Lancet* 1992;339:883-7.
16. Yla-Herttuala S, Palinsky W, Butler S, Picard S, Steinberg D, Witztum J. Rabbit and human atherosclerotic lesions contain IgG that recognizes epitopes of oxidized low density lipoprotein. *Arterioscler Thromb Vasc Biol* 1994;14:32-40.
17. Palinski W, Miller E, Witztum J. Immunization of low density lipoprotein (LDL) receptor deficient rabbits with homologous malondialdehyde-modified LDL reduces atherosclerosis. *Proc Natl Acad Sci USA* 1995;92:821-5.
18. Ameli S, Hultgardh-Nilsson A, Regnstrom J, et al. Effect of immunization with homologous LDL and oxidized LDL on early atherosclerosis in hypercholesterolemic rabbits. *Arterioscler Thromb Vasc Biol* 1996;16:1074-9.
19. Redgrave TG, Roberts DCK, West CE. Separation of plasma lipoproteins by density gradient ultracentrifugation. *Anal Biochem* 1975;65:42-9.
20. Lowry O, Rosenbrough N, Farr A, Randall R. Protein measurement with the Folin phenol reagent. *J Biol Chem* 1951;193:265-75.
21. Xu Q, Dietrich H, Steiner HJ, et al. Induction of arteriosclerosis in normocholesterolemic rabbits by immunization with heat shock protein 65. *Arterioscler Thromb Vasc Biol* 1992;12:789-99.
22. Ameli S, Hultgardh-Nilsson A, Cercek B, et al. Recombinant apolipoprotein A-I Milano reduces intimal thickening after balloon injury in hypercholesterolemic rabbits. *Circulation* 1994;90:1935-41.
23. Galis ZS, Sukhova GK, Lark MW, Libby P. Increased expression of matrix metalloproteinases and matrix degrading activity in vulnerable regions of human atherosclerotic plaques. *J Clin Invest* 1994;94:2493-503.
24. Steinberg D, Parthasarathy S, Carew TE, Khoo JC, Witztum JL. Beyond cholesterol: modifications of low-density lipoprotein that increase its atherogenicity. *N Engl J Med* 1989;320:915-25.
25. Esterbauer H, Striegl G, Puhl H, Rothender M. Continuous monitoring of in vitro oxidation of human low density lipoprotein. *Free Rad Res Commun* 1989;6:67-75.
26. Steinbrecher U, Zhang H, Loughheed M. Role of oxidatively modified LDL in atherosclerosis. *Free Rad Biol Med* 1990;9:155-68.
27. Steinberg D, Witztum JL. Role of oxidized low density lipoprotein in atherogenesis. *J Clin Invest* 1991;88:1785-92.
28. Gonen B, Fallon JJ, Baker SA. Immunogenicity of malonaldehyde-modified low density lipoprotein. *Atherosclerosis* 1987;65:265-72.
29. Haberland ME, Fong D, Cheng L. Malondialdehyde-altered protein occurs in atheroma of Watanabe heritable hyperlipidemic rabbits. *Science* 1988;241:215-8.
30. Palinski W, Tangirala RK, Miller E, Young SG, Witztum JL. Increased autoantibody titers against epitopes of oxidized LDL in LDL receptor-deficient mice with increased atherosclerosis. *Arterioscler Thromb Vasc Biol* 1995;15:1569-76.
31. Jovinge S, Ares M, Kallin B, Nilsson J. Human monocyte/macrophages release tumor necrosis factor alpha in response to oxidized low density lipoprotein. *Arterioscler Thromb Vasc Biol* 1996;16:1573-9.
32. Stiko A, Regnstrom J, Shah PK, Cercek B, Nilsson J. Active oxygen species and lysophosphatidylcholine are involved in oxidized low density lipoprotein activation of smooth muscle DNA synthesis. *Arterioscler Thromb Vasc Biol* 1996;16:194-200.
33. Ferns GAA, Forster L, Stewart-Lee A, Konneh M, Nourooz-Zadeh J, Angard E. Probucol inhibits neointimal thickening and macrophage accumulation after balloon injury in the cholesterol-fed rabbit. *Proc Natl Acad Sci USA* 1992;89:11312-6.
34. Freyschuss A, Stiko-Rahm A, Swedenborg J, et al. Antioxidant treatment inhibits the development of intimal thickening after balloon injury of the aorta in hypercholesterolemic rabbits. *J Clin Invest* 1993;91:1282-8.
35. Hansson GK, Holm J. Interferon gamma inhibits arterial stenosis after injury. *Circulation* 1991;84:1266-72.
36. Hansson GK, Hellstrand M, Rymo L, Rubbia L, Gabbiani G. Interferon gamma inhibits both proliferation and expression of alpha smooth muscle actin in arterial smooth muscle cells. *J Exp Med* 1989;170:1595-8.