

Contents lists available at [ScienceDirect](http://ScienceDirect)

## Respiratory Medicine Case Reports

journal homepage: [www.elsevier.com/locate/rmcr](http://www.elsevier.com/locate/rmcr)

## Case report

## Disseminated tuberculosis in a non immun compromised patient with a complicated diagnosis

Hatice Sahin <sup>a, \*</sup>, Hatice Isik <sup>b</sup>, Sevil Uygun Ilikhan <sup>a</sup>, Hakan Tanriverdi <sup>c</sup>, Muammer Bilici <sup>a</sup><sup>a</sup> Bülent Ecevit University School of Medicine, Department of Internal Medicine, Zonguldak, Turkey<sup>b</sup> Bülent Ecevit University School of Medicine, Department of Gynecology and Obstetrics, Zonguldak, Turkey<sup>c</sup> Bülent Ecevit University School of Medicine, Department of Chest Diseases, Zonguldak, Turkey

## A B S T R A C T

## Keywords:

Ascites

Tuberculosis

Diagnostic methods

Tuberculosis (TB) has become a global emergency worldwide. The long time period between the exposure to TB bacillus and the onset of symptoms cause a delay in diagnosis. Herein, we report a case of 64-year-old female patient suffering from dyspepsia, anorexia, weight loss and abdominal pain for the last 8 months. Physical examination, ascites fluid evaluation, chest radiography, ultrasonographic and tomographic scans, histopathological analysis of the lymphadenopathy (LAP) and endometrial tissue revealed TB. A fourfold antituberculous treatment with isoniazid, pyrazinamide, rifampicin and ethambutol was prescribed for two months and for four months maintenance therapy with isoniazid and rifampicin was given. On the fourth month of the medical treatment the patient clinically recovered. Since the diagnosis of TB is difficult, high grade suspicion, combination of the radiologic, microbiologic and histopathological examinations are needed to achieve a diagnosis.

© 2014 The Authors. Published by Elsevier Ltd. This is an open access article under the CC BY-NC-ND license (<http://creativecommons.org/licenses/by-nc-nd/3.0/>).

## Introduction

Tuberculosis (TB) is caused by *Mycobacterium tuberculosis* (MTB) or other *Mycobacterium* species. TB is a major contagious disease worldwide causing approximately 1.4 million deaths per year [1,2]. Pulmonary TB is the initial site of the infection, but the infection can spread to the kidneys, spine, genital organs, and rarely to the peritoneum [1]. Usually TB peritonitis patients have symptoms including abdominal pain, fever, weight loss, anorexia and malaise, rarely with diarrhea and constipation [3]. Ascites often accompanies TB peritonitis as well [4]. Female genital tuberculosis (FGTB) due to sexual transmission has been reported, but the direct spread from other intraperitoneal foci does not often occur [5]. The main histopathological finding of TB is epithelioid granulomas with typical Langhans cells including areas of caseous necrosis. In this case study, we present a case of a patient having both peritoneal and endometrial TB as well as pulmonary TB.

## Case report

A sixty-four year old multipar female was admitted to our outpatient clinic with fatigue, abdominal distension, anorexia, hot

flushes, and weight loss of 8 kg within eight months. She was hypertensive for a decade but did not report any important disease in her family history. She had no known exposure to TB, never smoked, and never used alcohol. During her physical examination the patient was conscious, cooperative, and showed normal vital signs. The conjunctiva was pale. The examination of the systems was normal except ascites and lymphadenopathies (LAPs). No stigmata of chronic liver disease were found. Multiple painless, mobile, and solid LAPs were found, the biggest being 2 cm in the left cervical and supraclavicular and 3 cm in the bilateral axillary and inguinal regions. The laboratory findings of the patient are summarized in Table 1. Evaluation of the initial laboratory parameters showed mild anemia and leukopenia, a high erythrocyte sedimentation rate (ESR), a high C-reactive protein (CRP) level, increased lactate dehydrogenase (LDH), a albumin globulin rate less than 1, a high CA-125 level, and low vitamin B12. The erythrocytes were normochromic normocytic; mild monocytosis (16%) but no atypical cells were seen in the peripheral blood smear. In the analysis of the ascites fluid, the serum ascitic albumin gradient (SAAG) was <1.1 g/dl, the cell count was 1600 leukocytes/mm<sup>3</sup> (70–80% mononuclear), the value of adenosine deaminase (ADA) was 60.4 U/l, and the LDH was high (281 U/L). No malignancy finding was found during the cytological evaluation of the ascites fluid. No bacteriological growth in the ascites fluid culture was observed. She was euthyroid and HIV seronegative. Her hepatitis B and C tests were negative and her coagulation tests were normal.

\* Corresponding author. Department of Internal Medicine, Bülent Ecevit University School of Medicine, Kozlu, Zonguldak 67600, Turkey. Tel.: +90 3722612644.  
E-mail address: [haticeharmansa@hotmail.com](mailto:haticeharmansa@hotmail.com) (H. Sahin).

**Table 1**  
Laboratory findings on admission.

Peripheral blood		Blood chemistry		Serological study	
WBC	3900/ $\mu$ L	TP	8.6 g/dL	CRP	26.6 mg/dL
Neutro	66.4%	Alb	3.7 g/dL		
Lymph	17.8%	BUN	13 mg/dL		
Mono	14.4%	Cr	0.95 mg/dL		
Eosino	1.1%	Ca	8.7 mg/dL	Microbiological	
Baso	0%	LDH	579 U/L	ESR	68 mm/h
Hb	11.7 g/dL	ALT	12 IU/L		
Hct	35.1%	AST	41 IU/L		
MCV	85.6	ALP	48 IU/L		
RDW	13.1%	GGT	18 IU/L		
Plt	$16.3 \times 10^4$ / $\mu$ L	D bil	0.3 mg/dL		
		Total bil	0.8 mg/dL		
		CA-125	901.1 U/ml		
		vitamin B12	79 pg/mL		
		Iron	24 $\mu$ g/dL		
		Iron binding capacity	238 $\mu$ g/dL		
		Ferritin	97.3 ng/mL		

Fecal occult blood revealed a negative result 3 times. No sign of heart failure was detected in both her echocardiography and her physical examination. Chest X-ray revealed bilateral reticulonodular infiltration (Fig. 1A).

On the abdominal USG, there was a LAP of 2 cm in the hepatic hilum and ascites, but no hepatosplenomegaly. The USG scans of the axillary, inguinal, and cervical regions also revealed hypochoic, lobulated, and heterogenous multiple LAPs. Ground-glass density areas in both lungs, especially in the left one, were seen on thoracic CT (Fig. 1B). On abdominal computed tomography (CT) multiple LAPs were observed in paraaortic region. Ascites, ventral abdominal mesenteric heterogeneity and thickness were seen on CT image as well (Fig. 2A). For the exclusion of an occult malignancy, an upper gastrointestinal system endoscopy was performed, and reflux esophagitis was seen. She was consulted to our Gynecology Department to rule out gynecologic malignancies since the serum level of CA-125 was high. A gynecologic examination revealed no pathological finding so a screening PAP smear test and an endometrial curettage were performed. No pathological finding was found in mammographic scan. A supraclavicular lymphadenectomy was performed for a diagnosis. The pathology of the lenfoid tissue and endometrial biopsy showed caseification necrosis in some granulomas. Her PAP smear showed a negative result for malignancy. The intradermally performed purified protein derivative (PPD) test was 15 mm. The direct microscopic examining of induced sputum acid-resistant bacilli (ARB) was negative and sputum cultures for MTB were performed. After all of the diagnostic tests,

genital TB became suspicious. A tetrad treatment with isoniazid 300 mg/day, rifampycin 600 mg/day, pyrazinamide 1500 mg/day, etambutol 1500 mg/day was started. Sputum culture before the treatment was positive for MTB. Four months after the initiation of the treatment, her hemoglobin and CA-125 levels turned to normal. The ascites had disappeared, the diameters of the LAPs had significantly decreased, and the symptoms of the patient had all regressed.

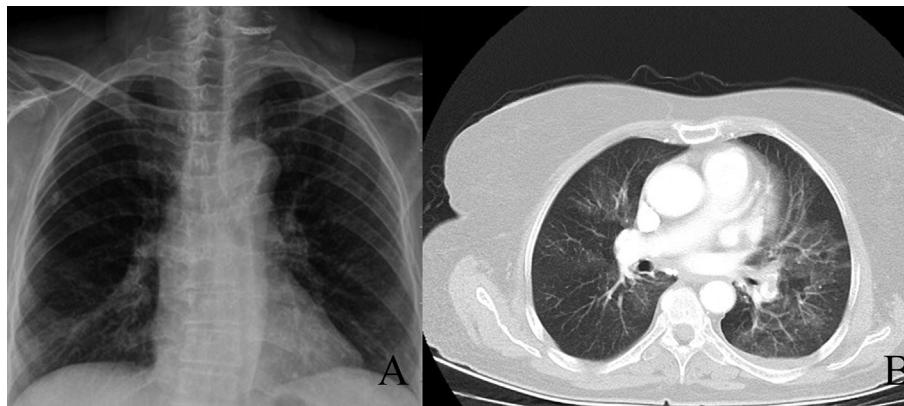
## Discussion

TB is an important health problem for developing countries. Since the symptoms, laboratory and physical findings are not specific, the diagnosis of extrapulmonary TB is difficult.

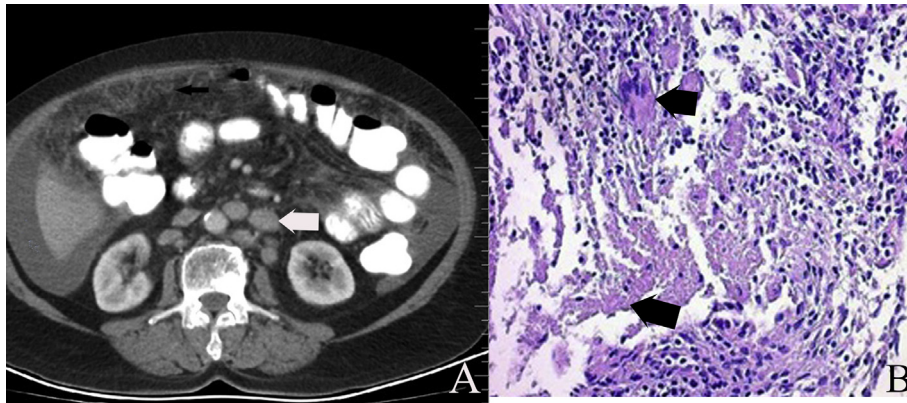
The most common symptoms in TB peritonitis are abdominal pain, fever, weight loss, and abdominal distention [6]. Ascites is usually seen in the physical examination of peritoneal TB [7,8]. Similarly, our patient had ascites, abdominal pain, and weight loss. TB peritonitis is usually associated with pulmonary TB [9]. TB peritonitis may present itself as disseminated TB. More than fifty percent of pulmonary TB has reported with TB peritonitis [10,11]. Yeh et al. reported that 77% of patients with TB peritonitis had abnormalities in chest radiographs [10]. Our patient's chest X-ray was abnormal but not specific for TB. In the literature, ascites, LAP, peritoneal, and mesenteric thickness are the most common findings in CT and USG scans of peritoneal TB, which has a low sensitivity and specificity [8,12]. The abdominal CT of our patient showed similar findings with that of the literature (Fig. 2A). CA-125 levels usually increase in tumors (epithelial over, endometrium, fallopian tubes, myometrium and non-gynecologic) and occasionally in TB peritonitis [13]. TB peritonitis rarely mimics tumors with high CA-125, so patients may undergo laparotomy [14]. Our patient had a high CA-125 level (901,1 U/ml) which became normal after the treatment stated in the literature [15].

FGTB can be seen with postmenopausal gynecological malignancies [16]. In postmenopausal women, genital TB is rare and endometrium is the most affected site (60–70%). FGTB is usually found in young patients diagnosed with infertility [17]. A microbiological culture of endometrial curettage for MTB and/or the histological appearance of granulomas, with or without caseation in curettage material, can verify the diagnosis [4]. Histopathological examination of our patient's endometrial curettage material revealed granulomas with caseation (Fig. 2B).

A high lymphocyte count, elevated LDH and total protein, decreased glucose level, ADA levels (>35 IU/L) in ascitic fluid, and a SAAG of less than 1.1 g/dl have been used as helpful diagnostic tests



**Fig. 1.** A: Chest X-ray revealed bilateral reticulonodular infiltration. B: Ground-glass density areas in both lungs especially in the left one are seen on thoracic CT.



**Fig. 2.** A: Multiple LAPs were observed in paraaortic region (white arrow). Also ascites (asterisk) and ventral abdominal mesenteric heterogeneity and thickness (black arrow) were seen on transverse abdominal CT image. B: Granulomas of epithelioid like histiocytes containing Langhans cells (blue arrow) and eosinophilic debris with caseification necrosis (white arrow) in endometrial stroma (H&E,  $\times 50$ ).

for TB peritonitis [10]. In our case, SAAG was  $<1.1$  g/dL, and ascitic fluid LDH, ADA were 281 U/L, 60.4 U/L, respectively. The Positive Mantoux test result was 80% specific and 55% sensitivity for the diagnosis of TB [18]. In our case PPD was also positive.

The distinctive feature in the case of our patient is that both pulmonary and genital TB were diagnosed at the same time. All the clinical, laboratory and radiological findings, histopathological analysis of granulomas with caseations in LAP, and endometrium biopsy supported the diagnosis of TB. The sputum culture verified our diagnosis. Since the growth of mycobacterium in culture takes a long time, we started the treatment before the culture results.

In conclusion, the patient primarily was considered to have a malignancy because of her older age, weight loss, and absence of TB exposure. Our diagnostic tests (radiological, laboratory, histopathological) contributed valuable information about TB to us. In endemic countries, such as Turkey, health providers must be aware of TB peritonitis in the differential diagnosis of patients with fever, weight loss, abdominal pain, ascites, and elevated serum CA-125 levels. Early diagnosis and treatment may improve prognosis.

### Acknowledgments

This paper was edited by the Proofreading Office at Bülent Ecevit University.

### References

- [1] Chou CH, Ho MW, Ho CM, Lin PC, Weng CY, Chen TC, et al. Abdominal tuberculosis in adult: 10-year experience in a teaching hospital in central Taiwan. *J Microbiol Immunol Infect* 2010 Oct;43(5):395–400.
- [2] World Health Organisation. Global tuberculosis report, WHO Library Cataloguing-in-Publication Data. Switzerland. 2012. p. 3 [chapter 1].
- [3] Sharma MP, Bhatia V. Abdominal tuberculosis. *Indian J Med Res* 2004;120:305–15.
- [4] Sanai FM, Bzeizi KI. Systematic review: tuberculous peritonitis – presenting features, diagnostic strategies and treatment. *Aliment Pharmacol Ther* 2005;22:685–700.
- [5] Mondal SK. Histopathologic analysis of female genital tuberculosis: a fifteen-year retrospective study of 110 cases in eastern India. *Turk Patoloji Derg* 2013;29(1):41–5.
- [6] Wittman DH. Intra-abdominal infections. Pathophysiology and treatment. classification systems for peritonitis. 1991. p. 43–4. New York: Madison.
- [7] Marshall JB. Tuberculosis of the gastrointestinal tract and peritoneum. *Am J Gastroenterol* 1993;88:989–99.
- [8] Dursun P, Ersoz S, Gultekin M, Aksan G, Yuce K, Ayhan A. Disseminated peritoneal tuberculosis mimicking advanced-stage endodermal sinus tumor: a case report. *Int J Gynecol Cancer* 2006;16(Suppl. 1):303–7.
- [9] Wang HK, Hsueh PR, Hung CC, Chang SC, Luh KT, Hsieh WC. Tuberculous peritonitis: analysis of 35 cases. *J Microbiol Immunol Infect* 1998 Jun;31(2):113–8.
- [10] Yeh HF, Chiu TF, Chen JC, Ng CJ. Tuberculous peritonitis: analysis of 211 cases in Taiwan. *Dig Liver Dis* 2012;44:111–7.
- [11] Hu ML, Lee CH, Kuo CM, Huang CC, Tai WC, Chang KC, et al. Abdominal tuberculosis: analysis of clinical features and outcome of adult patients in southern Taiwan. *Chang Gung Med J* 2009;32:509–16.
- [12] Okan A, Jacques P. Imaging of abdominal tuberculosis. *Eur Radiol* 2002;12:312–23.
- [13] Younossian AB, Rochat T, Favre L, Janssens JP. Ascites and highly elevated CA-125 levels in a case of peritoneal tuberculosis. *Scand J Infect Dis* 2006;38(3):216–8.
- [14] Mihmanlı A, Bilgin S, Özşeker F, Baran A, Güneşlioğlu D, Akkaya E. Diagnosis of tuberculous peritonitis. *Toraks Derg* 2003;4(1):21–4.
- [15] Bilgin T, Karabay A, Dolar E, Develioğlu OH. Peritoneal tuberculosis with pelvic abdominal mass, ascites and elevated CA125 mimicking advanced ovarian carcinoma: a series of 10 cases. *Int J Gynecol Cancer* 2001;11:290–4.
- [16] Saygılı U, Guclu S, Altunyurt S, Koyuncuoglu M, Önvural A. Primary endometrioid adenocarcinoma with coexisting endometrial tuberculosis. A case report. *J Reprod Med* 2002;47:322–4.
- [17] Maestre MA, Manzano CD, López RM. Postmenopausal endometrial tuberculosis. *Int J Gynaecol Obstet* 2004 Sep;86(3):405–6.
- [18] Piura B, Rabinovich A, Leron E, Yanai-Inbar I, Mazor M. Peritoneal tuberculosis mimicking ovarian carcinoma with ascites and elevated serum CA-125: case report and review of literature. *Eur J Gynaecol Oncol* 2002;23:120–2.