

Catheter ablation of atrial arrhythmias in a patient with surgically corrected congenital heart disease and inferior vena cava interruption



Jaishankar Krishnamoorthy^{a,*}, Ruchit A. Shah^a, Mulasari Ajit Sankaradas^a

^a Department of Cardiology, Institute of Cardiovascular Diseases, Madras Medical Mission, Chennai

^a India

A 15 year old girl who underwent surgical correction of ventricular septal defect and patent ductus arteriosus ligation in childhood presented with atrial tachycardia of crista terminalis origin and counterclockwise atrial flutter. She also had associated interruption of inferior vena cava which continued as azygous vein and left superior vena cava which drained via coronary sinus into the right atrium. She underwent radiofrequency ablation of both the tachycardias via internal jugular vein and azygous vein approach using 3D electroanatomical mapping system.

© 2014 The Authors. Production and hosting by Elsevier B.V. on behalf King Saud University. This is an open access article under the CC BY-NC-ND license (<http://creativecommons.org/licenses/by-nc-nd/3.0/>).

Keywords: Interrupted inferior vena cava, Atrial flutter, Radiofrequency ablation, Drug refractory arrhythmias, 3D mapping

Introduction

Catheter ablation of atrial arrhythmias is usually performed via the femoral vein. Interruption of the inferior vena cava (IVC) poses technical challenges in the performance of the procedure. We report a case with operated congenital heart disease having drug-resistant atrial arrhythmias with IVC interruption. Internal jugular vein and azygos vein were used for access with 3D electroanatomical mapping to successfully ablate the arrhythmias.

A 15-year-old girl born with a subaortic ventricular septal defect (VSD), patent ductus arteriosus (PDA) with left-to-right shunt, pulmonary artery hypertension, interrupted IVC continuing as azygos vein and left superior vena cava (LSVC) draining via coronary sinus (CS) into the right atrium. She underwent transatrial Gore-Tex patch closure of the VSD and PDA ligation at the age of two years. She also had an imperforate anus with a rectovesical fistula which was surgically repaired in infancy.

She presented with history of recurrent palpitations since the age of ten. Her electrocardiograms

Disclosure: Authors have nothing to disclose with regard to commercial support.

Received 21 July 2014; revised 14 November 2014; accepted 24 November 2014.

Available online 2 December 2014

* Corresponding author at: Institute of Cardiovascular Diseases, Madras Medical Mission, 4A, Dr. JJ Nagar, Mogappair, Chennai 600037, India. Tel.: +91 9791044123.

E-mail address: drkjs68@yahoo.com (J. Krishnamoorthy).



P.O. Box 2925 Riyadh – 11461KSA
Tel: +966 1 2520088 ext 40151
Fax: +966 1 2520718
Email: sha@sha.org.sa
URL: www.sha.org.sa

1016–7315 © 2014 The Authors. Production and hosting by Elsevier B.V. on behalf of King Saud University. This is an open access article under the CC BY-NC-ND license (<http://creativecommons.org/licenses/by-nc-nd/3.0/>).



Peer review under responsibility of King Saud University.
URL: www.ksu.edu.sa
<http://dx.doi.org/10.1016/j.jsha.2014.11.003>



Production and hosting by Elsevier

(ECG) showed regular narrow QRS tachycardia at the rate of 250–300 beats per minute, suggestive of atrial tachycardia (Fig. 1A) and atrial flutter (Fig. 1B). She was drug refractory and had breakthrough episodes on amiodarone, beta blockers, verapamil and digoxin with hemodynamic instability, which once required cardioversion.

In view of a past history of cardiac surgery during early childhood, scar related arrhythmias were a possibility; hence, the patient was taken up for electrophysiology study (EP) with 3D St. Jude Ensite velocity mapping system. Due to IVC interruption with azygos continuation and LSVC

draining to CS, there was a technical difficulty in placing the catheters. Three diagnostic EP catheters were positioned into the high right atrium, right ventricle and CS via azygos vein from the right femoral vein (Fig. 2). EP study revealed atrial tachycardia from the superior crista terminalis. Mapping and ablation of this tachyarrhythmia by transfemoral route was unsuccessful, and internal jugular vein approach was then taken. Superior crista terminalis of right atrium was mapped for the site of earliest activation. At a site which was 50 ms earlier than the P wave on surface ECG, radiofrequency energy of 50 W, 50 °C

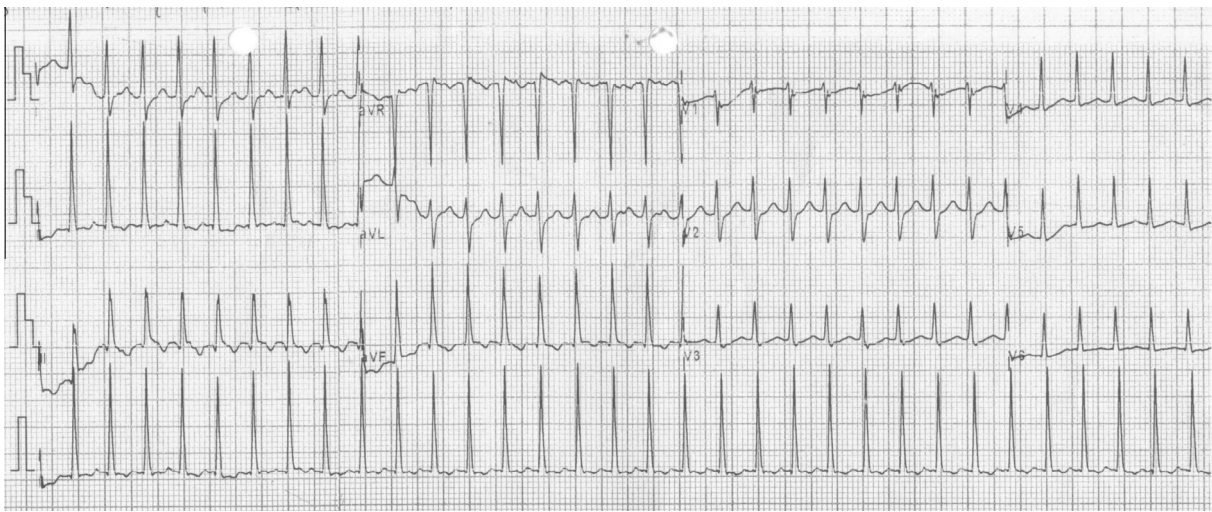


Figure 1A. ECG showing narrow QRS tachycardia suggestive of either atrial tachycardia with varying block or atrial fibrillation.

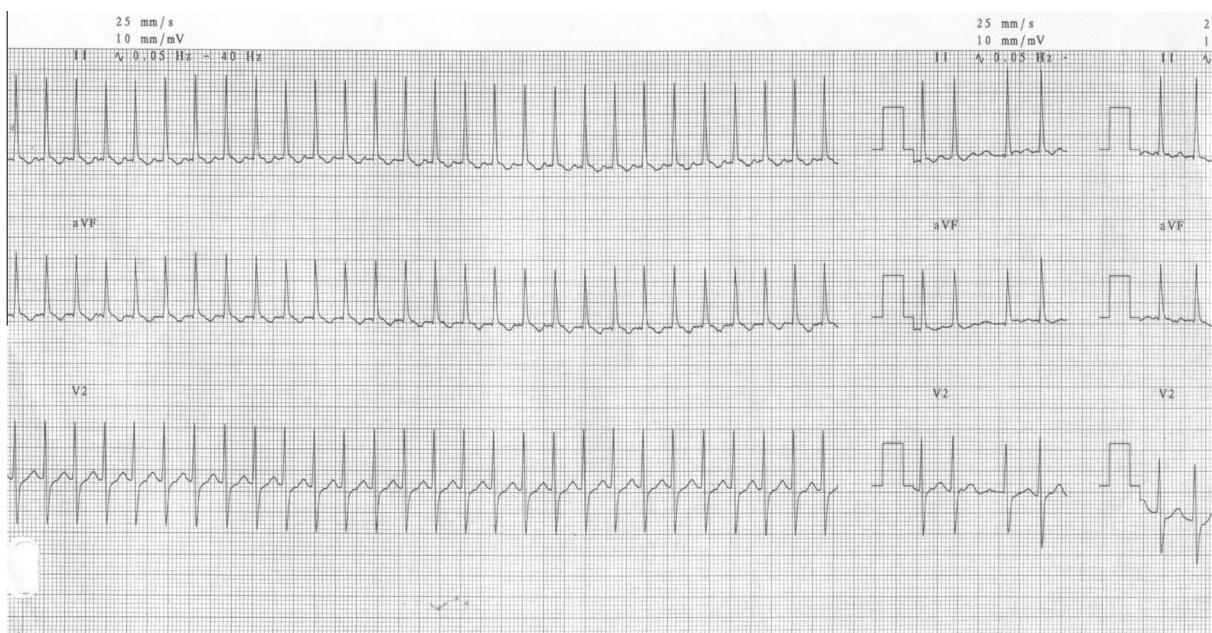


Figure 1B. ECG showing regular narrow QRS tachycardia at rate of 250–300 beats per minute suggestive of atrial flutter.

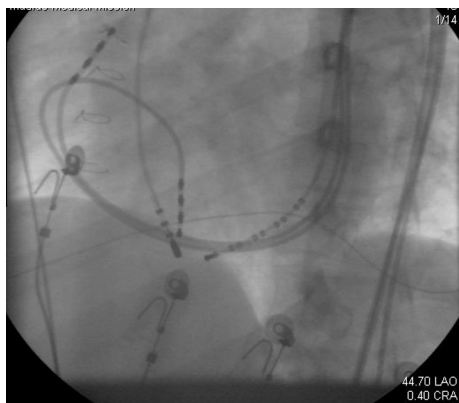


Figure 2. Fluoroscopy showing three diagnostic electrophysiology study catheters placed across LSVC to right atrium, right ventricle and coronary sinus, and mapping catheter through right IJV into cavotricuspid isthmus.

for 60–120 s, with a St. Jude irrigated Cool Path catheter was administered and the tachycardia was terminated (Fig. 3A). Following this, another irregular tachycardia was induced. The activation and propagation map was suggestive of typical counterclockwise atrial flutter. Linear lesions across cavotricuspid isthmus at 50 W, 50 °C for 120–240 s resulted in termination of atrial flutter and restoration of stable sinus rhythm (Fig. 3B). After ablation of this arrhythmia, no more arrhythmia could be induced with vigorous stimulation protocols and with isoprenaline. There were no periprocedural complications. Patient is not on any antiarrhythmic drugs. She has been on a

clinical follow-up of two years and has had no recurrence.

Discussion

IVC interruption or congenital stenosis is a rare congenital anomaly in the general population (<0.1%) [1]. Anomalies of IVC and associated abnormalities include retrocaval ureter, renal vein collar, left sided IVC, bilateral IVC, unilateral or bilateral azygos continuation of the IVC, circum-aortic left renal vein, retroaortic left renal vein, and the absence of infrarenal IVC or entire IVC [2,3]. Its incidence is 0.6% in patients with congenital heart disease (cyanotic and acyanotic) and dextrocardia [13,14]. Catheter ablation of cardiac arrhythmias is usually performed via the femoral vein approach. Congenital or acquired abnormalities of the IVC pose technical challenges in accessing the ablation site. Alternative approaches via internal jugular vein [4–7], subclavian vein [8,9], and transhepatic [10] approach have been described. There are case reports of radiofrequency ablation of atrioventricular nodal re-entrant tachycardia [15], accessory pathways [16], and atrial fibrillation [17] via superior approach in patients with IVC anomalies. There are reports of atrial flutter ablation via azygos vein approach [18]. There are case reports of radiofrequency ablation of atrial arrhythmias in patients with congenital heart diseases and IVC anomalies [11]

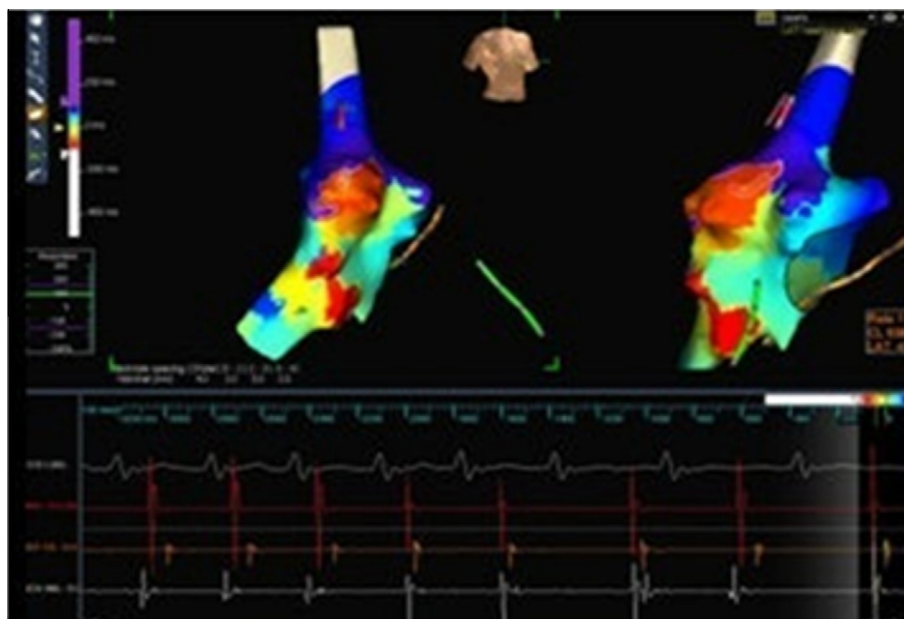


Figure 3A. 3D electroanatomical mapping system showing ablation catheter with good ablation signals at superior crista and termination of tachycardia.

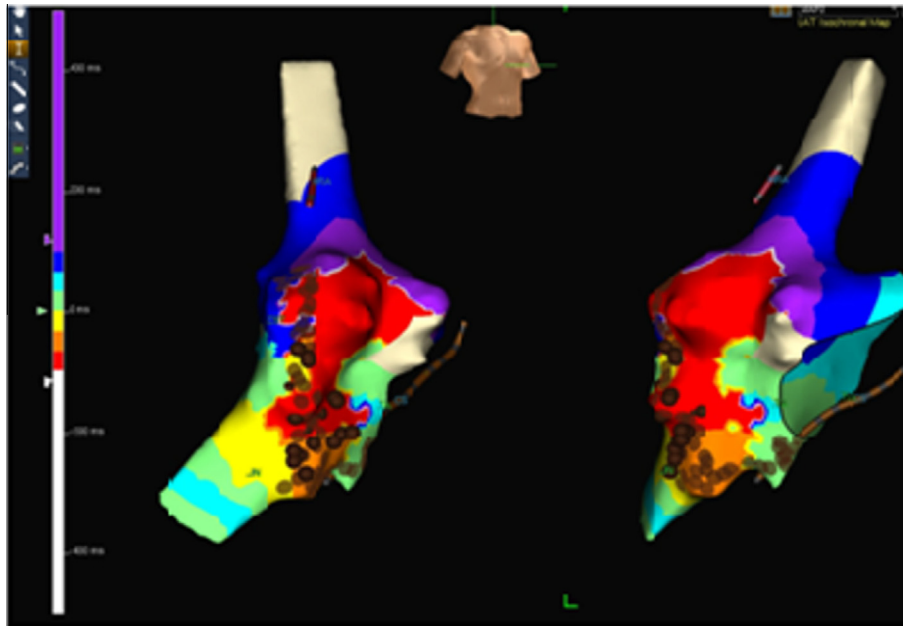


Figure 3B. 3D electroanatomical mapping system with right anterior oblique and left anterior oblique views showing ablation on the cavotricuspid isthmus.

using 3D electroanatomical mapping with Carto-Sound [12].

Conclusion

Arrhythmias in the presence of IVC interruption could be successfully ablated with the aid of 3D electroanatomical mapping. Prior cardiac surgery does not always lead to scar related arrhythmias and an attempt at ablation should always be made with a view to permanent cure. Further, IVC interruption may be technically challenging, but it does not preclude radiofrequency ablation as one of the therapeutic modalities.

References

- [1] Koc Z, Oguzkurt L. Interruption or congenital stenosis of the inferior vena cava: prevalence, imaging, and clinical findings. *Eur J Radiol* 2007;62(2):257–66.
- [2] Mayo J, Gray R, St Louis E, Grosman H, McLoughlin M, Wise D. Anomalies of the inferior vena cava. *AJR Am J Roentgenol* 1983;140(2):339–45.
- [3] Bass JE, Redwine MD, Kramer LA, Huynh PT, Harris Jr JH. Spectrum of congenital anomalies of the inferior vena cava: cross-sectional imaging findings. *Radiographics* 2000;20(3):639–52.
- [4] Salem YS, Burke MC, Kim SS, Morady F, Knight BP. Slow pathway ablation for atrioventricular nodal reentry using a right internal jugular vein approach: a case series. *Pacing Clin Electrophysiol* 2006;29(1):59–62.
- [5] Pai RK, MacGregor JF, Abedin M, Hamdan MH. Radiofrequency catheter ablation of typical atrial flutter and the atrioventricular junction via the superior vena caval approach in a patient with a congenital absence of an inferior vena cava. *J Interv Card Electrophysiol* 2005;14(3):193–5.
- [6] Mukerji S, Khunnawat C, Kantipudi S, Khasnis A, Sankaran S, Thakur RK. 3-dimensional mapping and radiofrequency ablation of atrial flutter in a patient with interrupted inferior vena cava. *J Interv Card Electrophysiol* 2005;14(2):107–9.
- [7] Karthigesan M, Jayaprakash S. Radiofrequency catheter ablation of atrioventricular nodal reentry tachycardia in a patient with inferior vena cava anomaly. *Indian Pacing Electrophysiol J* 2009;9(4):214–8.
- [8] Machado C, Liddon V, Roy D. Radiofrequency catheter ablation of fast pathway via unconventional right subclavian venous access for atrioventricular reentrant tachycardia. *J Interv Cardiol* 2003;16(5):377–80.
- [9] Malavasi VL, Casali E, Rossi L, Grazia Modena M. Radiofrequency catheter ablation of common atrial flutter in a patient with anomalous inferior vena cava and azygos continuation. *Pacing Clin Electrophysiol* 2005;28(7):733–5.
- [10] Singh SM, Neuzil P, Skoka J, Kriz R, Popelova J, Love BA, et al. Percutaneous transhepatic venous access for catheter ablation procedures in patients with interruption of the inferior vena cava. *Circ Arrhythm Electrophysiol* 2011;4(2):235–41.
- [11] Cordina RL, Celermajer DS, McGuire MA. Systemic venous anatomy in congenital heart disease: implications for electrophysiologic testing and catheter ablation. *J Interv Card Electrophysiol* 2012;33(2):143–9.
- [12] Forleo GB, Pappalardo A, Avella A, Visigalli L, Dello Russo A, Tondo C. Real-time integration of intracardiac echocardiography and 3D electroanatomical mapping to guide catheter ablation of isthmus-dependent atrial flutter in a patient with complete situs inversus and interruption of the inferior vena cava with azygos continuation. *J Interv Card Electrophysiol* 2011;30(3):273–7.
- [13] Anderson RC, Adams Jr P, Burke B. Anomalous inferior vena cava with azygos continuation (intrahepatic interruption of the inferior vena cava). Report of 15 new cases. *J Pediatr* 1961;59:370–83.
- [14] Garg N, Agarwal BL, Modi N, Radhakrishnan S, Sinha N. Dextrocardia: an analysis of cardiac structures in 125 patients. *Int J Cardiol* 2003;88(2–3):143–55.

- [15] Arbelo E, Caballero E, Medina A. Successful slow pathway ablation for atrioventricular nodal re-entrant tachycardia via a hypoplastic inferior vena cava in a patient with an azygos continuation. *Europace* 2008;10(4):467-8.
- [16] Guerra Ramos JM, Font ER, Moya I, Mitjans A. Radiofrequency catheter ablation of an accessory pathway through an anomalous inferior vena cava with azygos continuation. *Europace* 2004;6(2):134-7.
- [17] Kato H, Kubota S, Yamada Y, Kumamoto T, Takasawa Y, Takahashi N, et al. Circumferential pulmonary vein ablation of atrial fibrillation via superior vena cava approach in a patient with interruption of the inferior vena cava. *Europace* 2010;12(5):746-8.
- [18] Pérez-Silva A, Merino JL, Peinado R, Lopez-Sendon J. Atrial flutter ablation through the azygos continuation in a patient with inferior vena cava interruption. *Europace* 2011;13(3):442-3.