

Contents lists available at [ScienceDirect](#)

International Journal of Surgery Case Reports

journal homepage: www.casereports.com

Well leg compartment syndrome after surgery for ulcerative colitis in the lithotomy position: A case report

Tsuyoshi Enomoto^{a,*}, Yusuke Ohara^a, Masayoshi Yamamoto^b, Tatsuya Oda^a, Nobuhiro Ohkohchi^a^a University of Tsukuba, Faculty of Medicine, Department of Gastrointestinal and Hepato-Biliary-Pancreatic Surgery, 1-1-1 Tennodai, Tsukuba-shi, Ibaraki-ken 305-8575, Japan^b Department of Gastroenterological Surgery, Tsukuba Medical Center Hospital, 1-3-1 Amakubo, Tsukuba-shi, Ibaraki-ken 305-8558, Japan

ARTICLE INFO

Article history:

Received 21 February 2016
 Received in revised form 4 April 2016
 Accepted 4 April 2016
 Available online 7 April 2016

Keywords:

Well leg compartment syndrome
 Lithotomy position
 Ulcerative colitis
 Ileoanal pouch procedure
 Case report

ABSTRACT

INTRODUCTION: Well leg compartment syndrome (WLCS) is an uncommon and severe complication that occurs after colorectal surgery in the lithotomy position.

PRESENTATION OF CASE: The current patient was a 28-year-old male suffering from ulcerative colitis. He underwent elective proctectomy, including ileal J pouch formation and anal anastomosis with temporary loop ileostomy. The ileoanal pouch procedure was quite difficult, and during this procedure, the high lithotomy and head down tilt positions were continued for 255 min.

After the operation, the patient complained of severe cramping pain, swelling and serious tenderness on palpation in both legs. On the first postoperative day, the patient's complaints gradually worsened. The intra-compartmental pressure was measured, and WLCS was diagnosed. Emergency bilateral fasciotomy was performed. Initially, the patient had a sensory deficit and analgesia, however, his sensory disturbance and pain had almost recovered two months after fasciotomy by rehabilitation.

DISCUSSION: In the current case, the important factors associated with the development of WLCS are thought to be a prolonged operative time in which the patient is placed in the high lithotomy position during ileoanal pouch procedure.

CONCLUSION: We would thus like to emphasize that operations for the ileoanal pouch procedure to treat ulcerative colitis have a high potential for inducing WLCS, because it usually requires a prolonged operative time in which the patient remains in the high lithotomy position.

© 2016 The Authors. Published by Elsevier Ltd on behalf of IJS Publishing Group Ltd. This is an open access article under the CC BY-NC-ND license (<http://creativecommons.org/licenses/by-nc-nd/4.0/>).

1. Introduction

Well leg compartment syndrome (WLCS) is an uncommon and severe complication that causes neurological and motor dysfunction and can be a serious life-threatening complication after surgery in the lithotomy position. WLCS occurs when the intra-compartmental pressure increases within the non-expandable fascial space, subsequently leading to decreased tissue perfusion to the legs, with low tissue perfusion inducing severe complications as a result. It is very important that all operative staff be careful with respect to the patient's intraoperative position and ensure tissue

perfusion in order to prevent WLCS, and obtaining an early diagnosis and treatment is necessary to avoid severe complications. We herein present a case of bilateral WLCS after prolonged surgery in the lithotomy position for the ileoanal pouch procedure, followed by a literature review.

2. Presentation of the case

The patient was a 28-year-old male suffering from ulcerative colitis. He was hospitalized at the department of gastroenterological surgery and underwent elective proctectomy, ileal J pouch formation and anal anastomosis with temporary loop ileostomy. He had previously undergone emergency subtotal colectomy. He was a non-smoker and in good health, except for ulcerative colitis. His height, weight and body mass index were 163 cm, 77 kg and 28.9 (weight/height²), respectively.

* Corresponding author.

E-mail addresses: eno@md.tsukuba.ac.jp (T. Enomoto), y.ohara@md.tsukuba.ac.jp (Y. Ohara), m-yamamoto@tmch.or.jp (M. Yamamoto), tatoda@md.tsukuba.ac.jp (T. Oda), nokochi3@md.tsukuba.ac.jp (N. Ohkohchi).

The operation was carried out under general anesthesia with thoracic epidural anesthesia. Throughout the procedure, the patient wore anti-embolic stockings with an intermittent pneumatic compression device to prevent deep vein thrombosis. He was placed in the lower lithotomy position for the duration of the procedure using the Levitator (MIZUHO Corporation, Tokyo, Japan).

The operation was complicated. In particular, the procedures for transanal mucosectomy and hand sewn anastomosis of the ileal J pouch and dentate line were quite difficult because of the patient's narrow pelvis and long anal canal as well as the tension on the mesentery of the small bowel. During the procedure, the high lithotomy and head down tilt positions were continued for 255 min. The mean arterial systolic blood pressure was maintained at an average of 80 mm Hg. The operation lasted for 489 min, with 880 ml of blood loss.

One hour after the operation, the patient complained of severe cramping-type pain, swelling and serious tenderness on palpation in both legs (Fig. 1). Pulsation of the posterior tibial artery and dorsalis pedis artery was present in both legs. Two hours after the completion of surgery, gross hematuria was observed in the urinary balloon catheter. A blood chemistry analysis showed both the lactate dehydrogenase level and creatine kinase level to have markedly increased to 2103 IU/l, 142,850 IU/L, respectively. Urinalysis revealed 3+ results for blood and 3+ results for protein. In addition, myoglobin was elevated to 3000 ng/ml; however, the patient's renal function remained within the normal limits.

On the first postoperative day, the patient's complaints gradually worsened. We had a high index of suspicion for WLCS. Immediately, the intra-compartmental pressure was measured, and the results were as follows; the right anterior compartment was 130 mm Hg and the left posterior compartment was 80 mm Hg. Therefore, WLCSs were diagnosed in both legs.

Emergency bilateral fasciotomy with double incisions to release all four compartments was performed. All compartment muscles were extruded from the compartment and found to exhibit abnormal swelling and a slightly dark appearance (Fig. 2), although there was no evidence of necrosis of the muscles. The incisions were left open with sterile dressings (Fig. 3), and closure of the incisions was performed two weeks later.

Postoperatively, the patient had a complicated bilateral leg sensory deficit and analgesia, with reduced power on plantar flexion. At first, he was unable to dorsiflex and evert both feet. Seven days post-fasciotomy, rehabilitation was started. On the 25th postoperative day, he was able to walk with the support of crutches. His condition almost completely recovered, except for a sensory disturbance. Two months after fasciotomy, his sensory disturbance and pain had improved.

3. Discussion

Compartment syndrome is a well-known abnormal injury. However, it remains not widely known that compartment syndrome develops not from injury, but as a result of "abnormal" positioning of the limbs. Since the calf compartments are the most commonly affected, the term WLCS is used to describe this syndrome [1]. The overall incidence of WLCS in patients after major pelvic surgery in the lithotomy position is estimated to be 1 in 3500 cases [2]. The lower limb consists of four main compartments: the anterior, lateral, superficial and deep posterior compartments. These regions are bordered by strong, inelastic fascial layers or bone, and through each run neurovascular structures [3]. WLCS is caused by pathological elevation of the intra-compartmental pressure within the non-expansile tissue envelope [4]. A reduction in the blood perfusion pressure causes tissue ischemia. Ischemia may be followed by reperfusion with subsequent capillary leakage and

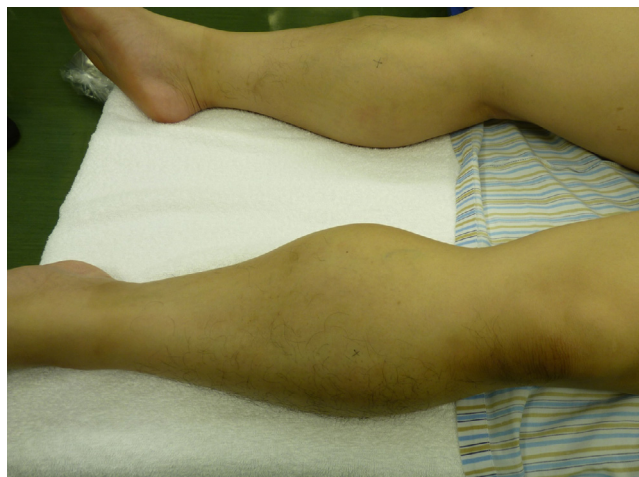

Fig. 1. One hour postoperatively, the patient complained of severe cramping-type pain, swelling and serious tenderness on palpation in both legs.

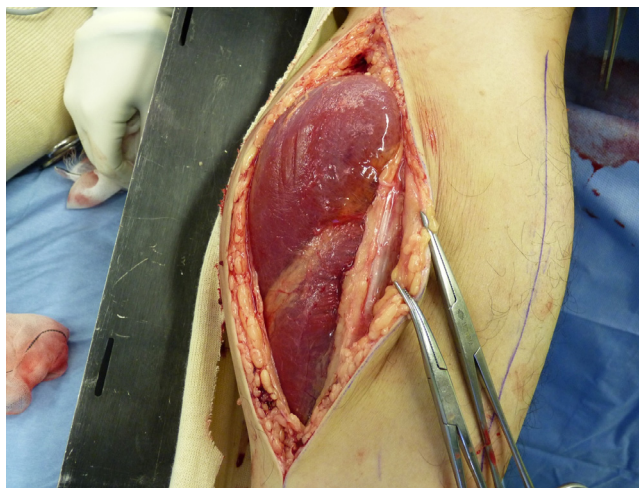


Fig. 2. Emergency bilateral fasciotomy with double incisions to release all four compartments was performed. All compartment muscles were extruded from the compartment and found to exhibit abnormal swelling and a slightly dark appearance.

tissue edema, after which a vicious circle of tissue edema and further impairment of perfusion may develop, subsequently leading to the onset of compartment syndrome [5].

Two pressures are considered to affect an elevation in the intra-compartmental pressure: these are the external pressure and perfusion pressure [6]. When the external pressure compresses the skin and feeding vessels in the calf regions, then the blood flow in the peripheral vessels stops and the adjacent muscles and nerves thus become exposed to ischemia. The external pressure is defined by the muscular status of the lower limbs, leg-holding types, the use of intermittent pneumatic calf compressors and circumferential wrappings. The hypoperfusion pressure reduces the blood flow, which thereby prevents nutrient and oxygen supply to the muscle cells [6]. The perfusion pressure is defined by prolonged surgery in the lithotomy position and the Trendelenburg position, ankle dorsiflexion, intraoperative hypotension, hypovolemia, hypothermia, vasoconstrictive drugs, epidural anesthesia, peripheral vascular disease and surgical retraction of major vessels intraoperatively [4]. In particular, the duration of the lithotomy position and the hydrostatic gradient between the level of the heart and the ankle

can be considered the most important factors associated with the perfusion pressure in the lower limbs [7].

WLCS typically presents postoperatively with leg pain out of proportion to the clinical findings. In general, patients complain of severe and otherwise unexplainable leg pain. Other symptoms include pain on passive stretching in the involved compartment, paresthesia and, in rare cases, at the late stage, pallor, paresis and pulselessness, most often seen in the setting of vascular injury. The sensitivity of individual findings is low (13–19%); however, each additional clinical finding observed increases the probability of compartment syndrome, up to 93% in cases involving three symptoms [8].

It is very important to accurately diagnose WLCS. The definitive diagnosis of WLCS is made only based on direct measurements of the intra-compartmental pressure. If WLCS is clinically suspected, the intra-compartmental pressure should be measured rapidly. Although the critical compartment pressure value is controversial, surgical decompression is needed when the compartmental pressure is over 30 mm Hg [3].

Once the diagnosis of a compartment syndrome is established, urgent fasciotomy through single or double incisions should be considered. Accurate placement of the incision is essential [9,10]. The superficial and deep posterior compartments are decompressed through a medial longitudinal incision placed 1–2 cm posterior to the medial border of the tibia. The anterior and peroneal compartments are decompressed through a longitudinal incision 2 cm lateral to the anterior tibial border [11]. Delayed treatment leads to increased morbidity and mortality.

Sajid et al. reviewed all published articles on compartment syndrome after colorectal surgery in the prolonged lithotomy position, and after that, few case reports were published [12–14]. Among these patients, 23 out of 36 subjects were treated surgically due to inflammatory bowel disease, especially as a result of the ileoanal pouch procedure. In colorectal surgery, compared with procedures for colorectal cancer, the reasons why WLCS tends to occur during operations for ulcerative colitis are considered to be as follows. In these operations, the patient is placed in the high lithotomy position for the ileoanal pouch procedure. This procedure is technically difficult; therefore, the operative time while in the high lithotomy position is prolonged.

In the current case, the risk factors for the development of WLCS are mainly thought a prolonged operative time in the high lithotomy position during the ileoanal pouch procedure, which decreased the perfusion pressure in the lower limbs. The patient's large muscle bulk, and intraoperative hypotension while placed in the high lithotomy position also affected the elevation of external pressure and the decreased perfusion pressure.

4. Conclusions

We therefore would emphasize that performing operation for the ileoanal pouch procedure to treat ulcerative colitis have a high potential for inducing WLCS, because it usually requires a prolonged operative time in which the patient is placed in the high lithotomy position. Therefore, colorectal surgeons should consider lowering the patients' legs periodically during such operation procedures in the high lithotomy position to prevent development of WLCS.

Conflict of interests

The authors declare that they have no conflict of interests.

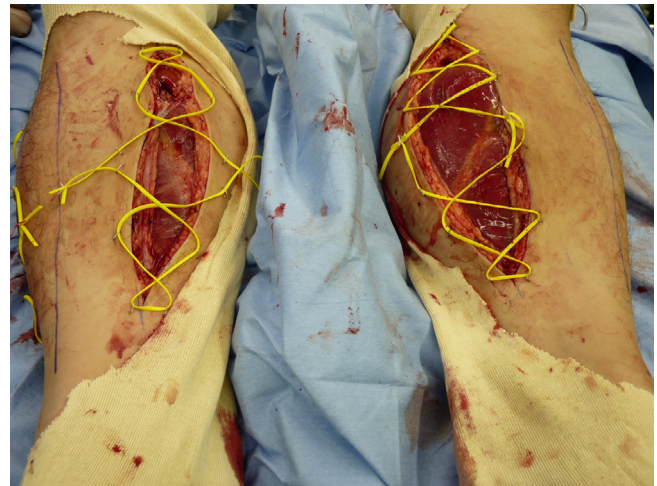


Fig. 3. There was no evidence of necrosis of the muscles. The incision was left open with sterile dressings.

Funding

All authors have no funding of research.

Ethical approval

Ethical approval is not required.

Consent

Written informed consent was obtained from the patient for the publication of this case report and any accompanying images.

Author contribution

Tsuyoshi Enomoto, Yusuke Ohara, Tatsuya Oda and Nobuhiro Ohkochi participated in the idea for the paper and helped to draft this manuscript. Tsuyoshi Enomoto and Masayoshi Yamamoto participated in the clinical treatment. All authors read and approved the final manuscript.

Guarantor

Tsuyoshi Enomoto.

References

- [1] B. Heppenstall, V. Tan, WLCS, *Lancet* 354 (1999) 970.
- [2] E. Ikeya, J. Taguchi, K. Ohta, O. Miyazaki, Y. Hashimoto, K. Yagi, Compartment syndrome of bilateral lower extremities following laparoscopic surgery of rectal cancer in lithotomy position: report of a case, *Surg. Today* 36 (2006) 1122–1125.
- [3] F.H. Mumtaz, H. Chew, J.S. Gelister, Lower limb compartment syndrome associated with the lithotomy position: concepts and perspectives for the urologist, *BJU Int.* 90 (2002) 792–799.
- [4] A. Raza, D. Byrne, N. Townell, Lower limb (well leg) compartment syndrome after urological pelvic surgery, *J. Urol.* 171 (2004) 5–11.
- [5] M.S. Simms, T.R. Terry, WLCS after pelvic and perineal surgery in the lithotomy position, *Postgrad. Med. J.* 81 (2005) 534–536.
- [6] J. Mizuno, T. Takahashi, Male sex, height, weight, and body mass index can increase external pressure to calf region using knee-crutch-type leg holder system in lithotomy position, *Ther. Clin. Risk Manag.* 12 (2016) 305–312.
- [7] J.R. Halliwill, S.A. Hewitt, M.J. Joyner, M.A. Warner, Effect of various lithotomy positions on lower-extremity blood pressure, *Anesthesiology* 89 (1998) 1373–1376.
- [8] E.C. Bauer, N. Koch, W. Janni, H.G. Bender, M.C. Fleisch, Compartment syndrome after gynecologic operations: evidence from case reports and reviews, *Eur. J. Obstet. Gynecol. Reprod. Biol.* 173 (2014) 7–12.
- [9] G.G. Cooper, A method of single-incision, four compartment fasciotomy of the leg, *Eur. J. Vasc. Surg.* 6 (1992) 659–661.

- [10] S.J. Mubarak, C.A. Owen, Double-incision fasciotomy of the leg for decompression in compartment syndromes, *J. Bone Joint Surg. Am.* 59 (1977) 184–187.
- [11] M.F. Pearse, L. Harry, J. Nanchahal, Acute compartment syndromes resulting from anticoagulant treatment, *BMJ* 325 (2002) 557–558.
- [12] M.S. Sajid, A.J. Shakir, K. Khatri, M.K. Baig, Lithotomy-related neurovascular complications in the lower limbs after colorectal surgery, *Colorectal Dis.* 13 (2011) 1203–1213.
- [13] K.Y. Chin, S.J. Hemington-Gorse, C.M. Darcy, Bilateral well leg compartment syndrome association with lithotomy (Lloyd Davies) position during gastrointestinal surgery: a case report and review of literature, *Eplasty* 9 (2009) e48.
- [14] A. Kalin, V. Hariharan, F. Tudor, Unicompartent compartment syndrome following laparoscopic colonic resection, *BMJ Case Rep.* (2013), <http://dx.doi.org/10.1136/bcr-2013-009894>.

Open Access

This article is published Open Access at scimedirect.com. It is distributed under the [IJSCR Supplemental terms and conditions](#), which permits unrestricted non commercial use, distribution, and reproduction in any medium, provided the original authors and source are credited.