



Available online at

SciVerse ScienceDirect
www.sciencedirect.com

Elsevier Masson France

EM|consulte
www.em-consulte.com/en

Orthopaedics
& Traumatology
Surgery & Research

ORIGINAL ARTICLE

Paralytic congenital talipes equinovarus of unknown origin: A new entity. Multicenter study of 42 cases

A. Roux^{a,*}, J.M. Laville^a, V. Rampal^b, R. Seringe^b, F. Salmeron^a

^a Pediatric Orthopaedic Surgery Department, F-Guyon Regional Hospital Center, 97405 Saint-Denis, Reunion

^b Hôpital Saint-Vincent-de-Paul, université Paris Descartes, 82, avenue Denfert-Rochereau, 75014 Paris, France

Accepted: 28 February 2012

KEYWORDS

Clubfoot;
Talipes equinovarus;
Paralysis;
Recurrence;
Tendon transfer;
Relapse

Summary

Background: Paralysis of the lateral and/or anterior leg muscles can lead to relapse of treated talipes equinovarus.

Hypothesis: The muscle function impairment is due to isolated permanent paralysis, and early palliative tendon transfer may prevent recurrence of the deformity.

Material and methods: Forty-two cases of congenital talipes equinovarus that recurred after conservative therapy were reviewed after a mean follow-up of 10 years. In 39 cases, second-line surgery was performed (posteromedial release, $n=33$; and muscle transfer, $n=26$). Outcomes were evaluated clinically.

Results: Separating the cases into two groups, based on whether muscle transfer was performed, showed a statistically significant difference: muscle transfer intended to restore eversion and/or dorsal flexion of the foot was associated with significantly better functional outcomes.

Discussion: In addition to providing etiological insights, the identification of paralysis in patients with talipes equinovarus can influence treatment decisions, depending on the nature of the muscle deficiencies, with the goal of preventing recurrences. Early muscle transfer to restore eversion and/or dorsal flexion of the foot may provide the best functional outcomes by minimizing the need for soft-tissue release.

Level of evidence: IV, retrospective multicentre study.

© 2012 Elsevier Masson SAS. All rights reserved.

Introduction

Restoration of muscle function responsible for eversion and dorsal flexion of the foot is a crucial step in the course of treated congenital talipes equinovarus (CTEV). This step cannot be achieved in patients with permanent paralysis of the anterior and/or lateral leg muscles, who usually

* Corresponding author. Tel.: +33 26 29 05 490;
fax: +33 26 29 05 498.

E-mail address: chir.infantile.fguyon@chr-reunion.fr (A. Roux).

experience a recurrence of the deformities in the absence of timely palliative tendon transfer surgery. The potential relevance of paralysis in CTEV is not specifically addressed in the medical literature, and neither is it mentioned in any of the textbooks focusing on CTEV, such as those by Turco [1], Simons [2], and Ponseti [3].

To evaluate the impact of leg muscle paralysis in CTEV, we conducted a retrospective multicentre study of 42 cases. In addition to providing etiological insights, the identification of paralysis in patients with CTEV can influence treatment decisions, depending on the nature of the muscle deficiencies, with the goal of preventing recurrences.

Material and methods

Inclusion criteria

We retrospectively reviewed cases of CTEV with isolated permanent paralysis in the same leg and a recurrence of the deformity after conservative treatment. All patients meeting these criteria and managed between September 1979 and May 2005 were included. Conservative treatment for CTEV was started at birth. The patients were managed at one of three centres in France (Saint-Vincent-de-Paul Teaching Hospital, Paris; Teaching Hospital, Toulouse; and Regional Hospital, Saint-Denis, Reunion), either from the outset or after referral from another centre.

Study patients

We identified 42 cases of CTEV meeting our inclusion criteria, in 30 patients, 15 girls and 15 boys. The left foot was involved in 11 patients, the right foot in seven, and both feet in 12. Concomitant abnormalities that were apparently unrelated to the foot deformity were noted in seven patients (Hirschsprung's disease, $n=2$; esophageal atresia and tarsal synostosis, $n=1$; microcephaly, $n=1$; phocomelia of the contralateral lower limb, $n=1$; and double major curve scoliosis with onset in adolescence, $n=2$).

The motor impairment was usually suspected during the first visit (Figs. 1 and 2) but was confirmed only after 18 months of age. The anterior leg compartment was

Table 1 Results of the electrophysiological studies done in 26 cases.

Findings	
Anterior horn involvement	11
Axonal degeneration	6
Common fibular nerve injury	2
Muscle wasting in the anterior and lateral leg compartments	2
Normal	5

involved in ten cases, the lateral leg compartment in seven, and both compartments in 25.

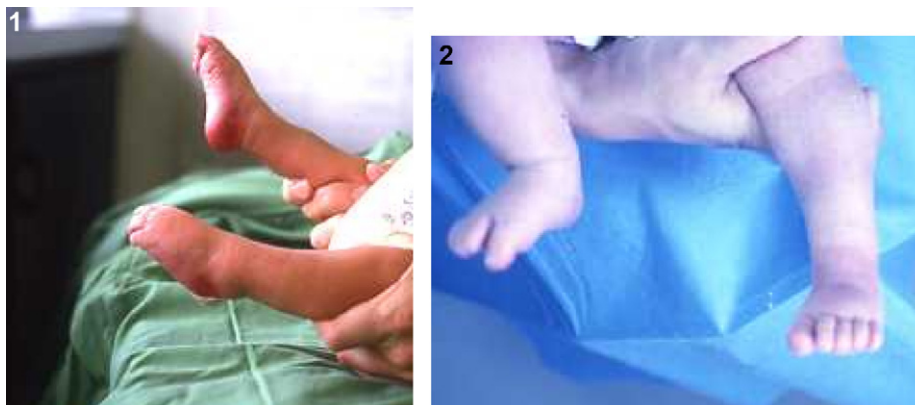
One or two electrophysiological studies were obtained in 26 cases. As shown in Table 1, anterior horn involvement was the most prevalent abnormality. Axonal degeneration was noted in six cases and an absent electromyogram trace in one case. Findings were normal in five cases. Anatomical abnormalities were noted during surgery in eight feet in five patients: they consisted in anterior leg muscle hypoplasia in five cases and common fibular nerve agenesis in three cases.

The outcomes varied with the type of initial conservative treatment. When the Ponseti method was used (seven feet in five patients), the outcome was favourable initially, with a flexible foot and more than 15° of dorsal flexion. However, recurrent deformities developed gradually in all seven cases when use of the splints was decreased. The remaining cases (35 feet in 25 patients) were managed using the French functional method; the deformities were only partially corrected and recurrent deformities developed consistently. Mean age at confirmation of these outcomes was 18 months (range, 7 months–3 years).

Treatment

Conservative treatment was used initially in all 42 cases and consisted in the Ponseti method [3] or the French functional method described by Seringe and Atia [4].

The indication for second-line surgical treatment was absence of muscle function recovery in the anterior and/or lateral leg compartments after 18 months of age, with or without recurrent deformities. Surgery consisted in



Figures 1 and 2 Clinical appearance of congenital talipes equinovarus with paralysis.

Table 2 Surgical procedures performed in 39 cases of congenital talipes equinovarus with paralysis.

Procedure	Number of cases	Type of transfer	Compartment involved		Outcome
PMR only	13		3 ant.	10 AL	Good: 0 Fair: 8 Poor: 5
PMR + transfer	20	17 tibialis post.	5 ant.	4 lat. 8 AL	Good: 13 Fair: 1 Poor: 3
		2 tibialis ant.		2 lat.	Good: 1 Fair: 1 Poor: 1
		1 hemi-triceps	1 ant.		Poor: 1
Transfer only	6	3 tibialis post. + FHL		3 AL	Very good: 1 Good: 2
		2 tibialis post.		2 AL	Good: 1 Fair: 1
		1 tibialis ant.		1 lat.	Good: 1

PMR: posteromedial release; FHL: flexor hallucis longus; ant.: anterior; post.: posterior; lat.: lateral; AL: anterolateral.

posteromedial release with or without palliative muscle and tendon transfer or, in a minority of cases, in isolated tendon transfer.

The muscle transfer techniques used in our study cases were as follows:

- lateral transfer of the tibialis anterior muscle ($n=3$);
- transfer of the tibialis posterior muscle as described by Watkins [5] ($n=22$ cases);
- transfer of the flexor hallucis longus muscle ($n=3$), which was preferred over transfer of the flexor digitorum communis muscle to avoid the development of a dorsal bunion; flexor hallucis longus muscle transfer was always performed in combination with tibialis posterior muscle transfer, and the two re-implantation sites could be different depending on the desired lever arm;
- hemi-triceps surae muscle transfer to the dorsum of the foot ($n=1$).

Secondary surgery was performed in 39 of the 42 cases (Table 2). Posteromedial release was performed in 33 cases (and was the only procedure in 13 cases) and muscle transfer in 26 cases (tibialis posterior in 22 cases, including three with concomitant flexor hallucis longus transfer; tibialis anterior in three cases; and hemi-triceps surae in one case) (Table 3). Muscle transfer was the only procedure in six cases, at a mean age of 4 years (range, 18 months–7 years); and was combined with posteromedial release in 20 cases, at a mean age of 2 years (range, 7 months–3 years). Mean age at performance of isolated posteromedial release ($n=13$) was 34 months (range, 5 months–8 years).

Evaluation methods

The Dimeglio score was determined to evaluate the severity of CTEV, and concomitant birth defects were looked for. Analytical muscle strength testing was performed routinely before surgery and at last follow-up. In patients with unilateral CTEV, calf diameter was compared between the

Table 3 Type of tendon transfer performed according to the muscle compartment involved.

Compartment involved	Transfer
Anterior ($n=10$, including 1 not treated surgically)	Tibialis post., $n=5$ Hemi-triceps, $n=1$
Lateral ($n=7$)	Tibialis post., $n=4$ Tibialis ant., $n=3$
Anterior and lateral ($n=25$, including 2 not treated surgically)	Tibialis post., $n=10$ Tibialis post.+FHL, $n=3$

FHL: flexor hallucis longus; ant.: anterior; post.: posterior.

two sides. An electrophysiological study was performed when technically feasible. Imaging studies have not been proven useful in CTEV and were not performed in the study patients.

Outcomes were classified into four categories depending on muscle function and residual anatomical defects:

- very good outcome, normal foot function with leg muscle wasting and mild residual defects that did not create difficulties for walking or procuring footwear;
- good outcome, restored foot function (eversion and at least 15° of dorsal flexion) with a residual morphological abnormality measurable with the foot in plantigrade position (metatarsus adductus, inadequate derotation of the calcaneotarsal unit, calcaneal varus);
- fair outcome, absent eversion and dorsal flexion with the foot in plantigrade position, with or without residual defects;
- and poor result, inability to place the foot in plantigrade position or recurrence.

These four outcomes were scored from 1 (poor) to 4 (very good) in the groups managed with and without muscle transfer. These two groups were then compared using the

Table 4 Postoperative outcomes in the groups managed with and without muscle transfer.

Outcome	Muscle transfer	
	Yes	No
Very good	1	0
Good	18	0
Fair	3	8
Poor	4	5
Total	26	13

non-parametric Mann-Whitney test — use of a nonparametric test suggests the data were not normally distributed; therefore, shouldn't the data reported as means \pm SEM be reported as medians (IQR)?

Results

Mean follow-up was 10 years (range, 3–35 years). None of the patients was lost to follow-up. No secondary overcorrection or other notable complications were recorded. The CTEV severity grade according to Dimeglio was II in 15 cases, III in 12 cases, and IV in 11 cases; the score could not be determined in the remaining four cases in three children who were referred secondarily to the study centres. The mean calf circumference difference at the time of surgery in the 18 patients with unilateral CTEV was 4 mm (range, 2–9 mm).

At last follow-up, the outcome was very good in one case, good in 18 cases, fair in 11 cases, and poor in nine cases. Fair outcomes were noted in all three cases managed without surgery. However, a normal foot was not obtained in any of the cases, because the treatments merely palliated the deficiencies. Sample sizes in the Dimeglio score subgroups were too small for a meaningful statistical analysis.

We analysed the outcomes according to whether muscle transfer was performed to restore eversion and/or dorsal flexion of the foot. A statistically significant difference was found between these two groups ($P < 0.001$) (Table 4): muscle transfer was clearly associated with better functional outcomes. Muscle transfer was performed at the time the paralysis was diagnosed (18 months of age) in six cases (four patients), none of which required posteromedial release. In these six cases, the foot was still flexible when muscle transfer was performed. In three of these six cases, combined tibialis posterior and flexor digitorum longus transfer was performed; the outcome was very good in one case and good with persistent forefoot adduction in two cases. Isolated transplantation of the tibialis posterior tendon as described by Watkins [5] was performed twice, with one good and one fair outcome. In the last case, the outcome was good after isolated tibialis anterior transfer.

In the remaining 20 cases managed with muscle transfer, posteromedial release was required also. In eight cases with paralysis of both the anterior and lateral compartments, the tibialis posterior muscle was transferred; the outcome was good in five cases, fair in one case, and poor in two cases. Of

the six cases with paralysis of the lateral compartment only, two were managed by tibialis anterior transfer (one good outcome and one fair outcome) and four with tibialis posterior transfer (four good outcomes). In six cases, paralysis was confined to the anterior compartment; tibialis posterior transfer, performed in five of these cases, produced four good outcomes and 1 poor outcome; the remaining case was managed with hemi-triceps transfer (Spitzzy procedure), which produced a poor outcome. Muscle transfer was not performed in the two patients with common fibular nerve agenesis, both of whom had fair outcomes.

Discussion

This study focuses on a specific abnormality that can occur concomitantly with CTEV and consistently causes the deformity to recur, namely, isolated permanent paralysis of the muscles responsible for foot eversion and/or dorsal flexion. Our series of 42 cases is retrospective, as well as heterogeneous, given the multicentre design. Nevertheless, our data raise important issues regarding the etiology and management of CTEV.

Whether neurological abnormalities may explain some cases of CTEV, designated "idiopathic CTEV", remains debated. Ahmed et al. found that the subtalar joint synovium exhibited a significant deficiency in sensory and mature nerve fibres (ranging from 28% to 52% depending on the type of neurotransmitter involved) [6]. Routine electrophysiological studies do not seem to benefit the management of patients with idiopathic CTEV [7]. In our study, the electrophysiological findings failed to predict the outcome. In addition, electrophysiological studies are difficult to perform and to interpret in neonates, and they contribute to the diagnosis only when performed in specialised centres [8]. Normal findings may merely constitute evidence of the technical difficulties raised by electrophysiological studies. Among differential diagnoses, stretching of the common fibular nerve related to breech presentation is usually followed by a full recovery within 6 weeks [9]. Herceg et al. [10] suggested that idiopathic CTEV might be related to muscular abnormalities, a hypothesis that converges with that of a neurological abnormality, since muscles and nervous structures develop interdependently. In a study of fetal cadavers obtained by premature termination of pregnancy for high-level myelomeningocele, leg muscle fibrosis due to denervation was 5% to 30% more marked in the group with CTEV than in the group without CTEV, and the peroneus longus muscle was more severely involved than the gastrocnemius muscle [11]. These data suggest that CTEV may be related to a neurological abnormality that results in a muscle imbalance. However, muscle hypoplasia or agenesis was found by surgical exploration in 5 of our cases. Muscle hypoplasia or agenesis may constitute a primary birth defect or occur as the result of a vascular abnormality. Hootnick et al. and Sodre et al. reported arterial abnormalities in 80% of cases of CTEV, with predominant involvement of the anterior tibial artery [12,13]. A magnetic resonance–angiography study produced similar findings [14]. Thus, there may be a subtle difference between CTEV due to developmental defects of the bones, muscles, and ligaments and CTEV due to muscle function

impairment of intrauterine onset with subsequent stiffness and underdevelopment resulting in more or less complete forms of clubfoot. Currently available data fail to shed any light on the possible relevance to CTEV of the concomitant birth defects recorded in our patients (e.g., Hirschsprung's disease and oesophageal atresia).

Some of our patients exhibited features that were disturbingly similar to those seen in arthrogryposis multiplex congenita, such as anterior horn alterations, peripheral nerve abnormalities, and muscle dystrophy [15]. Furthermore, clubfoot associated with arthrogryposis usually carries a high recurrence rate (73% according to Niki et al. [16]). Hyam et al. [17] previously pointed out the similarities between idiopathic CTEV and arthrogryposis. Over 80% of patients with arthrogryposis have anterior horn abnormalities [15,17,18], and Swart reported a 40% decrease in anterior horn motor neurons in some cases of idiopathic CTEV [19].

In our study of CTEV with paralysis, the initial outcomes after conservative treatment were similar to those reported in CTEV with normal motor function. However, the deformity recurred consistently. Anterior and/or lateral leg compartment paralysis in patients with CTEV is not always permanent and may resolve over time. Thus, the current validated treatment strategy consisting in initial conservative therapy provides enough time for spontaneous resolution to occur. If the paralysis persists after 18 months of age, muscle transfer surgery is indicated. Muscle transfer surgery should be performed before the deformity recurs, as posteromedial release is unnecessary in this situation (six of our cases). According to Ponseti [3], recurrence of the deformity develops within 6 months after the end of casting, i.e., during the early phase of splinting. The goal is to achieve a functional outcome similar to that seen in idiopathic CTEV without paralysis, which is considerably better in terms of joint function when conservative therapy is sufficient. In idiopathic CTEV, a variable degree of eversion muscle deficiency has been reported at birth [18,20]. This finding suggests several hypothesis, for instance that the action of the tibialis anterior muscle is not appropriately counteracted by the fibular muscles and tends to cause adduction and supination of the foot [21]. Similarly, the tibialis posterior muscle is not counteracted by the fibularis longus muscle and tends to invert the foot. These imbalances may explain the recurrence of idiopathic CTEV after conservative treatment alone. If splinting is not continued until eversion is sufficient to counteract the antagonist muscles, recurrence of the deformity is inevitable. When CTEV is combined with permanent paralysis of the lateral and/or anterior leg muscles, muscle function does not recover, and prolonged nocturnal splinting is never sufficient. Appropriate muscle transfer surgery must be performed.

Selection of the type of muscle transfer depends on whether the tibialis anterior muscle is present and functional and on whether the lateral compartment muscles are paralysed. If the tibialis anterior is present and functional, it is transferred laterally over a distance that depends on the severity of the deformity. In patients who lack a functioning tibialis anterior muscle, the tibialis posterior should be transferred, if needed with the flexor hallucis longus to increase strength, improve load distribution, and prevent the development of a dorsal bunion.

Conclusion

CTEV with permanent paralysis of the lateral and/or anterior leg muscles is uncommon but not exceedingly rare. The treatment differs substantially from that of idiopathic CTEV, since permanent leg muscle impairment is often associated with disappointing final outcomes. Initial conservative treatment provides enough time to allow for muscle function recovery to occur. In patients with persistent paralysis, appropriate muscle transfer surgery should be performed before the deformity recurs.

Disclosure of interest

The authors declare that they have no conflicts of interest concerning this article.

Acknowledgements

We are grateful to J.P. Cahuzac for sharing his medical files.

References

- [1] Turco VJ. Clubfoot. New York: Churchill Livingstone; 1981.
- [2] Simons G. The clubfoot. Berlin: Springer-Verlag; 1993.
- [3] Ponseti I. Congenital clubfoot. Fundamentals of treatment. New York: Oxford University Press; 1996.
- [4] Seringe R, Attia R. Pied bot varus équin congénital idiopathique: résultats du traitement «fonctionnel» (269 pieds). *Rev Chir Orthop* 1990;76:490–501.
- [5] Watkins MB, Jones RB, Ryder CT, Brown TH. Transplantation of the posterior tibial tendon. *J Bone Joint Surg (Am)* 1954;36:1181.
- [6] Ahmed M, Ahmed N, Khan KM, Umer M, et al. Sensory hypoinnervation in clubfoot. *J Bone Joint Surg (Br)* 2004;86:1163–9.
- [7] Bill PL, Versfeld GA. Congenital clubfoot: an electromyographic study. *J Pediatr Orthop* 1982;2:139–42.
- [8] Feldbrin Z, Gilai AN, Ezra E, Khernosh O, Kramer U, Wientroub S. Muscle imbalance in the aetiology of idiopathic clubfoot: an electromyographic study. *J Bone Joint Surg (Br)* 1995;77:596–601.
- [9] Godley DR. Neonatal peroneal neurapraxia: a report of two cases and review of the literature. *Am J Orthop* 1998;27:803–4.
- [10] Herceg MB, Weiner DS, Agamanolis DP, Hawk D. Histologic and histochemical analysis of muscle specimens in idiopathic talipes equinovarus. *J Pediatr Orthop* 2006;26:91–3.
- [11] Omeroglu S, Peker T, Omeroglu H, Gulekon N, Mungan T, Danisman N. Intrauterine structure of foot muscles in talipes equinovarus due to high-level myelomeningocele: a light microscopic study in foetal cadavers. *J Pediatr Orthop B* 2004;13:263–7.
- [12] Hootnick DR, Levinsohn EM, Crider RJ, Packard Jr DS. Congenital arterial malformations associated with clubfoot: a report of two cases. *Clin Orthop* 1982;167:160–3.
- [13] Sodre H, Bruschini S, Mestriner LA, Miranda Jr F, Levinsohn EM, Packard F D.S. Jr, et al. Arterial abnormalities in talipes equinovarus as assessed by angiography and the Doppler technique. *J Pediatr Orthop* 1990;10:101–4.
- [14] Merrill LJ, Gurnett CA, Siegel M, Sonavane S, Dobbs MB. Vascular abnormalities correlate with decreased soft tissue volumes in idiopathic clubfoot. *Clin Orthop Relat Res* 2011;469:1442–9.

- [15] Bewan WP, Hall JG, Bamshad M, Staheli LT, Jaffe KM, Song K. Arthrogryposis multiplex congenita (amyoplasia): an orthopaedic perspective. *J Pediatr Orthop* 2007;27:594–600.
- [16] Niki H, Staheli L, Mosca V. Management of clubfoot deformity in amyoplasia. *J Pediatr Orthop* 1997;17:803–7.
- [17] Hyam I, Handelsman JE, Badenhorst M, Pickering A. The muscles in club foot—a histological, histochemical and electron microscopic study. *J Bone Joint Surg (Br)* 1977;59:466–72.
- [18] Betty Q, Banker MD. Neuropathologic aspects of arthrogryposis multiplex congenita. *Clin Orthop and Relat Res* 1984;2:30–43.
- [19] Swart JJ. Congenital talipes equinovarus: an intrauterine paralysis. *J Bone Joint Surg Br* 2000;82(Suppl. II): 183–4.
- [20] Nadeem R, Brown J, Lawson G, Macnicol MF. Somatosensory evoked potentials as a mean of assessing neurological abnormality in congenital talipes equinovarus. *Dev Med Neurol* 2000;42:525–30.
- [21] Wicart P, Barthes X, Ghanem I, Seringe R. Clubfoot posteromedial release: advantages of tibialis anterior tendon lengthening. *J Pediatr Orthop* 2002;22:526–32.