

LETTER / *Cardiovascular imaging*

## Microsphere and coil embolisation of a mediastinal parathyroid adenoma

L. Tselikas<sup>a,\*</sup>, J.-Y. Pagny<sup>a</sup>, J. Joskin<sup>a</sup>, A. Palomera<sup>a</sup>,  
M. Ben Arfi<sup>a</sup>, M. Di Primio<sup>a</sup>, Y. Reznik<sup>b</sup>, M. Sapoval<sup>a</sup>

<sup>a</sup> Cardiovascular radiology department, Georges-Pompidou European Hospital, 25, rue Leblanc, 75015 Paris, France

<sup>b</sup> Endocrinology department, Caen University Hospital, avenue de la Côte-de-Nacre, 14033 Caen, France

### KEYWORDS

Parathyroid adenoma;  
Mediastinal;  
Embolisation;  
Microspheres;  
Coils

Parathyroid adenomas are the most common cause of primary hyperparathyroidism (around 90% of cases), and the main treatment is surgery. If surgery is unsuccessful or contraindicated, particularly for ectopic adenomas, there are alternatives such as medical treatment [1] (with cinacalcet) or, less commonly, percutaneous destruction of the gland by ultrasound-guided alcohol ablation [2] or by laser [3]. Endovascular ablation, which has been described from 1975 [4] to 2000, is now used less and less, although it is very effective and relatively low-risk.

### Case report

An 81-year old female was seen for management of a parathyroid adenoma located in the anterior mediastinum (retrosternal) that was discovered further to non-specific general signs (asthenia, diffuse bone pain, moderate renal failure, and polyuria and polydipsia), combined with hypercalcaemia. In addition, the main features of her medical history were dyslipidaemia, osteoporosis, gout, lumbar stenosis, a large umbilical hernia and a thyroidectomy with a parathyroidectomy for a multinodular goitre in early 2011. The pre-operative investigations found hypercalcaemia of 3.05 mmol/L (normal range of 2.2 to 2.6 mmol/L) with normal albumin levels, parathyroid hormone (PTH) of 230 ng/L (normal range of 10 to 65 ng/L), which was suggestive of primary hyperparathyroidism. In view of the hyperparathyroidism persisting after the parathyroidectomy, further imaging was carried out including a repeat ultrasound of the neck, Tc 99m-Sestamibi scintigraphy, and a computed tomography (CT) angiogram of the neck and chest to investigate aetiology.

\* Corresponding author.

E-mail address: [lambros.tselikas@gmail.com](mailto:lambros.tselikas@gmail.com) (L. Tselikas).

A retrosternal adenoma measuring 12 mm was demonstrated (both on scintigraphy and CT scan) (Figs. 1 and 2), probably vascularised by the branches of the right internal thoracic artery, which are difficult to visualise individually. Surgical management would require a sternotomy, which was contraindicated in this patient, and in view of her inability to tolerate cinacalcet (Mimpara®) due to gastrointestinal adverse effects, the decision was made to carry out selective endovascular embolisation of the adenoma.

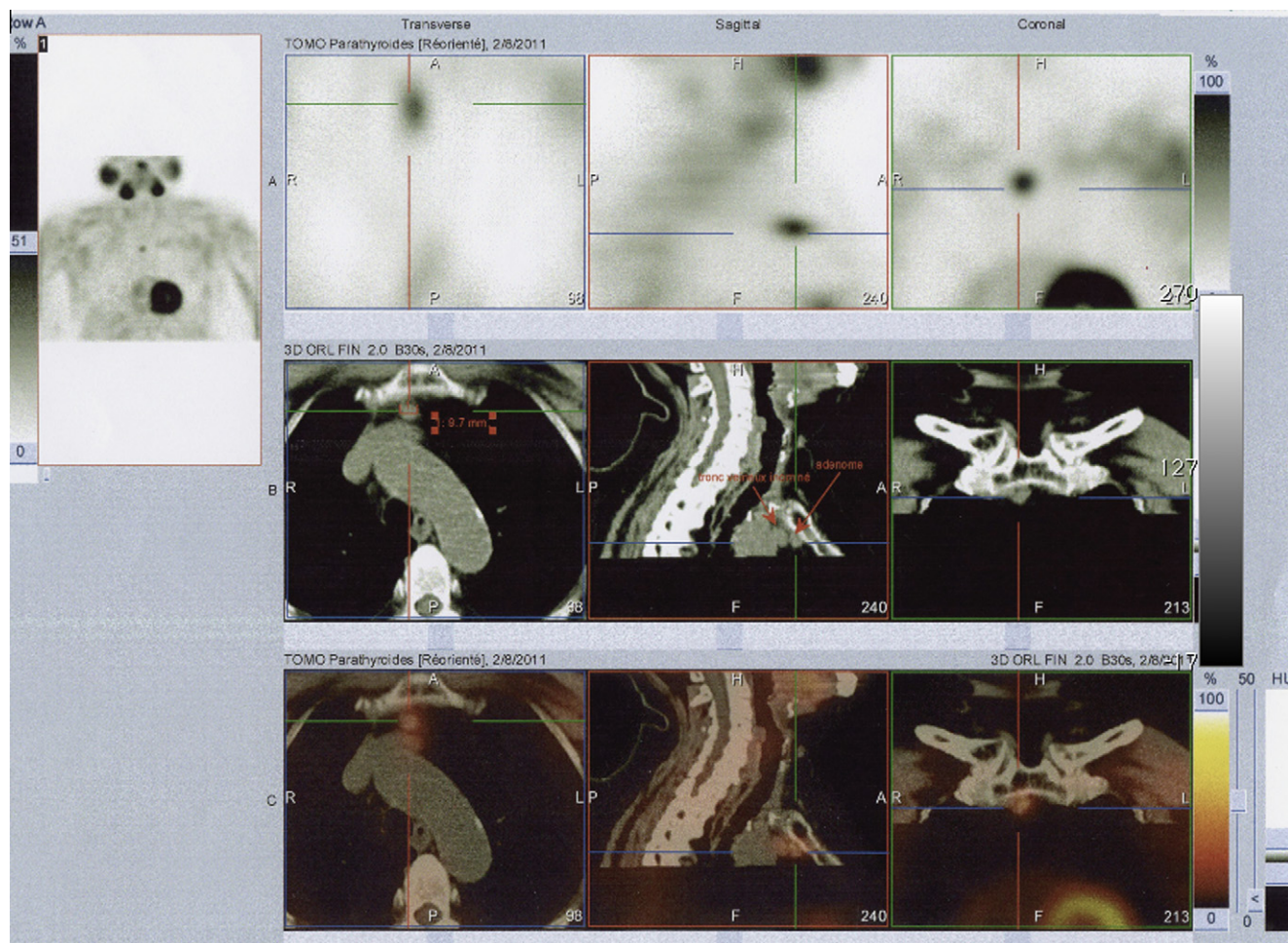
Access for the angiogram was obtained via the right femoral artery (5F catheter introducer), and after selective catheterisation of the right internal thoracic artery, it was confirmed that there was a hypervascular nodule in the same site as identified on the CT scan, vascularised by two branches of the right internal thoracic artery (Fig. 3).

Coils (Tornado®, Cook medical®) were used to embolise the right internal thoracic artery distal to the origin of the two arteries supplying the nodule in order to increase blood flow towards it, and to avoid a "blocked catheter" embolisation, at the risk of reflux, which could occur in the vertebrobasilar system. After selective catheterisation of the two feeding vessels using a microcatheter (Progreat® 2.7 mm, Terumo®), free-flow embolisation with 300-500 µm microspheres (Embospheres®, Biosphere Medical®) was carried out with care until occlusion was complete (Fig. 4).

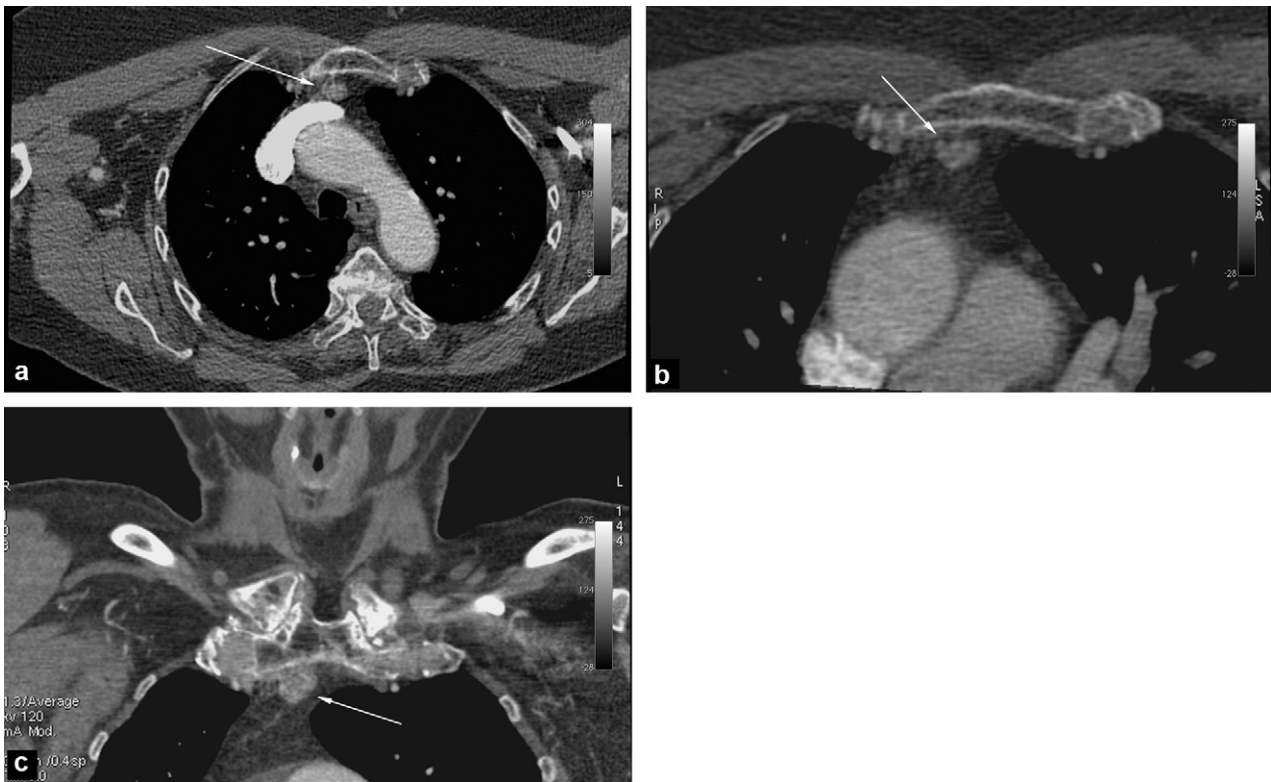
The embolisation was completed by coils being placed in the feeding vessels and in the internal thoracic artery opposite their origin, with the final repeat angiogram showing complete devascularisation of the retrosternal nodule (Fig. 5). On repeat investigations 4 hours post-procedure the patient's calcaemia had fallen to 2.76 mmol/L, and normal levels were re-established 24 hours after embolisation. PTH 1-84 also returned to normal levels (Fig. 6). Six months later, calcium and PTH levels had increased slightly, stabilising at 2.9 mmol/L and 130 ng/L, with the patient remaining asymptomatic.

## Discussion

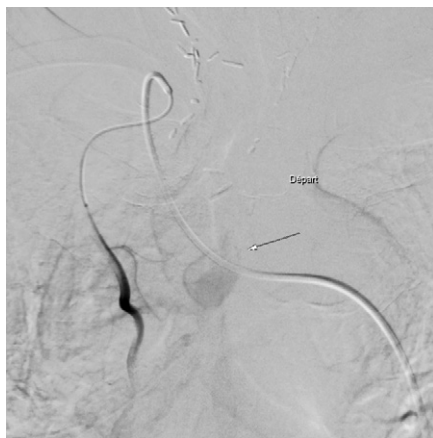Mediastinal parathyroid adenomas are relatively common (25% of ectopic adenomas [5]) especially in the sub-group of patients who have had a "clear" surgical exploration as part of the management of primary hyperparathyroidism. In young patients who have symptomatic hypercalcaemia and who are free from comorbid disease, surgery, which may go as far as a sternotomy, is a "reasonable" option. In older patients presenting contraindications to surgery, or in whom surgery is not clinically suitable, medical treatment with anti-parathyroid drugs (calcimimetics) is increasingly



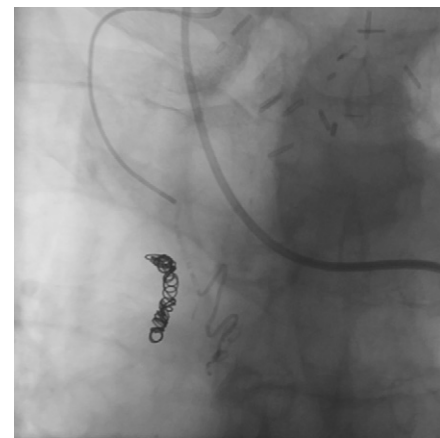
**Figure 1.** Tc99 SestaMIBI scintigraphy and SPECT showing high fixation localised to the anterior mediastinum.



**Figure 2.** Axial and coronal views on a computed tomography (CT) angiogram of the neck showing a retrosternal hypervascular nodule measuring 12 mm (white arrows).



**Figure 3.** Arteriography, after selective catheterisation of the right internal thoracic artery, showing a mid-thoracic hypervascular nodule (white arrow) vascularised by two branches of the right internal thoracic artery.



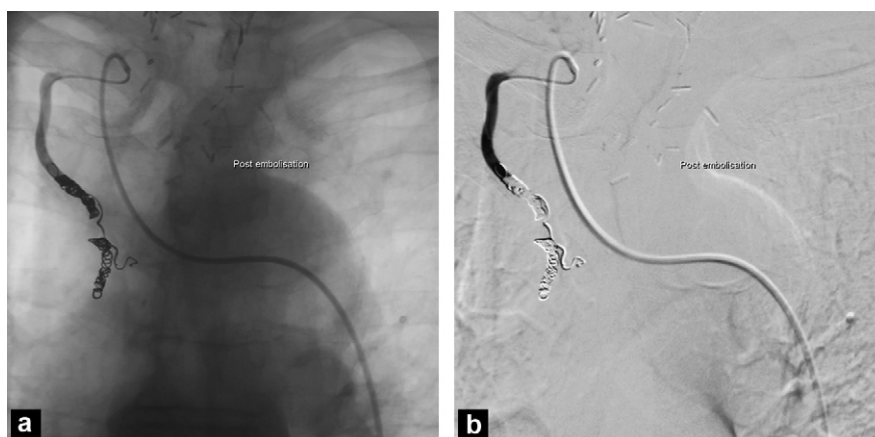
**Figure 4.** Arteriography, after the coils were placed in the right internal thoracic artery distal to the vessels supplying the mediastinal adenoma, during embolisation with 500 to 700  $\mu$ m microspheres.

used. However, endovascular ablation of an adenoma that is difficult to access with surgery or, as in this case report, in a patient who cannot tolerate cinacalcet, has been described through the 1970s and 1980s, mainly by medical teams in France [6,7] and the USA [8] with satisfactory long-term results. The equipment for embolisation consisted mainly of absolute ethanol or hyperosmolar ionic contrast agents. Today, with the progress in equipment for catheterisation (specific catheters, microcatheters, guidewires), in image acquisition (flat panel detector digital angiography,

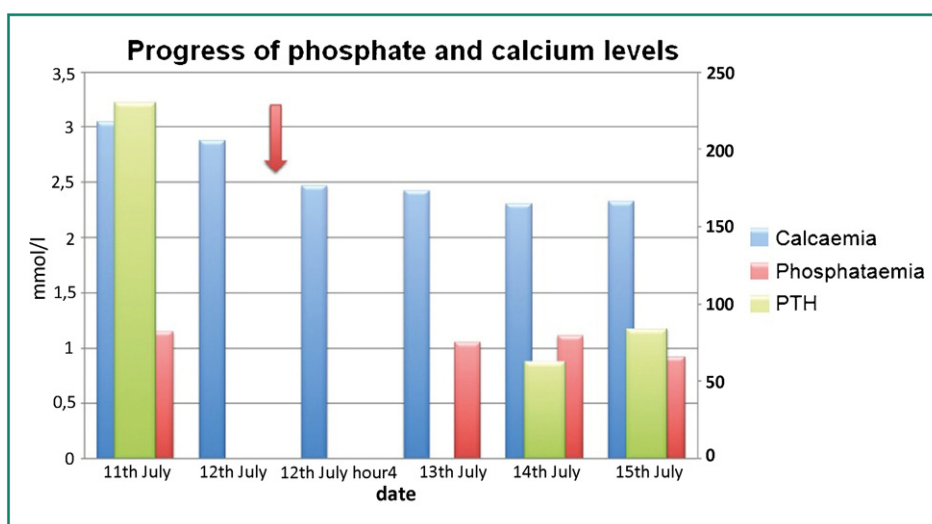
three-dimensional rotation acquisition), and in equipment for embolisation (microcoils, calibrated microspheres) the procedure has become easier and more reliable with fewer risks. Moreover, the quality of preoperative investigations using scintigraphy with  $^{99}\text{Tc}$ -MIBI, and possibly also a CT scan (single photon emission computed tomography [SPECT]), CT angiogram of the chest and neck, an ultrasound of the neck or, less commonly, MRI [9–11] enables the adenoma to be formally localised in the majority of cases.

In these cases, arteriography allows the vessels supplying the adenoma, which are not always visible on a CT scan, to





**Figure 5.** Arteriography, after the coils were placed in the right internal thoracic artery distal to the vessels supplying the mediastinal adenoma, and the post embolisation repeat imaging showing complete devascularisation of the nodule.



**Figure 6.** Table showing the progress of the patient's phosphate and calcium levels in the period immediately after embolisation, with calcium and PTH 1-84 levels returning to normal within 24 hours. The red arrow indicates embolisation.

be visualised, so that embolisation can be carried out. The risks are the same as those of an arterial puncture (with a 5F catheter introducer being placed in situ), and there is the risk of embolism during catheterisation and embolisation, although such cases still remain exceptional. Radiology to check effectiveness of the procedure is done immediately, while clinical checks and laboratory tests are carried out soon after, and phosphate and calcium levels usually normalise, in these cases, from day one.

## Conclusion

Embolisation of parathyroid adenomas requiring radical treatment may be an alternative to surgery and could be the treatment of choice in patients who are not candidates for surgery. With the progress that has been made in interventional radiology, and once the patient has undergone specific pre-treatment investigations, the procedure is reliable and may be useful in cases where a therapeutic impasse has been reached. This is the first case, to our knowledge, of

microsphere and coil embolisation and it provides an example of these kinds of circumstances.

## Disclosure of interest

The authors declare that they have no conflicts of interest concerning this article.

## References

- [1] Duntas LH, Stathatos N. Cinacalcet as alternative treatment for primary hyperparathyroidism: achievements and prospects. *Endocrine* 2011;39:199–204.
- [2] Veldman MW, Reading CC, Farrell MA, Mullan BP, Wermers RA, Grant CS, et al. Percutaneous parathyroid ethanol ablation in patients with multiple endocrine neoplasia type 1. *AJR Am J Roentgenol* 2008;191:1740–4.
- [3] Bennedbaek FN, Karstrup S, Hegedus L. Ultrasound-guided laser ablation of a parathyroid adenoma. *Br J Radiol* 2001;74:905–7.

- [4] Marx SJ, Doppman JL, Spiegel AM, Wolfe D, Aurbach GD. Embolization of a mediastinal parathyroid adenoma. *J Clin Endocrinol Metab* 1974;39:1110–4.
- [5] Powell AC, Alexander HR, Chang R, Marx SJ, Skarulis M, Pingpank JF, et al. Reoperation for parathyroid adenoma: a contemporary experience. *Surgery* 2009;146:1144–55.
- [6] Raynaud A, Guéris J, Bureau L, Seurot M, Cattan S, Gaux JC. A propos d'un cas d'adénome parathyroïdien médiastinal traité par embolisation. *Rev Med Interne* 1982;3:147–52.
- [7] Raynaud A, Gaux JC. L'embolisation des adénomes médiastinaux. Possibilité thérapeutique au cours de l'hyperparathyroïdie primaire. *Presse Med* 1984;13:2458.
- [8] Miller DL, Doppman JL, Chang R, Simmons JT, O'Leary TJ, Norton JA, et al. Angiographic ablation of parathyroid adenomas: lessons from a 10-year experience. *Radiology* 1987;165:601–7.
- [9] Ernst O. Hyperparathyroidism: CT and MR findings. *J Radiol* 2009;90:409–12.
- [10] Richard B. Primary hyperparathyroidism: ultrasonography and scintigraphy. *J Radiol* 2009;90:397–408.
- [11] Johnson NA, Carty SE, Tublin ME. Parathyroid imaging. *Radiol Clin North Am* 2011;49:489–509 [vi].