



REVISTA BRASILEIRA DE REUMATOLOGIA

www.reumatologia.com.br



Case report

Legionella pneumonia after infliximab in a patient with Rheumatoid Arthritis



Karina de Souza Giassi^a, Vilson Furlanetto Junior^a, Sonia Fialho^b,
Giovana Gomes Ribeiro^b, Ivânio Alves Pereira^{b,*}

^a Universidade Federal de Santa Catarina, Florianópolis, SC, Brazil

^b Rheumatology Center, Hospital Universitário Polydoro Ernani de São Thiago, Florianópolis, SC, Brazil

ARTICLE INFO

Article history:

Received 18 June 2012

Accepted 15 April 2013

Available online 20 August 2014

Keywords:

Legionella pneumophila

Tumour necrosis factor alpha

Rheumatoid arthritis

Infliximab

ABSTRACT

The antagonists of tumour necrosis factor (anti-TNF) have been successfully used in several chronic inflammatory diseases such as Rheumatoid Arthritis (RA), but some studies have observed the development of infections by intracellular pathogens in patients using anti-TNF. We report a case of a female patient with previous diagnosis of RA for 16 years that used several disease-modifying anti-rheumatic drugs (DMARDs) that resulted in treatment failure, and then was treated with infliximab. After fifteen days of the second dose, the patient developed ventilatory-dependent chest pain, dry cough and dyspnea. She was hospitalized, and the diagnosis of pneumonia by *Legionella pneumophila* was confirmed by the presence of *Legionella* antigen in an urine test. TNF is an inflammatory cytokine that also acts inhibiting the bacterial growth of intracellular pathogens, and its inhibition seems to increase susceptibility to these infections in some patients.

© 2014 Elsevier Editora Ltda. All rights reserved.

Pneumonia por *Legionella* após uso de Infliximabe em paciente com Artrite Reumatoide

RESUMO

Os antagonistas do fator de necrose tumoral (anti-TNF) têm sido utilizados com sucesso em várias doenças inflamatórias crônicas, como artrite reumatoide (AR), mas alguns estudos observaram a ocorrência de infecções por patógenos intracelulares em pacientes medicados com anti-TNF. Relatamos um caso de paciente mulher com diagnóstico prévio de AR durante 16 anos e que estava sendo medicada com várias drogas antirreumáticas modificadoras de doença (DARMDs), tendo como resultado o insucesso terapêutico, sendo em seguida tratada com infliximab. Depois de transcorridos 15 dias da segunda dose, a paciente foi acometida

Palavras-chave:

Legionella pneumophila

Fator alpha de necrose por tumor

Artrite reumatoide

Infliximabe

DOI of original article: <http://dx.doi.org/10.1016/j.rbr.2013.04.008>.

* Corresponding author.

E-mail: ivaniop@matrix.com.br (I.A. Pereira).

<http://dx.doi.org/10.1016/j.rbre.2013.04.006>

2255-5021/© 2014 Elsevier Editora Ltda. All rights reserved.

por dor torácica ventilatório-dependente, tosse seca e dispneia. Foi hospitalizada, e o diagnóstico de pneumonia por *Legionella pneumophila* foi confirmado pela presença do antígeno de *Legionella* na urina. TNF é uma citocina inflamatória que também promove inibição do crescimento bacteriano de patógenos intracelulares, e sua inibição parece aumentar a sensibilidade a essas infecções em alguns pacientes.

© 2014 Elsevier Editora Ltda. Todos os direitos reservados.

Introduction

Antagonists of tumor necrosis factor (anti-TNF) have shown significant changes in the course of a number of chronic inflammatory diseases, such as Crohn's disease, ankylosing spondylitis and RA.¹

The tumor necrosis factor- α (TNF- α) is a proinflammatory cytokine with multiple targets and interactions, but it has a well-established role in the pathogenesis of rheumatoid inflammation.

Besides this proinflammatory function in RA, TNF α also acts as a cellular defence mechanism against infections. Studies have observed that anti-TNF therapy may be related to increased risk of infections by intracellular pathogens, including *Mycobacterium tuberculosis*, *Legionella pneumophila*, *Listeria monocytogenes*, *Aspergillus fumigatus*, *Histoplasma capsulatum* and *Pneumocystis jirovecii*.

The evidence supporting this association between anti-TNF and increased risk of infections include case reports, epidemiological studies and experiments with animal models.²

We report a case of *Legionella* pneumonia in a patient with RA during the use of anti-TNF and discuss the main factors possibly involved in the genesis of this type of infection.

Case report

Female patient, 50 years-old, with a history of erosive RA and rheumatoid factor-positivity for 16 years. The patient made use of several disease-modifying antirheumatic drugs (DMARDs), including hydroxychloroquine, sulfasalazine, methotrexate (MTX), leflunomide, and combination therapy with MTX and 25 mg/week SC, and leflunomide 20 mg/day. After treatment failure and gastrointestinal intolerance to MTX, the patient began treatment with infliximab.

Based on that, we opted to introduce infliximab associated with leflunomide. On that occasion, the chest X-ray was normal, and PPD = 10 mm; isoniazid 300 mg/day was introduced as prevention against reactivation of latent tuberculosis.

Fifteen days after the second dose of infliximab, the patient developed fever, dry cough, ventilatory-dependent chest pain, and dyspnea. She was admitted at the hospital presenting hypoxemia and alveolar consolidations in the left hemithorax (Fig. 1A). The bronchoalveolar lavage fluid was negative for acid-fast bacilli and fungi, as well as for HIV. A diagnosis of legionellosis was confirmed by a positive search for *L. pneumophila* antigen in urine.

The patient experienced improvement after four weeks of combined use of a macrolide and a quinolone (Fig. 1B), remaining persistent activity (DAS28 > 5.1) despite the

combination of methotrexate and leflunomide used as therapeutic option. One year after the resolution of the infection, the patient restarted infliximab, and since then, has maintained clinical remission (DAS-28 < 2.6) without further infectious complications.

Discussion

Anti-TNF drugs act, in general, by blocking TNF- α . The use of these drugs has provided excellent results. Its effects range from symptomatic improvement in patients resistant to treatment with DMARDs to the interruption of progression of joint damage in RA.³

TNF is a cytokine with an important role in the defence against intracellular microorganisms. It is produced by monocytes and macrophages, stimulates nitric oxide production and induces differentiation of macrophages in epithelioid macrophages, which are necessary for the formation of granulomas. Macrophages and monocytes are also useful in the recognition and destruction of any macrophages, and monocytes are also useful in the recognition and destruction of any intracellular pathogen able or unable of forming granulomas. In addition, TNF is essential for maintaining the integrity of the granuloma.⁴ Granuloma formation is essential to counter infections and, thus, to prevent their spread. This becomes particularly important in infections with *Mycobacterium tuberculosis*.

L. pneumophila is a facultative intracellular bacterium that preferably invades and infects macrophages and monocytes. Studies in animal models have shown that the infection of macrophages by *L. pneumophila* induces the production of proinflammatory cytokines, such as TNF and IL-1, and that the addition of recombinant TNF to macrophages infected with *L. pneumophila* results in a significant resistance of these cells to bacterial growth.⁵ The mechanism by which TNF reduces the bacterial replication has not been fully clarified; some suggest that the cytokine acts synergistically with interferon-gamma synthesized by T lymphocytes in the inhibition of bacterial growth, aided by increased concentrations of nitric oxide and by the depletion of intracellular iron induced by TNF activity.⁶

In addition to these aforementioned mechanisms, TNF also appears to act mediating the induction of glutathione, a powerful antioxidant. In this way, TNF would minimize the effects of *L. pneumophila*- and hyperoxia-induced lung injury.⁷

After the introduction of anti-TNF in clinical practice, the appearance of opportunistic infections and infections by intracellular bacteria was observed. *In vitro* studies have concluded that cultured macrophages treated with TNF showed resistance to infection by *L. pneumophila*, but also noted that this resistance decreased after administration of anti-TNF in

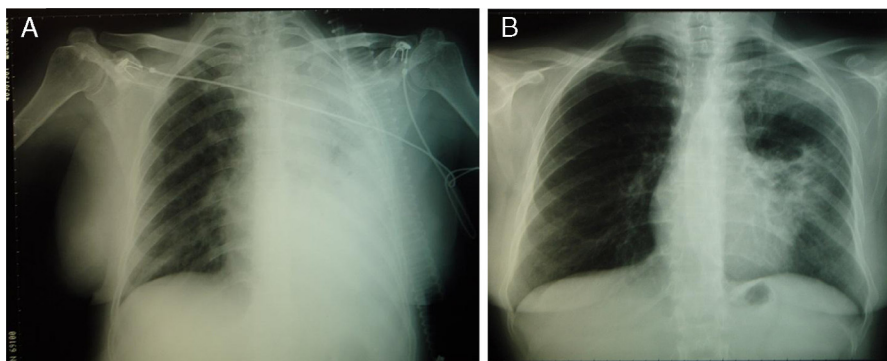


Figure 1 – A. Chest radiograph showing extensive consolidation into the left hemithorax. B. Chest radiograph after treatment with a macrolide and a quinolone (azithromycin and levofloxacin).

these cultures. In addition, animal models infected with *L. pneumophila* treated with anti-TNF exhibited persistent pneumonia, with greater numbers of infected macrophages and bacteria versus controls untreated with anti-TNF.⁸

Epidemiological studies suggesting an increased risk of opportunistic infections in general in patients treated with anti-TNF were published.^{9,10} Case reports and case series in the literature called the attention of physicians to the development of *L. pneumophila* infection in patients treated with anti-TNF. Tubach et al. estimated that the relative risk of infection by *L. pneumophila* in patients treated with anti-TNF is about 16.5 times greater than in the general population in France.¹¹

Most reports of *L. pneumophila* infection are associated with infliximab. The same pattern is confirmed when we refer to *M. tuberculosis* infection. Data from the Food and Drug Administration (FDA) show that the incidence of this infection may be 8 to 9 times greater in patients treated with infliximab versus etanercept.

The anti-TNF drugs mentioned have different mechanisms of action, which may partly explain the difference in the incidence of infections. Infliximab, by being a monoclonal antibody, forms more stable and irreversible bonds with the TNF bound to cell membrane. Etanercept, which behaves like a soluble TNF receptor, forms complexes less cytokine-avid.¹²

Therefore, physicians should be alert to the diagnosis of this disease in patients treated with anti-TNF. Despite the well established effectiveness and safety of these drugs, potentially serious side effects should be monitored.

Conflicts of interest

The authors declare no conflicts of interest.

REFERENCES

1. Ruiz AA, Pijoan JI, Ansuategui E, Urkaregi A, Calabozo M, Quintana A. Tumor necrosis factor alpha drugs in rheumatoid arthritis: systematic review and meta analysis of efficacy and safety. *BMC Musculoskelet Disord.* 2008;9:52.
2. Crum NF, Lederman ER, Wallace MR. Infections associated with tumor necrosis factor-alpha antagonists. *Medicine (Baltimore).* 2005;84:291-302.
3. Kolarz B, Targońska-Stepniak B, Darmochwał- Kolarz D, Majdan M. Autoimmune aspects of treatment with TNF-alpha inhibitors. *Postepy Hig Med Dosw.* 2007;61:478-84.
4. Gardam MA, Keystone EC, Menzies R, Manners S, Skamene E, Long R, et al. Anti-tumour necrosis factor agents and tuberculosis risk: mechanisms of action and clinical management. *Lancet Infect Dis.* 2003;3:148-55.
5. McHugh SL, Newton CA, Yamamoto Y, Klein TW, Friedman H. Tumor necrosis factor induces resistance of macrophages to *Legionella pneumophila* infection. *Proc Soc Exp Biol Med.* 2000;224:191-6.
6. Gobbi FL, Benucci M, Angela Del Rosso MD. Pneumonitis Caused by *Legionella pneumoniae* in a Patient With Rheumatoid Arthritis Treated With Anti-TNF- Therapy (Infliximab). *J Clin Rheumatol.* 2005;11:119-20.
7. Nara C, Tateda K, Matsumoto T, Ohara A, Miyazaki S, Standiford TJ. Legionella-induced acute lung injury in the setting of hyperoxia: protective role of tumour necrosis factor-alpha. *J Med Microbiol.* 2004;53:727-33.
8. Wondergem M, Voskuyl AE, Agtmael MA. A case of legionellosis during treatment with TNF α antagonist. *Scand J Infect Dis.* 2004;36:310-20.
9. Bongartz T, Sutton AJ, Sweeting MJ, Buchan I, Matteson EL, Montori V. Anti-TNF antibody therapy in rheumatoid arthritis and the risk of serious infections and malignancies. *JAMA.* 2006;295:2275-85.
10. Freitas DS, Machado N, Andrigueti FV, Reis Neto ET, Pinheiro MM. Hanseníase virchowiana associada ao uso de inibidor do fator de necrose tumoral α : relato de caso. *Rev Bras Reumatol.* 2010;50:333-9.
11. Tubach F, Ravaud P, Salmon-Céron D, Petitpain N, Brocq O, Grados F. Emergence of *Legionella pneumophila* pneumonia in patients receiving tumor necrosis factor-alpha antagonists. *Clin Infect Dis.* 2006;43:95-100.
12. Dinarello CA. Differences between anti-tumor necrosis factor- α monoclonal antibodies and soluble TNF receptors in host defense impairment. *Rheumatology.* 2005;32:40-7.