

Contents lists available at [ScienceDirect](http://www.sciencedirect.com)

American Journal of Ophthalmology Case Reports

journal homepage: <http://www.ajocasereports.com/>

Case report

Management of orbital emphysema secondary to rhegmatogenous retinal detachment repair with hyperbaric oxygen therapy



Dante L. Iniesta-Sanchez ^a, Fatima Romero-Caballero ^a, Adriana Aguirre-Alvarado ^b,
Victoria Rebollo-Hurtado ^c, Raul Velez-Montoya ^{d,*}

^a Ophthalmology Department, Hospital Central Militar, Army and Air Force University, México DF, Mexico

^b Critic Care Unit, Hospital Central Militar, Army and Air Force University, México DF, Mexico

^c Radiology Department, Hospital Central Militar, Army and Air Force University, México DF, Mexico

^d Retina Department, Asociación para Evitar la Ceguera en México "Hospital Dr. Luis Sánchez Bulnes" IAP, Mexico City, Mexico

ARTICLE INFO

Article history:

Received 17 December 2015

Received in revised form

23 February 2016

Accepted 17 March 2016

Available online 19 March 2016

Keywords:

Gas tamponade

Hyperbaric oxygen therapy

Subcutaneous emphysema

Compartment syndrome

Surgical complications

ABSTRACT

Purpose: To describe the case of orbital subcutaneous emphysema who was successfully treated with hyperbaric oxygen therapy.

Observations: Case report. Retrospective analysis of medical records and computer tomography images. A 40 years-old female, with retinal detachment who was seen at the emergency department, two weeks after undergoing a combined procedure of pars plana vitrectomy, scleral buckle and Sulfur hexafluoride tamponade. The patient complained of pain, decrease eye movement and edema of the upper eyelid. Clinical examination revealed periorbital crepitus. She was treated immediately with soft tissue decompression with small-gauge needle. Orbital emphysema recurred quickly, indicating possible gas trapped in the soft tissue. Using the US NAVY decompression protocol we were able to achieve fast clinical improvement. The protocol was repeated in several occasions until complete resolution.

Conclusion and importance: Hyperbaric oxygen therapy is an effective treatment for orbital and periorbital emphysema, due to its property of helping accelerate N₂ elimination from adipose tissue.

© 2016 The Authors. Published by Elsevier Inc. This is an open access article under the CC BY-NC-ND license (<http://creativecommons.org/licenses/by-nc-nd/4.0/>).

1. Introduction

The introduction of gas tamponade in vitreoretinal surgery is without a doubt one of the most important contributions to the retina specialist's surgical armamentarium [1,2]. The primary purpose of using gas in retinal detachment surgery is to take advantage of the surface tension created on the bubble's walls after being placed on a fluid-filled cavity; which produce an internal physical blockage of the retinal tear, preventing fluid from gaining access to the subretinal space. In addition, it creates a buoyant force which helps displacing the retina gently toward the retinal pigment epithelium [1,2].

Sulfur hexafluoride (SF₆) is one the most widely used gas tamponade worldwide. It is a colorless, odorless and nontoxic gas; is five times heavier than atmospheric air and has a molecular weight of 146 g/mol. Although it is chemically inert, it can expand 2 times its original volume when used 100% pure into the vitreous cavity. It has a non-expansile concentration of 18%, a half-life of 2.5 days and a total lifespan of about 15 days [1,3,4].

As with other surgical devices, the use of SF₆ tamponade has potential adverse effects; being orbital subcutaneous emphysema (OSE) one of them. It is characterized by the abnormal presence of gas bubbles within the orbital and periorbital tissue [5]. Even though most of the times is self-limited and has a benign clinical course with spontaneous resolution in about 2 weeks; there are more severe forms in where the build-up pressure within tissue can cause a localized compartment syndrome with tissue destruction, central retinal artery occlusion and irreversible vision loss if not immediately decompresses [6–8].

Hyperbaric oxygen therapy (HOT), as defined by the Undersea and Hyperbaric Medical Society (UHMS), is a therapeutic intervention in which the patient breathes almost 100% oxygen

* Corresponding author. Vicente García Torres #46, Col: San Lucas Coyoacán, México city, Mexico.

E-mail addresses: pieam@hotmail.com (D.L. Iniesta-Sanchez), famaloroca@hotmail.com (F. Romero-Caballero), dra.adriaguirre@gmail.com (A. Aguirre-Alvarado), victoriarhmd@hotmail.com (V. Rebollo-Hurtado), rvelezmx@yahoo.com (R. Velez-Montoya).

intermittently, inside a specially-designed chamber which is pressurized above atmospheric pressure, usually above 1.4 ATA (absolute atmospheres) [9]. The basic therapeutic principle of HOT in OSE lies in increasing the oxygen partial pressure within tissue (ischemia relief), which then increases the blood's oxygen carrying capacity, leading to a decrease in circulating nitrogen. Low nitrogen in tissue and blood stream leads to bubble shrinkage due to an increase in the diffusion gradient of nitrogen from the gas bubble toward the blood, decreasing the pressure within the orbit [9–11].

In the following case we will describe the use of HOT for the first time in the treatment of OSE secondary to retinal detachment surgery. A comprehensive analysis of the follow-up and clinical outcomes will be done as well as a concise discussion about the possible future application of HOT.

2. Case report

The following case report description was approved by the local institutional review board. Before all medical procedures described herein, a comprehensive explanation, including the risk of doing nothing, was conducted with the patient. The patient read and signed individual consent forms for each procedure; including consent for publication of personal information like medical records details and photographs.

A 40 years of age Mexican-mestizo female, with previous medical history of congenital cataract, extracapsular cataract extraction in OD and secondary glaucoma, currently treated with hypotensive drops; was seen as an outpatient, complaining of significant inferior visual field loss in the right eye since one week ago. At presentation she had 20/70 vision in OU and lateral nystagmus. Slit lamp examination was unremarkable. Fundus examination revealed a superotemporal macula-on retinal detachment with an evident retinal tear at 11 o'clock. The patient underwent an immediate combined scleral buckle- 23 gauge pars plana vitrectomy procedure with 18% SF6 as tamponade agent under general anesthesia. The platform of choice was an Accurus equipment (Alcon Lab, Froth worth Texas, US). The 23 gauge non-valved trocars were inserted in a two-step motion. The blade's design was the EDGE-PLUS[®], which constructs more linear wounds. The core vitrectomy, vitreous base dissection and air-fluid interchange were uneventful. Gas was drawn from prediluted syringe, prepared by allied personnel, few minutes before its use. The syringe is filled using a silicon tube attached to a millipore filter, which in turn is connected to the gas container, provided by the gas' manufacturer. The syringe is filled with 100% pure gas and it is later diluted with room air, in the presence of the surgeon. Although the surgeon did not participate in the dilution process at this time, he supervised the procedure at all time.

Two days post-op, she was seen at the emergency department complaining of pain and further visual loss in OD. Her vision was hand motion and intraocular pressure was 36 mmHg. Slit lamp examination showed superior and inferior eyelid edema, +3 chemosis and corneal epithelial edema. Fundus examination showed an attached retina with a patent retinal artery and gas filling the vitreous cavity 100%. We decided to perform an anterior chamber paracentesis and discharged the patient with topical hypotensive, antibiotics and steroids drops.

Five days later (postsurgical day 7), she returned to our office complaining of severe ocular and periorbital pain and periorbital "puffiness" (Fig. 1). Her vision remained hand motion. At this time, her examination was remarkable for severe eyelid edema, complete ptosis, mild proptosis, partial ophthalmoplegia and +4 chemosis.

Orbital cellulitis was suspected and therapy with empiric intravenous antibiotics was started.

One week later (postsurgical day 14), the eyelid edema increased and palpebral and periorbital crepitus was noted. Urgent CT scan was performed using 1 mm slices with a soft tissue and bone algorithm (Fig. 2). The study showed large amounts of gas (palpebral, subconjunctival, retrobulbar and compressing the optic nerve and causing exophthalmus) in the orbit and in anterior chamber. There were no evidence of gas in the vitreous cavity, however, the retina remained attached.

Surgical decompression with fine needle insertion and aspiration along with scleral buckle removal was done immediately. No gas leakage was detected at this time. After surgery, the patient recover partially, regaining ocular motility and less proptosis (Fig. 3). However, gas started collecting again in the retrobulbar and orbital space; requiring several more decompressions with fine needle aspiration (x6) and even a gas-fluid exchange. Every time with partial recovery and relapse shortly after. Without a clear gas origin and since it seemed to be trapped in the soft tissue; we decided to enhance its elimination by using HOT. Using the USNAVY decompression protocol, we started therapy 39 days after the first surgery. HOT profile was 3.0 ATA for 300 minutes with 2 five-minute air breaks at 30 minutes intervals, divided in ten sessions (one per day). Clinical improvement was fast and significant with almost total resolution of proptosis and control of intraocular pressure (Fig. 4). The HOT protocol was repeated as soon as gas start collecting again in the retrobulbar and orbital space on CT scans; or if the patient referred recurrence of the clinical symptoms; twenty five additional sessions with the same protocol was needed (35 sessions total). Four months after initial surgery she had total resolution of the symptoms and 20/60 of visual capacity. Although control CT scan still showed 1–1.5 cc of intraconal gas. Eighteen months later, the patient is 20/60, has an attached retina and total resolution of the orbital emphysema (Fig. 5).

3. Discussion

The kinetic of gas tamponade is complex and has three phases: bubble expansion (driven by nitrogen [N₂]), equilibrium of nitrogen concentration and bubble clearance [1]. About 10% of the gas bubble is made of carbon dioxide and oxygen; which remain at constant concentration at all time. The volume of the bubble gradually decreases as all the gases are absorbed at the same rate. Because the longest-acting gas is the slowest to being absorbed, it controls the rate of bubble clearance in the final stage [2,3]. Additionally, the half-life of the gas bubble is influenced also by other factor like the volume of gas injected and concentration, its molecular weight, diffusion coefficient, water solubility, the intraocular pressure, the posterior choroid venous concentration of the gas and the vascular perfusion rate of the choroid [2,10].

According to a basic principle described by John Scott Haldane in the early 1900s, gas saturation rate varies depending of the tissue and that N₂ is 4.5 times more soluble in fat than in water. This means that if fat and water are exposed to the same concentration of N₂, the gas will dissolve into both compartments at the same rate but it will take 4.5 times longer for the N₂ in the fat to equilibrate concentration with the surrounding gas and when it does, the fat will contain 4.5 times more N₂ than the surrounding water [12]. Since most of the tissue in human body has a solubility for N₂ similar to water except for fat; the absorption of nitrogen/inert gas by tissues is determined by the cardiac output. However, it will vary according to the tissue's specific blood flow and its fat content. Usually, adipose tissue has an extremely limited blood flow,

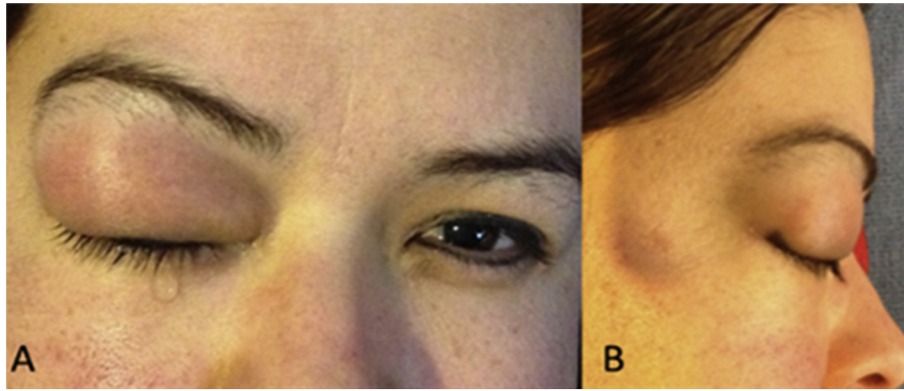


Fig. 1. One week after combine procedure of vitrectomy and scleral buckle; frontal view (A) and lateral view (B). The picture from the outpatient department shows edema of the superior eyelid and mild redness of the skin, painful to the touch. Bacterial orbital cellulitis was suspected at that time.

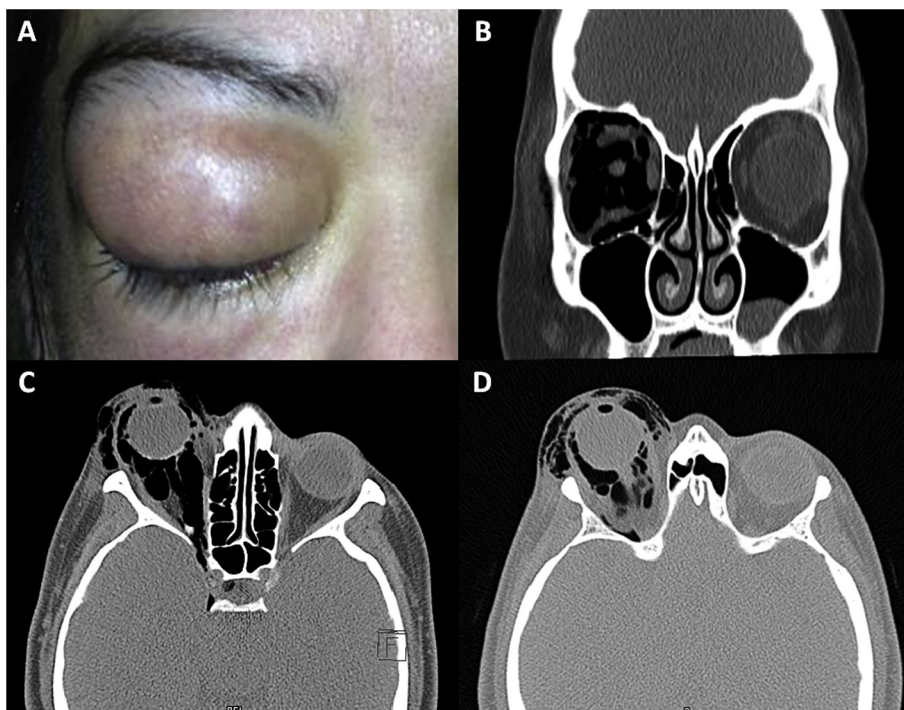


Fig. 2. A: Clinical photograph, frontal view; taken at the emergency department at postsurgical day 14. The patient referred an increase in pain, upper eyelid volume and crepitus. B to D: CT scan of the same day. B shows a bone window, coronal section of the skull; it shows massive amount of gas, surrounding the optic nerve and extraocular muscles. C & D: soft tissue window, axial sections at two different levels; the images shows gas contained in the upper eyelid, retrobulbar space and anterior chamber.

therefore N_2 rises very slowly on fat, it serves as storage and takes a very long time to eliminate the absorbed N_2 [12,13].

Although the reason of gas expansion and accumulation in orbital and periorbital adipose tissue in our case is unknown; one possibility is that instead of SF_6 , a mixture of 18% octafluoropropane (C_3F_8) was used. At that dilution, the gas gradually expanded eventually leaking through sclerotomies as microbubbles toward the periorbital and intraconal space. Where due to the presence of orbital fat and slow metabolism of N_2 ; the gas coming from the vitreous cavity accumulates in great amount without reabsorption. This would explain the constant recurrences of gas despite repeatedly decompressions with fine needle aspiration and the later success of HOT. Despite there is no prior experience regarding treatment of subcutaneous emphysema with HOT; we observed that the behavior of the gas was similar than in decompression

sickness. Therefore, using USANAVY decompression protocol was logic and justified.

4. Conclusion

The use of gas as tamponade agent in vitreoretinal surgery has been extensively studied. Although the gas dynamics, expansion properties, diffusion and resorption in the vitreous cavity is very well known; a different behavior can be expected if the gas gains access to the periorbital space, mainly due to presence of adipose tissue and a slow N_2 metabolism. Sutureless sclerotomies may be the escape route of gas. A key step of the surgery is ensuring that the proper gas and proper dilution is going to be used. Despite the fact that there are some previous reports of orbital emphysema secondary to intraocular gas tamponade, the current report

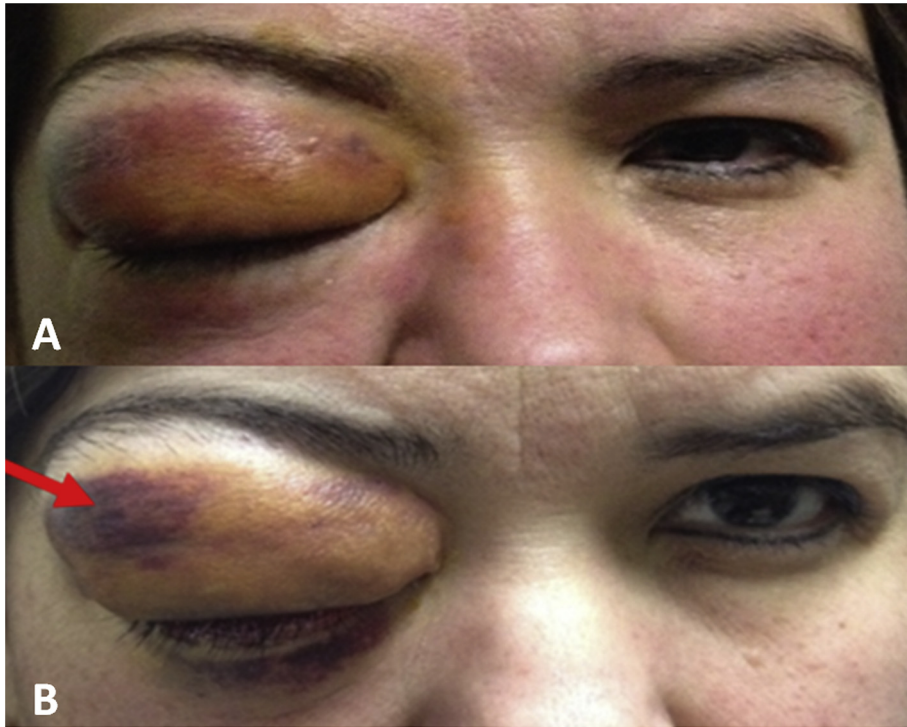


Fig. 3. Upper image (A) was taken after first needle decompression. The patient improved mildly. Few days later, gas began collecting again and more decompression were performed (B). Red arrow indicates the site of repeated needle decompressions.

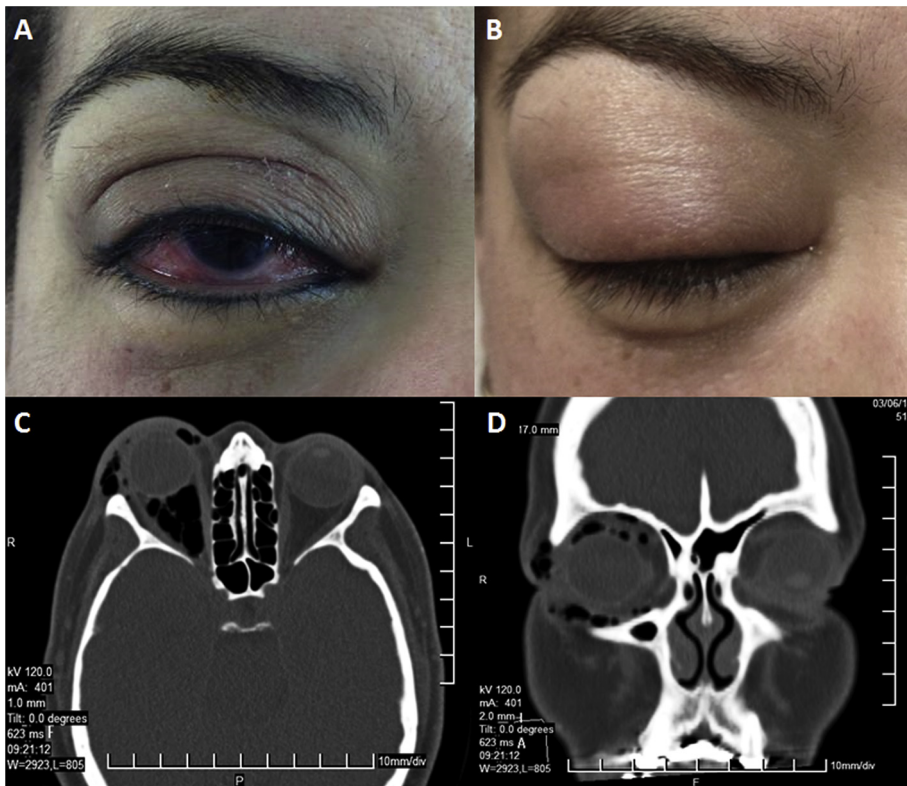


Fig. 4. A: Clinical photograph, frontal view, taken 24hrs after the first hyperbaric treatment. An important decrease in eyelid emphysema can be seen. The patient showed a better eyelid opening, with less pain and better eye movements. B: 24 h later, the gas started collecting again quickly. C & D: Axial and coronal sections, soft tissue window; obtained after hyperbaric treatment. The scans shows less amount of gas, although complete resolution was achieve after several hyperbaric sessions.

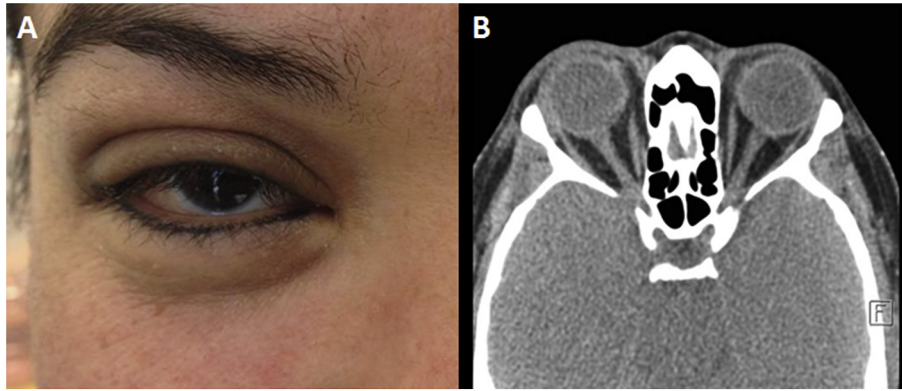


Fig. 5. Clinical photograph, frontal view (A) and axial CT scan (B), taken at the patient's last office visit (18 months after surgery). The vision was 20/60, full range of ocular movements, good eyelid opening and no evidence of intraorbital gas.

describe a case of greater severity that did not respond to traditional management. The successful use of HOT was because it helped to accelerate N_2 elimination from adipose tissue, leading to a shrinkage of the gas bubble contained in the periocular space, avoiding further irreversible lesion to structures like the optic nerve.

References

- [1] S. Rizzo, F. Barca, Vitreous substitute and tamponade substances for microincision vitreoretinal surgery, *Dev. Ophthalmol.* 54 (2014) 92–101.
- [2] M.G. Krzystolik, D.J. D'Amico, Complications of intraocular tamponade: silicone oil versus intraocular gas, *Int. Ophthalmol. Clin.* 40 (2000) 187–200.
- [3] H. Lincoff, J. Mardirossian, A. Lincoff, P. Liggett, T. Iwamoto, F. Jakobiec, Intravitreal longevity of three perfluorocarbon gases, *Archives Ophthalmol.* 98 (1980) 1610–1611.
- [4] G.W. Abrams, D.E. Swanson, W.I. Sabates, A.I. Goldman, The results of sulfur hexafluoride gas in vitreous surgery, *Am. J. Ophthalmol.* 94 (1982) 165–171.
- [5] P.M. Jacobs, J.M. Twomey, P.K. Leaver, Behaviour of intraocular gases, *Eye* 2 (Pt 6) (1988) 660–663.
- [6] S.L. Lee, D.M. Mills, D.R. Meyer, S.M. Silver, Orbital emphysema, *Ophthalmology* 113 (2113) (2006) e1–2.
- [7] P. Tomasetti, C. Jacobsen, T. Gander, W. Zemmann, Emergency decompression of tension retrobulbar emphysema secondary to orbital floor fracture, *J. Surg. Case Rep.* 2013 (3) (2013 Mar 21).
- [8] E.F. Damasceno, N. Damasceno, S. Horowitz, M.M. Rodrigues, Emphysema following vitrectomy with fluid-gas exchange: description of a rare complication, *Clin. Ophthalmol.* 8 (2014) 401–403.
- [9] J. Shah, Hyperbaric oxygen therapy, *J. Am. Coll. Certif. Wound Specialists* 2 (2010) 9–13.
- [10] H. Oguz, G. Sobaci, The use of hyperbaric oxygen therapy in ophthalmology, *Surv. Ophthalmol.* 53 (2008) 112–120.
- [11] G. Gabb, E.D. Robin, Hyperbaric oxygen. A therapy in search of diseases, *Chest* 92 (1987) 1074–1082.
- [12] A.M. Bakken, M. Farstad, H. Holmsen, Fatty acids in human platelets and plasma. Fish oils decrease sensitivity toward N_2 microbubbles, *J. Appl. physiology* 70 (1991) 2669–2672.
- [13] N. Malkevich, R.M. McCarron, R.T. Mahon, Decompression from saturation using oxygen: its effect on DCS and RNA in large swine, *Aviat. space, Environ. Med.* 81 (2010) 15–21.