

CASE REPORT

Acquired acanthosis nigricans with tripe palms in a patient with interstitial lung disease

Melissa J. Danesh, BS,^a Drew K. Saylor, MD,^a Lorriana E. Leard, MD,^b
Jeffrey P. North, MD,^a and Lindy P. Fox, MD^a
San Francisco, California

Key words: interstitial lung disease; malignancy; malignant acanthosis nigricans; nonspecific interstitial pneumonia; paraneoplastic syndrome; tripe palms.

INTRODUCTION

Tripe palms (TP); acral acanthosis nigricans (AN), is a rare cutaneous syndrome in which the palms develop velvety thickening and rugosity that creates an exaggeration or distortion of dermatoglyphics, resembling boiled tripe. In more than 90% of patients, TP is associated with malignancy, predominantly pulmonary and gastric carcinomas.¹ However, in approximately 6% to 10% of patients with TP, no associated malignancy is found.¹ We report a case of TP associated only with interstitial lung disease (ILD), specifically idiopathic nonspecific interstitial pneumonia (NSIP), and no associated malignancy.

CASE REPORT

A 43-year-old man presented with a 2-year history of worsening dyspnea. The radiographic pattern on chest computed tomography was most suggestive of NSIP. The finding of NSIP in a 43-year-old man strongly suggested an underlying connective tissue disease (CTD) or autoimmune process. Joint examination and an extensive serologic evaluation for CTD were negative for a specific CTD, and thus, an idiopathic autoimmune etiology was favored as the etiology for his NSIP. He was treated with a 6-month course of prednisone (maximum dose of 40 mg daily) but had progressive worsening of his ILD and was referred to our center for lung transplant evaluation. Over this same period he was noted to have asymptomatic and gradually progressive thickening of his bilateral palmar skin, which

Abbreviations used:

AN:	acanthosis nigricans
CTD:	connective tissue disease
ILD:	interstitial lung disease
NSIP:	nonspecific interstitial pneumonia
TP:	tripe palms

correlated with progression of his ILD and continued to worsen despite oral prednisone.

Examination found rugose thickening and brownish-yellow hyperpigmentation with enhanced dermatoglyphics on the bilateral palms and plantar feet (Fig 1), symmetric tan velvety hyperpigmented plaques on the bilateral neck folds, and digital clubbing. Skin biopsies of the palms and neck folds showed papillomatosis of the epidermis, hyperkeratosis, and thin suprapapillary plates, consistent with the clinical diagnoses of TP and AN (Fig 2).

The concomitant findings of TP and AN suggested a cutaneous paraneoplastic syndrome and prompted an extensive malignancy workup with whole-body positron emission tomography-computed tomography and virtual colonoscopy, all without evidence of malignancy. Barium swallow and sputum cytology findings were normal. Laboratory findings were nonspecific with elevated serum erythrocyte sedimentation rate (59 mm/h; normal, <15 mm/h), carcinoembryonic antigen level (9 ng/mL; normal, <5 ng/mL), and carbohydrate antigen 19-9 level (256 U/mL; normal, 0–37 U/mL). He was started on mycophenolate mofetil for his ILD, and slight improvement in his palmar thickening was observed.

From the Departments of Dermatology^a and Pulmonary, Critical Care, Allergy, and Sleep Medicine,^b University of California, San Francisco.

Funding sources: None.

Conflicts of interest: None declared.

Correspondence to: Drew K. Saylor, MD, Department of Dermatology, University of California, San Francisco, 1701 Divisadero St #3, San Francisco, CA 94115. E-mail: Drew.Saylor@ucsf.edu.

JAAD Case Reports 2016;2:59-62.

2352-5126

© 2015 by the American Academy of Dermatology, Inc. Published by Elsevier, Inc. This is an open access article under the CC BY-NC-ND license (<http://creativecommons.org/licenses/by-nc-nd/4.0/>).

<http://dx.doi.org/10.1016/j.jidcr.2015.11.008>

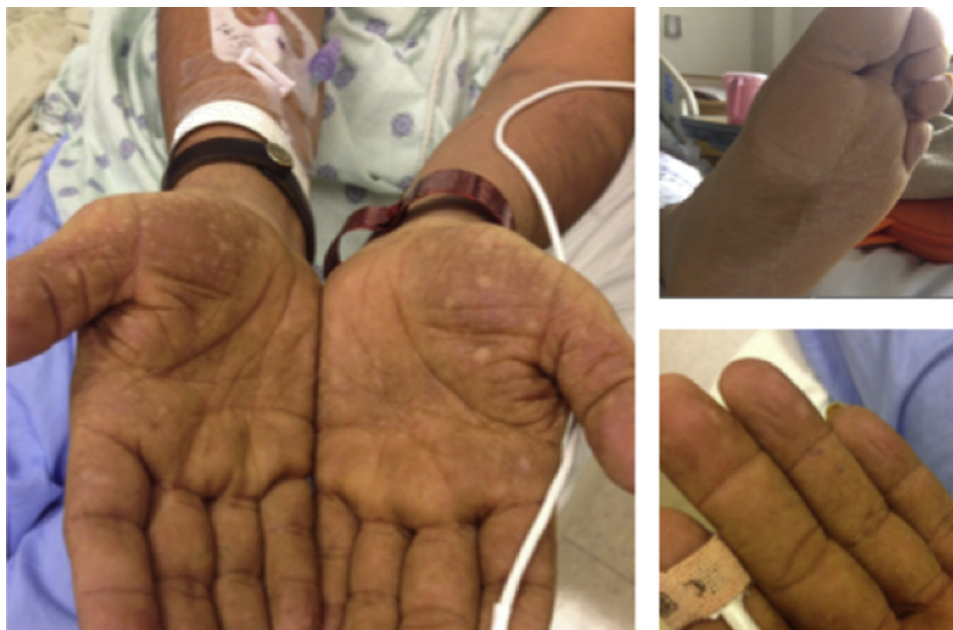

Fig 1. Initial physical examination. Bilateral palms and plantar feet show significant rugose thickening and brownish-yellow hyperpigmentation.

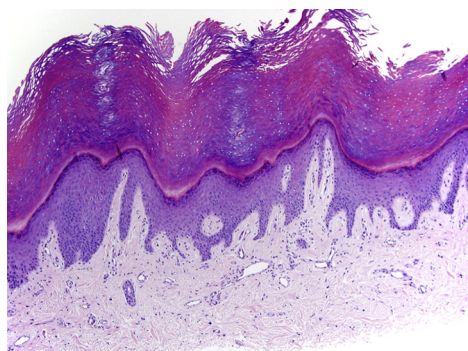


Fig 2. Palmar biopsy specimen shows hyperkeratosis and papillomatosis with thin suprapapillary plates. (Hematoxylin-eosin stain; original magnification: $\times 100$.)

Because evaluation for malignancy was negative, the patient underwent lung transplantation. At the time of transplantation, frozen sections of lung tissue and lymph nodes sent for pathologic review were negative for malignancy, with the final explanted lung specimen having fibrosing NSIP with superimposed organizing diffuse alveolar damage. Follow-up surveillance more than 6 months after transplant shows no evidence of malignancy. Marked decrease in skin thickness of both palms and improvement in the digital clubbing has been observed after transplant (Fig 3) while on an immunosuppressive regimen of prednisone, mycophenolate mofetil, and tacrolimus.

DISCUSSION

TP is associated with malignancy in greater than 90% of cases.^{1,2} Although this correlation holds true even when TP is found in isolation, its 77% rate of co-occurrence with malignant AN suggests that TP may represent a variant of malignant AN.^{3,4} When AN and TP are found together, an association with gastrointestinal malignancy is most common.⁵ When found in isolation or with clubbing of the digits, TP is most commonly associated with lung cancer.⁵ Our patient had TP with both AN and digital clubbing, creating a high suspicion for gastric or pulmonary malignancy. Given his known ILD, his skin findings raised the question of whether there was one diagnosis that could explain both issues, such as a co-occurrence of a pulmonary malignancy with ILD that remained hidden on imaging because of the extensive fibrosis, a pulmonary malignancy presenting as ILD, or a coincidental undetected gastric malignancy. Despite an extensive search that included histopathologic examination of both explanted lungs, no malignancy could be identified.

The absence of malignancy prompted a review for rarer potential nonmalignant causes of TP, such as bullous pemphigoid, benign hepatic neoplasia, systemic mastocytosis, psoriasis, and exfoliative dermatitis.^{2,6} None of these conditions were found; instead, there was a parallel course with TP and ILD alone. Specifically, his palmar thickening correlated with the onset of ILD, and these were progressive together over the same period, even while on

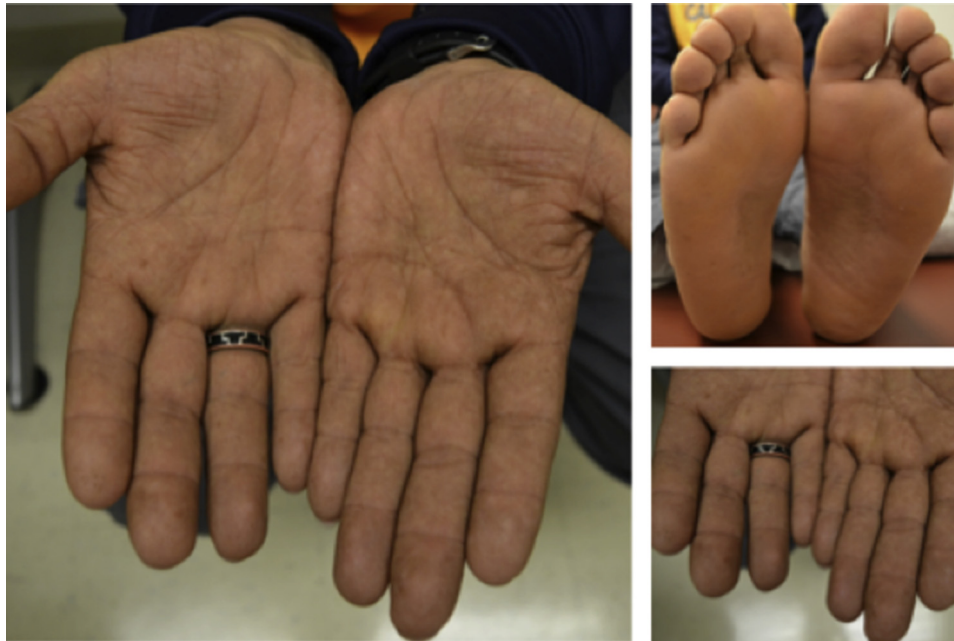

Fig 3. Decreased thickening and rugosity of bilateral palms and feet after immunosuppressive therapy and pulmonary transplant.

prednisone. Furthermore, within weeks of treatment with mycophenolate mofetil and lung transplantation, there was marked improvement in both the rough texture and thickness of his palms.

The concurrent progression and resolution of the patient's ILD and TP strongly suggests that the pathophysiology of each of these conditions is linked. One hypothesis is that an underlying autoimmune process resulted in the development of both ILD and TP in our patient. One case described an association between diffuse AN and an autoimmunity (Sjogren's syndrome and systemic lupus erythematosus—like features) in which the AN responded to immunosuppressive therapy.⁷ The authors speculated that other yet-to-be-identified antibodies (ie, other than insulin receptor antibodies) may cause cutaneous findings similar to those seen in patients with insulin resistance (ie, AN).⁷

Alternatively, ILD-associated growth factors implicated in clubbing may contribute to the development of TP. Although TP in the context of malignancy has been attributed to the secretion of epidermal growth factor by tumor cells,⁸ its pathogenesis in the absence of malignancy has yet to be elucidated. Perhaps platelet-derived growth factor, which is increased in ILD,⁹ produces cutaneous effects comparable to those of epidermal growth factor.¹⁰

The strong association between TP and malignancy prompts an appropriately extensive workup but also has other implications, such as potential

preclusion from organ transplantation. Our report adds to the small literature on nonmalignant TP. It is important to document these rare cases, as recognizing nonmalignant TP is essential to appropriate decision making in complex clinical scenarios and evokes alternative pathophysiologic mechanisms of disease.

REFERENCES

1. Clarke J. Malignant acanthosis nigricans. *Clin Exp Dermatol.* 1977;2(2):167-170.
2. Ben Hmida M, Zarea I, Mrabet D, et al. Tripe Palms, digital clubbing and Jaccoud's-type arthropathy: a quiz. Pachydermatoglyphy in an apparently cancer-free smoker. *Acta Derm Venereol.* 2011;91(3):380, 384.
3. Stawczyk-Macieja M, Szczerkowska-Dobosz A, Nowicki R, Majewska H, Dubowik M, Sokolowska-Wojdylo M. Malignant acanthosis nigricans, florid cutaneous papillomatosis and tripe palms syndrome associated with gastric adenocarcinoma. *Postepy Dermatol Alergol.* 2014;31(1):56-58.
4. Cohen PR, Grossman ME, Almeida L, Kurzrock R. Tripe palms and malignancy. *J Clin Oncol.* 1989;7(5):669-678.
5. Cohen PR, Kurzrock R. Malignancy-associated tripe palms. *J Am Acad Dermatol.* 1992;27(2 Pt 1):271-272.
6. Breathnach SM, Wells GC. Acanthosis palmaris: tripe palms. A distinctive pattern of palmar keratoderma frequently associated with internal malignancy. *Clin Exp Dermatol.* 1980; 5(2):181-189.
7. Kondo Y, Umegaki N, Terao M, Murota H, Kimura T, Katayama I. A case of generalized acanthosis nigricans with positive lupus erythematosus-related autoantibodies and antimicrosomal antibody: autoimmune acanthosis nigricans? *Case Rep Dermatol.* 2012;4(1):85-91.
8. Douglas F, McHenry PM, Dagg JH, MacBeth FM, Morley WN. Elevated levels of epidermal growth factor in a patient with tripe palms. *Br J Dermatol.* 1994;130(5):686-687.

9. Spicknall KE, Zirwas MJ, English III JC. Clubbing: An update on diagnosis, differential diagnosis, pathophysiology, and clinical relevance. *J Am Acad Dermatol*. 2005; 52(6):1020-1028.
10. Cooper JA, Bowen-Pope DF, Raines E, Ross R, Hunter T. Similar effects of platelet-derived growth factor and epidermal growth factor on the phosphorylation of tyrosine in cellular proteins. *Cell*. 1982;31(1):263-273.