



## Original research

# Post-pneumonectomy broncho-pleural fistula successfully closed by open-window thoracostomy associated with V.A.C. therapy



Paolo Laperuta, Filomena Napolitano, Alessandro Vatrella, Rosa Maria Di Crescenzo, Antonio Cortese, Vincenzo Di Crescenzo\*

Department of Medicine and Surgery, Unit of Maxillofacial Surgery, University of Salerno, Salerno, Italy

## ARTICLE INFO

## Article history:

Received 15 May 2014

Accepted 15 June 2014

Available online 23 August 2014

## Keywords:

Post-pneumonectomy broncho-pleural fistula

Open-window thoracostomy

Vacuum assisted closure therapy

## ABSTRACT

Broncho-pleural fistula (BPF), is a dramatic complication that may occur after lung resection. The treatment is challenging due to its high rate of morbidity and mortality. Herein, a case of BPF associated with empyema, occurred in an elderly patient who had undergone to left pneumonectomy for non-small cell lung cancer (NSCLC), is reported. After various treatments including chest drainage and endoscopic procedures, BPF was successfully closed by open-window thoracotomy associated with vacuum assisted closure (V.A.C.) device therapy. The authors conclude that V.A.C. is a convenient and safe measure in the management of empyema with BPF. Moreover, in similar clinical contexts, V.A.C. may be the only option available that may assure the survival of the patient and the avoiding any later-phases of residual cavity.

© 2014 Surgical Associates Ltd. Published by Elsevier Ltd. All rights reserved.

## 1. Introduction

Broncho-pleural fistula (BPF) is a dramatic complication after lung resection. Post-resection bronchopleural fistula especially if associated with empyema, while relatively uncommon, represents one of the most dangerous morbid and difficult complications encountered in thoracic surgery [1–9]. The treatment is challenging due to high rate of morbidity and mortality. Herein, we report a case of BPF associated with empyema occurred in an elderly patient undergoing left pneumonectomy for non small-cell lung cancer (NSCLC). After various treatments including chest drainage and endoscopic procedures the BPF was successfully closed by open-window thoracotomy (OWT).

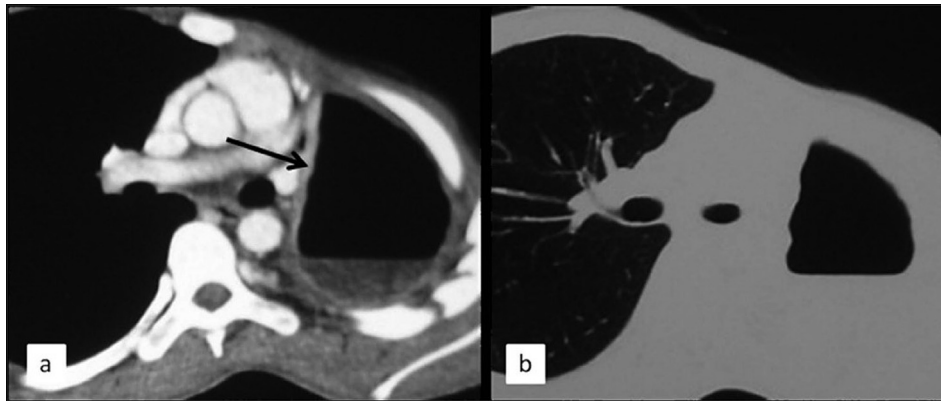
## 2. Clinical case

A 77 years-old man was referred to our hospital for treatment of NSCLC of left lung carcinoma (clinical stage T2N0M0). The tumor was localized between the upper and lower lobe, an anatomical configuration that contraindicated a bronchoplastic procedure.

Clinical and functional conditions were acceptable. A cytological diagnosis of the tumor was performed by a CT-guided fine-needle cytology (FNC); FNC technical details have been described elsewhere [10–19]. Thus, a standard pneumonectomy via thoracotomy was performed in a standard manner. The artery and veins were manually closed and the mainstem left bronchus was closed using a stapler (green cartridge). The post-operative course was unremarkable and the patient was discharged postoperative day 10. In the light of post-operative findings (pathological stage T2N0M0), no adjuvant treatments were planned. Five months later, the patient presented with low grade fever, chills, sweating, cough with mucopurulent sputum, dyspnea on mild exertion, anorexia, and weight loss. Chest computed tomography showed the presence of pleural effusion within left thorax (Fig. 1). A diagnosis of empyema was made. Chest tube drainage and systemic infusion of antibiotics were started immediately. Bronchoscopic examination revealed a fistula of about 7 mm at the level of mainstem bronchus. Repeated bronchoscopic procedure using Tissucol as sealant was performed for closing fistula without success. Thus, an OWT was performed. Briefly, under general anesthesia, an incision was made into the thoracotomy scar at the place of the largest fluid retention and about 10 cm of the underlying rib is resected. The cavity was thoroughly cleaned from debris and necrotic tissue, whereupon the edges of the skin were sutured onto the edges of the parietal pleura and saline-soaked gauzes were applied in the thoracic cavity. A Vacuseal system was applied in the following days by two specialized nurse technicians. Not only the defect in the thoracic

\* Corresponding author. Department of Medicine and Surgery, University of Salerno, Thoracic Surgery, Largo Città di Ippocrate, 84131 Salerno, Italy.

E-mail addresses: [laper@libero.it](mailto:laper@libero.it) (P. Laperuta), [milena.napolitano@yahoo.it](mailto:milena.napolitano@yahoo.it) (F. Napolitano), [avatrella@unisa.it](mailto:avatrella@unisa.it) (A. Vatrella), [vdcre@alice.it](mailto:vdcre@alice.it) (R.M. Di Crescenzo), [ancortese@unisa.it](mailto:ancortese@unisa.it) (A. Cortese), [vdicrescenzo@unisa.it](mailto:vdicrescenzo@unisa.it) (V. Di Crescenzo).



**Fig. 1.** Chest computed tomography showing a pleural effusion within left thorax.

wall, but also the space in the thoracic cavity was filled with tailored polyurethane sponges (V.A.C. GranuFoam; KCI Medical B.V., Houten, the Netherlands), because the lung parenchyma is often still compressed at this stage. Suction was applied (125 mm Hg) directly onto the pleural cavity (without covering gauze dressings) using the ATS-V.A.C. The system was changed on the surgical ward without anesthesia once every 3–5 days according to the increasing of purulent secretions or infection. When the pleural cavity was completely free by secretions and the surfaces appeared granulating, and infection decreased (C-reactive protein levels less than 70 mg/L), A plastic and reconstructive surgery performed using the pedicled latissimus dorsi and a free rectus abdominal muscle flap. After the bronchial closure, the patient was monitored on the ward, and the drains were removed when production had diminished to less than 30 cc in 24 h. No complications were observed in the postoperative period; the production of pus diminished within days. After the operation the general condition of the patient improved rapidly with disappearance of the systemic symptoms of the empyema. The patients could leave the hospital 3 weeks after.

### 3. Discussion

Post-resection bronchopleural fistula especially if associated with empyema, while relatively uncommon, remain perhaps the most morbid and difficult complications encountered in thoracic surgery. After 90 days fibro thorax is formed and pleural space becomes compartmented into small spaces. It is difficult to explain the process of fistula formation as well the method through which its appearance can be prevented. In the present case, systemic antibiotics, adequate tube drainage and irrigation with lavage and/ local instillation of antibiotics and endoscopic procedure were unable to obtain the closure of the BPF. It leads to the decision of performing a thoracostomy with an open window. Open drainage of the pleural cavity along with its irrigation is a method that has been used for the first time 40 years ago by Clagett and Geraci (5) (while introducing the treatment in two steps of empyema appearing after pneumotomy). Later on, Pairolero et al. [4] had modified the procedure by adding bronchial sutures with intrathoracic muscular transposition. In those cases where the fistulas are less than 8 cm and the anesthetic risk for the surgical intervention is high, an endoscopic approach can be tried. In the literature, the use of V.A.C. therapy as part of the surgical treatment of chest wall defects has rarely been described. The advent of V.A.C. for infected wounds in various areas of the body has revolutionized the closure of these defects. In cardiothoracic surgery, the success of

this treatment modality in deep sternal found infections is unequivocal [20–24]. The obliteration of dead space between layers of infected tissue and the removal of bacteria loaded interstitial fluids induces rapid angiogenesis and accelerates the granulation process [4]. As demonstrated by our results, the principle of V.A.C. is also applicable inside the thoracic cavity. One of the critical steps for successful treatment is to completely fill the thoracic cavity with the polyurethane sponge, to prevent reoccurrence of empyema. Finally, the OWT with V.A.C. therapy is a safe measure of the management of empyema with BPF. V.A.C. therapy diminishes the duration of OWT and wound care, in addition to accelerating surgical closure. In this respect, the proposed V.A.C. treatment strategy may improve the quality of life in this particular patient. Post-resection bronchopleural fistula especially if associated with empyema, while relatively uncommon, remain perhaps the most morbid and difficult complications encountered in thoracic surgery.

### Ethical approval

Ethical approval was requested and obtained from the Campania Sud ethical committee.

### Source of funding

All authors have no source of funding.

### Author contribution

**Paolo Laperuta:** Participated substantially in conception, design, and execution of the study and in the analysis and interpretation of data; also participated substantially in the drafting and editing of the manuscript.

**Filomena Napolitano:** Participated substantially in conception, design, and execution of the study and in the analysis and interpretation of data.

**Alessandro Vatrella:** Participated substantially in conception, design, and execution of the study and in the analysis and interpretation of data.

**Rosa Maria Di Crescenzo:** Participated substantially in conception, design, and execution of the study and in the analysis and interpretation of data.

**Antonio Cortese:** Participated substantially in conception, design, and execution of the study and in the analysis and interpretation of data.

**Vincenzo Di Crescenzo:** Participated substantially in conception, design, and execution of the study and in the analysis and

interpretation of data; also participated substantially in the drafting and editing of the manuscript.

### Conflict of interest

All authors have no conflict of interests.

### References

- [1] J.F. Regnard, M. Alifano, P. Puyo, E. Fares, P. Magdeleinat, P. Levasseur, Open window thoracostomy followed by intrathoracic flap transposition in the treatment of empyema complicating pulmonary resection, *J. Thorac. Cardiovasc. Surg.* 120 (2000) 270–275.
- [2] M. Okuda, H. Yokomise, G. Muneuchi, S. Ishikawa, Obliteration of empyema space by vascularized anterolateral thigh flaps, *Ann. Thorac. Surg.* 87 (2009) 1615–1616.
- [3] D. Schneider, T. Grodzki, D. Lardinois, P.B. Kestenholz, J. Wojcik, B. Kubisa, J. Pierog, W. Weder, Accelerated treatment of postpneumonectomy empyema: a binational long-term study, *J. Thorac. Cardiovasc. Surg.* 136 (2008) 179–185.
- [4] S. Zaheer, M.S. Allen, S.D. Cassivi, F.C. Nichols 3rd, C.H. Johnson, C. Deschamps, P.C. Pairolero, Postpneumonectomy empyema: results after the Clagett procedure, *Ann. Thorac. Surg.* 82 (2006) 279–286.
- [5] O.T. Clagett, J.E. Geraci, A procedure for the management of post-pneumonectomy empyema, *J. Thorac. Cardiovasc. Surg.* 45 (1963) 141–145.
- [6] A. Fiorelli, G. Vicidomini, A. Mazzella, G. Messina, R. Milione, V.G. Di Crescenzo, M. Santini, The influence of body mass index and weight loss on outcome of elderly patients undergoing lung Cancer resection, *Thorac. Cardiovasc. Surg.* (2014 Jun 24) [Epub ahead of print].
- [7] P. Laperuta, F. Napolitano, A. Garzi, B. Amato, A. Vatrella, V. Di Crescenzo, Extrathoracic recurrence of type A thymoma, *Int. J. Surg.* (2014 May 22) [Epub ahead of print].
- [8] V. Di Crescenzo, P. Laperuta, A. Garzi, F. Napolitano, A. Cascone, A. Vatrella, Small cell lung cancer associated with solitary fibrous tumors of the pleura: a case study and literature review, *Int. J. Surg.* (2014 May 22) [Epub ahead of print].
- [9] A. Fiorelli, M. Petrillo, G. Vicidomini, V.G. Di Crescenzo, E. Frongillo, A. De Felice, A. Rotondo, M. Santini, Quantitative assessment of emphysematous parenchyma using multidetector-row computed tomography in patients scheduled for endobronchial treatment with one-way valves, *Interact. Cardiovasc. Thorac. Surg.* 19 (2014) 246–255.
- [10] C. Baldi, A. Ieni, I. Cozzolino, V. Cerbone, D. Memoli, P. Zeppa, Ultrasound-guided fine needle aspiration cytology of a primary lymph node leiomyoma: a flexible procedure for a complex case, *Acta Cytol.* 58 (2014) 303–308.
- [11] I. Cozzolino, E. Vigliar, P. Todaro, A.L. Peluso, M. Picardi, L.V. Sosa Fernandez, M.D. Mignogna, G. Tuccari, C. Selleri, P. Zeppa, Fine needle aspiration cytology of lymphoproliferative lesions of the oral cavity, *Cytopathology* 25 (2014) 241–249.
- [12] M. Picardi, N. Pugliese, M. Cirillo, P. Zeppa, I. Cozzolino, G. Ciancia, G. Pettinato, C. Salvatore, C. Quintarelli, F. Pane, Advanced-stage Hodgkin lymphoma: US/Chest radiography for detection of relapse in patients in first complete remission—a randomized trial of routine surveillance imaging procedures, *Radiology* 272 (2014) 262–274.
- [13] E. Vigliar, I. Cozzolino, M. Picardi, A.L. Peluso, L.V. Fernandez, A. Vetrani, G. Botti, F. Pane, C. Selleri, P. Zeppa, Lymph node fine needle cytology in the staging and follow-up of cutaneous lymphomas, *BMC Cancer* 14 (2014) 8.
- [14] F. Petruzzello, P. Zeppa, G. Ciancia, I. Cozzolino, L.S. Fernandez, M. Cervasio, P. Musto, F. D'Auria, G. Vita, F. Morabito, E. Piro, M.R. Ponti, G. Pettinato, R. Ciancia, F. Pane, L. Catalano, Cytological and histological detection of amyloid deposits in bone marrow of patients affected by multiple myeloma, *Leuk. Lymphoma* 52 (2011) 2304–2307.
- [15] I. Cozzolino, R. Zeppa, P. Zeppa, Lymph nodal Merkel cell carcinoma: primary tumor or metastasis from unknown primary site? *J. Cutan. Pathol.* 38 (2011) 836–837.
- [16] P. Zeppa, E. Barra, V. Napolitano, I. Cozzolino, G. Troncone, M. Picardi, A. De Renzo, P.P. Mainenti, A. Vetrani, L. Palombini, Impact of endoscopic ultrasound-guided fine needle aspiration (EUS-FNA) in lymph nodal and mediastinal lesions: a multicenter experience, *Diagn. Cytopathol.* 39 (2011) 723–729.
- [17] I. Cozzolino, S. Nappa, M. Picardi, A. De Renzo, G. Troncone, L. Palombini, P. Zeppa, Clonal B-cell population in a reactive lymph node in acquired immunodeficiency syndrome, *Diagn. Cytopathol.* 37 (2009) 910–914.
- [18] A. D'Antonio, G. Paoletta, P. Zeppa, Rapidly growing intraparotid mass in a young child, *J. Craniofac. Surg.* 23 (2012) e305–6.
- [19] E. Vigliar, A. Caleo, M. Vitale, V. Di Crescenzo, A. Garzi, P. Zeppa, Early cytological diagnosis of extranodal stage I, primary thyroid Non-Hodgkin lymphoma in elderly patients. Report of two cases and review of the literature, *BMC Surg.* 13 (Suppl. 2) (2013) S49.
- [20] A. Fiorelli, S. Mazzone, V.G. Di Crescenzo, G. Costa, A. Del Prete, G. Vicidomini, A. Mazzone, M. Santini, A simple technique to control placement of Dumon stent in subglottic tracheal stenosis, *Interact. Cardiovasc Thorac. Surg.* 18 (2014) 390–392.
- [21] A. Fiorelli, F. Morgillo, M. Fasano, G. Vicidomini, V.G. Di Crescenzo, M. Di Domenico, M. Accardo, M. Santini, The value of matrix metalloproteinase-9 and vascular endothelial growth factor receptor 1 pathway in diagnosing indeterminate pleural effusion, *Interact. Cardiovasc Thorac. Surg.* 16 (2013) 263–269.
- [22] V. Di Crescenzo, P. Laperuta, F. Napolitano, C. Carlomagno, M. Danzi, B. Amato, A. Garzi, M. Vitale, Migration of surgical clips through a right lobectomy stump mimicking an asthmatic syndrome, *BMC Surg.* 13 (Suppl. 2) (2013) S32.
- [23] J.I. Miller, K.A. Mansour, F. Nahai, M.J. Jurkiewicz, C.R. Hatcher Jr., Single-stage complete muscle flap closure of the postpneumonectomy empyema space: a new method and possible solution to a disturbing complication, *Ann. Thorac. Surg.* 38 (1984) 227–231.
- [24] H.C. Chen, Y.B. Tang, M.S. Noordhoff, C.H. Chang, Microvascular free muscle flaps for chronic empyema with bronchopleural fistula when the major local muscles have been divided — one-stage operation with primary wound closure, *Ann. Plast. Surg.* 24 (1990) 510–516.