

Case Report

Term delivery of a complete hydatidiform mole with a coexisting living fetus followed by successful treatment of maternal metastatic gestational trophoblastic disease



Hsiu-Huei Peng^a, Kuan-Gen Huang^{a,*}, Ho-Yen Chueh^a, Aizura-Syafinaz Adlan^b,
Shuenn-Dyn Chang^a, Chyi-Long Lee^a

^a Department of Obstetrics and Gynecology, Chang Gung Memorial Hospital, Linkou Medical Center and Chang Gung University College of Medicine, Kwei-Shan, Taoyuan, Taiwan

^b Department of Obstetrics and Gynaecology, University Malaya Medical Centre, Faculty of Medicine, University of Malaya, Kuala Lumpur, Malaysia

ARTICLE INFO

Article history:

Accepted 6 February 2013

Keywords:

EMA-CO
metastatic gestational trophoblastic disease
twin pregnancy with one complete
hydatidiform mole

ABSTRACT

Objective: A twin pregnancy consisting of a complete hydatidiform mole with a coexisting normal fetus is extremely rare with an incidence of 1/22,000 to 1/100,000. The incidence of preterm delivery is high and few pregnancies reach near term with a viable fetus.

Case report: A 34-year-old woman presented at 20 weeks of gestation with increased levels of serum beta human chorionic gonadotropin (beta-HCG) at 4.74 multiples of the median (310277.7 mIU/mL). Ultrasonography showed a hydatidiform mole together with a normal fetus. Fetal karyotyping revealed 46XY. The serum beta-HCG levels were followed up throughout the remainder of the pregnancy. A male infant weighting 2260 g and the molar tissue were delivered at 37 weeks of gestation. The karyotype of the molar tissue showed 46XX and the histopathological report confirmed our diagnosis. At 4 months postpartum, metastatic gestational trophoblastic disease of the lung was diagnosed in the mother by a computed tomography scan due to increased beta-HCG levels. The patient received three unsuccessful cycles of methotrexate and folinate. Another four cycles of chemotherapy consisting of etoposide, methotrexate, actinomycin D, cyclophosphamide, and vincristine (EMA-CO) were initiated and the beta-HCG levels returned to normal. There was no evidence of recurrence in the subsequent 5 years of regular follow up.

Conclusion: A pregnancy with a complete hydatidiform mole and a living cotwin can be a serious threat to the health of both the mother and the fetus. Early diagnosis depends on a combination of detecting an unusually high level of serum beta-HCG and ultrasound examination. We suggest that continuation of the pregnancy may be an acceptable option and that the pregnancy may continue until term if a normal fetal anatomy is assured and maternal complications are under control. Patients require careful postpartum follow up and any recurrent disease should be managed aggressively.

Copyright © 2014, Taiwan Association of Obstetrics & Gynecology. Published by Elsevier Taiwan LLC. All rights reserved.

Introduction

Twin pregnancies consisting of a complete hydatidiform mole with a coexisting normal fetus are extremely rare [1–7], accounting for an incidence of 1/22,000 to 1/100,000 pregnancies. There is an increased risk of maternal and fetal complications in twin

pregnancies with one complete hydatidiform mole [8–11]. The incidence of preterm delivery is high and few pregnancies reach near term with a viable fetus. Careful evaluation of the risks of maternal and fetal complications is crucial during the continuing pregnancy.

Case report

A 34-year-old woman, gravida 4, para 0, presented at 20 weeks of gestation with increased levels of serum beta human chorionic gonadotropin (beta-HCG) of up to 4.74 multiples of the median

* Corresponding author. Department of Obstetrics and Gynecology, Chang Gung Memorial Hospital, Linkou Medical Center and Chang Gung University College of Medicine, 5 Fu-Hsin Street, Kwei-Shan, Taoyuan 333, Taiwan.

E-mail address: kghuang@ms57.hinet.net (K.-G. Huang).

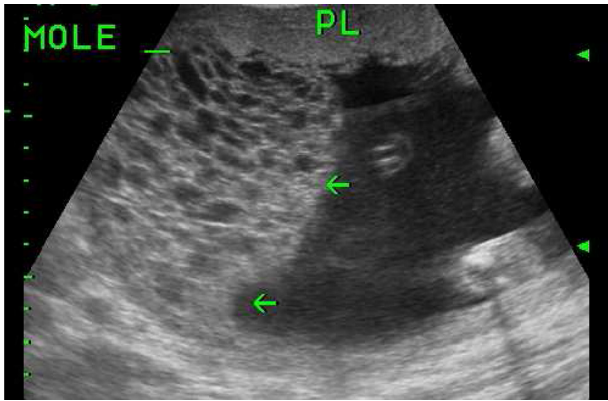


Fig. 1. Ultrasound scan at 20 weeks of gestation showing a live fetus and one hydatidiform mole (arrows) located at the uterine fundus with a grape-like appearance. PL = normal placenta.

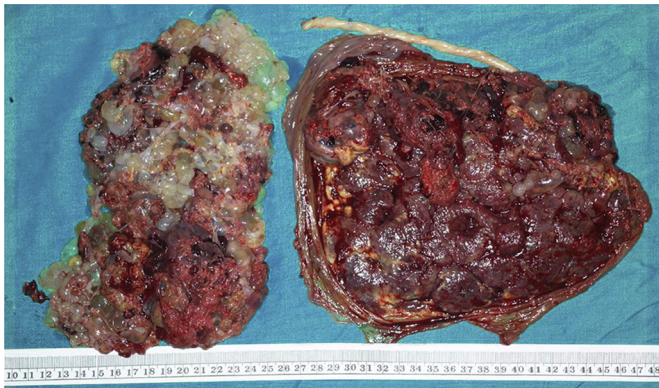

Fig. 2. Gross appearance of the hydatidiform mole (left) with grape-like tissue and another normal placenta with umbilical cord (right).

(310277.7 mIU/mL) detected at the maternal serum screening for Down's syndrome. An ultrasound scan showed a normal fetus and a coexisting, but separate, soft tissue mass with multiple cystic spaces in the uterine fundus, measuring 7.5 cm × 6.8 cm × 5.4 cm (Fig. 1). Amniocentesis for fetal karyotyping revealed 46XY. There was no episode of vaginal bleeding nor evidence of hypertension

during the pregnancy. Ultrasound examination at 35 weeks of gestation showed the normal fetus in a breech presentation and appearing small for gestational age, whereas the hydatidiform mole had grown to 12.2 cm × 9.2 cm × 3.0 cm in size. A male infant weighing 2260 g was delivered by cesarean section at 37 weeks of gestation and the accompanying molar tissue measuring 11 cm × 9.2 cm × 3.0 cm at the uterine fundus was removed (Fig. 2). Karyotyping of the molar pregnancy revealed 46XX and the histopathological report confirmed the diagnosis of a complete hydatidiform mole with visible large hydropic villi and mild trophoblastic proliferation.

The patient recovered well and her levels of serum beta-HCG decreased to 995.3 mIU/mL 1 week later (Fig. 3). At 4 months postpartum, however, she had symptoms of fatigue, dizziness, and intermittent dyspnea. Her beta-HCG levels were rechecked and were 268.1 mIU/mL. A computed tomography scan of her chest showed a nodule (1.6 cm) over the left lower lung, suggestive of an invasive metastatic mole lesion. The patient started chemotherapy with three cycles of methotrexate and folinate when the initial beta-HCG level was 601.2 mIU/mL. Subsequent serum beta-HCG measurements showed a further increase to 2806 mIU/mL, indicating resistance to methotrexate. Therefore a different chemotherapy regimen consisting of etoposide, methotrexate, actinomycin D, cyclophosphamide, and vincristine (EMA-CO) was prescribed. After four cycles of the EMA-CO regimen, the beta-HCG levels were reduced and decreased to within the normal range (<2.0 mIU/mL). There was no evidence of recurrent disease in the following 5 years of follow up.

Discussion

Twin pregnancies consisting of a complete hydatidiform mole with a coexisting normal fetus are rare [1–7], with an incidence ranging from 1/22,000 to 1/100,000. These cases are usually detected in the middle trimester by ultrasound examination and further confirmed by cytogenetic studies and histopathological examination. In our patient, increased beta-HCG levels were noted during maternal serum screening for Down's syndrome, which prompted us to carry out a further evaluation to clarify the underlying condition.

There is an increased risk of maternal and fetal complications in twin pregnancies with one complete hydatidiform mole [8–11], including vaginal bleeding, pre-eclampsia, hyperthyroidism, pregnancy termination, preterm birth, and spontaneous fetal loss [10].

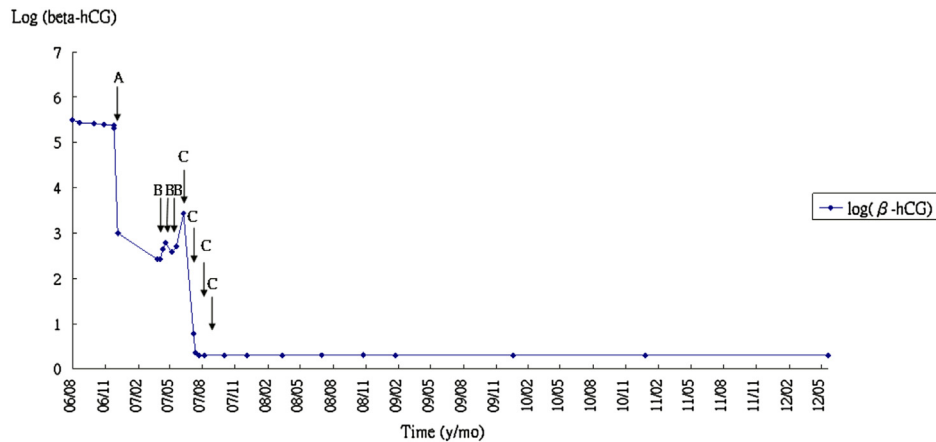


Fig. 3. Log beta-human chorionic gonadotropin (beta-hCG) versus time curve during pregnancy, cesarean delivery, and chemotherapy treatment. (A) Cesarean section at 37 weeks of gestation; (B) chemotherapy with three cycles of methotrexate; and (C) chemotherapy with four cycles of etoposide, methotrexate, actinomycin D, cyclophosphamide, and vincristine.

Table 1
Twin pregnancies consisting of a complete hydatidiform mole with viable fetus.

Study	Number of patients	Maternal age (y)	Gestational age at delivery (wk)	Body weight of neonate (g)	Delivery method	Maternal complications
Anderson et al [1]	1	25	36	2750	Cesarean section	Vaginal bleeding, gestational diabetes
Fishman et al [4]	2	N/A	26	N/A	Vaginal delivery	One patient had preterm labor
			34		Cesarean section	Two patients had persistent gestational trophoblastic tumor
Johnston et al [6]	1	26	30	1410	Cesarean section	Vaginal bleeding
Bruchim et al [7]	2	25	26	875	Cesarean section	One patient had vaginal bleeding, preterm labor and
		28	41	3240	Vaginal delivery	metastatic gestational trophoblastic tumor
Matsui et al [13]	2	37	38	3019	N/A	One patient had persistent gestational trophoblastic tumor
		22	40	2519		
Present report	1	34	37	2260	Cesarean section	Metastatic gestational trophoblastic tumor

N/A = not available.

The incidence of preterm delivery is high and few pregnancies reach near term with a viable fetus (Table 1). A risk of persistent gestational trophoblastic disease has been observed in some studies. In one series, 12 of 22 (55%) patients with a complete mole and a coexisting viable fetus developed persistent gestational trophoblastic disease and required chemotherapy; five of these patients developed metastatic disease requiring multiple cycles of chemotherapy [8]. However, another study reported that the risk of persistent trophoblastic disease after a pregnancy with a diploid mole and a coexisting fetus is similar to that after a singleton molar pregnancy and expectant management instead of therapeutic abortion can be pursued [12].

In the past, immediate termination after the diagnosis of a twin pregnancy with one complete hydatidiform mole has been suggested due to the increased risk of developing persistent gestational trophoblastic disease and maternal complications. Continuation of the pregnancy has recently become an acceptable choice and several cases of continued pregnancy with a living fetus have been reported [1–7] with successful management of complications. In a series of Japanese patients, researchers noted that the rate of subsequent development of persistent trophoblastic tumors was considerably higher in patients with a hydatidiform mole with a coexisting live twin fetus than in patients with a single complete mole [13]. However, as the risk of malignancy is unchanged with advancement of gestational age, continued pregnancy may be allowed in patients under conditions of well-controlled maternal complications and a normal viable fetus [13]. In conclusion, if the diagnosis is made close to fetal viability, continuation of the pregnancy is an acceptable option after extensive discussion and agreement with the parents.

The most common metastatic site of gestational trophoblastic disease is the lungs, which are affected in over 80% of patients. The vagina is the second most common site of metastasis, accounting for 30% of cases. Malignant gestational trophoblastic disease is very sensitive to chemotherapy and a number of chemotherapy regimens are used to treat the disease [14]. Early stage gestational trophoblastic disease is often cured with single-agent chemotherapy. By contrast, advanced stage disease requires multi-agent combination chemotherapeutic regimens to achieve a cure. EMA-CO is the most commonly used combination chemotherapy to treat high-risk gestational trophoblastic disease as it has the best effectiveness to toxicity ratio. In a series of 272 women with high-risk malignant gestational trophoblastic disease who were treated with EMA/CO, 78% achieved complete remission [15]. In cases refractory to EMA-CO or relapse from EMA/CO chemotherapy, researchers reported that etoposide and cisplatin is an effective, but moderately toxic, regimen for these patients [16,17].

In summary, a pregnancy with a complete hydatidiform mole and a living cotwin can be a serious health threat to both the mother and fetus. Early diagnosis depends on a combination of

detecting an unusually high level of serum beta-HCG (perhaps during maternal serum screening for Down's syndrome as in our patient) and ultrasound examination. We suggest that the continuation of the pregnancy may be an acceptable option and a prolonged pregnancy until term is likely if a normal fetal anatomy is assured and any maternal complications are under control. Patients are required to observe careful postpartum follow up and any recurrent disease should be managed aggressively. Women with a history of gestational trophoblastic disease are at increased risk of developing subsequent gestational trophoblastic disease and therefore their future pregnancies require careful monitoring to ensure normal gestational development.

Conflicts of interest

The authors have no conflicts of interest relevant to this article.

Acknowledgments

This study was supported by the following grants: NSC97-2314-B-182-024 (H.H.P.) from the National Science Council, Taiwan; CMRPG 340201 and CMRPG371611 (H.H.P.) and CMRPG 1013 and CMRPG371711 (S.D.C.) from Chang Gung Memorial Hospital, Taoyuan, Taiwan.

References

- Anderson CK, Deiter RW, Motz MJ, Goldstein JA. Complete hydatidiform mole with a coexistent healthy, viable fetus near term: a case report. *J Reprod Med* 1996;41:55–8.
- Vandeginste S, Vergote IB, Hanssens M, Moerman P, Page G, Van Den Berghe K, et al. Malignant trophoblastic disease following a twin pregnancy consisting of a complete hydatidiform mole and a normal fetus and placenta. A case report. *Eur J Gynaecol Oncol* 1999;20:105–7.
- Soysal M, Kara S, Ekici E. Twin pregnancy with a fetus and a complete hydatidiform mole. *Arch Gynecol Obstet* 1996;259:41–4.
- Fishman DA, Padilla LA, Pacita K, Cohen L, Fredereksen M, Lurain JR. Management of twin pregnancies consisting of a complete hydatidiform mole and normal fetus. *Obstet Gynecol* 1998;91:546–50.
- Malinowski W, Biskup I, Dec W. Sad fetus syndrome—gestational trophoblastic disease concurrent with a living fetus or fetuses. *Acta Genet Med Gemello* 1995;44:193–202.
- Johnston KM, Steele EK, Magee SE. Twin pregnancy with a living fetus and coexisting complete hydatidiform mole. *Ulster Med J* 2000;69:168–70.
- Bruchim I, Kidron D, Amiel A, Altaras M, Fejgin MD. Complete hydatidiform mole and a coexistent viable fetus: report of two cases and review of the literature. *Gynecol Oncol* 2000;77:197–202.
- Steller MA, Genest DR, Bernstein MR, Lage JM, Goldstein DP, Berkowitz RS. Clinical features of multiple conception with partial or complete molar pregnancy and coexisting fetuses. *J Reprod Med* 1994;39:147–54.
- Steller MA, Genest DR, Bernstein MR, Lage JM, Goldstein DP, Berkowitz RS. Natural history of twin pregnancy with complete hydatidiform mole and coexisting fetus. *Obstet Gynecol* 1994;83:35–42.
- Wee L, Jauniaux E. Prenatal diagnosis and management of twin pregnancies complicated by a co-existing molar pregnancy. *Prenat Diagn* 2005;25:772–6.

- [11] Edi V, Alon B, Ram D, Sharon P, Nadia S, Zion H. Twin pregnancy consisting of a complete hydatidiform mole and co-existent fetus: report of two cases and review of literature. *Gynecol Oncol* 2005;98:19–23.
- [12] Niemann I, Sunde L, Petersen LK. Evaluation of the risk of persistent trophoblastic disease after twin pregnancy with diploid hydatidiform mole and coexisting normal fetus. *Am J Obstet Gynecol* 2007;197:45. e41–5.
- [13] Matsui H, Sekiya S, Hando T, Wake N, Tomoda Y. Hydatidiform mole coexistent with a twin live fetus: a national collaborative study in Japan. *Humanit Rep* 2000;15:608–11.
- [14] Deng L, Yan X, Zhang J, Wu T. Combination chemotherapy for high-risk gestational trophoblastic tumour. *Cochrane Database Syst Rev* 2009;15: CD005196.
- [15] Bower M, Newlands ES, Holden L, Short D, Brock C, Rustin GJ, et al. EMA/CO for high-risk gestational trophoblastic tumors: results from a cohort of 272 patients. *J Clin Oncol* 1997;15:2636–43.
- [16] Mao Y, Wan X, Lv W, Xie X. Relapsed or refractory gestational trophoblastic neoplasia treated with the etoposide and cisplatin/etoposide, methotrexate, and actinomycin D (EP-EMA) regimen. *Int J Gynaecol Obstet* 2007;98:44–7.
- [17] Newlands ES, Mulholland PJ, Holden L, Seckl MJ, Rustin GJ. Etoposide and cisplatin/etoposide, methotrexate, and actinomycin D (EMA) chemotherapy for patients with high-risk gestational trophoblastic tumors refractory to EMA/cyclophosphamide and vincristine chemotherapy and patients presenting with metastatic placental site trophoblastic tumors. *J Clin Oncol* 2000;18:854–9.