



Available online at

SciVerse ScienceDirect  
www.sciencedirect.com

Elsevier Masson France

EM|consulte  
www.em-consulte.com/en

Orthopaedics  
& Traumatology  
Surgery & Research

## TECHNICAL NOTE

# Anterior minimally invasive extrapleural retroperitoneal approach to the thoraco-lumbar junction of the spine

C.F. Litré<sup>a</sup>, J. Duntze<sup>a,\*</sup>, Y. Benhima<sup>b</sup>, C. Eap<sup>a</sup>, S. Malikov<sup>c</sup>, G. Pech-Gourg<sup>d</sup>,  
B. Blondel<sup>d</sup>, P. Métellus<sup>d</sup>, S. Fuentes<sup>d</sup>

<sup>a</sup> Department of Neurosurgery, Maison-Blanche Hospital, Reims Teaching Medical Center, 45, rue Cognacq-Jay, 51092 Reims cedex, France

<sup>b</sup> Department of Neurosurgery, Paul-Desbieff Hospital, 38, rue Forbin, 13002 Marseille, France

<sup>c</sup> Department of Vascular Surgery, La Timone Hospital, 264, rue Saint-Pierre, 13385 Marseille cedex 5, France

<sup>d</sup> Department of Neurosurgery, La Timone Hospital, 264, rue Saint-Pierre, 13385 Marseille cedex 5, France

Accepted: 30 August 2012

**KEYWORDS**

Anatomy;  
Thoraco-lumbar  
spinal junction;  
Minimally invasive  
approach;  
Spinal cord;  
Spine anterior  
approach

**Summary**

**Background:** The anterior approach to the thoraco-lumbar junction of the spine allows therapeutic interventions on post-traumatic, infectious, and neoplastic vertebral lesions from T11 to L2 combining spinal cord decompression, corporectomy, and vertebral body fusion. However, this approach also has a reputation for damaging the intervening anatomic structures (lungs, peritoneum, and diaphragm). The objective of this study was to show that both nervous structure decompression and anterior vertebral reconstruction can be achieved via an anterior minimally invasive extrapleural retroperitoneal (AMIER) approach.

**Material:** We describe each of the steps of the AMIER approach to the thoraco-lumbar junction of the spine.

**Results:** The AMIER approach ensures excellent exposure that allows full decompression and satisfactory anterior anatomic reconstruction. The main difficulties and complications relate to the lungs, and a painstaking and rigorous technique limits the complications compared to conventional thoraco-phreno-lumbotomy.

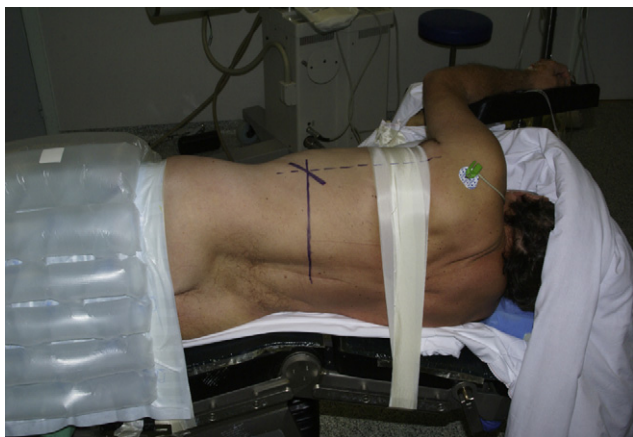© 2012 Elsevier Masson SAS. All rights reserved.

**Introduction**

The thoraco-lumbar junction of the spine (T11-L2) is the most common site of various spinal lesions such as fractures, neoplasms, and infections [1,2]. The optimal treatment

\* Corresponding author.

E-mail address: [jduntze@chu-reims.fr](mailto:jduntze@chu-reims.fr) (J. Duntze).



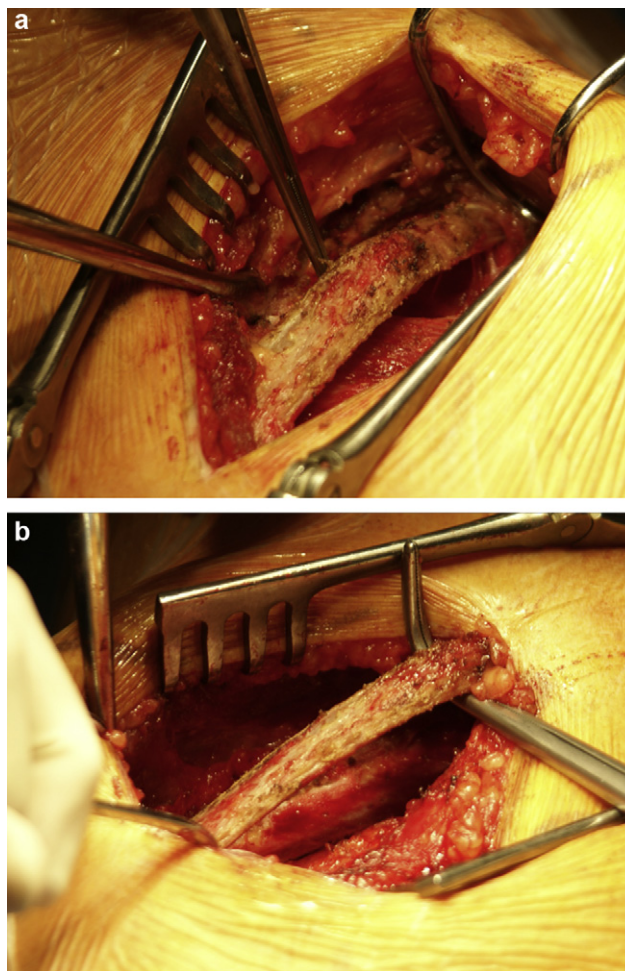
**Figure 1** Patient in the right lateral decubitus position. Note the break in the operating table at the level of the vertebra of interest to open up the left intervertebral space. The posterior axillary line is shown in blue as a dashed line. The abnormal vertebra, identified by fluoroscopy, is identified in blue by a solid horizontal line. The two lines intersect over the rib that will be removed.

of these lesions usually requires both decompression and surgical stabilisation. An abundance of published data establishes the efficacy of anterior surgical procedures in patients with fractures or neoplasms of the thoraco-lumbar junction [3,4]. The standard anterior approach to the thoraco-lumbar junction is thoraco-phreno-lumbotomy [5,6]. Although this approach provides extensive exposure of the anterolateral aspect of T11 to L2, it has the major drawback of causing substantial tissue damage.

### **Surgical procedure: anterior minimally invasive extrapleural retroperitoneal (AMIER) approach**

Spinal cord arteriography is performed routinely before the procedure to identify the origin of the anterior spinal artery (vertebral level and side). General anaesthesia is achieved using standard techniques. Anterolateral exposure of the thoraco-lumbar junction is more difficult and more risky on the right side, because of the presence of the liver. Consequently, the AMIER approach is performed on the left side. The patient is in the right lateral decubitus position, supported by a gel pad placed under the right armpit (Fig. 1).

The position of the operating table is modified under fluoroscopic guidance until the incident beam is parallel to the endplates of the vertebra of interest. A skin incision 6 to 10 cm in length (1 cm/10 kg body weight) is performed over the rib that will be removed (Fig. 1). This rib is identified by tracing a line that runs through the vertebra of interest perpendicularly to the posterior axillary line. The skin incision is centered on the intersection of these two lines. The skin incision and removed rib are usually located two levels above the abnormal level. The intercostal muscles are detached subperiosteally over 8 to 10 cm (Fig. 2a). The rib segment is exposed then removed (leaving the costo-transverse portion over 4 cm) (Fig. 2b). The diaphragm is then released from the lower ribs (Fig. 3).

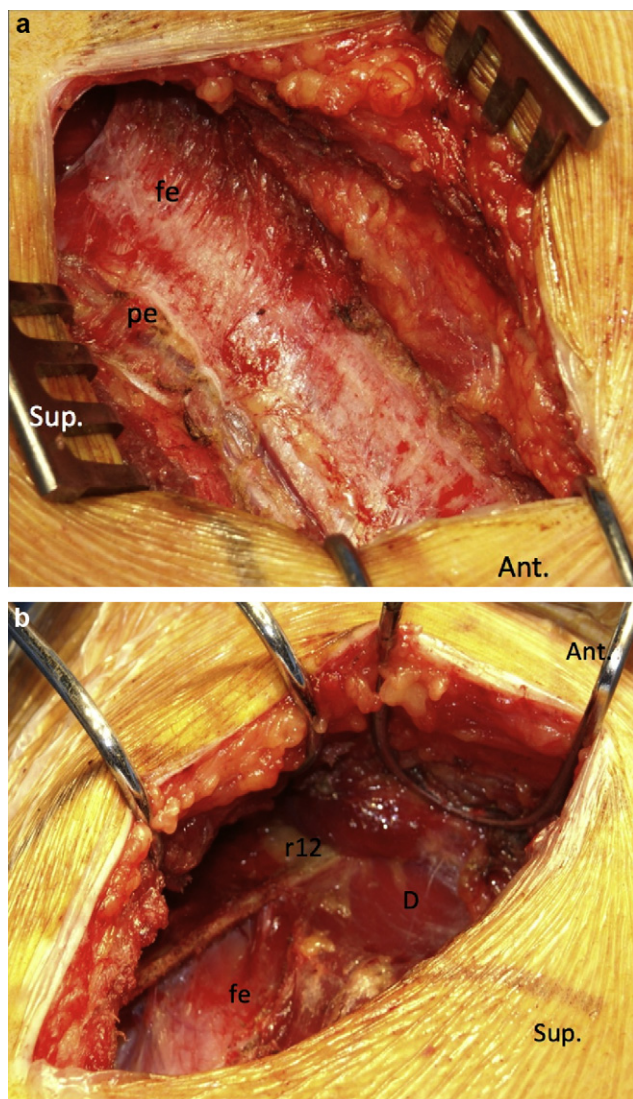


**Figure 2** a, b: circumferential subperiosteal separation of the rib to detach the endothoracic fascia (a) from the medial aspect of the 11th rib (b).

The contiguity of the endothoracic fascia, lower costal origins of the diaphragm, and fascia transversalis allow caudal extension of the exposure to the lumbar vertebral segments without penetration of the thoracic and abdominal cavity (Fig. 4). The endothoracic fascia is separated from the chest wall using a mounted elevator and tamp to expose the lower thoracic vertebrae to T10. Separation of the fascia transversalis and perirenal fat from the abdominal wall during strictly retroperitoneal dissection allows exposure of the lumbar vertebrae to L3 caudally (Fig. 5). The psoas muscle is identified then mobilized, starting with the disk attachments to avoid injury to the segmental vascular pedicle. This pedicle can then be clipped or ligated depending on the vertebral level to be treated. In addition to the psoas muscle, the posterior crus of the diaphragm covers the bodies of L1 and L2. Mobilization of the posterior crus allows downward extension of the exposure of the thoraco-lumbar junction, thus opening up the pathway towards the lumbar vertebrae. The posterior crus should therefore also be detached if lumbar corporectomy is considered.

The discs above and below the vertebra of interest are removed, taking care to spare the endplates of the normal supra- and infrajacent vertebrae. Corporectomy is then

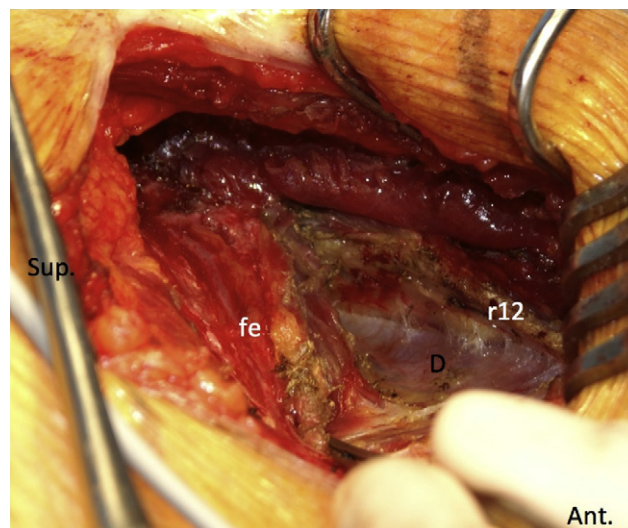




**Figure 3** a: lateral view showing the endothoracic fascia (ef) after removal of the 11th rib. The intercostal vasculo-nervous bundles (vnb), thoracic sympathetic chain, thoracic duct, and azygos veins are contained within this fascia, in contact with the chest wall and vertebral bodies; b: view from above showing the 12th rib in place. The medial aspect of the 12th rib receives the attachments of the diaphragm (D) ventrally and of the endothoracic fascia (ef) dorsally. These two structures are cautiously separated using a Cobb elevator.

performed. The posterior cortex is usually removed using a burr. The dural sheath and nerve roots are decompressed. To reconstruct the vertebral defect, a titanium cage is positioned under fluoroscopic guidance. The cage is filled with acrylic cement in patients with neoplasms and with a tricortical iliac-crest bone graft in those with fractures. A plate screwed to the supra- and infra-adjacent vertebrae ensures stability of the assembly (Fig. 6).

During closure, pleural tears are looked for painstakingly, in particular via a routine Valsalva manoeuvre. Pleural tears are sutured if possible. A standard small-calibre drain is placed in the operative site, in contact with the psoas muscle. A chest radiograph is taken in the post-anaesthesia



**Figure 4** Lateral view showing the lower diaphragmatic attachments to the ribs.

care unit to look for pneumothorax. The patient is then transferred to the ward, with no intermediate stay in the intensive care unit.

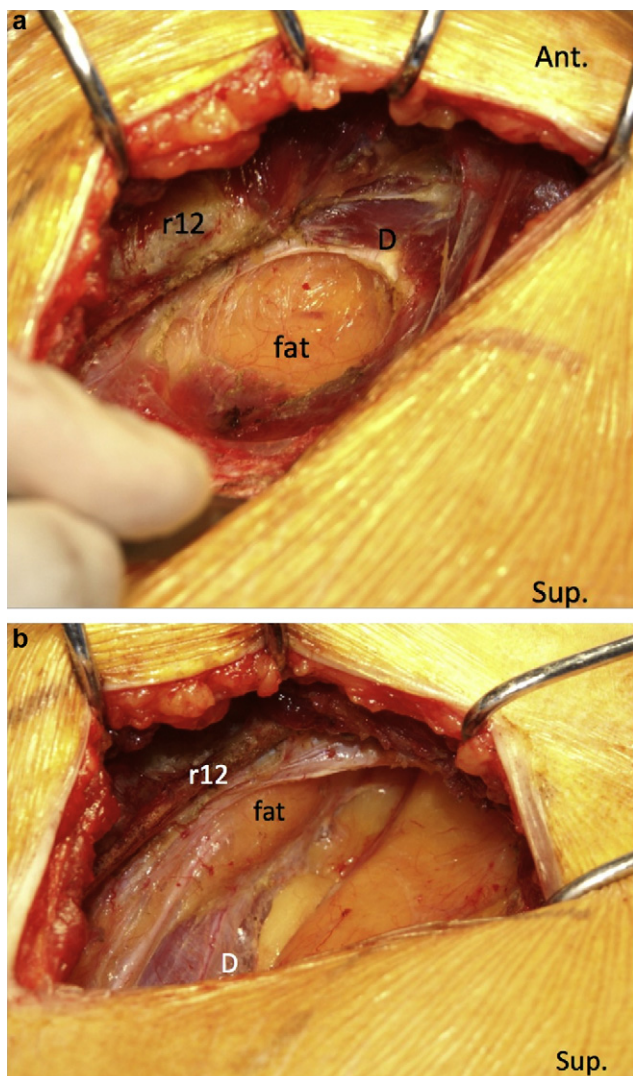
## Clinical results

We prospectively studied the clinical and radiological data from two single-centre case-series [7,8]. Short posterior fixation via pedicle screws was consistently performed before the corporectomy and anterior vertebral body fusion via the AMIER approach. The exposure provided by the AMIER approach allowed full decompression followed by satisfactory anterior anatomic reconstruction as assessed by postoperative imaging studies in all the patients.

Surgical complications were fairly uncommon. In our latest case-series of 40 patients, only one patient experienced intraoperative bleeding, from a large vein that was injured by the burr and promptly controlled by clipping [7]. A chest tube was required in one patient and blood transfusions in two patients. There were no neurological complications or other complications.

## Discussion

The AMIER approach provides satisfactory exposure of the thoraco-lumbar spinal junction without exposing the patient to the risks inherent in opening the pleural and peritoneal cavities (ventilatory function impairment, atelectasis, reflex ileus). This approach was first described for minimally invasive retroperitoneal surgery. The extrapleural retroperitoneal approach with removal of the 12th rib was initially developed to allow kidney surgery and, more specifically, perirenal abscess drainage [9]. Spine surgeons then modified the technique to gradually increase the number of exposed vertebral levels. In 1973, Mirbaha described an anterior extrapleural approach to the thoraco-lumbar junction via the 12th rib [9]. Watkins reported a similar retroperitoneal approach through the 12th rib but stated that, although the

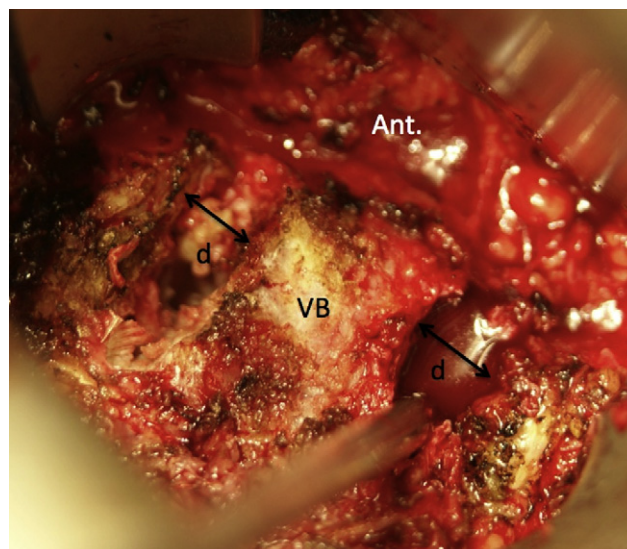


**Figure 5** Separation of the diaphragmatic crus (D) from the body of L2 may be required to increase exposure and to allow complete L1 or L2 corpectomy (5a before and 5b after detachment of the diaphragmatic crus).

extrapleural space could theoretically be extended to T10, exposure would be inadequate above T12 [10].

McAfee et al. reported clinical data on their experience with the extrapleural retroperitoneal approach involving removal of the 12th rib [11]. Kim et al. described a case-series of 26 patients with T11-L1 lesions treated by an extrapleural retroperitoneal approach with removal of the 11th rib [5]. McCormick used a retropleural approach with removal of the 12th rib to expose L2 in two patients [12]. This approach was described by McCormick as requiring an incision in the endothoracic fascia with sparing of the parietal pleural membrane. In contrast to McCormick, we feel that incision of the endothoracic fascia is unnecessary. Leaving the fascia intact allows similar satisfactory exposure without the risk of weakening the pleural membrane and increasing the risk of pneumothorax [8].

One of the main challenges raised by this approach is preservation of the pleural membranes during the dissection. Dissection should be performed with extreme care, as



**Figure 6** Lateral view showing the abnormal vertebral body (VB) after complete removal of the adjacent discs. The emptied intervertebral disc (d) is identified by a black double arrow.

the pleural membranes are very thin. Pleural tears must be sutured if at all possible. The risk of vascular injury is relatively limited, since none of the large vessels is exposed; instead, the vessels are displaced and remain connected to the retroperitoneum.

## Conclusion

The AMIER approach provides excellent exposure allowing full decompression and satisfactory anterior anatomic reconstruction. A cautious and rigorous technique drastically decreases the risk of complications compared to conventional thoraco-phreno-lumbotomy.

## Disclosure of interest

The authors declare that they have no conflicts of interest concerning this article.

## References

- [1] Clohisy JC, Akbarnia A, Bucholz RD. Neurologic recovery associated with anterior decompression of spine fractures at the thoracolumbar junction (T12-L1). *Spine* 1992;17:S325–30.
- [2] Eismont FJ, Bohlman HH, Soni PL, Goldberg VM, Freehafer AA. Pyogenic and fungal vertebral osteomyelitis with paralysis. *J Bone Joint Surg Am* 1983;65:19–29.
- [3] Johnson JR, Leatherman KD, Holt RT. Anterior decompression of the spinal cord for neurological deficit. *Spine* 1983;8:396–405.
- [4] Kitchel SH. Surgical approaches to the thoracic and lumbar spine. In: Levine A, Eismont F, Garfin S, editors. *Spine trauma*. Philadelphia: WB Saunders; 1998. p. 144–55.
- [5] Kim M, Nolan P, Finkelstein JA. Evaluation of 11th rib extrapleural-retroperitoneal approach to the thoracolumbar junction. Technical note. *J Neurosurg* 2000;93:S168–74.



- [6] Muhlbauer M, Pfisterer W, Eyb R, Knosp E. Minimally invasive retroperitoneal approach for lumbar corpectomy and reconstruction. Technical note. *Neurosurg Focus* 1999;7(6):e4.
- [7] Litré CF, Benhima Y, Pech-Gourg G, Malikov S, Blondel B, Métellus P, et al. Minimally invasive extrapleural retroperitoneal approach for thoracolumbar junction. Prospective study of 40 cases. *Neurochirurgie* 2012;58(3):331–6.
- [8] Fuentes S, Blondel B, Malikov S, Benhima Y, Metellus P, Grisoli F. Minimally invasive extrapleural retroperitoneal approach to the thoracolumbar spine junction: clinicoradiologic study of 29 consecutive cases. *Neurosurg Q* 2010;20:100–6.
- [9] Mirbaha MM. Anterior approach to the thoraco-lumbar junction of the spine by a retroperitoneal-extrapleural technic. *Clin Ortop* 1973;91:41–7.
- [10] Watkins RG. *Surgical approaches to the spine*. New York: Springer-Verlag; 1983.
- [11] McAfee PC, Bohlman HH, Yuan HA. Anterior decompression of traumatic thoracolumbar fractures with incomplete neurological deficit using a retroperitoneal approach. *J Bone Joint Surg Am* 1985;67:89–104.
- [12] McCormick PC. Retropleural approach to the thoracic and thoracolumbar spine. *Neurosurgery* 1995;37:908–14.