

(PV) flow, left atrial appendage (LAA) flow as well as mitral and tricuspid inflows were recorded. RFA was successful in all patients. The recovery of booster pump function (defined by the presence of the mitral inflow A-wave, the LAA a-wave and the PV A-reversal wave velocities greater than 10 cm/sec) was observed for 39 of 45 patients (86.6%). LAA emptying in AF predicted the degree of recovery of atrial cavity and appendage function following RFA ( $F=41.34$ ,  $p<0.0001$  by Stepwise multivariate regression analysis). Additionally, the change in PVF S-wave pre and post-ablation correlated to the degree of atrial booster function following RFA ( $R=0.48$ ,  $p=0.001$  with PVF A-reversal and  $R=0.41$ ,  $p=0.008$  with LAA a-wave). PV S1-wave (atrial relaxation) was the best (by ROC curve analysis) predictor of LA booster pump function in recovery with a sensitivity of 72%, and specificity of 78% using a cut-off value of 32.5 cm/s. Conclusion: LAA emptying during AF was an important predictor of the degree of recovery of atrial and appendage function. PVF also correlated to the degree of booster pump function recovery. These parameters may be useful in patient selection as well as long term anti-arrhythmic and anticoagulation management for RFA

1166-47

#### Monitoring of Catheter Thrombus and Char Formation Using Phased Array Intracardiac Echo During Pulmonary Vein Isolation in Patients With Atrial Fibrillation

Nassir F. Marrouche, The Cleveland Clinic Foundation, Cleveland, OH, Klinikum Coburg, Coburg, Germany

**Background:** Cerebrovascular accidents (CVA) due to embolic events represent a major procedural risk in patients undergoing left atrial or left ventricular radiofrequency ablation procedures. These embolic events are mainly due to thrombus or char formation on the ablation and/or mapping catheters. We report the importance of intracardiac echo (ICE) in the early detection of catheters related char and thrombus during PV isolation procedures. **Methods and Results:** Two hundred patients presented for circular mapping guided PV isolation (165 men; mean age  $54\pm 11$  years) for treatment of symptomatic AF. Activated clotting time (ACT) was maintained above 300 sec using intravenous heparin. Radiofrequency energy was delivered using a cooled tip ablation catheter. Energy delivery was titrated watching for micro-bubbles formation using the ICE in all study patients. In 4% of patients (8/200) an echo-dense mobile structure on the circular mapping catheter (Lasso) was detected by the ICE during the ablation procedure. The mapping catheter was immediately removed from the left atrium. The mobile structure appeared to be associated with charring in all patients. LA size, procedure time, number of lesions delivered, and RF power did not predict char formation. **Conclusion:** The use of phased array intracardiac echo seems facilitates the detection of intra-procedural charring and thrombus formation. These preliminary findings should encourage the use of ICE during left atrial and/or left ventricular ablation procedures. This could minimize the risk of CVA in such population.

1166-48

#### Wavelet Versus JPEG Compression of Echocardiograms

Christian H. Jansen, Li Zeng, Muthuvel Arigovindan, Michael Suehling, Stephan Marsch, Patrick R. Hunziker, University Hospital, Basel, Switzerland, EPFL, Lausanne, Switzerland

**Background:** Image compression of echocardiograms is important because it allows fast data transmission across slow lines in telemedicine and limits the expense for storage media. Although wavelet compression becomes increasingly important, there is limited data about its value in echo, whereas JPEG compression is well established. **Methods:** Nonselected clinical echos were subjected to JPEG compression, to wavelet compression (using biorthogonal wavelet filters and a zerotree compression strategy) and compared to noncompressed loops. Compression quality was judged quantitatively by comparing the signal-to-noise ratio of compressed vs noncompressed data, as well as qualitatively by expert review of the loops (Visual scale 10 best, 0 worst). Compression rates from 20:1, 32:1, 64:1, 128:1 and 300:1 were tested. **Results:** Compression results are given in Table. Already at low compression rate, quantitative error analysis shows an advantage of wavelet compression, although the visible loss is small (apart from JPEG block artifacts) with both methods. At higher compression rate, image quality deteriorates less rapidly with wavelets than with JPEG. Very high compression (128-300:1) is feasible only with wavelets. **Conclusion:**

Compared to JPEG, wavelet compression of clinical echo loops yields better compression quality, especially at higher compression rates. For telemedicine across connections with limited bandwidth and in cost-sensitive storage applications, wavelets should be preferred.

JPEG vs Wavelets: Subjective and Objective Results

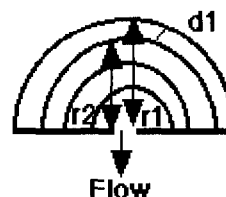
| Compression strategy/<br>rate | JPEG<br>visual | Wavelet<br>visual | p             | Wavelet<br>SNR | JPEG<br>SNR |
|-------------------------------|----------------|-------------------|---------------|----------------|-------------|
| 20:1                          | 8.8±0.9        | 8.9±0.7           | 0.68,<br>n.s. |                |             |
| 32:1                          | 8.8±0.8        | 8.5±0.7           | 0.44,<br>n.s. | 37.69          | 21.88       |
| 64:1                          | 6.0±1.2        | 7.2±0.6           | <0.001        | 36.41          | 13.17       |
| 128:1                         | 3.5±1.1        | 6.5±1.1           | <0.001        | 34.62          | 11.71       |
| 300:1                         | 1.33±0.5       | 5.1±1.0           | <0.001        | 33.73          | 9.84        |

1166-49

#### Quantitative Assessment of Severity of Ventricular Septal Defect Use of the Noninvasive New Method: An Interlasing Distance Flow Convergence Region Study

Masahiro Ishii, Yoko Sugahara, Toyojiro Matsuishi, Kurume University, Kurume, Japan

A new approach using the interlasing distance of the flow convergence region (FCR) from 2 dimensional (2D) color Doppler has offered the opportunity of evaluating the FCR without directory identifying the defect center. We evaluated VSD shunt flow quantification using the distance between adjacent aliasing boundaries (interlasing distance = IAD) of the FCR in 14 patients with isolated VSD (age 8 to 36 weeks). Color Doppler data were obtained with 7.5 MHz or 12 MHz probe (Philips Inc.) placed on the chest and system Nyquist limits (V) set at 22 to 66 cm/sec. VSD shunt flow (Q) was calculated by deriving the area of the two FCR hemispheres (2Br<sup>2</sup>) and multiplying this by the velocity difference (V) according to the simplified equation:  $Q = 72.5 \cdot d^2 \cdot V$ . There was an excellent correlation and agreement between the VSD shunt flow volume calculated from IAD and reference results by cardiac catheterization ( $r = 0.98$ ,  $p < 0.05$ , mean difference =  $0.19 \pm 0.56$  l/min). There was a good correlation between shunt flow rates calculated using the conventional 2D one-axis measurement of the FCR isovelocity surface area with the hemispheric assumption and reference results by cardiac catheterization ( $r = 0.92$ ,  $p < 0.05$ , mean difference =  $-0.57 \pm 0.76$  l/min). However, the conventional FCR method substantially underestimated the actual shunt flow rate. Conclusion Our new method is fast, and accurate; it is easy to use, and it should facilitate use of flow field acceleration method in the clinical setting.



1166-50

#### Substernal Epicardial Echocardiography May Be a Critical Diagnostic Tool in the Postoperative Cardiac Surgery Patient

Harmony R. Reynolds, Robert M. Applebaum, Daniel M. Spevack, Alan Shah, Eileen P. McAleer, Ambika C. Nayar, Paul A. Tunick, Angelo LaPietra, Sandeep Patel, Costas S. Bizakis, Michael G. Wood, Eugene A. Grossi, Greg H. Ribakove, Stephen B. Colvin, Itzhak Kronzon, New York University School of Medicine, New York, NY

**Background:** Postoperative cardiac surgery pts often pose a challenge: they may become critically ill and often have nondiagnostic transthoracic echo (TTE). Transesophageal echo (TEE) is frequently used when TTE is not diagnostic. However, TEE is semi-invasive and may be technically limited. Recently, a new echocardiographic window was introduced with the modification of a mediastinal drainage tube to allow substernal epicardial echo (SEE). The tube has 2 lumens: one for mediastinal drainage and another with a blind end. This allows insertion of a standard TEE probe into the mediastinum without contact with tissues or body fluids.

**Methods:** SEE was attempted in 40 pts. Images were compared to intraop TEE and bedside TTE.

**Results:** In 36 of 40 pts, the echo probe was inserted easily into the SEE tube. In 4 pts, it could not be advanced beyond the rectus sheath. In one pt the tube angle was too steep and the tube kinked; in 3 pts the rectus fascia incision was too small. In all 4 of these pts, mediastinal drainage was adequate. These 4 pts represent the initial experience of 3 surgeons; with more experience we did not encounter this problem. There were no complications. In 2 pts, TEE could not be performed. In all pts, TTE was suboptimal.

In the 36 pts in whom the SEE probe could be passed, image quality was excellent, similar to or better than TEE. Images of anterior structures were of particularly high quality. Detailed assessment of the anatomy and function of the right atrium and ventricle and tricuspid valve could be carried out. In addition, the proximal coronary arteries and coronary bypass grafts were often seen. In all 36 pts, SEE image quality was far superior to TTE. SEE exams lasted approximately 5 minutes.

In 3 patients with hypotension, we used SEE to diagnose life-threatening disorders which were not apparent on TTE or TEE: tamponade and right ventricular hypokinesia, hypovolemia and systolic anterior motion of the mitral valve with outflow tract obstruction.

**Conclusions:** SEE is an important tool in the management of the postop cardiac surgery pt. SEE can be performed easily as long as the tube is properly inserted; this technique is easily learned. SEE may be the only available window in pts with nondiagnostic TTE and TEE.