



Available online at

SciVerse ScienceDirect  
[www.sciencedirect.com](http://www.sciencedirect.com)

Elsevier Masson France

EM|consulte  
[www.em-consulte.com/en](http://www.em-consulte.com/en)

Orthopaedics  
& Traumatology  
Surgery & Research

ORIGINAL ARTICLE



# The anatomical basis for anterior interosseous nerve palsy secondary to supracondylar humerus fractures in children

Y. Vincelet<sup>a</sup>, P. Journeau<sup>a,\*</sup>, D. Popkov<sup>b</sup>, T. Haumont<sup>a</sup>,  
P. Lascombes<sup>c</sup>

<sup>a</sup> Service d'orthopédie et traumatologie pédiatrique (Pr P.-Journeau), hôpital d'enfants de Brabois, CHU de Nancy, Nancy, France

<sup>b</sup> Scientific and Clinical Laboratory for Deformity Correction and Limb Lengthening, Federal State-Financed Institution Russian Ilizarov Scientific Center for Restorative Traumatology and Orthopaedics, M. Ulyanova street, 6, 640014, Kurgan, Russia

<sup>c</sup> Service d'orthopédie pédiatrique, hôpital des enfants et adolescents, HUG, Genève, Switzerland

Accepted: 24 April 2013

## KEYWORDS

Anterior interosseous nerve;  
Supracondylar fracture;  
Nerve palsy;  
Children;  
Anatomy

## Summary

**Introduction:** Various studies have found that 6.6 to 31% of supracondylar elbow fractures in children have nerve-related complications. One-third of these are cases of anterior interosseous nerve (AIN) palsy that usually result in a deficit of active thumb and index flexion. The goal of this cadaver study was to describe the course of the AIN to achieve a better understanding of how it may get injured.

**Materials and methods:** On 35 cadaver specimens, the median nerve and its collateral branches destined to muscles were dissected at the elbow and forearm levels. The distance at which the various branches arose was measured relative to the humeral intercondylar line. Interfascicular dissection of the AIN was used to map its distribution within the median nerve.

**Results:** The AIN arises at an average of 45 mm from the humeral intercondylar line. Before emerging from the median nerve, the AIN fascicles were always found in the dorsal part of the median nerve. After emerging, the AIN was divided into two zones. Zone 1 was the transitional portion from its exit point until its entrance into the interosseous space, where it changes direction. Zone 2 was the interosseous portion between the radius and ulna that comes into

\* Corresponding author. Service de chirurgie orthopédique pédiatrique (Pr P.-Journeau), hôpital d'enfants, centre hospitalo-universitaire de Nancy, 5, allée du Morvan, 54511 Vandœuvre, France. Tel.: +33 3 83 15 47 07/+33 3 83 15 47 15; fax: +33 3 83 15 46 91/+33 3 83 15 47 15.

E-mail address: [p.journeau@chu-nancy.fr](mailto:p.journeau@chu-nancy.fr) (P. Journeau).

contact with the anterior interosseous membrane to which it is attached over its entire length until it ends in the pronator quadratus (PQ) muscle. The muscle branches of the AIN destined for the flexor pollicis longus (FPL) and flexor digitorum profundus (FDP) muscles mostly originated in Zone 1, which is the transitional portion between the median nerve and the fixed Zone 2. The branches destined to the pronator teres (PT) and flexor carpi radialis (FCR) originating from the median nerve are more proximal and superficial.

*Discussion:* The injury mechanisms leading to selective AIN palsy secondary to supracondylar elbow fracture in children are probably the result of two factors: direct contusion of the posterior aspect of the median nerve, and thereby the AIN fascicles, by the proximal fragment; stretching of AIN in Zone 1, which has less ability to withstand stretching than the median nerve and its other branches because the AIN is fixed in Zone 2.

*Conclusion:* Details about the origin and course of the AIN can explain the high percentage of AIN palsy in supracondylar elbow fractures in children.

*Level of evidence:* Level IV. Anatomic study.

© 2013 Elsevier Masson SAS. All rights reserved.

## Introduction

Supracondylar elbow fractures make up 3% of all fractures in children [1]. Five fracture types were identified and described by Lagrange and Rigault in 1962 [2,3]. Types III and IV are responsible for most of the immediate complications, which are mainly nerve-related but can also be vascular in nature [4–6]. Several series have found that 6.6 to 31% of supracondylar elbow fractures in children have nerve-related complications [1,4,6,7]. Since 95% of these fractures occur in extension, the displacement of the distal fragment seems to be an important factor in the pathophysiology of the nerve trunk injury [4]. Among the 60 nerve-related complications observed in a series of 210 supracondylar fractures [4], the median nerve was involved in 28 cases (with posterolateral displacement in 86% of these cases), the radial nerve was injured in 13 cases (posteromedial displacement in 92% of cases) and the ulnar nerve was paralysed in 25 cases (with posterolateral and posteromedial displacement in 56% and 40% of cases, respectively).

The anterior interosseous nerve (AIN) is a branch of the median nerve that always innervates the flexor pollicis longus (FPL) muscle and the flexor digitorum profundus (FDP) muscle fascicle destined to the index. In cases of palsy, an active flexion deficit exists in the thumb interphalangeal joint and the index distal interphalangeal joint, leading to a duck bill deformity when the patient is asked to make a circle with their index finger and thumb; however this sign is non-specific [5,8]. This palsy is found in multiple diseases having a neuritis-related or compressive etiology [9–20]. The prognosis, all etiologies combined, is good, even without exploratory surgery, which only finds a clearly identified anatomical injury in 16% of cases [19].

AIN palsy is found in 7.6 to 8.6% of supracondylar fractures and by itself, makes up 47% of all nerve-related complications and 70% of median nerve injuries [1,4,6,7,14,21,22]. But these only occur with posterolateral fragment displacement [4]. The prognosis is good with the spontaneous recovery being permanent. The hypothesis of a neuropraxia-type injury seems most likely in this case [4,7,14].

But how can 70% of median nerve injuries be attributed to damage done to only one of its branches, the AIN, when it emerges distally to the fracture site?

Some authors [23,24] have explored this paradox and hypothesized that the median nerve's AIN fascicles across from the fracture site are bruised. However, no specific anatomical studies have looked at the injury mechanisms. The goal of this cadaver study was to describe the trajectory of the AIN to get a better understanding of how it is injured.

## Material and methods

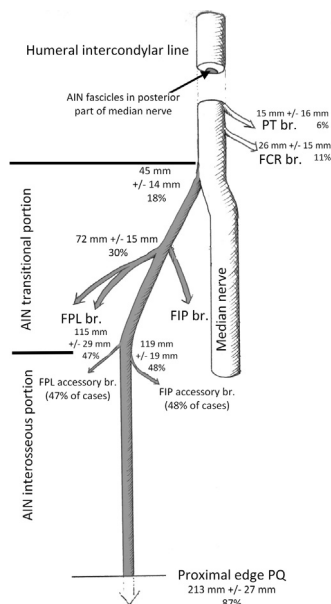
Our study consisted of dissecting 35 cadaver specimens, 27 that were freshly thawed after freezing and eight that were formalin preserved. Each dissection was performed with 4.3 × magnification surgical loupes.

The same approach to the site was used each time. After removing the skin, the median nerve and humeral artery at the upper portion of the pronator teres (PT) were identified. After cutting the distal tendons of the palmaris longus (PL) and flexor carpi radialis (FCR) muscles, we located and inventoried the muscle branches destined to the superficial compartment muscles (PT, FCR, PL). We then located the median nerve under the flexor digitorum superficialis (FDS), which allowed us to cut and reflect the PT muscle. This allowed us to divide the individual muscle branches destined to the FDS muscle. After the FDS was fully opened, the AIN stemming from the median nerve was identified by following it up to the pronator quadratus (PQ) muscle. The muscle branches of the AIN destined to the FPL and FDP muscles were separated into individual branches.

For each muscle branch identified, the location where it arose from and penetrated into the muscle body was measured in millimeters from the humeral intercondylar line, which was used as a reference point. All the distances were expressed as a percentage relative to forearm length, which was defined as the distance between the humeral intercondylar line and the radial styloid process.

With four specimens, we performed a retrograde intra-neural dissection of the AIN fascicles within the median nerve, from the point where it arose up to the elbow joint.

In two specimens, all the muscles and fascia were resected until the bone was reached, except for the median nerve and AIN. We performed a distal humerus osteotomy above the humeral intercondylar line to reproduce a supracondylar fracture. The goal was to analyze the behavior of,



**Figure 1** Drawing showing the distances at which the various muscle branches arise from the median nerve and the anterior interosseous nerve. Each value is given in mm and as a percentage of forearm length. The standard deviation of this value is given in mm. PT: pronator teres; FCR: flexor carpi radialis; FPL: flexor pollicis longus; FIP: flexor indicis profundus; PQ: pronator quadratus.

and the relationship between, the median nerve and AIN when the fracture fragments are displaced.

## Results

As summarized in Fig. 1, the median nerve gives off muscle branches destined to the PT muscle at  $15 \pm 16$  mm from the humeral intercondylar line (6% of the forearm length) and to the FCR muscle at  $26 \pm 15$  mm (11%). The branch destined to the FRC muscle arose from the posteromedial portion of the nerve. The AIN arose from the posterior portion of the median nerve at  $45 \pm 13.6$  mm (18% of forearm length). When the median nerve was dissected, the AIN fascicles were always located posteriorly before emerging.

Distal to where it arose, the AIN had two portions. One was transitional, proximal and free-moving, located from the AIN's median nerve origin point up to where it comes into contact with the interosseous membrane. The other was distal and interosseous, and corresponded to the portion of the nerve from where it is appended to the interosseous membrane up until it penetrates into the PQ muscle.

### Transitional portion

This originated at  $45 \pm 13.6$  mm (18% of forearm length) and extended from where it arose from the AIN to where it entered into the interosseous space (corresponding to the start of the apposition of the nerve onto the interosseous membrane) at  $117 \pm 17$  mm (47% of forearm length). This portion was free to move and had no fibrous attachments.

Almost all of the motor branches of the AIN arose from this portion.

- One main branch systematically went to the flexor indicis profundus (FIP) muscle at  $72 \pm 12$  mm, thus 30%. This was always the largest of the branches destined to this muscle. In 55% of cases, the AIN gave off branches to the remainder of the FDP, either through another independent branch or by branching off from the main branch.
- Two main branches for the FPL muscle at  $72 \pm 15$  mm (30%), one going in front of the FPL muscle body and the other behind it. These either originated from a common trunk (83% of cases) or arose from the AIN, independent of each other.
- Gantzer's muscle (accessory head to FPL), which is not always present (18% in this series), received a branch arising at  $60 \pm 15$  mm (24%).
- Martin Gruber anastomosis: this median-ulnar motor nerve anastomosis was found in 40% of specimens. When present, it originated either directly from the AIN (63% of specimens) or from the branch destined to the FIP muscle (27% of specimens).

### Interosseous portion

This portion started at the AIN entry point into the interosseous space at  $117 \pm 17$  mm (47%) and extended up to where it ended in the PQ muscle at  $213 \pm 27$  mm (87%). In 45% of specimens, no muscle branches arose from this portion of the nerve. In 55% of specimens, the nerve gave off a very small accessory branch to the FPL and/or FIP at  $115 \pm 29$  mm (47%) and  $119 \pm 19$  mm (48%), respectively.

In three specimens, the AIN had an intramuscular trajectory inside the FPL. It passed under the PQ muscle at  $184 \pm 19$  mm (75%) and innervated the PQ with an average of 3.5 branches. The joint branch for the wrist was not always found, probably because of its miniscule size.

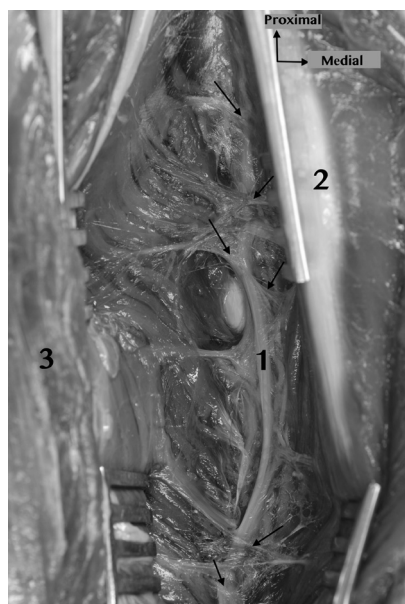
In every specimen, this portion of the entire length of the AIN was attached to the interosseous membrane by multiple fibrous bands, which did not allow it to move or adapt (Fig. 2).

The simulation of the posterior displacement of the fracture on two specimens via an osteotomy found greater tension being placed on the AIN relative to the median nerve because of its fixed interosseous portion. The median nerve was trapped in the coronoid fossa of the humerus during posterolateral displacements, but was not trapped during posteromedial displacements (Fig. 3).

## Discussion

Our study confirmed the descriptions of the posterior location of AIN fascicles in the median nerve at the elbow, up until it emerged from this nerve [25,26]. In other published studies, the AIN arose at 50 to 80 mm from the humeral intercondylar line [25,27–29]. Our average value of 45 mm (18% of forearm length) was close to the published value. There was relatively little variability in this point of origin (standard deviation less than 14 mm).

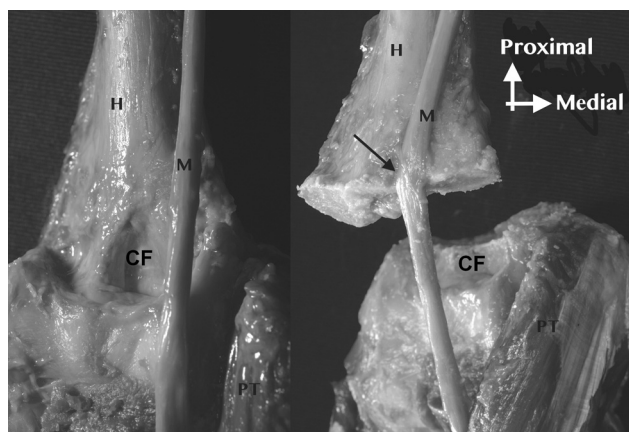
The muscles innervated by the AIN were identical to published data [30–32], including the inconsistent Gantzer



**Figure 2** Anterior view of the right forearm showing the interosseous portion of the anterior interosseous nerve (AIN) (1) between the flexor indicis profundus (FIP) (2) and the flexor pollicis longus (FPL) (3), along with its multiple fibrous attachments (black arrows).

muscle. Lepage et al. [30] found a single branch in all specimens for the FPL and in 94% of cases for the FPD. We found more than one branch for these two muscles in 47% and 48% of cases, respectively. This difference could be explained by the small size of these branches, which makes them hard to find.

This nerve is more often involved during supracondylar fracture with posterior fragment displacement. We hypothesize that the AIN is not being directly bruised by the fracture edge, since it arises distal to the fracture site. Some of the proposed mechanisms relate to either aponeurotic arcades



**Figure 3** Right forearm that has been dissected to leave only the humerus (H), its coronoid fossa (CF), the median nerve (M) and the pronator teres (PT) muscle. Once an osteotomy was performed to reproduce a supracondylar elbow fracture, the median nerve was trapped in the coronoid fossa when the distal fragment was displaced (arrow).

at the PT and FDS muscles or signs of intranerve ischemia [24,33]. However, these two mechanisms cannot in themselves explain the isolated AIN palsy because the median nerve would also have to be injured. Spinner and Schreider [23] and Geutjen [24] proposed that the posterior part of the median nerve was being bruised at the fracture site. Based on other cadaver studies [26,34,35], it was hypothesized that the AIN fascicles are the first to be bruised by the proximal fragment, especially since the palsy occurs in Type III and IV fractures [2,3], thus secondary to posterior displacements.

This explanation was based on modeling of the injury on cadaver specimens but seemed inadequate to us. This led to us to suggest that a combination of events leads to an isolated AIN injury secondary to this fracture.

- First, direct contusion by the free edge of the proximal fracture fragment of the AIN fascicles in the portion where the AIN is still enclosed in the median nerve before arising from it (Fig. 3).
- Then the coronoid fossa of the humerus catches the median nerve during posterolateral fracture fragment displacement and makes this posterior contusion to the median nerve worse (Fig. 3).
- Stretching of the shorter, free portion of the AIN, seems to be made worse by the interosseous part of the AIN being attached along the interosseous membrane. Thus the AIN has a limited capacity to withstand any stretch injury because its longest part is fixed. Since the median nerve is free-moving, it could theoretically withstand more stretching during the fragment displacements without being injured.

## Conclusion

AIN palsy secondary to supracondylar elbow fracture in children is not likely due only to bruising of the posterior part of the median nerve by the proximal fragment. This relatively dated cadaver-derived observation cannot by itself explain the selective injury to the AIN. Our study allowed us to shed light on a more complex series of event, which can be explained by the anatomy and relative location of the AIN.

## Disclosure of interest

The authors declare that they have no conflicts of interest concerning this article.

## References

- [1] Dormans JP, Squillante R, Sharf H. Acute neurovascular complications with supracondylar humerus fractures in children. *J Hand Surg [Am]* 1995;20:1–4.
- [2] Lagrange J, Rigault P. Fractures supra-condyliennes. *Rev Chir Orthop* 1962;48:337–414.
- [3] Lagrange J, Rigault P. Traitement des fractures supra-condyliennes de l'enfant. *Presse Med* 1970;78:2382.
- [4] Louahem DM, Nebunescu A, Canavese F, Dimeglio A. Neurovascular complications and severe displacement in supracondylar



- humerus fractures in children: defensive or offensive strategy? *J Pediatr Orthop B* 2006;15:51–7.
- [5] Duteille F, Amara B, Dautel G, Merle M. Isolated palsy of the flexor pollicis longus in anterior interosseous nerve syndrome. *Rev Chir Orthop* 2000;86:306–9.
- [6] Culp RW, Osterman AL, Davidson RS, Skirven T, Bora Jr FW. Neural injuries associated with supracondylar fractures of the humerus in children. *J Bone Joint Surg Am* 1990;72:1211–5.
- [7] Ramachandran M, Birch R, Eastwood DM. Clinical outcome of nerve injuries associated with supracondylar fractures of the humerus in children: the experience of a specialist referral centre. *J Bone Joint Surg Br* 2006;88:90–4.
- [8] Mangini U. Flexor pollicis longus muscle. Its morphology and clinical significance. *J Bone Joint Surg Am* 1960;42-A:467–70.
- [9] Farber JS, Bryan RS. The anterior interosseous nerve syndrome. *J Bone Joint Surg Am* 1968;50:521–3.
- [10] Fearn CB, Goodfellow JW. Anterior interosseous nerve palsy. *J Bone Joint Surg Br* 1965;47:91–3.
- [11] Hollinshead WH. *Anatomy for surgeons*. 2d ed. New York: Hoeber Medical Division; 1968.
- [12] Kiloh LG, Nevin S. Isolated neuritis of the anterior interosseous nerve. *Br Med J* 1952;1:850–1.
- [13] Parsonage MJ, Turner JW. Neuralgic amyotrophy; the shoulder-girdle syndrome. *Lancet* 1948;1:973–8.
- [14] Warren JD. Anterior interosseous nerve palsy as a complication of forearm fractures. *J Bone Joint Surg Br* 1963;45:511–2.
- [15] Hartz CR, Linscheid RL, Gramse RR, Daube JR. The pronator teres syndrome: compressive neuropathy of the median nerve. *J Bone Joint Surg Am* 1981;63:885–90.
- [16] O'Neill DB, Zarins B, Gelberman RH, Keating TM, Louis D. Compression of the anterior interosseous nerve after use of a sling for dislocation of the acromioclavicular joint. A report of two cases. *J Bone Joint Surg Am* 1990;72:1100–2.
- [17] Sharrard WJ. Anterior interosseous neuritis. Report of a case. *J Bone Joint Surg Br* 1968;50:804–5.
- [18] Vichare NA. Spontaneous paralysis of the anterior interosseous nerve. *J Bone Joint Surg Br* 1968;50:806–8.
- [19] Miller-Breslow A, Terrono A, Millender LH. Nonoperative treatment of anterior interosseous nerve paralysis. *J Hand Surg [Am]* 1990;15:493–6.
- [20] Sood MK, Burke FD. Anterior interosseous nerve palsy. A review of 16 cases. *J Hand Surg Br* 1997;22:64–8.
- [21] Lyons ST, Quinn M, Stanitski CL. Neurovascular injuries in type III humeral supracondylar fractures in children. *Clin Orthop Relat Res* 2000;376:62–7.
- [22] Lipscomb PR. Vascular and neural complications in supracondylar fractures of the humerus in children. *J Bone Joint Surg Am* 1955;37-A:487–92.
- [23] Spinner M, Schreiber SN. Anterior interosseous-nerve paralysis as a complication of supracondylar fractures of the humerus in children. *J Bone Joint Surg Am* 1969;51:1584–90.
- [24] Geutjens GG. Ischaemic anterior interosseous nerve injuries following supracondylar fractures of the humerus in children. *Injury* 1995;26:343–4.
- [25] Canovas F, Moulleron P, Bonnel F. Biometry of the muscular branches of the median nerve to the forearm. *Clin Anat* 1998;11:239–45.
- [26] Sunderland S. The intraneural topography of the radial, median and ulnar nerves. *Brain* 1945;68:243–99.
- [27] Spinner M. The anterior interosseous-nerve syndrome, with special attention to its variations. *J Bone Joint Surg Am* 1970;52:84–94.
- [28] Ukrit A, Leechavengvongs S, Malungpaishrope K, Uerpaiojkit C, Chongthammakun S, Witoonchart K. Nerve transfer for wrist extension using nerve to flexor digitorum superficialis in cervical 5, 6, and 7 root avulsions: anatomic study and report of two cases. *J Hand Surg [Am]* 2009;34:1659–66.
- [29] Linell EA. The distribution of nerves in the upper limb, with reference to variabilities and their clinical significance. *J Anat* 1921;55:79–112.
- [30] Lepage D, Parratte B, Tatu L, Vuiller F, Monnier G. Extra- and intramuscular nerve supply of the muscles of the anterior antebrachial compartment: applications for selective neurotomy and for botulinum toxin injection. *Surg Radiol Anat* 2005;27:420–30.
- [31] Sunderland S. *Nerves and nerve injuries*. 2d ed. Edinburgh; New York: Churchill Livingstone ed; distributed by Longman; 1978.
- [32] Tabib W, Aboufarah F, Asselineau A. Compression of the anterior interosseous nerve by Gantzer's muscle. *Chir Main* 2001;20:241–6.
- [33] Combalia A, Suso S. Ischemic anterior interosseous nerve injuries following supracondylar fractures of the humerus in children. *Injury* 1996;27:530.
- [34] Jabaley ME, Wallace WH, Heckler FR. Internal topography of major nerves of the forearm and hand: a current view. *J Hand Surg [Am]* 1980;5:1–18.
- [35] Gunther SF, DiPasquale D, Martin R. The internal anatomy of the median nerve in the region of the elbow. *J Hand Surg [Am]* 1992;17:648–56.