

Cone Reconstruction of the Tricuspid Valve for Ebstein's Anomaly: Anatomic Repair

Joseph A. Dearani, MD, Emile Bacha, MD, and José Pedro da Silva, MD

Ebstein's anomaly is a congenital malformation of the right ventricle and tricuspid valve that is characterized by multiple features that can exhibit an infinite spectrum of malformation.¹ Abnormalities of the tricuspid valve and right ventricle include the following: (1) adherence of the tricuspid leaflets to the underlying myocardium (failure of delamination); (2) anterior and apical rotational displacement of the functional annulus (septal > posterior > anterior leaflet); (3) dilation of the "atrialized" portion of the right ventricle with variable degrees of hypertrophy and thinning of the wall; (4) redundancy, fenestrations, and tethering of the anterior leaflet; (5) dilation of the right atrioventricular junction (the true tricuspid annulus); and (6) variable ventricular myocardial dysfunction. These anatomical and functional abnormalities cause important tricuspid regurgitation, which results in right atrial and right ventricular dilation and atrial and ventricular arrhythmias.

Numerous techniques of repair have been described since the first report of Hunter and Lillehei.² This is not surprising, because each heart with Ebstein's anomaly is different, and there is infinite variability that can occur with all of the above-mentioned characteristics. The cone reconstruction as described by Dr. da Silva and coworkers³ is different than previous valvuloplasty techniques in that it is closest to an "anatomic repair." The end result of the cone reconstruction includes 360° of tricuspid leaflet tissue surrounding the right atrioventricular junction. This allows leaflet tissue to coapt with leaflet tissue, similar to what occurs with normal tricuspid valve anatomy. In addition, the reconstructed tricuspid valve is reattached at the true tricuspid valve annulus (atrio-

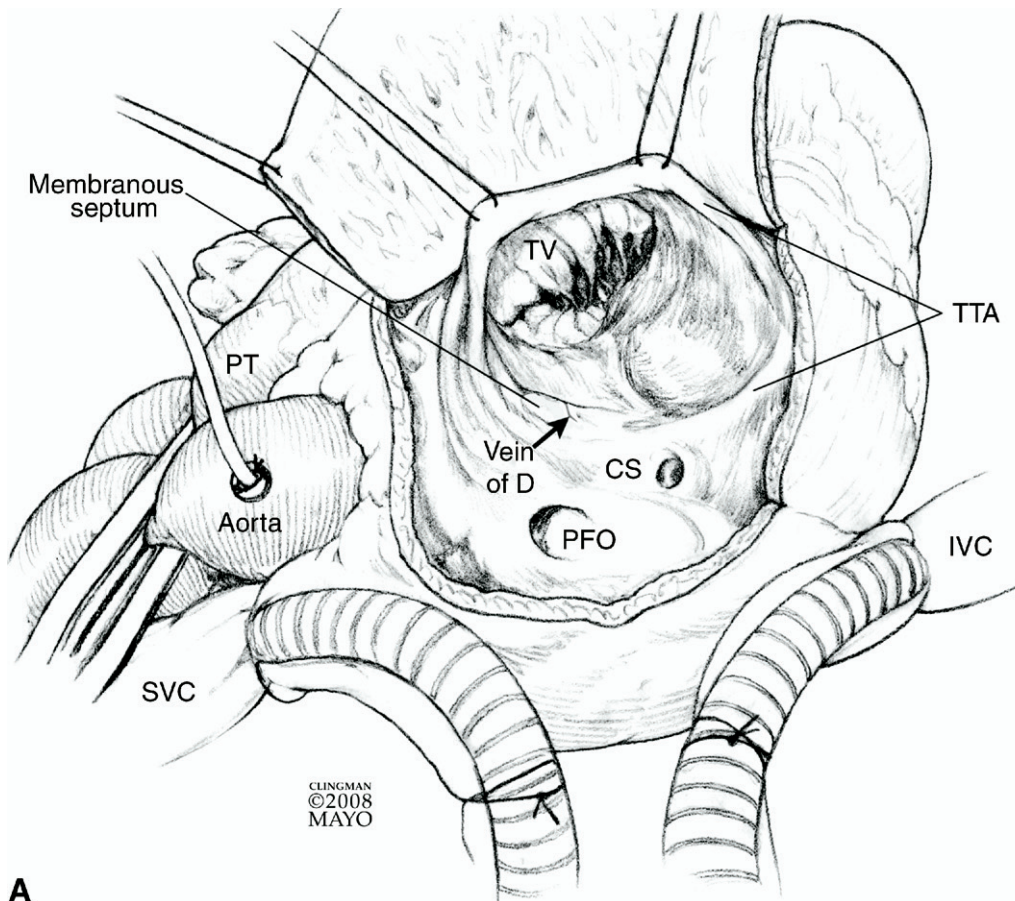
ventricular junction) so the hinge point of the valve is now in a normal anatomical location. Thinned, transparent atrialized right ventricle is plicated so any areas of right ventricular dyskinesia are eliminated. Redundant right atrium is excised so the size of the right atrium is closer to normal. With the exception of some persistent right ventricular dilation in the early postoperative period, the cone reconstruction restores the appearance of normal tricuspid valve anatomy and function more than any previously described technique. Because this technique can be applied to the wide variety of anatomical variations encountered with Ebstein's anomaly, we have adopted this repair technique when approaching patients with this malformation.

Indications for operation have included symptoms, deteriorating exercise capacity, New York Heart Association functional class III, IV heart failure, cyanosis (oxygen saturation <90%), paradoxical embolism, progressive cardiomegaly on chest X-ray (computed tomographic ratio >0.6), progressive right ventricular enlargement on echocardiography, and onset or progression of atrial or ventricular arrhythmias. Observation has been recommended for asymptomatic patients with low normal exercise tolerance, no right-to-left shunting, and only mild cardiomegaly. With the introduction of the cone repair and its excellent early to mid-term results,³ consideration to earlier operative intervention may be given because this procedure can be performed with low risk and provides a near anatomic repair.

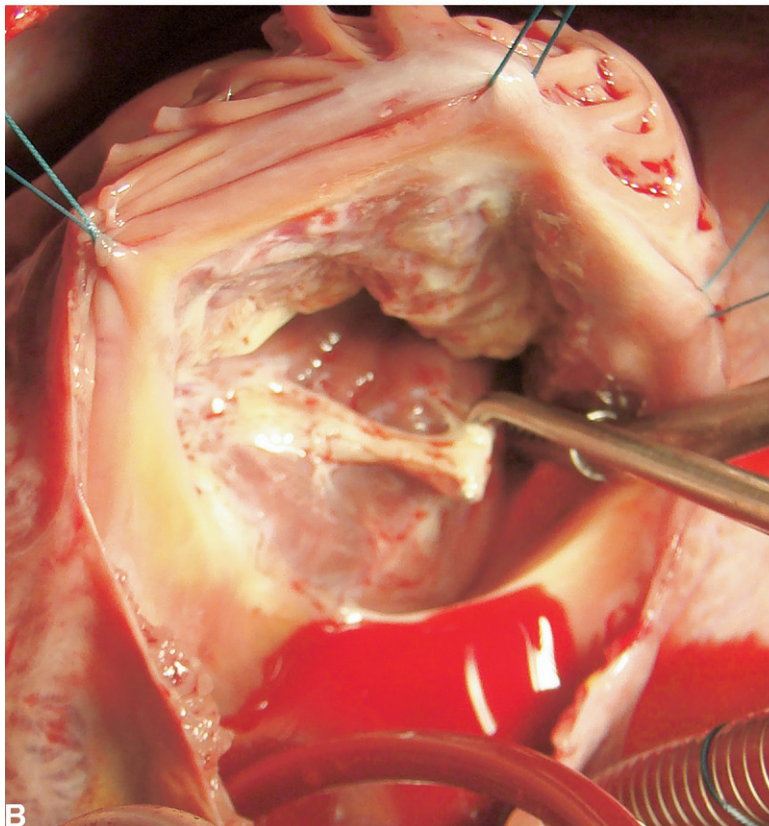
Relative contraindications to the cone reconstruction include older age (>50 years), moderate pulmonary hypertension, significant left ventricular dysfunction (ejection fraction ≤30%), complete failure of delamination of septal and inferior leaflets with poor delamination of the anterior leaflet (ie, <50% delamination of the anterior leaflet), severe right ventricular enlargement, and severe dilation of the right atrioventricular junction (true tricuspid annulus).

Division of Cardiovascular Surgery, Mayo Clinic, Rochester, Minnesota.
Address reprint requests to Joseph A. Dearani, MD, Division of Cardiovascular Surgery, Mayo Clinic, 200 First Street SW, Rochester, MN 55905.
E-mail: dearani.joseph@mayo.edu

Operative Technique



A



B

Figure 1 (A) Operation is performed via median sternotomy. Intraoperative transesophageal echocardiogram is used routinely. Standard cardiopulmonary bypass techniques with aortic and bicaval cannulation is utilized. Mild systemic hypothermia (32-34°C) and cardioplegic arrest with aortic cross-clamping and cold blood antegrade cardioplegia (30 mL/kg) is used. Asystolic arrest is maintained with subsequent doses (10-15 mL/kg) of antegrade blood cardioplegia given at 20- to 30-minute intervals during the cross-clamp period. The main pulmonary artery can be also included with the aortic cross-clamp as it will facilitate examination of the tricuspid valve after repair when the right ventricle is filled with saline via a bulb syringe.

A standard oblique right atriotomy is performed with an incision from the right atrial appendage toward the inferior vena cava that is parallel to the atrioventricular groove. The left heart is vented with a catheter inserted across the patent foramen ovale or atrial septal defect. Exposure of the tricuspid annulus is facilitated by stay sutures placed in the true tricuspid annulus at approximately 10:00 and 2:00. The tricuspid valve anatomy is examined using a blunt nerve hook and the atrialized right ventricle is evaluated. The membranous septum and atrioventricular node are marked by a small vein (vein of D) and fatty tissue that is characteristically present. CS, coronary sinus; IVC, inferior vena cava; PFO, patent foramen ovale; PT, pulmonary trunk; SVC, superior vena cava; TTA, true tricuspid valve annulus. (Copyrighted and used with permission of Mayo Foundation for Medical Education and Research.) (B) Intraoperative photo demonstrating valve inspection; the blunt nerve hook has engaged the displaced, diminutive septal leaflet.

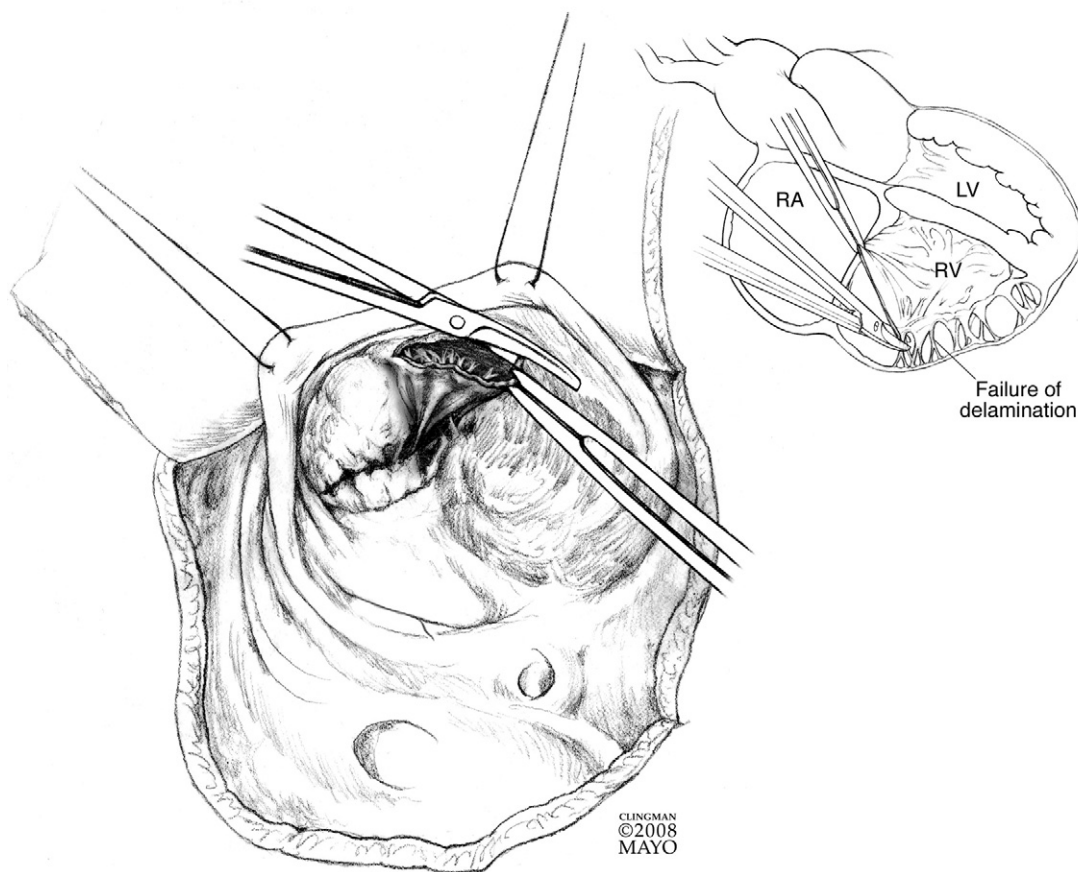


Figure 2 The first incision is made with a no. 15 blade in the anterior leaflet at 12:00; the incision is a few millimeters away from the true annulus. The incision is then extended rightward in a clockwise fashion using a scissors. It is common for there to be a true space between the anterior leaflet and the right ventricle in this region (ie, normally delaminated leaflet). However, when the transition is met between the anterior and inferior (posterior) leaflets, it is common for there to be failure of delamination (inset) resulting in fibrous and muscular attachments between the leaflet and myocardium. The diagram demonstrates the scissors approaching the area where there is some adherence of leaflet tissue to the underlying myocardium. The dissection continues in a way that a portion of distal anterior leaflet and some inferior leaflet tissue is “surgically delaminated.” The most important aspect of this surgical delamination is to incise all fibrous and muscular attachments between the body of the leaflet and the right ventricular myocardium, but to maintain intact all fibrous and (and occasionally muscular) attachments of the leading edge of the leaflet to the underlying myocardium. Importantly, do not disrupt chordal attachments to the leading edge of any leaflet. LV, left ventricle; RA, right atrium; RV, right ventricle. (Copyrighted and used with permission of Mayo Foundation for Medical Education and Research.)

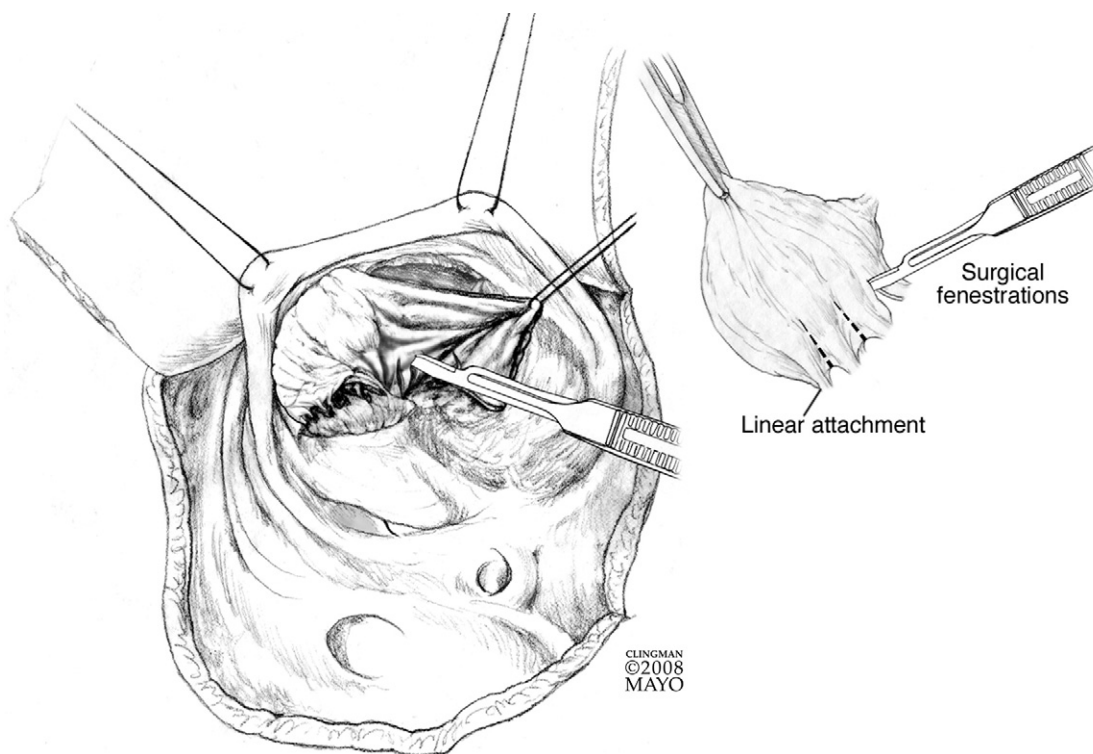


Figure 3 A 5-0 monofilament stay suture is placed in the leaflet tissue at approximately 2:00. At this juncture, it is important to examine the anatomy of the leaflet from both sides. Specifically, the edge of the leaflet is carefully examined to see if there are individual chordal attachments present or whether the leading edge is attached directly to the myocardium—this has been referred to as a “linear attachment.”^{1,4} When a linear attachment is present (inset), it is treated by making fenestrations in the distal aspect of the leaflet—the equivalent of making natural “neo-chordae.” This allows blood to enter the right ventricular cavity. It is important to make these incisions in the leaflet by looking at the leaflet edge from both sides (tricuspid valve orifice side and right ventricular side) to avoid inadvertent injury to the markedly thinned underlying right ventricular myocardium, which can be easily fenestrated. The height of the incisions in the leaflet is typically about one-fourth to one-third the distance from the leaflet edge. It is important to note that this maneuver is not always necessary and is applied only when the edge is “tethered” or “adherent” (linearly attached) to the underlying myocardium. (Copyrighted and used with permission of Mayo Foundation for Medical Education and Research.)

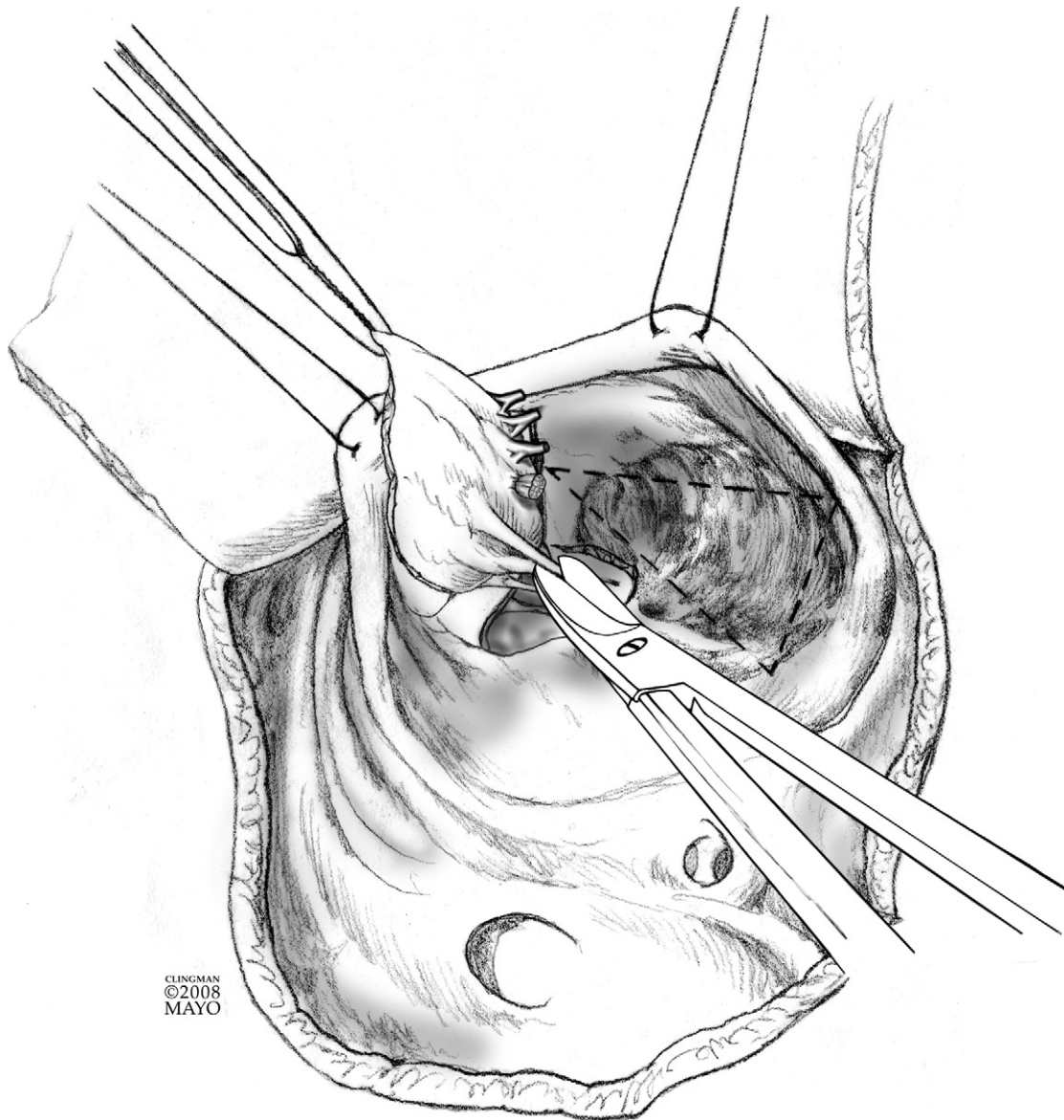


Figure 4 As the anterior and surgically delaminated inferior leaflet is reflected away from the right ventricular myocardium, all fibrous and muscular attachments into the body of the underside of the leaflet are incised as shown with the scissors. It is important to keep all attachments of the leading edge of the leaflet intact; if the edge is linearly attached, then surgical fenestrations are created as depicted earlier. The dotted triangle represents the atrialized right ventricle. (Copyrighted and used with permission of Mayo Foundation for Medical Education and Research.)

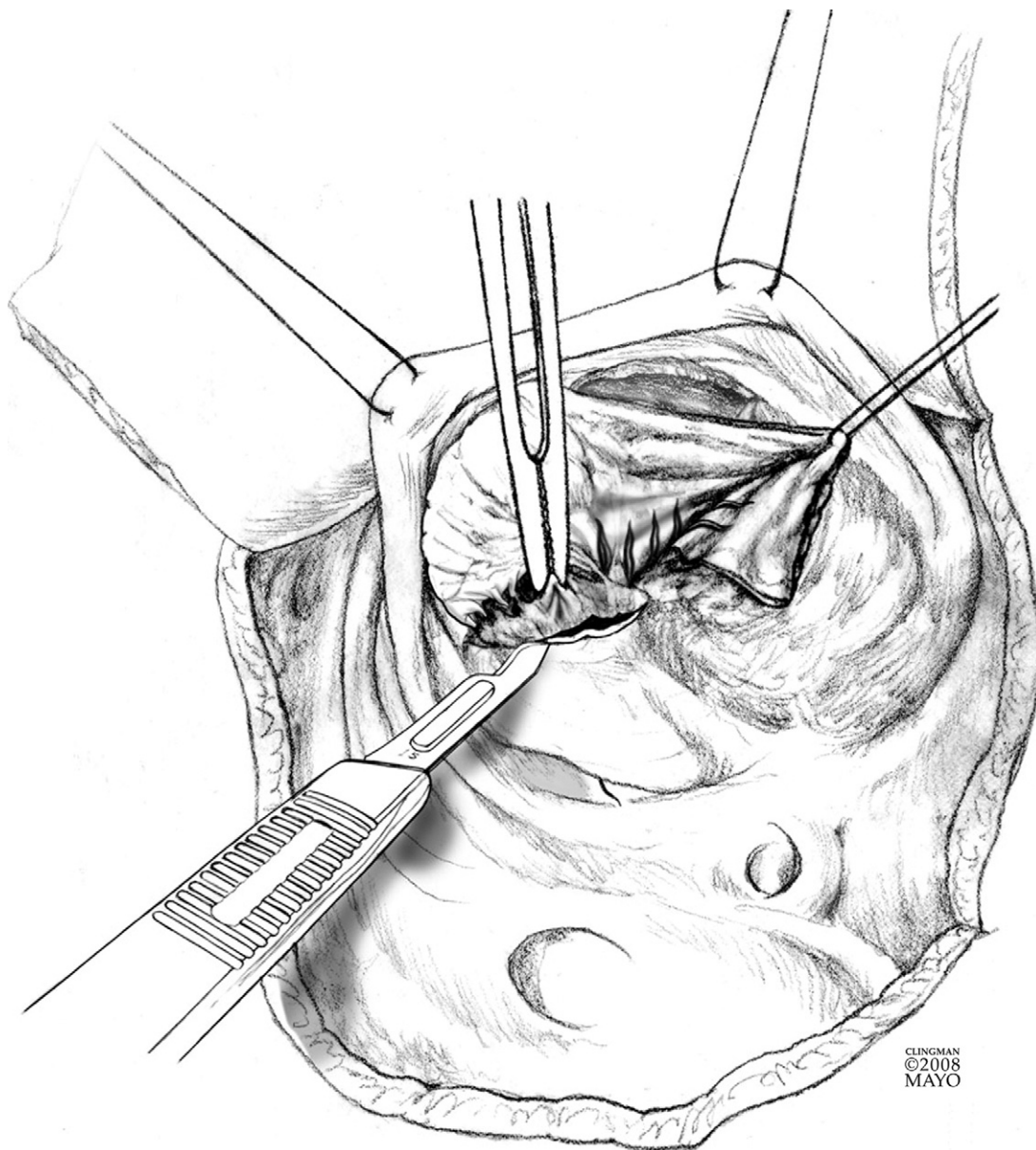


Figure 5 By definition, the septal leaflet is displaced in an apical rotational fashion into the right ventricle. The proximal edge of the leaflet is incised off of the endocardium as shown with a no. 15 blade. (Copyrighted and used with permission of Mayo Foundation for Medical Education and Research.)

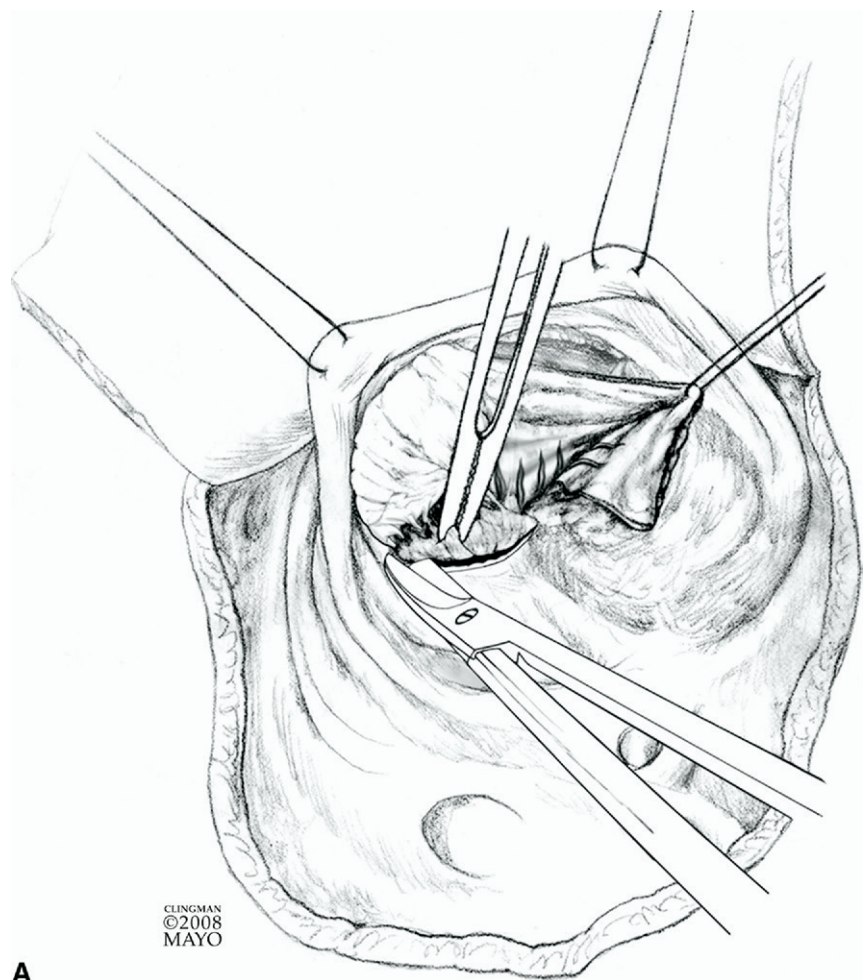
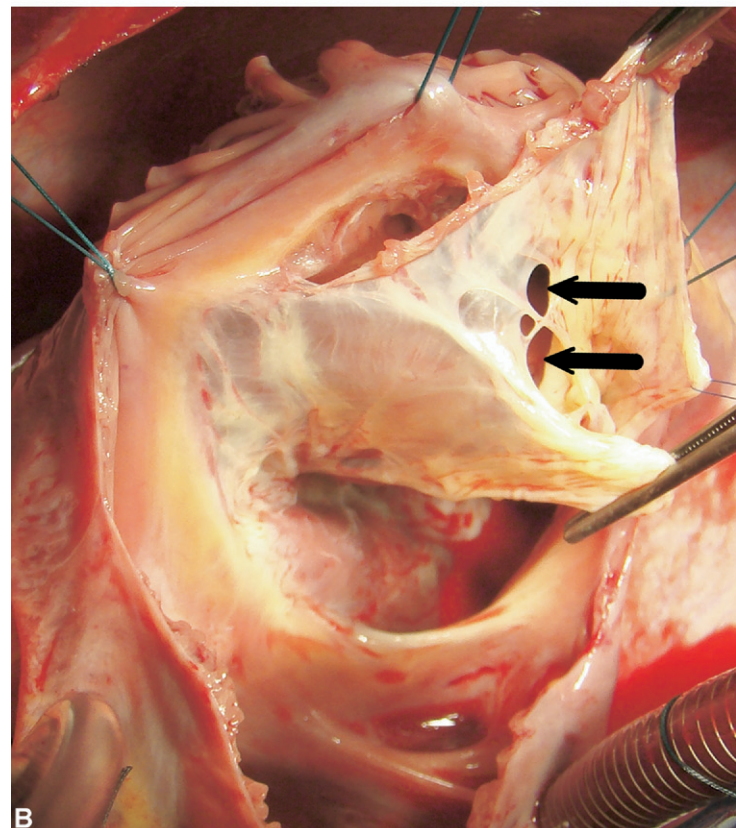


Figure 6 (A) Dissection is continued with a scissors with the goal of taking down all attachments between the septal leaflet and myocardium but preserving all attachments of the leading edge to the endocardium as described above. The dissection should proceed medially all the way to the anteroseptal commissure. The leaflet tissue is typically very fragile and thin in this area. There can be marked variability in the status of the leading edge of the septal leaflet as was described for the anterior and inferior leaflets. If there is a linear attachment, then surgically created fenestrations are also made in this leaflet (not shown). (Copyrighted and used with permission of Mayo Foundation for Medical Education and Research.) (B) Intraoperative photo demonstrating the mobilized anterior and inferior (posterior) leaflets. Natural fenestrations are shown at the junction of the anterior and inferior leaflets (arrows).



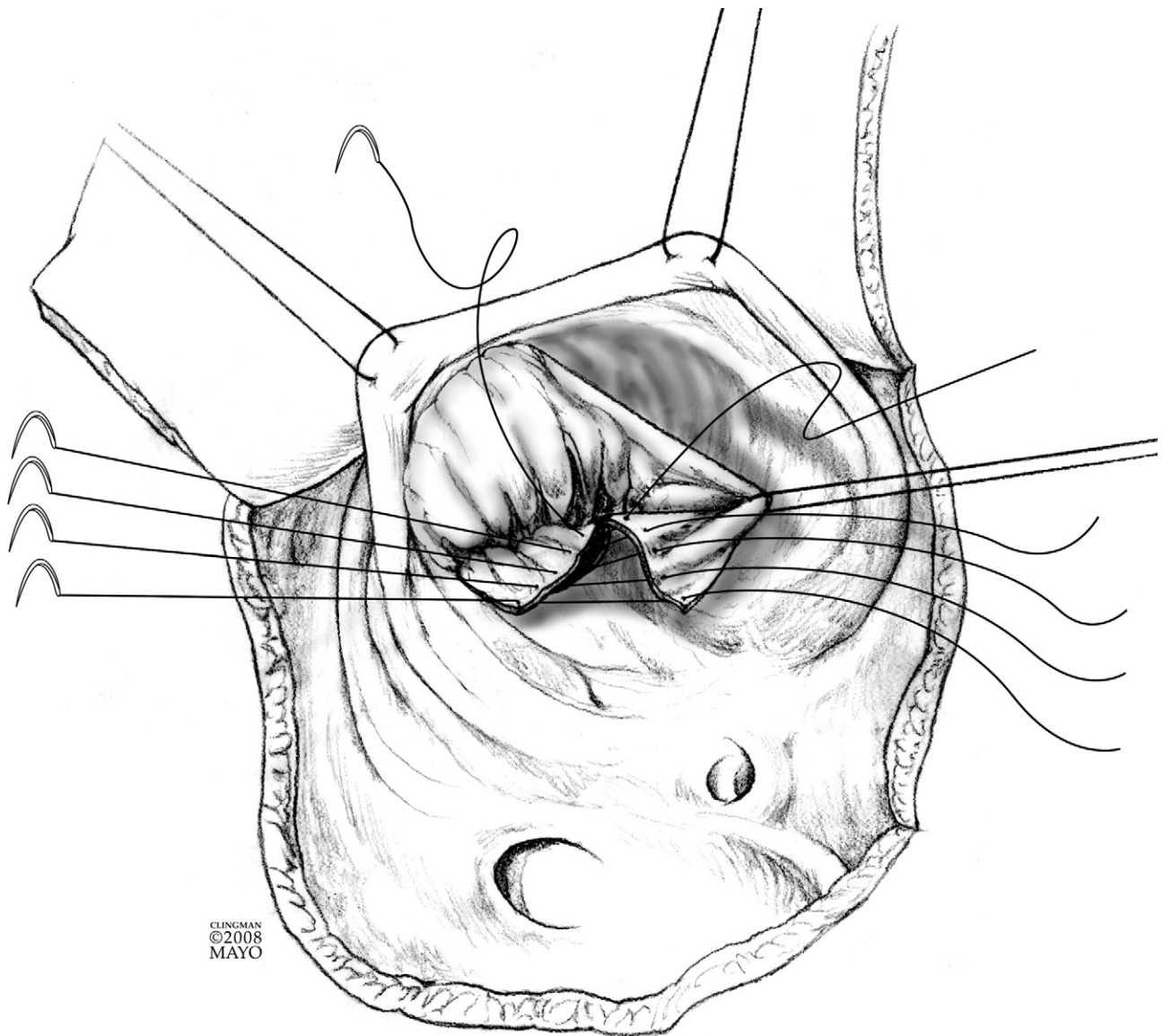


Figure 7 After the anterior, inferior, and septal leaflets have been completely mobilized, the cut edge of the inferior leaflet is rotated clockwise to meet the proximal edge that has been prepared of the septal leaflet. The two are approximated with interrupted 6-0 monofilament sutures completing the cone reconstruction. This results in 360° of leaflet tissue that will make up the new tricuspid valve orifice. (Copyrighted and used with permission of Mayo Foundation for Medical Education and Research.)

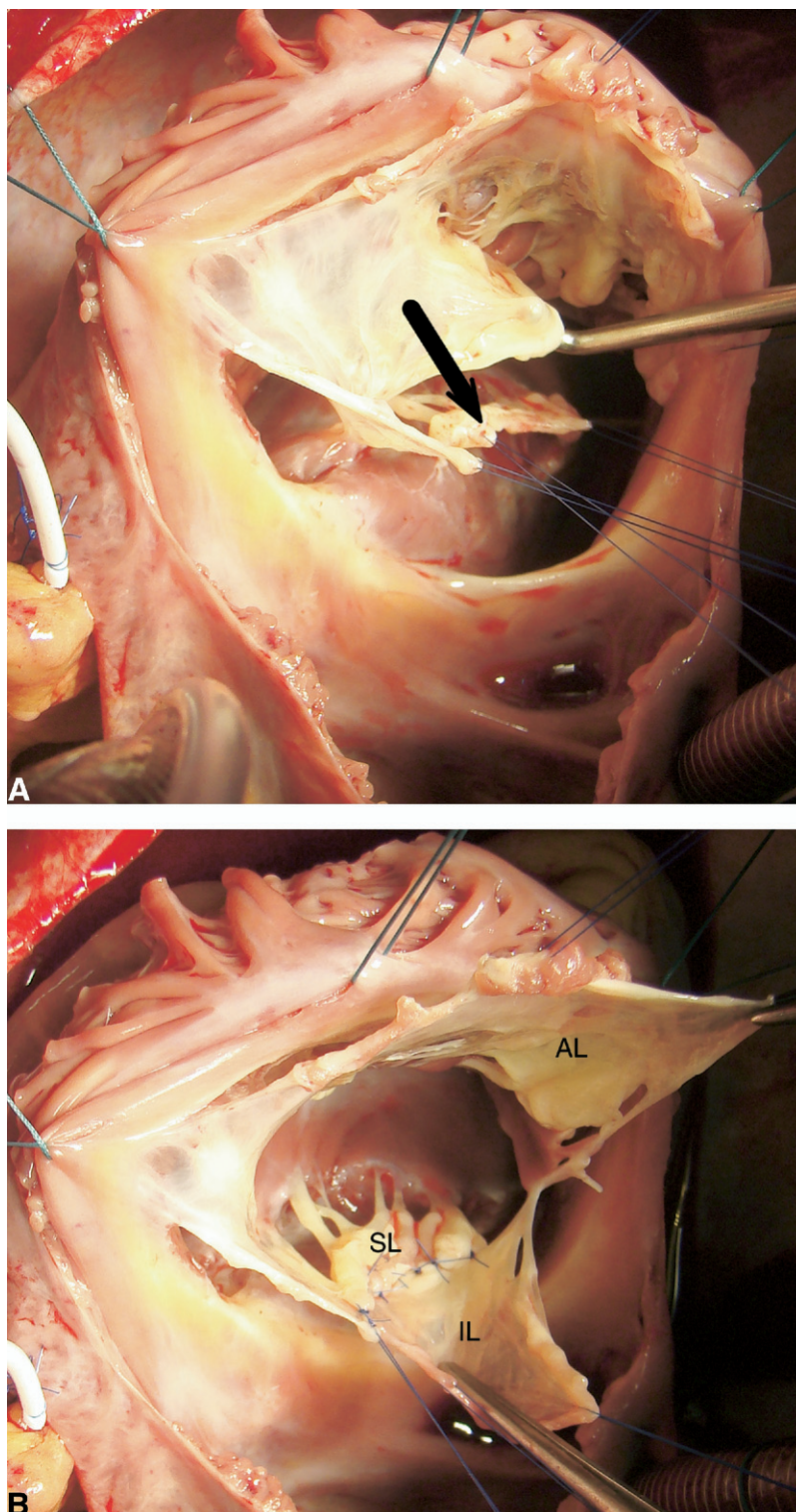
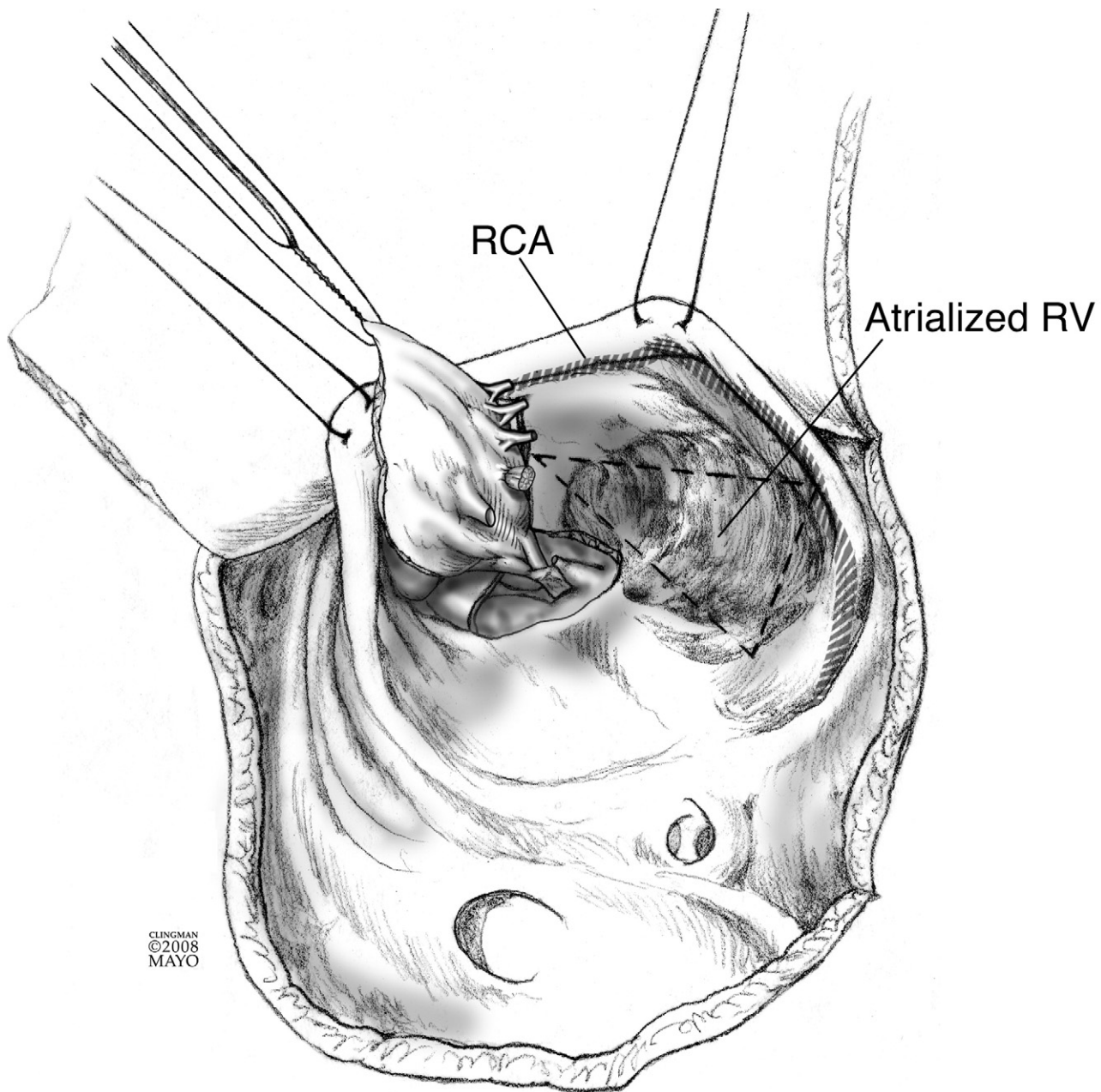


Figure 8 (A) Intraoperative picture showing the mobilized anterior, inferior, and septal leaflets. The arrow is pointing to the diminutive septal leaflet. (B) A portion of the inferior leaflet has been rotated clockwise and sewn to the diminutive septal leaflet, thus increasing the height of the septal leaflet. Fine interrupted monofilament sutures are usually used to avoid distortion of the delicate leaflet tissue. AL, anterior leaflet; IL, inferior leaflet; SL, septal leaflet.



CLINGMAN
©2008
MAYO

Figure 9 After the cone reconstruction is completed, the atrialized right ventricle (RV) is examined to determine if plication is necessary. Note the position of the right coronary artery (RCA) in the true tricuspid valve annulus and keep in mind that there are acute marginal branches of the right coronary artery that can be compromised with plication. (Copyrighted and used with permission of Mayo Foundation for Medical Education and Research.)

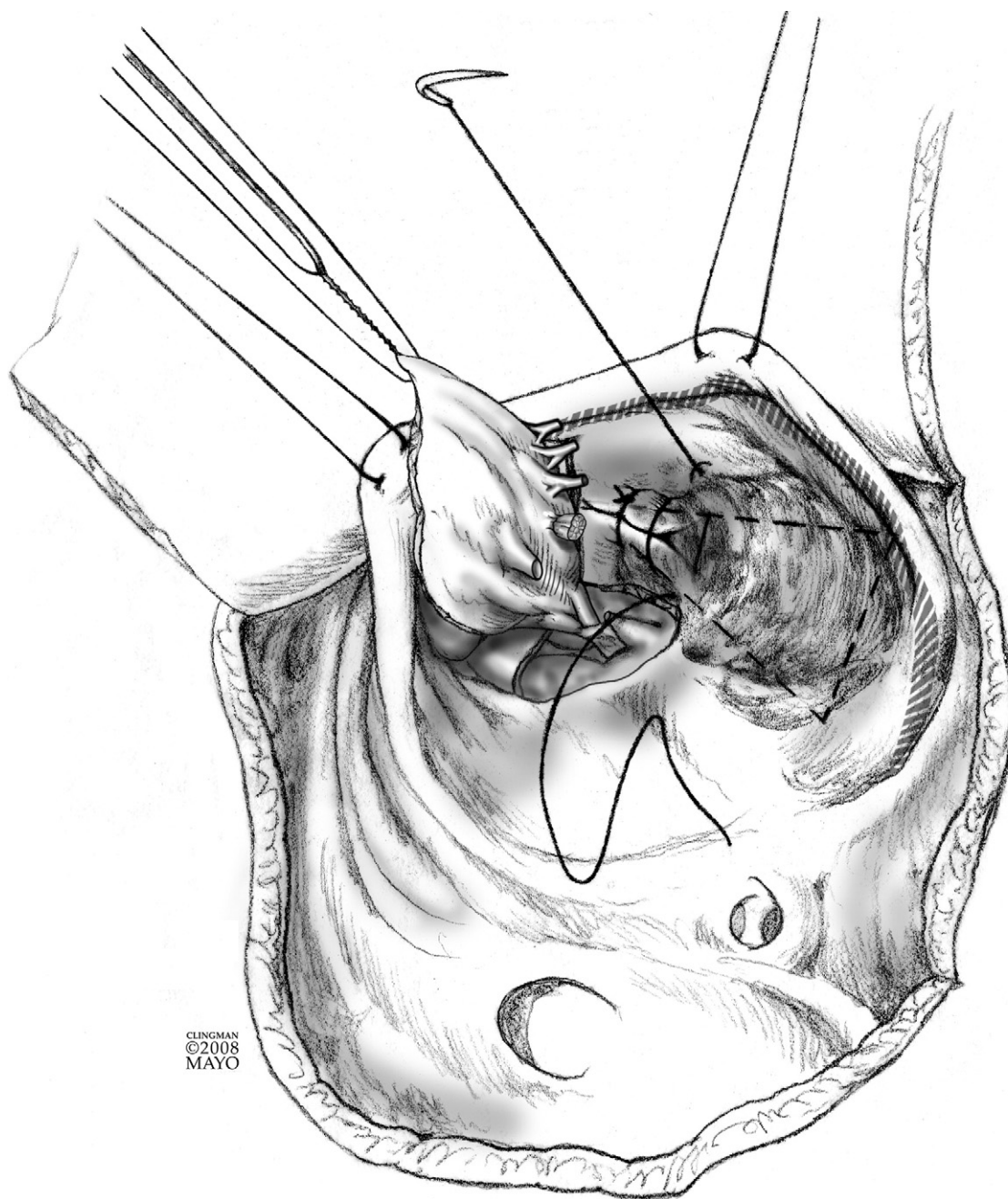
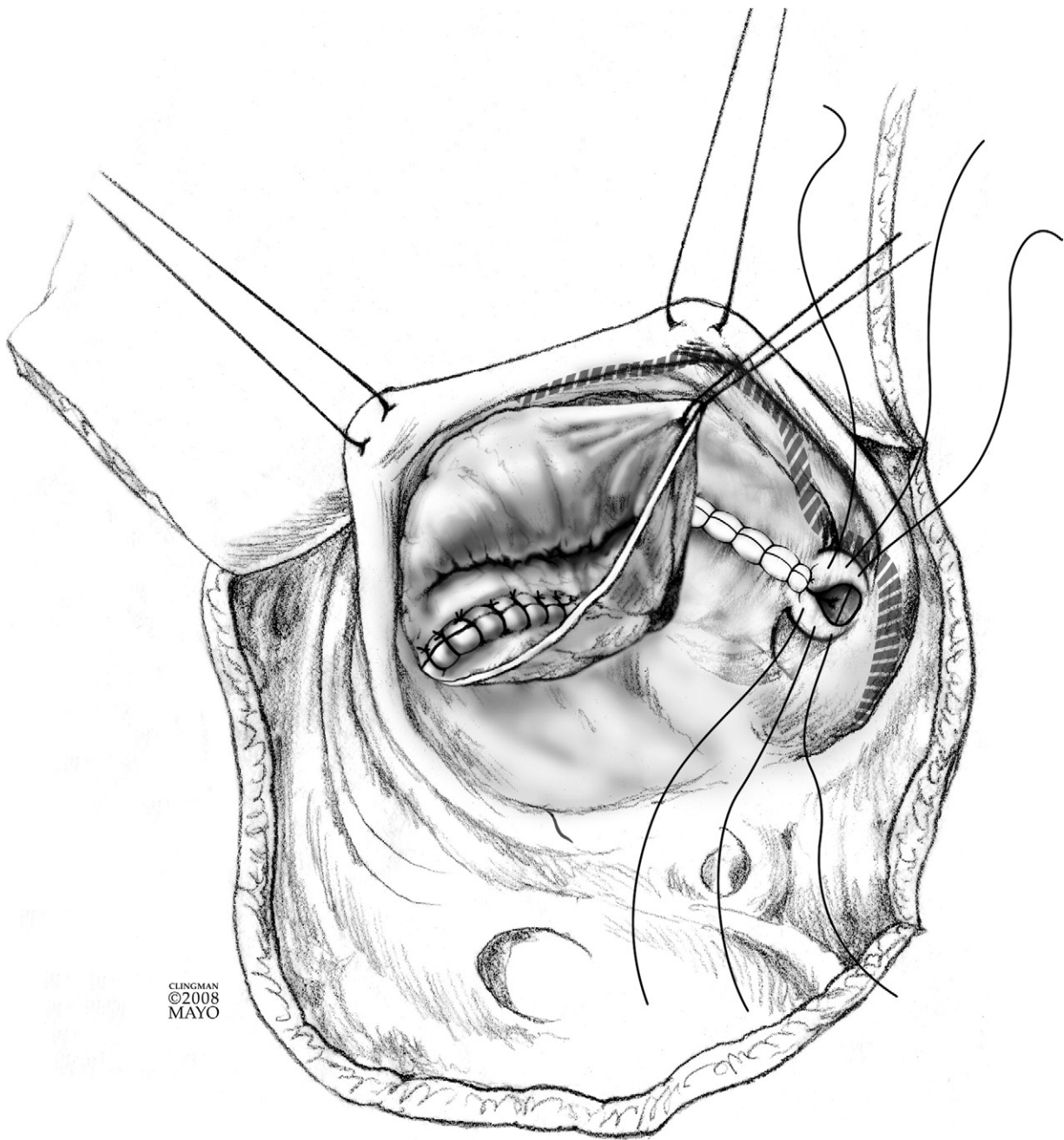


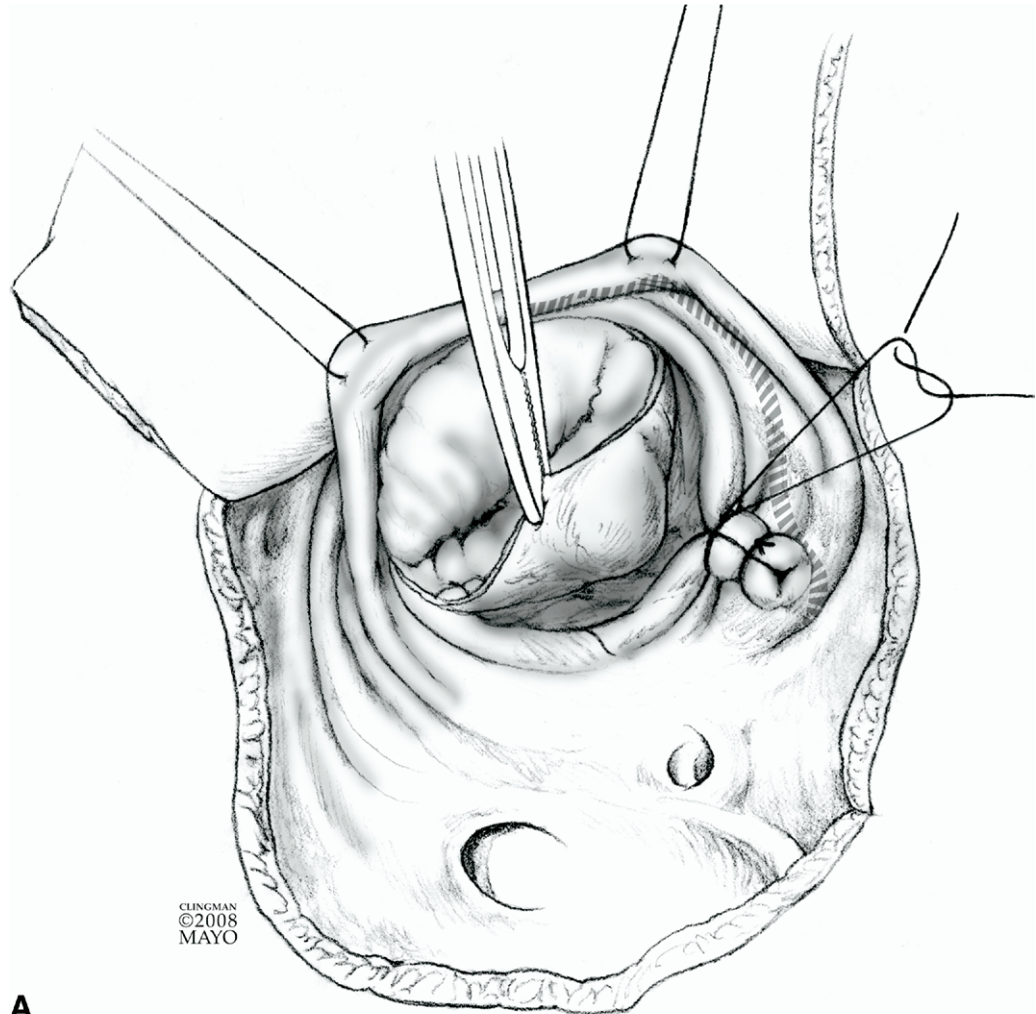
Figure 10 This figure demonstrates the technique for internal plication of the atrialized right ventricle. Monofilament 5-0 is utilized and the suture is begun distally, ie, closest to the apex of the right ventricle. It is important to frequently examine the outside of the inferior wall of the right ventricle to insure that inadvertent compromise of branches of the right coronary artery is avoided. (Copyrighted and used with permission of Mayo Foundation for Medical Education and Research.)



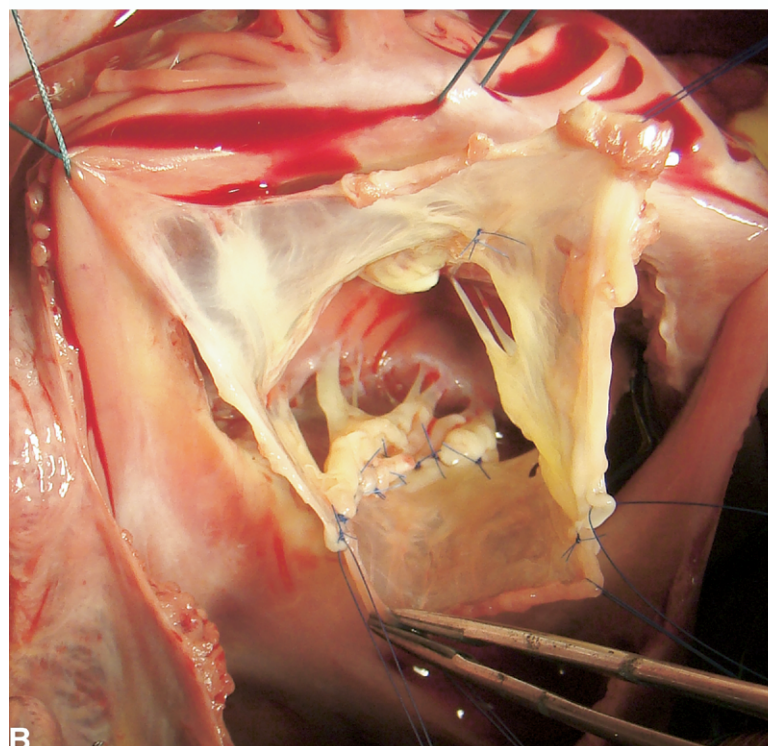
CLINGMAN
©2008
MAYO

Figure 11 The suture line is advanced toward the base of the heart, ie, toward the atrioventricular groove. As the dotted lines of the triangle are effectively approximated, the atrialized RV is excluded. It is important for this suture line to stop approximately 1 cm before reaching the atrioventricular groove to avoid injury or distortion of the right coronary artery. After the sides of the triangle are approximated, the entrance into the excluded atrialized segment of the right ventricle is then closed to eliminate the “blind pouch.” (Copyrighted and used with permission of Mayo Foundation for Medical Education and Research.)

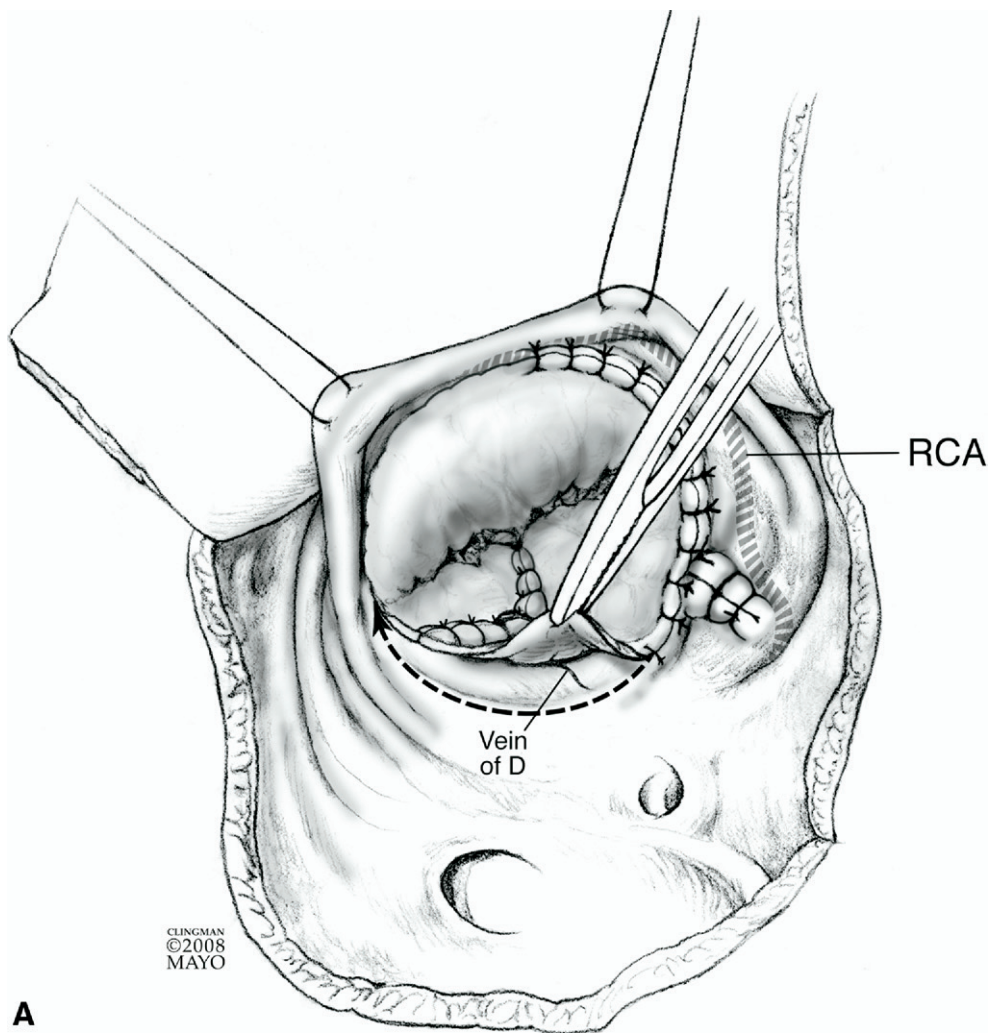
Figure 12 (A) After the plication or resection is completed, the newly constructed tricuspid valve is then reattached at the level of the true tricuspid annulus. Because the neotricuspid valve will have an orifice that is smaller than the original dilated atrioventricular junction, a plication of the inferior annulus is necessary to meet the size of the neotricuspid valve. The inferior annulus is usually plicated with two to four simple or figure-of-eight 5-0 monofilament sutures. Proper placement of these sutures is critical to the success of this repair. The sutures need to be deep enough to maintain the integrity of the new annulus intact *without* compromising or significantly distorting the right coronary artery. If the size discrepancy between the true tricuspid annulus and the neotricuspid valve is large, smaller annular plication sutures should be placed in multiple areas around the true annulus to avoid distortion of the right coronary artery by a large plication in a single area. (Copyrighted and used with permission of Mayo Foundation for Medical Education and Research.) (B) Intraoperative photo demonstrating the cone reconstruction. There is 360° of leaflet tissue with chordal support to the leading edge of all leaflets. The annulus will be reduced in size to accommodate the neotricuspid valve.



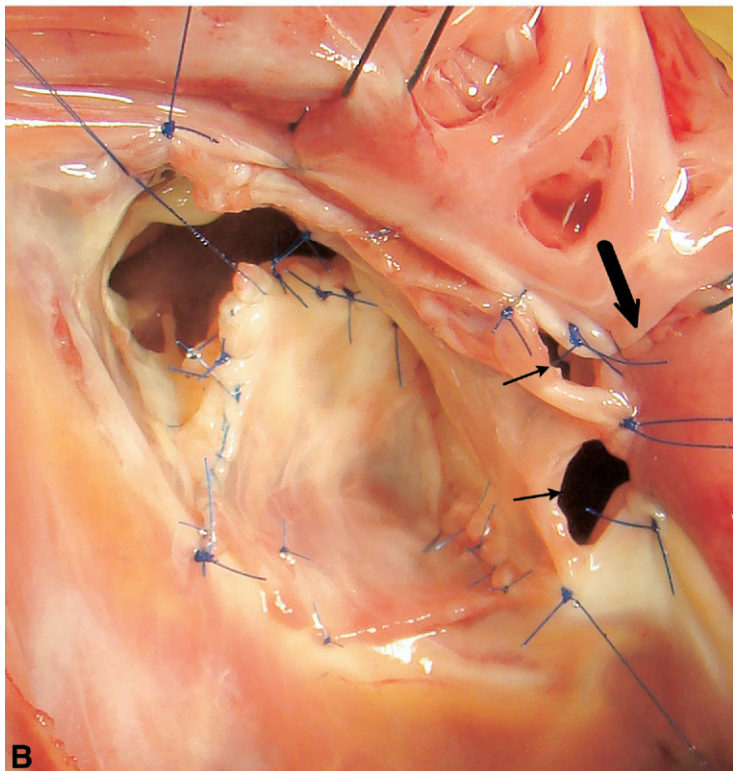
A



B



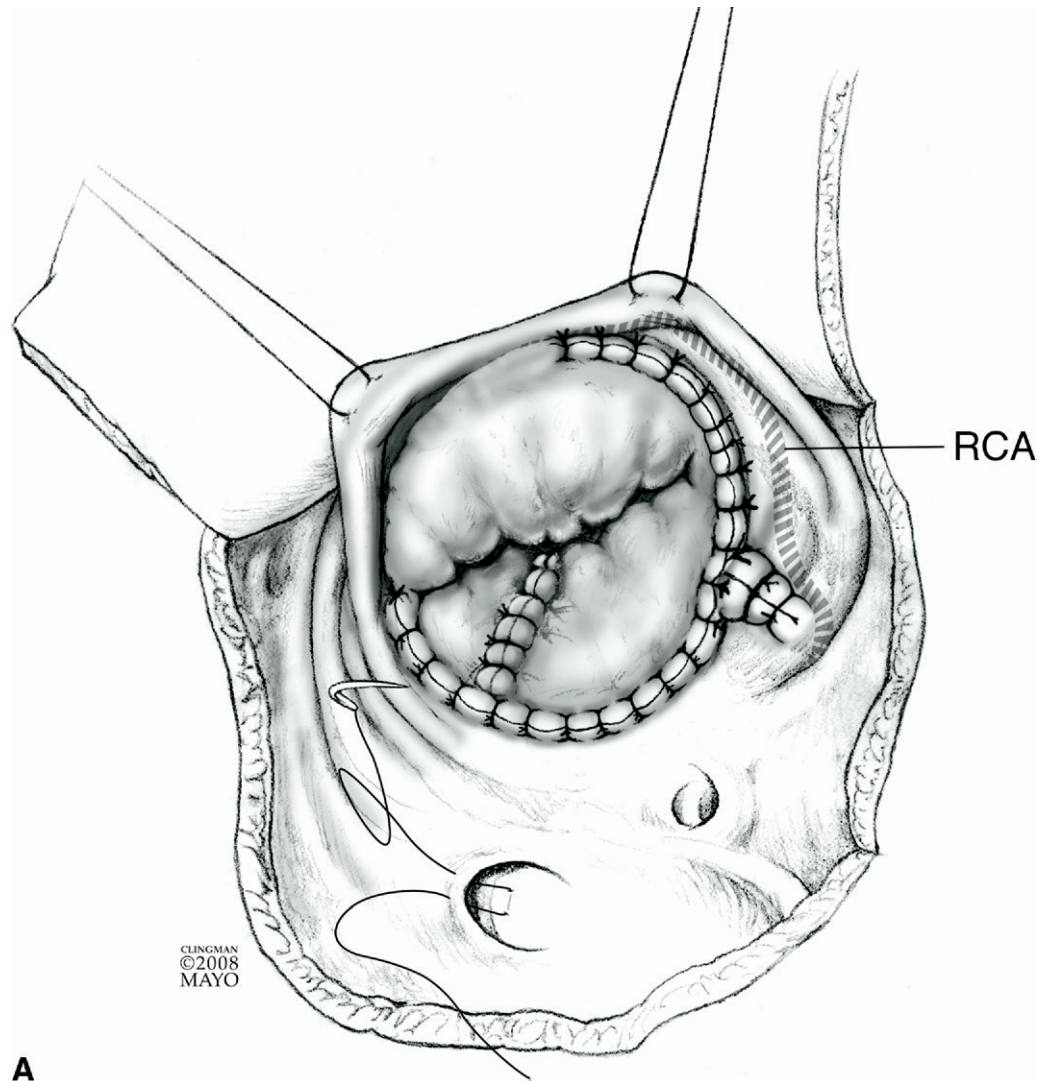
A



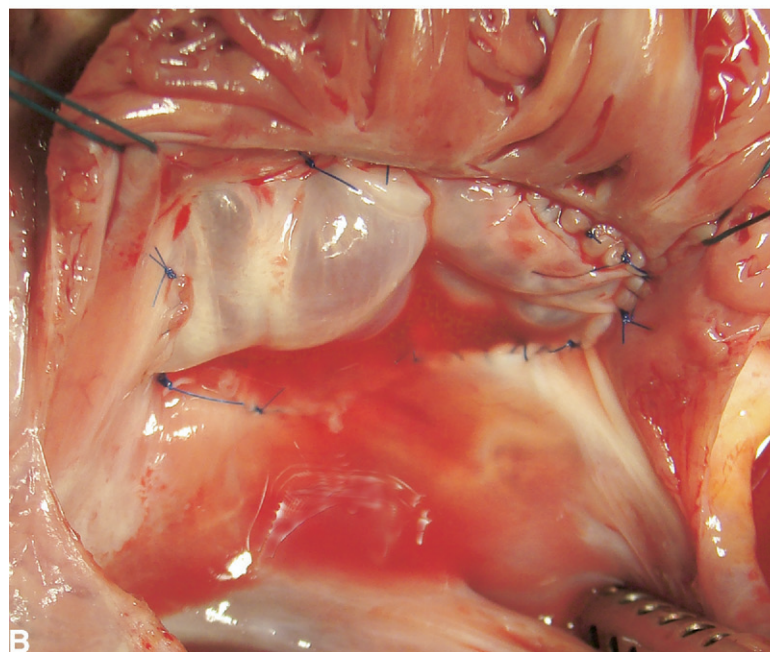
B

Figure 13 (A) After the inferior annulus is plicated to the appropriate size of the neotricuspid valve, the leaflet tissue is then anchored to the true annulus with interrupted 5-0 or 6-0 monofilament suture. This avoids any “purse-string” effect and eliminates any concern about growth if the procedure is being performed in a young child. To avoid heart block, the suture line is deviated slightly cephalad to the membranous septum and atrioventricular node, which is marked by the previously mentioned vein and fatty tissue. RCA = right coronary artery. (Copyrighted and used with permission of Mayo Foundation for Medical Education and Research.) (B) Intraoperative photo demonstrating reattachment of the neotricuspid valve to the true tricuspid annulus with interrupted monofilament suture. The site of plication of the true tricuspid annulus is indicated by the heavy arrow. The smaller arrows indicate additional areas of anterior and inferior leaflet that need to be attached to the true tricuspid annulus.

Figure 14 (A) The completed cone reconstruction of the tricuspid valve. Saline is injected via bulb syringe into the right ventricle to examine competency of the tricuspid valve. Any residual fenestrations or areas of leak are repaired as needed. A subtotal closure of the patent foramen ovale or atrial septal defect is usually performed. If it is felt that a bidirectional Glenn shunt is needed because of a small effective orifice of the neotricuspid valve, or because of severely depressed RV function; then the intra-atrial communication may be closed completely. Redundant right atrium is excised from each side of the atriotomy and then the atriotomy is closed. RCA = right coronary artery. (Copyrighted and used with permission of Mayo Foundation for Medical Education and Research.) (B) Intraoperative photo showing the completed repair of the cone reconstruction. Saline has been injected into the right ventricle and the tricuspid valve is noted to be competent.



A



B

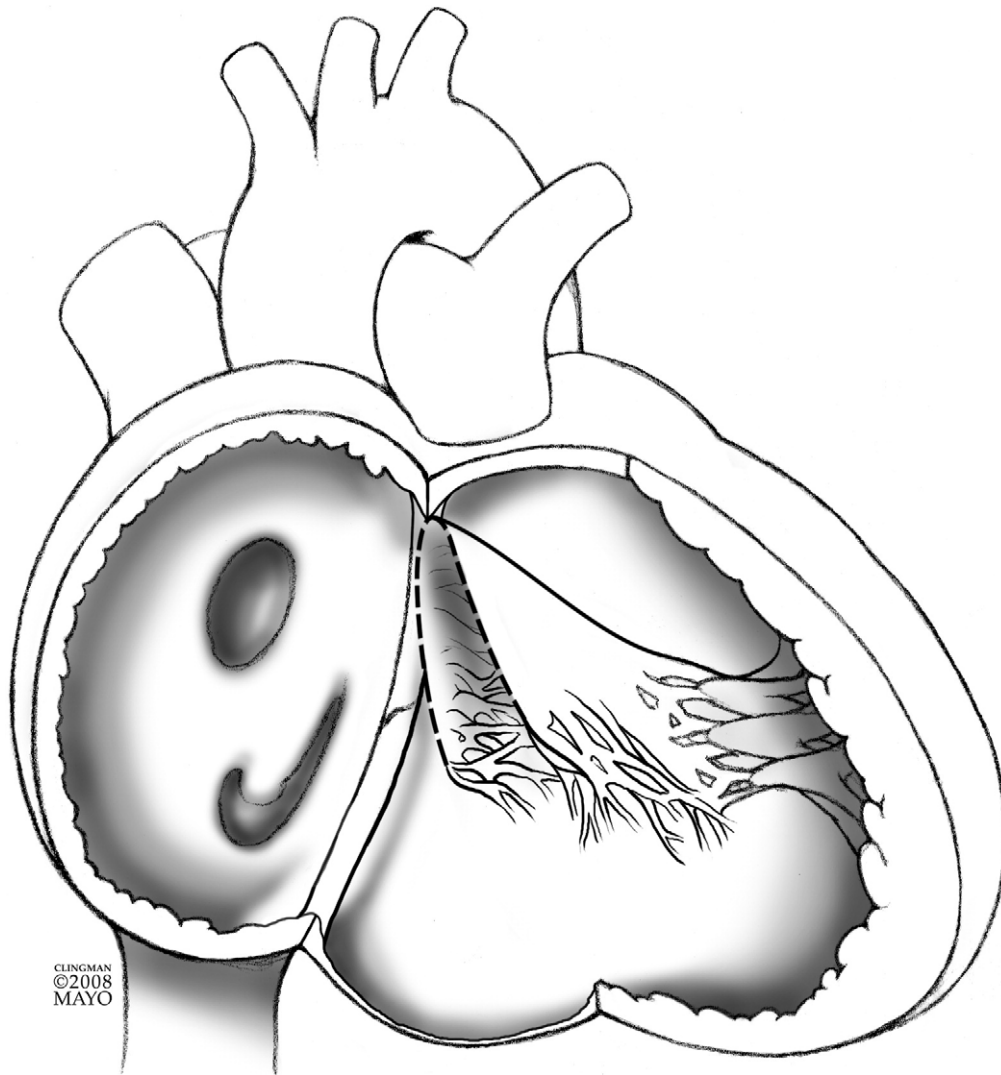


Figure 15 Preoperative demonstration of the displaced tricuspid valve and atrialized right ventricle in Ebstein's anomaly. The displacement is in an antero-apical rotational fashion and directed progressively toward the right ventricular outflow tract. The hinge-point of the functional tricuspid valve is at some level in the right ventricular cavity away from the true tricuspid valve annulus. (Copyrighted and used with permission of Mayo Foundation for Medical Education and Research.)

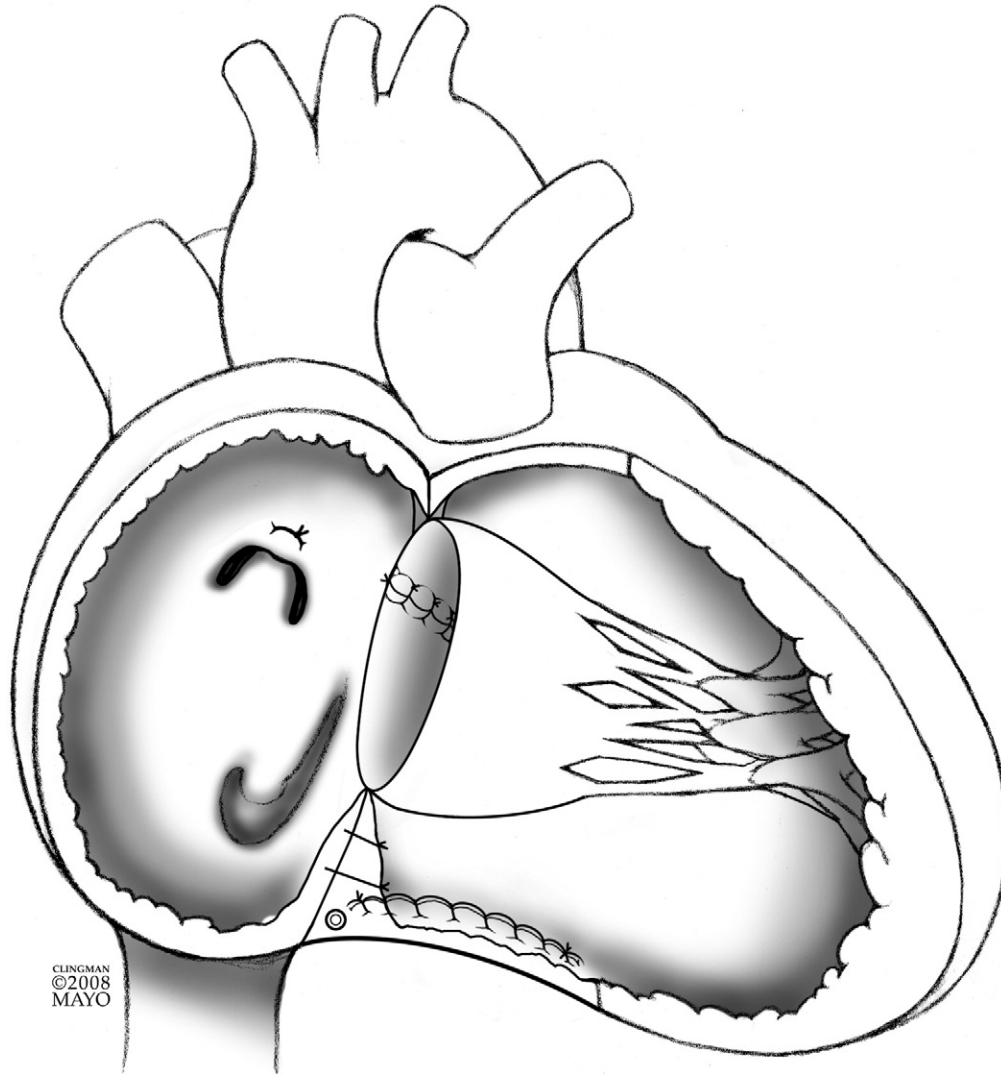


Figure 16 The completed cone reconstruction of the tricuspid valve for Ebstein's anomaly. This represents an "anatomic repair" because there is 360° of tricuspid leaflet tissue that surrounds the orifice of the tricuspid valve and it is anchored at the level of the normal right atrioventricular junction (true tricuspid valve annulus). Extreme forms of thinned, atrialized right ventricle are plicated and redundant right atrium is excised. (Copyrighted and used with permission of Mayo Foundation for Medical Education and Research.)

References

1. Dearani JA, O'Leary PW, Danielson GK: Surgical treatment of Ebstein's malformation: state of the art in 2006. *Cardiol Young* 16:12-20, 2006 (suppl 3)
2. Hunter SW, Lillehei W: Ebstein's malformation of the tricuspid valve: study of a case together with suggestion of a new form of surgical therapy. *Dis Chest* 33:297-304, 1958
3. da Silva JP, Baumgratz JF, da Fonseca L, et al: The cone reconstruction of the tricuspid valve in Ebstein's anomaly. The operation: early and mid-term results. *J Thorac Cardiovasc Surg* 133:215-223, 2007
4. Leung MP, Baker EJ, Anderson RH, et al: Cineangiographic spectrum of Ebstein's malformation: its relevance to clinical presentation and outcome. *J Am Coll Cardiol* 11:154-161, 1988