



Myxolipoma of the renal capsule: A case report

Basri Cakiroglu^{a,*}, Tuncay Tas^b, Tarık Esen^c, Lora Ates^d, Suleyman Hilmi Aksoy^e^a Hisar Intercontinental Hospital Department of Urology, Umraniye, Istanbul, Turkey^b Taksim Training and Research Hospital Department of Urology, Istanbul, Turkey^c Koc University Medical School Department of Urology, Istanbul, Turkey^d Hisar Intercontinental Hospital Department of Pathology, Umraniye, Istanbul, Turkey^e Hisar Intercontinental Hospital Department of Radiology, Umraniye, Istanbul, Turkey

ARTICLE INFO

Article history:

Received 7 April 2014

Received in revised form 3 July 2014

Accepted 7 September 2014

Available online 24 November 2014

Keywords:

Myxolipoma

Renal benign tumor

Lipoma

ABSTRACT

INTRODUCTION: Although lipomas are the most common mesenchymal tumors of the human body, primary intrarenal lipomas are quite rare. In this report we present a case of benign mesenchymal tumor with lipomatous and myxoid components.

PRESENTATION OF CASE: A sixty one years old male patient was admitted to our outpatient clinic for a general control since he had a right radical nephrectomy operation due to renal cell carcinoma (RCC) eight years ago and he did not have any urological control for last 3 years. However the urinary ultrasound revealed a mass lesion on left kidney and then on axial contrast-enhanced computed tomography (CT) scan, there were two masses on the left kidney. In the magnetic resonance imaging (MRI), the tumor on cortex was depicted as a homogeneous low-signal intensity on the T1-weighted pulse sequence and as a heterogeneous high-signal intensity on the T2-weighted pulse sequence. In pathological evaluation, the biopsy material of the cortical mass was a tumoral lesion containing lipomatous and mixoid areas without atypia, mitosis or necrosis which was diagnosed as myxolipoma.

DISCUSSION: Myxolipoma, an uncommon type of lipoma, is a benign tumor composed mainly of fat cells with myxoid (mucus-like) components. In our case, the tumor was composed of mature adipocytes together with areas rich in mucoid substances and there were no malignant features including lipoblasts, mitosis or abundant capillary network.

CONCLUSION: Herein we present a case of a fatty tumor originating from the renal capsule with the histologic diagnosis of myxolipoma. To the best of our knowledge, myxolipoma, a very rare form of lipoma, is not reported in kidney, in the literature before.

© 2014 The Authors. Published by Elsevier Ltd. on behalf of Surgical Associates Ltd. This is an open access article under the CC BY-NC-ND license (<http://creativecommons.org/licenses/by-nc-nd/3.0/>).

1. Introduction

Lipomas are the most common neoplasms of mesenchyme, arising from mature adipocytes of fat tissue. Lipomas have different histologic variants according to the accompanying mesenchymal elements including fibrolipoma, chondrolipoma, osteolipoma, myolipoma and angiomyolipoma.¹ Myxolipoma is one of these variants which is considered to be a lipoma with a high degree of myxoid change owing to its abundant mucoid component.² Although lipomas are very common, myxolipoma is an uncommon type of mesenchymal tumor. Myxolipomas are reported in the literature in different locations including retroperitoneal region, heart, tongue, oral cavity and epiglottis.³

Benign renal neoplasms constitute a large range of lesions including adenoma, angiomyolipoma, oncocytoma, leiomyoma and nephroma.⁴ Angiomyolipomas are the most common

mesenchymal renal neoplasms arising from the cortex or medulla and contain varying amounts of fat, smooth muscles and blood vessels.⁵ On the other hand renal lipomas are extremely rare and the renal cortex is the most common location for intrarenal lipomas which are reported in middle-aged women in general.⁶

Herein we present a case of a fatty tumor originating from the renal capsule with the histologic diagnosis of myxolipoma. To the best of our knowledge this is the first report of myxolipoma, a very rare form of lipoma, in kidney.

2. Case report

A sixty one years old male patient was admitted to our outpatient clinic for a general control since he had a right radical nephrectomy operation due to renal cell carcinoma (RCC) eight years ago and he did not have any urological control for last 3 years. His physical examination revealed nothing abnormal. The laboratory tests including routine blood tests and the urinalysis also revealed no abnormal findings and the urine cytology was negative.

* Corresponding author. Tel.: +90 216 5241300; fax: +90 216 5241223.
E-mail address: drbasri@gmail.com (B. Cakiroglu).

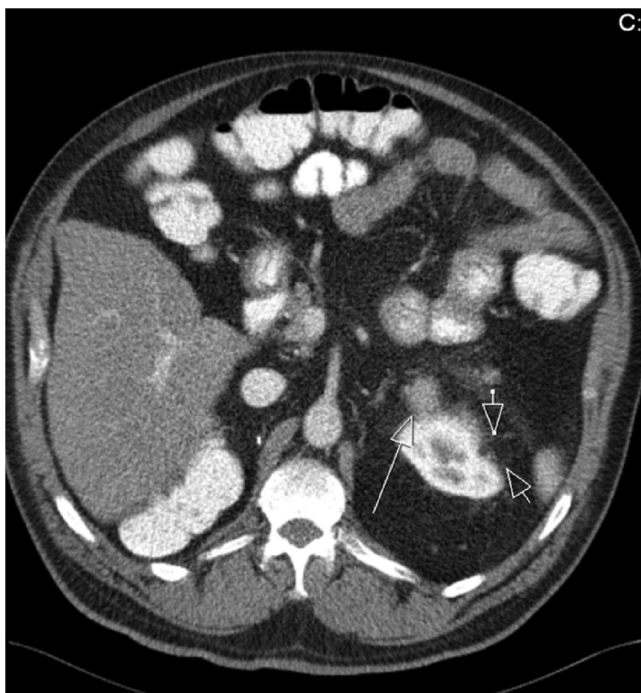


Fig. 1. Two lesions on left kidney. One is originating from cortical region and growing through perirenal fat tissue (arrowheads) while the other one is in the parenchyma having nodular growth through perirenal fat tissue (arrow).

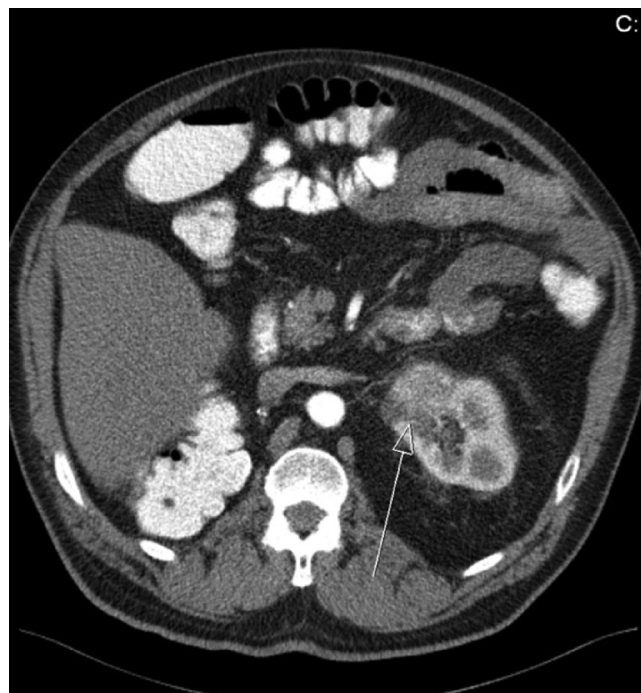


Fig. 2. The lesion located in the parenchyma having nodular growth through perirenal fat tissue (arrow).

However the urinary ultrasound revealed a mass lesion on left kidney and then on axial contrast-enhanced computed tomography (CT) scan, there were two masses on the left kidney. One of them (Fig. 1) was 3×1 cm in dimensions, originating from cortical region and growing through perirenal fat tissue. However, since it was containing fatty material, it could not be demarcated from perirenal fat tissue and only finding related to this mass was the indentation of the cortex. Other lesion (Figs. 1 and 2) was a heterogeneous solid mass with the dimensions of $4 \times 2 \times 2$ cm, in the parenchyma and it was having nodular growth through perirenal fat tissue (Figs. 1 and 2). In the magnetic resonance imaging (MRI), the tumor on cortex was depicted as a homogeneous low-signal intensity on the T1-weighted pulse sequence and as a heterogeneous high-signal intensity on the T2-weighted pulse sequence. The bone scan and chest CT showed no evidence of metastasis. The histological type of the tumor on cortex could not be supposed before the operation. The patient underwent a left retroperitoneal nephrectomy. In pathological evaluation, the biopsy material of the cortical mass was a tumoral lesion containing lipomatous and mixoid areas without atypia, mitosis or necrosis which was diagnosed as myxolipoma (Fig. 3) while the diagnosis of other parenchymal lesion was renal cell carcinoma of clear cell type. The post-operative period was uneventful and he remained free of residual or recurrent disease 13 months later.

3. Discussion

Benign mesenchymal neoplasms of the kidney in adults cover a wide spectrum with characteristic histologic findings and variable biologic and imaging profiles including angiomyolipoma, leiomyoma, hemangioma, lymphangioma, medullary fibroma, lipoma and schwannoma.⁶ Among those angiomyolipoma, which accounts for approximately 1% of all surgically removed renal tumors, is the most common benign mesenchymal neoplasm of the kidney and is composed of variable proportions of mature adipose tissue, dysmorphic blood vessels, and smooth muscle.⁷ Although lipomas are

the most common mesenchymal tumors of the human body, primary intrarenal lipomas are very rare neoplasms with only less than 25 cases reported in the literature.⁸ Similarly, renal myxomas are extremely rare neoplasms and very few cases have been reported in the literature.⁹

Myxolipoma, an uncommon type of lipoma, is a benign tumor composed chiefly of fat cells with myxoid (mucus-like) components. Myxolipoma is an extremely rare benign tumor and it has to be distinguished from benign and malignant lipomatous tumors with abundant mucoid substances, such as chondroid lipoma, spindle cell lipoma with myxoid changes and myxoid liposarcoma.³ Though myxolipoma has been reported in different locations including tongue, larynx, thigh or skin, to the best of our knowledge,

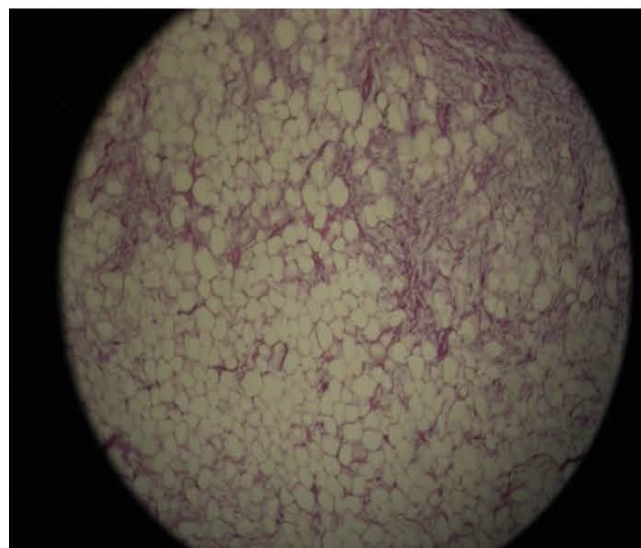


Fig. 3. Basophilic mixoid areas on right upper and lateral sides with lipomatous areas (HE $\times 10$).

myxolipoma of the kidney has not been reported before. In our case, the tumor was composed of mature adipocytes together with areas rich in mucoid substances and there were no malignant features including lipoblasts, mitosis or abundant capillary network. Therefore the histopathological diagnosis of the tumor was myxolipoma.

Surgical excision is the first choice of treatment in myxolipoma and relapse of myxolipoma have not been reported in any part of the body before.³ In the present case, in 13 months of follow up, from the operation till the present, the patient had no relapse.

In conclusion, myxolipoma is a very rare benign adipose tissue tumor with characteristic histopathological features. This tumor should be discriminated from other lipomatous and/or myxoid tumors and should be kept in mind in differential diagnosis of benign renal tumors.

Conflict of interest

None of the authors has a financial interest in any of the products, devices, or drugs mentioned in this manuscript.

Funding

This work was not supported by any external funding. None of the remaining authors have any financial disclosures.

Ethical approval

Written informed consent was obtained from the patient for publication of this case report and accompanying images.

Authors' contributions

All authors were involved in drafting the article or revising it critically for important intellectual content and all authors approved the final version for publication. Dr Basri had full access to all of the data in the study and takes responsibility for the integrity of the data and accuracy of the data analysis. Study conception and design: Basri Cakiroglu, Tuncay Tas. Acquisition of data: Tarık, Suleyman, Lora. Analysis and interpretation of data: Basri, Tuncay, Tarık, Suleyman, Lora.

Key learning points

- Myxolipoma is a very rare benign adipose tissue tumor with characteristic histopathological features.
- To the best of our knowledge this is the first report of myxolipoma, a very rare form of lipoma, in kidney.

References

1. Fletcher CDM, Unni KK, Mertens F. *Pathology and genetics: tumours of soft tissue and bone*. IARC Press; 2002. p. 9–46.
2. Chen SY, Fantasia JE, Miller AS. Myxoid lipoma of oral soft tissue. A clinical and ultrastructural study. *Oral Surg Oral Med Oral Pathol* 1984;**57**:300.
3. Ono S, Rana M, Takechi M, Ogawa I, et al. Myxolipoma in the tongue – a clinical case report and review of the literature. *Head Neck Oncol* 2011 Dec;**3**:50.
4. Srougi V, Kato RB, Salvatore FA, Ayres PP, Dall'Oglio MF, Srougi M. Incidence of benign lesions according to tumor size in solid renal masses. *Int Braz J Urol* 2009;**35**(July–August (4)):427–31.
5. Lemaitre L, Claudon M, Dubrulle F, Mazeman E. Imaging of angiomyolipomas. *Semin Ultrasound CT MR* 1997;**18**:100–14.
6. Katabathina VS, Vikram R, Nagar AM, Tamboli P, Menias CO, Prasad SR. Mesenchymal neoplasms of the kidney in adults: imaging spectrum with radiologic–pathologic correlation. *Radiographics* 2010 Oct;**30**(6):1525–40.
7. Eble JN, Sauter G, Epstein JI, Sesterhenn IA, editors. *World Health Organization classification of tumours: pathology and genetics of tumours of the urinary system and male genital organs*. Lyon, France: IARC; 2004.
8. Tamboli P, Ro JY, Amin MB, Ligato S, Ayala AG. Benign tumors and tumor-like lesions of the adult kidney. II. Benign mesenchymal and mixed neoplasms, and tumor-like lesions. *Adv Anat Pathol* 2000;**7**(1):47–66.
9. Shah A, Sun W, Cao D. Myxoma of the kidney associated with hemorrhage. *Indian J Surg* 2013;**75**(June (Suppl. 1)):480–3.

Open Access

This article is published Open Access at scimedirect.com. It is distributed under the [IJSCR Supplemental terms and conditions](#), which permits unrestricted non commercial use, distribution, and reproduction in any medium, provided the original authors and source are credited.