

## CASE REPORT

## *Escherichia vulneris*: an unusual cause of complicated diarrhoea and sepsis in an infant. A case report and review of literature

S. Jain<sup>1</sup>, D. Nagarjuna<sup>2</sup>, R. Gaind<sup>1</sup>, S. Chopra<sup>1</sup>, P. K. Debata<sup>3</sup>, R. Dawar<sup>4</sup>, R. Sardana<sup>4</sup> and M. Yadav<sup>2</sup>

1) Department of Microbiology, Vardhman Mahavir Medical College (VMMC) and Safdarjung Hospital, 2) Dr. B.R. Ambedkar Centre for Biomedical Research (ACBR), University of Delhi, 3) Department of Paediatrics, Vardhman Mahavir Medical College (VMMC) and Safdarjung Hospital, Delhi and 4) Department of Microbiology, Indraprastha Apollo Hospital, Sarita Vihar, New Delhi, India

### Abstract

*Escherichia vulneris* is an opportunistic human pathogen. It has been primarily reported in adult patients and invasive infections have been observed in immune-suppressed individuals. This is the first report of *E. vulneris* causing complicated diarrhoea and sepsis in an infant.

Two month old sick infant, born full-term, was admitted to the paediatrics department with loose motions and refusal to feed for four days. *E. vulneris* was isolated from blood in pure culture. The isolate was characterized for diarrhoeal virulence markers: heat labile and heat stable toxins (LT, ST) and hemolysin (*hlyA*) by PCR. The presence of LT enterotoxin and hemolysin provides strong evidence of the diarrhoeagenic potential of *E. vulneris*, further leading to the invasive infection triggering sepsis.

As *E. vulneris* can lead to serious complications, an attempt should be made in clinical laboratories to identify and further characterize this new *Escherichia* species.

© 2016 The Authors. Published by Elsevier Ltd on behalf of European Society of Clinical Microbiology and Infectious Diseases.

**Keywords:** Complicated diarrhoea, *Escherichia vulneris*, hemolysin (*hlyA*), infant, LT toxin, sepsis

**Original Submission:** 23 January 2016; **Revised Submission:** 21 June 2016; **Accepted:** 1 July 2016

**Article published online:** 9 July 2016

**Corresponding author:** R. Gaind, Department of Microbiology, VMMC & Safdarjung Hospital, New Delhi 110029, India  
**E-mail:** [rgaind5@hotmail.com](mailto:rgaind5@hotmail.com)

### Case report

A 2-month-old lethargic and sick female infant presented to the Paediatrics Department with diarrhoea. She had been refusing to breastfeed for 4 days before presentation and had no history of fever, vomiting or seizures. There was no history of maternal fever during the antenatal period. She was born full-term by lower-segment caesarean section and the postnatal period was uneventful. The infant was receiving bottle feeds. Physical examination revealed that the pulse and respiratory rates were 120/min and 51/min, respectively. She was dehydrated and febrile with a temperature of 38.3°C (101°F). The neonatal reflexes were poor along with a reduced muscle tone and low activity. A probable diagnosis of acute gastroenteritis with

moderate dehydration was made. The infant was admitted and intravenous fluids were administered. Her stool examination and culture were unremarkable.

On day two of hospitalization, the infant developed high-grade fever and repeated episodes of seizures. Laboratory investigations revealed haemoglobin of 163g/L, total leucocyte count of  $18.2 \times 10^9/L$  and a platelet count of  $572 \times 10^9/L$ . The level of serum calcium was slightly decreased to 1.9 mmol/L. The qualitative C-reactive protein measurement was positive ( $>10$  mg/L). On day 3, blood and cerebrospinal fluid samples were sent for examination, querying the possibility of sepsis. An empirical therapy for sepsis consisting of intravenous ampicillin and amikacin was initiated. Cerebrospinal fluid microscopy and biochemical parameters were unremarkable and culture was negative. Blood culture yielded pure growth of non-lactose fermenting, motile, Gram-negative bacilli after 48 h of incubation. The colonies showed the presence of yellow pigment.

Biochemical tests revealed a positive catalase test and exhibited glucose fermentation with production of gas in a triple sugar iron agar differential medium. The isolate was

negative for oxidase reaction, indole, urease or H<sub>2</sub>S production, citrate utilization and Voges–Proskauer test. After 48 h of incubation, an ortho-nitrophenyl-β-D-galactopyranoside test was positive. The isolate was identified as *Escherichia vulneris* by Vitek 2 Compact using ID GN card (BioMérieux, Marcy l'Etoile, France) and Vitek MS (matrix-assisted laser desorption/ionization time-of flight mass spectrometry; BioMérieux) with a confidence value of 99.4. The identity of the isolate was further confirmed by 16s rRNA gene sequencing. A single isolated colony from an overnight culture was used to perform a colony PCR using universal primers 27F and 1492R. The PCR product was run on gel and the amplicon of around 1400 bp was eluted. The eluted DNA was further sequenced using a Sanger dideoxy sequencing method. The sequence obtained was blasted using NCBI nucleotide blast. The blast results confirmed the isolate as *E. vulneris*. The sequence is submitted to NCBI (Accession No. KX357823).

Antimicrobial susceptibility was performed by Kirby–Bauer's disc diffusion method as per the CLSI guidelines. The isolate was extended spectrum β-lactamase negative and was susceptible to ampicillin, amoxicillin-clavulanate, cephalosporins (Cefuroxime, Cefoxitin, Cefazidime and Cefotaxime), aminoglycosides (gentamicin, amikacin and netilmicin), ciprofloxacin, piperacillin-tazobactam, trimethoprim-sulphamethoxazole and carbapenems (Imipenem, Meropenem, Ertapenem). Meanwhile, a repeat blood culture after 24 h also yielded pure growth of *E. vulneris*. Based on the susceptibility report, the initial therapy was continued. After 7 days of the antibiotic treatment, the infant improved clinically with lowering of fever, normal skin turgor and a sucking reflex. The antibiotics were discontinued on day 10 and the infant was discharged on oral feeds. Her follow-up blood culture at the time of discharge was sterile.

### Molecular characterization

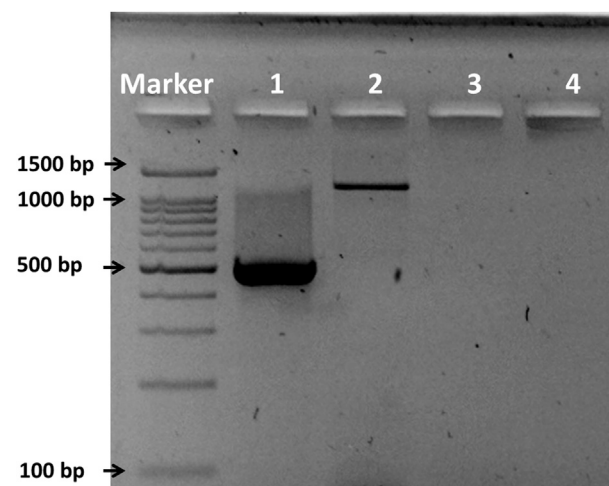
The *E. vulneris* isolate was screened for virulence markers encoding heat-labile (LT) and heat-stable (ST) enterotoxins [1] and haemolysin (*hlyA*) [2] associated with diarrhoea and sepsis. The DNA extracted from the culture grown overnight in tryptic soy broth at 37°C in a CO<sub>2</sub> incubator is used as template. The primer sequences were: LT-F 5'-GGCGACA-GATTATACCGTGC-3'; LT-R 5'-CCGAATTCTGTTATATA TGTC-3'; ST-F 5'-TTAATAGCACCCGGTACAAGCAGG-3'; ST-R 5'-CTTGACTCTTCAAAGAGAAAATTAC-3'; *hlyA* F 5'-AACAAGGATAAGCACTGTTCTGGCT-3'; *hlyA* R 5'-ACCATATAAGCGGTCATTCCCGTCA-3'.

The PCR for LT and ST toxin genes was performed using a predefined program with an initial denaturation at 95°C for 5 min, 35 cycles of denaturation at 95°C for 30 seconds,

annealing at 56°C for 30 seconds, extension at 72°C for 45 min and final extension at 72°C for 5 min with following primer pairs. For haemolysin, the reaction conditions were initial denaturation at 95°C for 5 min, 35 cycles of denaturation at 95°C for 30 seconds, annealing at 55°C for 30 seconds, extension at 72°C for 1 min and final extension at 72°C for 5 min. The isolate was found to be positive for LT toxin and haemolysin (*hlyA*) but it was negative for ST toxin (Fig. 1).

### Discussion

*Escherichia vulneris* is an opportunistic human pathogen and there are limited clinical reports of human infections worldwide [3–5]. A review of *E. vulneris* infections reported in humans worldwide is presented in Table 1. In humans, *E. vulneris* was initially isolated from infected wounds, in association with other bacteria such as *Staphylococcus aureus*, *Staphylococcus epidermidis*, streptococci, enterococci and *Enterobacter* spp., *Acinetobacter lwoffii* and *Cedecea neteri* [4,6]. Later, *E. vulneris* was also isolated from other clinical specimens, such as stool, sputum, urine, vaginal swabs and throat swabs, where it was thought to be a colonizer [3]. As *E. vulneris* failed to induce soft-tissue infections or lethality in mice on pathogenicity testing, the clinical significance of this species was doubted [4]. However subsequent studies showed *E. vulneris* as the sole pathogen in clinical cases of urosepsis, osteomyelitis, intravenous catheter-related bacteraemia,



**FIG. 1.** Gel picture showing *Escherichia vulneris* positive for heat-labile (LT) toxin (508 bp, Lane 1); *hlyA* toxin (1177 bp, Lane 2); and negative for heat-stable (ST) toxin (Lane 3); PCR mixture without the template was taken as a negative control (Lane 4); 100-bp ladder was used as a DNA marker. PCR products were run on 1.8% agarose gel and visualized under UV Transilluminator and pictured using a gel documentation system.

**TABLE 1.** Review of human *Escherichia vulneris* infections reported so far

Year and place	Age and sex	Diagnosis	Associated bacteria	Immune status	Source	Treatment	Outcome
1985, Hawaii [3]	12 cases	Wound infection	Heavy growth of <i>Staphylococcus aureus</i>	NA	NA	NA	NA
1991, California [6]	86 years, F	Urosepsis	Pure growth of <i>E. vulneris</i>	Type II diabetes mellitus	Urinary catheter	Ampicillin-sulbactam	Cured
1993, Spain [5]	2 cases	Post-operative wound infection	<i>Enterococcus faecium</i> <i>Cedecea neteri</i>	NA	NA	NA	NA
1994, Massachusetts [8]	13 years, M	Post-operative peritonitis Osteomyelitis	Pure growth of <i>E. vulneris</i>	Normal	Wooden foreign body	NA	NA
1996, Massachusetts [9]	62 years, F	Intravenous-catheter-related bacteraemia	Pure growth of <i>E. vulneris</i>	Poor nutrition; Crohn's disease	PICC line	Cefazolin, catheter removal	Cured
1997, Denmark [10]	14 years, M	Infected soccer wound	<i>Bacillus cereus</i> , CoNS, non-haemolytic streptococci	Normal	Not known	Cefuroxime, wound debridement	Cured
1999, Andhra Pradesh, India [13]	12 cases	Gastroenteritis	Pure growth of <i>E. vulneris</i>	NA	NA	NA	NA
2005, Delhi, India [11]	4 years, F	Meningitis	Pure growth of <i>E. vulneris</i>	Normal	Nosocomial	Piperacillin-tazobactam and Meropenem	Cured
2006, Australia [12]	83 years, F	CAPD-associated peritonitis	Pure growth of <i>E. vulneris</i>	Immune-suppressants for myeloproliferative disease	Peritoneal catheter	Gentamicin	Cured
2007, Tunisia [7]	70 years, M	Bacteraemia following subcutaneous abscess	Pure growth of <i>E. vulneris</i>	Chronic lymphocytic leukaemia	Abscess	Ciprofloxacin and Gentamicin	Cured
2008, Turkey [1]	64 years, M	CAPD-associated peritonitis	Pure growth of <i>E. vulneris</i>	Chronic renal failure	Not known	Ceftriaxone	Cured
Present case: 2013, New Delhi, India	2 months, F	Acute gastroenteritis and sepsis	Pure growth of <i>E. vulneris</i>	Normal	Not known	Ampicillin and Amikacin	Cured

Note: NA, not available; M, male; F, female; PICC, peripherally inserted central catheter; CoNS, coagulase-negative staphylococci; CAPD, continuous ambulatory peritoneal dialysis.

Danish soccer wound infection, meningitis, dialysis-related peritonitis and bacteraemia in a patient with chronic lymphocytic leukaemia [1,7–13]. Infections were primarily reported in adults or elderly individuals and invasive infections were usually observed in immunosuppressed individuals. The source of infection remains unclear.

Experimental studies on animals to ascertain the diarrhoeagenic potential of *E. vulneris* have been reported [14]. However, this is the first report of *E. vulneris* causing complicated diarrhoea with associated sepsis in an infant. Chaudhury et al. studied enteropathogenicity in mice of new *Escherichia* species isolated from 50 diarrhoeal stools (12 *E. vulneris*, six *Escherichia fergusonii*, two *Escherichia hermannii* isolates). No lethality was produced in mice; however, a significant fluid accumulation in ileal loops was produced by *E. vulneris*. The probable mechanism for enteropathogenicity was speculated as enterotoxin production, though the role of other virulence factors, such as adherence or invasiveness, could not be excluded [14].

In the present case the 2-month-old infant presented with acute gastroenteritis and subsequently developed early signs of sepsis. There was no significant maternal history and the natal and postnatal periods were uneventful. As the stool culture was negative for *E. vulneris* and other enteropathogens, we investigated the isolate from the blood culture for the diarrhoeal and other virulence markers. The presence of LT enterotoxin has been reported for the first time in a clinical isolate of *E. vulneris* in this case.

In the absence of other possible source of infection like lung, skin and soft-tissue and urinary tract infections and the use of

an invasive device, we hypothesize that *E. vulneris* bacteraemia apparently followed diarrhoea. The presence of the LT enterotoxin and the haemolysin (*hlyA*) provides strong evidence of the diarrhoeagenic potential of *E. vulneris*, further leading to the invasive infection triggering sepsis. Microbial contamination of food and water are the major causes of childhood diarrhoea. As the infant was not exclusively breastfed, exposure to the contaminated formula top-up feed may be the source of infection. The other probable sources of contamination include the immediate environmental flora including maternal flora or contaminated water used for formulation of top-up feed. Moreover children under the age of 2 years are more predisposed to infections because of their under-developed gastrointestinal tract immune system, impaired spleen, B lymphocytes and T-cell helper functions, which are important mechanisms for combating microbial attack. In addition, the levels of IgA, essential for combating microbial infections in the gastrointestinal tract are also drastically reduced in children.

As in previous reports, the *E. vulneris* isolated from the present case was a pan-sensitive strain (susceptible to all classes of antimicrobials tested) [3,7,8,13]. Rarely, resistance to ampicillin and/or first- and second-generation cephalosporins, chloramphenicol and tetracycline has been reported [4,12,14]; however, there is a single clinical report of extended spectrum  $\beta$ -lactamase producing *E. vulneris* [12].

In conclusion, we report *E. vulneris* as a potential diarrhoeal pathogen in infants and young children that may be associated with serious complications such as sepsis. An attempt should be made in clinical laboratories to identify and further characterize this rare *Escherichia* species.

## Conflict of interest

---

All authors have no potential conflicts of interest.

## References

---

- [1] Arslan U, Cosar M, Tuncer I, Findik D. *Escherichia vulneris* peritonitis in a patient on CAPD. *Peritoneal Dialysis Int* 2008;28:681–2.
- [2] Nagarjuna D, Mittal G, Dhanda RS, Verma PK, Gaind R, Yadav M. Faecal *Escherichia coli* isolates show potential to cause endogenous infection in patients admitted to the ICU in a tertiary care hospital. *New Microb New Infect* 2015;7:57–66.
- [3] Brenner DJ, McWhorter AC, Knutson JK, Steigerwalt AG. *Escherichia vulneris*: a new species of *Enterobacteriaceae* associated with human wounds. *J Clin Microbiol* 1982;15:1133–40.
- [4] Pien FD, Shrum S, Swenson JM, Hill BC, Thornsberry C, Farmer 3rd JJ. Colonization of human wounds by *Escherichia vulneris* and *Escherichia hermannii*. *J Clin Microbiol* 1985;22:283–5.
- [5] Horii T, Suzuki Y, Kimura T, Kanno T, Maekawa M. Intravenous catheter-related septic shock caused by *Staphylococcus sciuri* and *Escherichia vulneris*. *Scand J Infect Dis* 2001;33:930–2.
- [6] Anon MT, Ruiz-Velasco LM, Borrajo E, Giner C, Sendino M, Canton R. [*Escherichia vulneris* infection. Report of 2 cases]. *Enfermedades infecciosas y microbiologia clinica* 1993;11:559–61.
- [7] Awsare SV, Lillo M. A case report of *Escherichia vulneris* urosepsis. *Rev Infect Dis* 1991;13:1247–8.
- [8] Kilani B, Ammari L, Benaissa HT, Ben Chaabane T, Fendri C. *Escherichia vulneris* as a cause of bacteremia in a patient with chronic lymphocytic leukemia. *Int J Infect Dis* 2008;12:110–1.
- [9] Levine WN, Goldberg MJ. *Escherichia vulneris* osteomyelitis of the tibia caused by a wooden foreign body. *Orthopaed Rev* 1994;23(3):262–5.
- [10] Spaulding AC, Rothman AL. *Escherichia vulneris* as a cause of intravenous catheter-related bacteremia. *Clin Infect Dis* 1996;22(4):728–9.
- [11] Jepsen CF, Klebe TM, Prag J. *Escherichia vulneris* in a Danish soccer wound. *Scand J Infect Dis* 1997;29:313–4.
- [12] Mohanty S, Chandra SP, Dhawan B, Kapil A, Das BK. Meningitis due to *Escherichia vulneris*. *Neurol India* 2005;53:122–3.
- [13] Senanayake SN, Jadeer A, Talaulikar GS, Roy J. First reported case of dialysis-related peritonitis due to *Escherichia vulneris*. *J Clin Microbiol* 2006;44:4283–4.
- [14] Chaudhury A, Nath G, Tikoo A, Sanyal SC. Enteropathogenicity and antimicrobial susceptibility of new *Escherichia* spp. *J Diarrh Dis Res* 1999;17:85–7.