



## CLINICAL INFORMATION

# Ultrasound-guided paravertebral block for pyloromyotomy in 3 neonates with congenital hypertrophic pyloric stenosis



Javier Mata-Gómez, Rosana Guerrero-Domínguez\*, Marta García-Santigosa, Antonio Ontanilla

*Departamento de Anestesiología y Reanimación, Hospital Universitario Virgen del Rocío, Sevilla, Spain*

Received 9 January 2014; accepted 13 March 2014

Available online 28 April 2015

### KEYWORDS

Pyloromyotomy;  
Paravertebral block;  
Hypertrophic pyloric  
stenosis;  
Regional anesthesia;  
Pediatrics

### Abstract

**Background and objectives:** Hypertrophic pyloric stenosis is a relatively common affection of gastrointestinal tract in childhood that results in symptoms, such as projectile vomiting and metabolic disorders that imply a high risk of aspiration during anesthetic induction. In this way, the carrying out of a technique with general anesthesia and intravenous rapid sequence induction, preoxygenation and cricoid pressure are recommended. After the correction of systemic metabolic alkalosis and pH normalization, cerebrospinal fluid can keep a state of metabolic alkalosis. This circumstance, in addition to the residual effect of neuromuscular blocking agents, inhalant anesthetics and opioids could increase the risk of postoperative apnea after a general anesthesia.

**Case report:** We present the successful management in 3 neonates in those a pyloromyotomy was carried out because they had presented congenital hypertrophic pyloric stenosis. This procedure was done under general anesthesia with orotracheal intubation and rapid sequence induction. Then, ultrasound-guided paravertebral block was performed as analgesic method without the need for administering opioids within intraoperative period and keeping an appropriate analgesic level.

**Conclusions:** Local anesthesia has demonstrated to be safe and effective in pediatric practice. We consider the ultrasound-guided paravertebral block with one dose as a possible alternative for other local techniques described, avoiding the use of opioids and neuromuscular blocking agents during general anesthesia, and reducing the risk of central apnea within postoperative period.

© 2014 Sociedade Brasileira de Anestesiologia. Published by Elsevier Editora Ltda. All rights reserved.

\* Corresponding author.

E-mail: [rosanabixi7@hotmail.com](mailto:rosanabixi7@hotmail.com) (R. Guerrero-Domínguez).

**PALAVRAS-CHAVE**

Piloromiotomia;  
Bloqueio  
paravertebral;  
Estenose hipertrófica  
de piloro;  
Anestesia regional;  
Pediátrica

## Ultrasound-guided paravertebral block for pyloromyotomy in 3 neonates with congenital hypertrophic pyloric stenosis

**Resumo**

*Justificativa e objetivos:* A estenose hipertrófica do piloro é uma condição relativamente comum do trato gastrointestinal na infância, que causa um quadro de vômitos em jato e alterações metabólicas que envolvem um alto risco de aspiração durante a indução da anestesia. Assim, recomenda-se a realização de uma técnica sob anestesia geral e indução intravenosa de sequência rápida, pré-oxigenação e pressão cricoide. Após a correção da alcalose metabólica sistêmica e normalização do pH, o líquido cefalorraquidiano pode manter um estado de alcalose metabólica. Isto, juntamente com os efeitos residuais de agentes bloqueadores neuromusculares, anestésicos e opioides, pode aumentar o risco de apneia pós-operatória após anestesia geral.

*Casos clínicos:* Apresentamos o manejo bem sucedido em 3 recém-nascidos que foram submetidos a piloroplastia por apresentar estenose hipertrófica do piloro congênita. O procedimento foi realizado sob anestesia geral com intubação orotraqueal e indução de sequência rápida. Em seguida, realizou-se um bloqueio paravertebral guiado por ultrassonografia como método analgésico sem a necessidade de administração de opioides durante o período intraoperatório e mantendo o nível analgésico adequado.

*Conclusões:* A anestesia regional é comprovadamente segura e eficaz na prática pediátrica. Consideramos o bloqueio paravertebral guiado por ultrassom com dose única como uma possível alternativa a outras técnicas regionais descritas, evitando o uso de opioides e bloqueadores neuromusculares durante a anestesia geral e reduzindo o risco de apneia central no pós-operatório. © 2014 Sociedade Brasileira de Anestesiologia. Publicado por Elsevier Editora Ltda. Todos os direitos reservados.

**Introduction**

Hypertrophic pyloric stenosis (HPS) is a gastrointestinal disorder inherent to childhood, with an incidence of 0.9 to 5.1/1.000 cases,<sup>1</sup> an average age of presentation of 5 weeks and an average weight of 4 kg<sup>-1</sup>. The classic clinical picture is characterized by projectile vomiting, malnutrition, dehydration and electrolyte and metabolic disturbances.<sup>1</sup> The treatment of this condition consists of the performance of pyloromyotomy under general anesthesia and orotracheal intubation,<sup>2</sup> which is a challenge for anesthesiologists given the risk of bronchopulmonary aspiration,<sup>3,4</sup> and frequent metabolic alterations in the context of a general anesthesia by hyperventilation<sup>3,4</sup> or administration of opioids and neuromuscular blockers may increase the risk of central apnea. An operation under general anesthesia combined with locoregional techniques could reduce the risk of apnea and postoperative complications.<sup>3,5</sup>

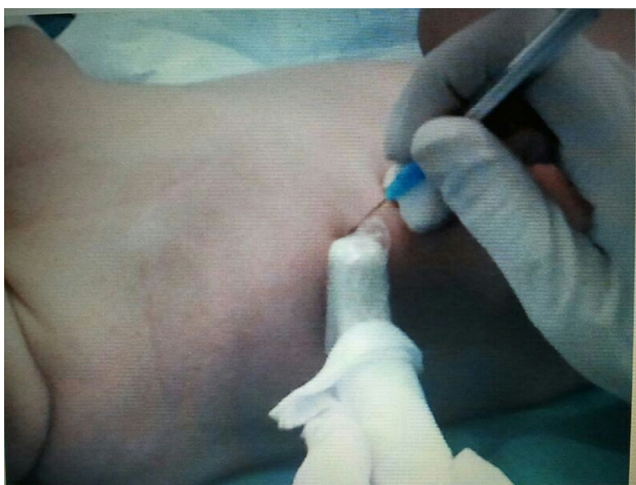
**Case reports**

We report 3 infants undergoing pyloromyotomy due to HPS of 30, 34 and 42 days of age and weights of 3500; 3200; and 4 kg respectively. On arrival at the operating room they were monitored by noninvasive blood pressure, electrocardiogram, and pulse oximetry with peripheral vein channeling under sedation with sevoflurane 5%. Intravenous atropine 0.02 mg/kg<sup>-1</sup> was given as premedication and intravenous propofol induction was performed at a dose of 4 mg/kg<sup>-1</sup> until reaching optimal conditions for

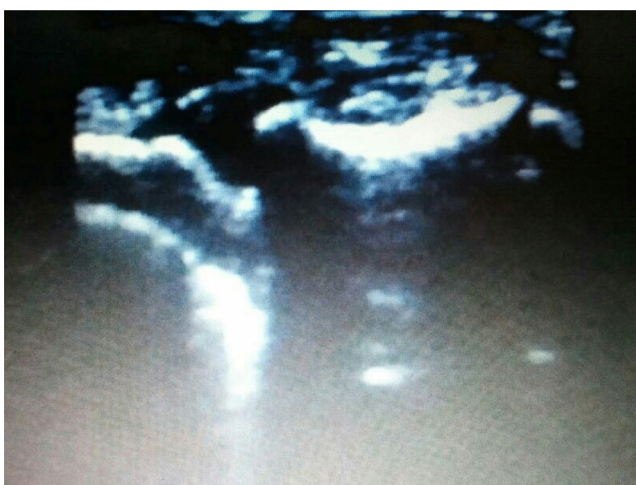
endotracheal intubation with rapid sequence induction and cricoid pressure, with subsequent checking of correct placement of endotracheal tube by capnography and volume controlled mechanical ventilation. Anesthesia was maintained with sevoflurane at 1 CAM.

The paravertebral technique was performed after induction of anesthesia in the left lateral decubitus position, keeping the right side accessible for the procedure to be carried out. The material used consisted of a Toshiba Nemio XG<sup>®</sup> ultrasound device with transducer model PLM-1202S and a 23 G hypodermic needle of 25 mm of length. T8 level was identified by placing the probe transversely and lateral to the spinous process at this level, with costal hyperechoic acoustic shadowing being located and, subsequently, being slightly shifted cranially until identifying the pleura as a hyperechoic line in the intervertebral space with posterior echo with comet tail shape; above it, an isoechogenic image corresponding to the external and medial intercostal muscle, and out of this, a hyperechoic line that served to mark the boundaries of the paravertebral space. Having identified these structures the needle (Fig. 1) was introduced under sterile conditions, lateral and medial to the probe with the tip of the probe being located at all times until reaching the paravertebral space infiltrating it with 0.25 mL/kg<sup>-1</sup> bupivacaine 0.25% in a single bolus and after prior suction to rule out intravascular injection (Fig. 2).

Surgery in the 3 cases took place with no incidents, with no adjunctive administration of opioids and muscle relaxants being needed, and keeping an adequate hemodynamic stability and analgesic level that allowed early extubation after completion of the surgical procedure.



**Figure 1** Performance of ultrasound-guided paravertebral block in a patient with HPS.



**Figure 2** Ultrasound view of paravertebral space at T8 level.

No episodes of apnea in the early postoperative 24 h were detected and none of the 3 infants required analgesia in the first 12 h.

## Discussion

The recurrent vomiting associated with HPS causes a state of hypochloremic metabolic alkalosis<sup>3</sup> and increased pH of cerebrospinal fluid. Cerebrospinal fluid alkalosis may persist after correction of systemic metabolic alkalosis.<sup>3</sup> The pH of the cerebrospinal fluid is one of the determinants of respiratory stimulus.<sup>3</sup> Metabolic disturbances, hyperventilation, dehydration and the residual effect of neuromuscular blocking agents, inhalants and opioids used primarily during the anesthetic procedure<sup>3</sup> could increase the risk of central apnea, increased in preterm infants who constitute 12% of cases,<sup>3</sup> leading to respiratory problems that require long-term maintenance of mechanical ventilation.<sup>2</sup>

Neonates are especially sensitive to the respiratory depressant effects associated with opioid analgesia. This

sensitivity appears to be related to immaturity of the respiratory muscles and respiratory control centers.<sup>3</sup> Although respiratory complications and incidence of apnea breaks are more frequent in the latter, postoperative apnea was described in healthy neonates who underwent pyloroplasty and received opioids in the intraoperative period,<sup>3</sup> remaining intubated and connected to mechanical ventilation during the postoperative period. For this reason, some anesthetists recommend limiting the use of opioids during pyloromyotomy.<sup>3</sup>

HPS patients are considered with "full stomach",<sup>1,3,4</sup> so that a general anesthetic technique is recommended with adequate preoxygenation and rapid sequence induction with cricoid pressure and orotracheal intubation<sup>4</sup> to reduce the risk of bronchopulmonary aspiration. Up to 5% of anesthetists recommend awake intubation to limit the risk of aspiration and possible desaturation. However, it is associated with other complications, such as soft tissue trauma, bradycardia, laryngospasm and hypoxia.<sup>4</sup> Inhalational induction has been recommended due to its safety in pediatric patients.<sup>2,4,6</sup>

In the neonatal period, the regional analgesia is indicated when our goal is an early extubation. Besides providing an adequate level of intraoperative analgesia and its longer duration in the postoperative period,<sup>5</sup> it provides a degree of muscle relaxation to facilitate the surgical technique.<sup>7</sup> The need for postoperative ventilatory support is significantly reduced<sup>7</sup> when locoregional analgesic techniques are performed, compared with the administration of intraoperative opioid drugs, decreasing the duration of mechanical ventilation and minimizing respiratory complications, which thus reduces the morbidity and mortality.<sup>7</sup>

For locoregional anesthetic technique performance, knowledge of the exact location of the surgical incision is needed. Pyloromyotomy requires a right supraumbilical incision, with analgesic level being required for this T4 surgery.<sup>1</sup>

We present a novel anesthetic technique in patients with HPS undergoing pyloromyotomy, based on the performance of an ultrasound-guided thoracic paravertebral block (PVB) and administration of a single dose of local anesthetic under general anesthesia and tracheal intubation.

Thoracic paravertebral space is a wedge-shaped area containing the thoracic nerves and sympathetic trunk.<sup>8,9</sup> The posterior wall is formed by the upper costotransverse ligament, the medial wall by the vertebral body and the intervertebral disk, and the anterolateral wall of the parietal pleura that goes with the intercostal space.<sup>8</sup> In PVB, the anterior branch of the spinal nerve roots, gray and white communicans rami and sympathetic chain<sup>9</sup> are blocked. To minimize the risk of vascular puncture, nerve injury, and pneumothorax, ultrasound-guided technique is recommended.<sup>8,9</sup>

PVB is associated with less urinary retention<sup>7</sup> compared to other techniques, lower incidence of postoperative nausea and vomiting, and less episodes of hypotension and a reduction of pulmonary complications. Furthermore, the administration of local anesthetics in the paravertebral space produces a unilateral somatic and sympathetic block that is advantageous for unilateral surgical procedures of chest and abdomen.

There are several studies in which other locoregional techniques are used in pyloromyotomy due to HPS.

Willschke et al.<sup>1</sup> describe an ultrasound-guided thoracic epidural technique under sedation as an alternative to general anesthesia for pyloromyotomy.

At present, evidence supports that PVB is as effective as the epidural block for postoperative pain management, and has a better safety profile than neuroaxial techniques.<sup>5</sup>

Somri et al.<sup>3</sup> suggested that spinal anesthesia with isobaric bupivacaine at a concentration of 0.5% and a dose of 0.8 mg/kg<sup>-1</sup> was an alternative to general anesthesia; however spinal block for pyloromyotomy can cause uncontrolled high block with consequent respiratory<sup>1</sup> failure and the need for urgent endotracheal intubation.<sup>3</sup>

Moyao-García et al.<sup>4</sup> show a case series of pyloromyotomy with performance of caudal block with 0.25% bupivacaine and a volume of 1.6 mL/kg<sup>-1</sup>. Despite the use of high doses of local anesthetic, the analgesic level required could be insufficient, with a T4–T6<sup>1</sup> level being necessary. The dose of local anesthetics administered in caudal block to achieve an adequate metameric level of analgesia exceeds recommended maximum doses<sup>5</sup>, allowing the occurrence of cardiovascular<sup>4</sup> and neurological complications, which could even be masked in this study, given the degree of sedation used.

On the other hand, the sympathetic block associated with both spinal block and the caudal anesthesia, could lead to hemodynamic repercussions in hypovolemic and dehydrated patients due to the underlying medical condition.

In these 3 aforementioned studies, the authors use locoregional techniques combined with deep sedation, so that the patient responded only to strong stimuli.

Our opinion is that endotracheal intubation is a safer technique in controlling airway in patients undergoing pyloromyotomy, since sedation levels used to maintain patient's immobility, as well as the variability of the response to sedation in neonates, both with the use of midazolam and propofol, could compromise the safety of the airway, leading to loss of reflexes with the resulting risk of bronchopulmonary aspiration in patients at high risk.

Therefore, from our experience, we conducted an intravenous induction with no administration of neuromuscular blockers nor opioids, decreasing the incidence of episodes of apnea in the postoperative period due to residual pharmacological effect. With the completion of PVB, optimal conditions of analgesia and muscle relaxation were obtained to facilitate surgical access and adequate postoperative analgesia in the 12h of postoperative with no need for supplementary analgesics, a period that coincides with the highest incidence of apnea in these patients.

In summary, the ultrasound-guided PVB with single bolus of local anesthetic associated with general anesthesia with endotracheal intubation was successfully used in 3 cases of infants with pyloromyotomy due to HPS, with no episodes of apnea in the following 24h of postoperative. We consider this technique an attractive alternative to the administration of intravenous opioids during general anesthesia, optimizing an adequate level of analgesia and reducing respiratory complications associated with the residual effect of opioids and therefore the risk of central apnea and allowing early extubation.<sup>3</sup>

On the other hand, compared to other locoregional techniques described, from our experience, paravertebral block reduces the risk of respiratory failure associated with epidural block, is associated with fewer complications and, unlike the caudal block, ensures a sufficient analgesic level for this surgical technique.<sup>1,5,7</sup>

## Conflicts of interests

The authors declare no conflicts of interest.

## References

1. Willschke H, Machata AM, Rebhandl W, et al. Management of hypertrophic pylorus stenosis with ultrasound guided single shot epidural anaesthesia – a retrospective analysis of 20 cases. *Paediatr Anaesth.* 2011;21:110–5.
2. Kachko L, Simhi E, Freud E, et al. Impact of spinal anesthesia for open pyloromyotomy on operating room time. *J Pediatr Surg.* 2009;44:1942–6.
3. Somri M, Gaitini LA, Vaida SJ, et al. The effectiveness and safety of spinal anaesthesia in the pyloromyotomy procedure. *Paediatr Anaesth.* 2003;13:32–7.
4. Moyao-García D, Garza-Leyva M, Velázquez-Armenta EY, et al. Caudal block with 4 mg × kg<sup>-1</sup> (1.6 ml × kg<sup>-1</sup>) of bupivacaine 0.25% in children undergoing surgical correction of congenital pyloric stenosis. *Paediatr Anaesth.* 2002;12:404–10.
5. Jöhr M, Berger TM. Regional anaesthetic techniques for neonatal surgery: indications and selection of techniques. *Best Pract Res Clin Anaesthesiol.* 2004;18:357–75.
6. Andreu E, Schmucker E, Drudis R, et al. Algorithm for pediatric difficult airway. *Rev Esp Anesthesiol Reanim.* 2011;58:304–11.
7. Bosenberg A. Benefits of regional anesthesia in children. *Paediatr Anaesth.* 2012;22:10–8.
8. Chelly JE. Paravertebral blocks. *Anesthesiol Clin.* 2012;30:75–90.
9. Renes SH, Bruhn J, Gielen MJ, et al. In-plane ultrasound-guided thoracic paravertebral block: a preliminary report of 36 cases with radiologic confirmation of catheter position. *Reg Anesth Pain Med.* 2010;35:212–6.