

HOSTED BY



ELSEVIER

Available at [www.sciencedirect.com](http://www.sciencedirect.com)

ScienceDirect

journal homepage: [www.elsevier.com/locate/IJMYCO](http://www.elsevier.com/locate/IJMYCO)

# Morphological changes in experimental tuberculosis resulting from treatment with quercetin and polyvinylpyrrolidone

Dmytro O. Butov<sup>a,\*</sup>, Svetlana I. Zaitseva<sup>a</sup>, Mykola M. Pitenko<sup>b</sup>,  
Ganna L. Stepanenko<sup>a</sup>, Tatyana S. Butova<sup>c</sup>

<sup>a</sup> Department of Phthysiology and Pulmonology, Kharkiv National Medical University, 4 Lenina Avenue, Kharkiv 61022, Ukraine

<sup>b</sup> Department of Pathomorphology, Kharkiv National Medical University, 4 Lenina Avenue, Kharkiv 61022, Ukraine

<sup>c</sup> Department of Internal Medicine N3, Kharkiv National Medical University, 4 Lenina Avenue, Kharkiv 61022, Ukraine

## ARTICLE INFO

### Article history:

Received 17 July 2015

Accepted 8 August 2015

Available online 5 September 2015

### Keywords:

Epithelioid cellular granuloma

Experimental model

Morphological changes

Polyvinylpyrrolidone

Quercetin

Treatment of tuberculosis

## ABSTRACT

**Research objective:** Morphological study of tissue necrosis stages in experimental organ-preserving tuberculosis pharmacotherapy using Quercetin and Polyvinylpyrrolidone (QP).

**Background and methods:** 32 laboratory mice of C57BL/6JLacSto strain were used in the experiment. The animals were divided into five groups, six to seven mice in each: group 1- Mycobacterium tuberculosis (MBT) uninfected mice; group 2- MBT infected mice; group 3- MBT infected and treated with antituberculosis preparation (ATP); group 4- MBT infected and QP treated; group 5- MBT infected and treated with ATP and QP. The mice were infected through caudal vein injection with MTB H37Rv strain. The preparation QP, which belongs to the capillary-stabilizing-remedy group, was used for the research. The ATP were isoniazid and streptomycin.

**Results:** QP produced a strict delineation of caseous necrosis from the unaffected parts of the connective tissue with fibrosis in the center and a large number of Langerhans cells, which was not observed in the control groups without QP. The combination of QP and ATP had more pronounced effects. In MBT-infected mice, where QP was not used, unlike the group where QP was used, adipose dystrophy of hepatocytes was observed. Thus, the hepatoprotective effect of QP against TB can be suggested.

**Conclusion:** QP produces a clear delineation of caseous necrosis from an uninfected tissue by connective-tissue formation, and by forming fibrotic tissue in the center of epithelioid cells that prevents further TB dissemination by enhancing TB pharmacotherapy.

© 2015 Asian African Society for Mycobacteriology. Production and hosting by Elsevier Ltd.

All rights reserved.

## Introduction

In recent years in Ukraine, as in many countries, we observed an unstable epidemiological situation connected with

tuberculosis (TB) [1], which became a silent social threat to humanity [2]. Therefore, in April 1993, the World Health Organization (WHO) recognized the fact that TB is a global threat [3]. In addition, TB is the leading disease among all

\* Corresponding author at: Department of Phthysiology and Pulmonology, Kharkiv National Medical University, 4 Lenin Avenue, Kharkiv 61022, Ukraine.

E-mail address: [dddimid@yandex.ua](mailto:dddimid@yandex.ua) (D.O. Butov).

Peer review under responsibility of Asian African Society for Mycobacteriology.

<http://dx.doi.org/10.1016/j.ijmyco.2015.08.003>

2212-5531/© 2015 Asian African Society for Mycobacteriology. Production and hosting by Elsevier Ltd. All rights reserved.

infectious diseases and causes of death worldwide. In 2013, according to the estimations conducted by the WHO, 9.0 million people were infected with TB, and of those 1.5 million died [1].

The results of treatment of patients suffering from destructive pulmonary TB with bacterio excretion in spite of high possibilities of antibacterial therapy remain insufficient [4–6]. Antimycobacterial therapy regimes recommended by the WHO allow achieving negative smear in 67–96.3% of patients suffering from TB [7–9]. One of the factors that increases the treatment efficiency of patients with pulmonary TB is the development of new treatment technologies [4,10,11]. According to most authors, the main modern method of treatment of TB is connected with the integrated approach to the use of antibacterial drugs [12–15]; their use now is urgently needed. Thus, the problem of treatment of patients with destructive pulmonary TB is very topical and difficult.

One reason for the ineffective treatment of TB patients is the insufficient modern view concerning pathomorphism and pathophysiological interacting processes of the macroorganism with *Mycobacterium tuberculosis* (MBT), which dictates the need for the implementation of an integrated effect method into the medical process not only to suppress MBT, but also to preserve lung tissue from further destruction.

Organ preservation from the consequences of TB influences a patient's future life. With the progression of the tuberculous process and myocardial hypoxia, which occurs as a result of the destruction of lung tissue, cardiopulmonary insufficiency develops, from which the patient dies. The restoration of respiratory function in the case of pulmonary TB is an important criterion for clinical treatment, and for the medical and social rehabilitation of patients with respiratory diseases. The aforementioned effects may be obtained by applying an effective treatment.

In each form of TB, immunopathological inflammation caused by the violation of microcirculation and trophic factors of lung tissue occurs, which may be complicated by its melting, secreting of cheesy masses through the bronchi, and the formation of cavities (i.e., the process transition in the destructive form). This worsens the course of TB, resulting in the subsequent loss of a part of or even the whole organ, unless an adequate, effective type of therapy is applied. According to some authors, there is a necessity for a new effective integrated treatment in the therapeutic conditions [16–18]. According to the literature, treatment schedules primarily aim at the destruction of MBT. We have not seen works connected with the application of therapy of organ preservation by limiting the spread of the pathological process, preventing lung-tissue melting and the rapid decline of intoxication syndrome with the restoration of the immune-system functioning. We focused our attention on quercetin with polyvinylpyrrolidone (QP). QP is a chemical compound that is used in clinical practice for the treatment of patients suffering from myocardial infarction. However, in the literature, there is no information on the use of QP in the case of TB. QP is a chemical compound that belongs to a group of capillary-stabilizing drugs and antioxidants (bioflavonoids). The main effect of QP in the treatment of myocardial infarction is the separation of necrosis tissue from healthy areas. Thus, the spreading of necrosis to healthy areas is halted and localization of the pathological process

in the affected organ is observed, which leads to its preservation. The attempt to find out the morphological changes that would confirm the separation of caseous necrosis convinced us to initiate the study on the effectiveness of QP against TB in mice, as a property of the drug consists not only of the effect on "sterile" necrosis, but perhaps also on inflammation in the infectious disease process.

## Materials and methods

Thirty-two laboratory mice of C57BL/6J strain were used in the experiment. The experimental study of QP was conducted according to the literature [19], which provided an example of research of pharmacological compounds in the case of TB in mice.

The mice (17 males and 15 females) were all young (males: 3 months,  $12 \pm 5$  days; females: 3 months,  $26 \pm 5$  days). The weight of the female mice varied from 18.17 g to 19.83 g ( $18.83 \pm 0.52$  g), whereas that of the male mice varied from 19.35 g to 20.47 g ( $19.8 \pm 0.38$  g). None of the animals have been used in any previous research. All animals were kept under the same housing and feeding conditions.

The mice were infected via caudal-vein injection with MBT H37Rv strain [19]—0.5 mL of isotonic solution (according to group), which corresponds to  $2.0 \times 10^7$  microbial bodies of the laboratory strain of MBT H<sub>37</sub>Rv.

The animals were divided into five groups, with six to seven mice in each group: (a) Group 1, MBT-uninfected mice; (b) Group 2, MBT-infected mice; (c) Group 3, MBT infected and treated with anti-TB preparation (ATP); (d) Group 4, MBT infected and treated with QP; and (e) Group 5, MBT infected and treated with ATP and QP. The ATP included isoniazid and streptomycin.

Recalculation of the doses of the drugs used (QP, isoniazid, and streptomycin) for the mice was carried out using the conversion factor of doses between a person and a mouse, which is generally accepted in conducting research [20]. Thus, the drug doses for the mice contained the following: isoniazid (10%, 5 mL), 45 mg/kg; streptomycin (1 g), 90 mg/kg; and QP (0.5 g), 45 mg/kg of the body weight of a mouse. The medicines used in the experiment on the mice were applied as follows: isoniazid and streptomycin, intramuscularly once a day; and QP, intraperitoneally according to a schedule (on the 5th day after the introduction of the infection every 2 h, and then every 12 h; on the 6th day and 7th day two times a day every 12 h).

Based on the literature [19], treatment was performed on the 5th day after the animals had been infected and after pathomorphological (macroscopic and microscopic) confirmation of the presence of the TB process in the mice.

Mouse removal was conducted using chloroform overdose on the 11th day after the introduction of MBT [21].

The lungs, spleens, and livers of the control and experimental groups of animals were used for the morphological examination.

The degree of lesions on the internal organs of the mice and comparisons depending on the character of the given treatment were evaluated macroscopically [22] by the sum of points. The data on index lesions are shown in Table 1.

**Table 1 – Criteria for calculating the index lesions of the internal organs of mice infected with tuberculosis.**

Organ	Index lesion
Liver	Maximum: 5 points No change: 0; increased: 1; increased: +1; focus: 3; many: 5
Spleen	Maximum: 5 points No change: 0; increased: 1–2; increased: +1; focus: 3; many: 5
Abdominal cavity	Maximum: 5 points No change: 0; focus single: 1; several foci: 2; joining foci: 4; general intestinal lesions: 5
Lungs	Maximum: 5 points No change: 0; full blooded: 1–2; single foci of caseous necrosis: 3; several foci: 4; joining foci: 5

In addition, examination of the weight, appearance, and view in of the section (lungs, spleen, and liver) was carried out, from which small pieces of size 0.3 cm × 0.2 cm were cut. The tissue taken was fixed by the use of 10% neutral formalin. Pieces were conducted by uplink concentrations of alcohol, water was removed and covered with paraffin. Then, the pieces were fixed in wooden blocks. The paraffin-embedded pieces were used in the production of histological sections on a microtome to a thickness of 4–6 µm. The sections were painted with hematoxylin and eosin stain using van Gieson's picrofuchsin method. The painted sections were placed on a glass slide and fixed using polystyrene. Tissue specimens were examined using a microscope (Olympus BX41, Tokyo, Japan). The most demonstrative sections were used for the production of color photographs.

The experiment was reviewed and approved by the ethical and bioethical committee of Kharkiv National Medical University in Ukraine. The work was conducted in accordance with the requirements of the European Convention for the Protection of Vertebrate Animals (Strasbourg, March 18, 1986) and the Directive of the Council of the European Economic Society for the Protection of Vertebrate Animals (Strasbourg, November 24, 1986).

## Results

At the final stage of the experiment, all animals were removed following the macroscopic study of the lesion character of the internal organs with TB.

The study of macroscopic changes established the following:

1. The macroscopic study of the internal organs of the intact animals (Group 1) showed no pathological changes. The results of the study are presented in [Table 2](#).
2. In the second group of animals, the macroscopic picture of the internal organs showed active TB and increased liver caseous foci. TB tubercles were observed not only in the lungs, but in other tissues as well. Most of animals tended to joining foci, most foci, and the level of caseous necrosis was higher than in the lungs of the animals belonging to the third, fourth, and fifth groups, which received antibiotic therapy and/or QP treatment. The total index lesions with TB composed ( $11.49 \pm 0.22$  points).
3. The total macroscopic lesion of the group that received QP treatment ( $7.83 \pm 0.22$  points) was significantly lower compared with that of the group that did not receive treatment, and also was not significantly lower in the group that received only ATP ( $8.65 \pm 0.40$  points). In combinations of QP and ATP, we observed a significant decrease in these indicators ( $4.59 \pm 0.31$  points) compared with the group of animals that received only ATP treatment.

The following are the results of the microscopic study:

1. Group 1 (noninfected control mice) showed no specific changes.
2. In the second control group of mice (infected with MBT H37Rv), epithelioid cellular granulomas in the lungs, livers, and spleens were macroscopically and microscopically observed, and were found mostly with caseous necrosis in the center ([Fig. 1](#)). The most striking changes were found in the spleens, and to a lesser extent in the livers

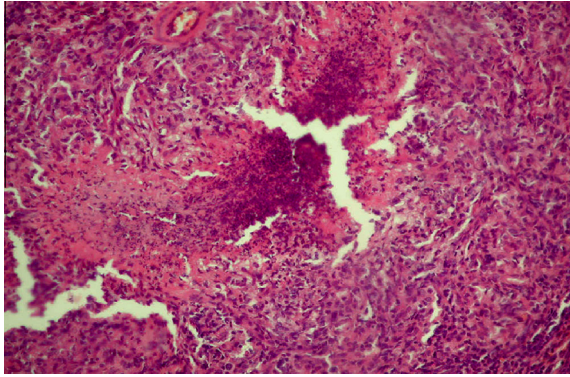
**Table 2 – Effect of isoniazid, streptomycin, and quercetin and polyvinylpyrrolidone, and their combinations on experimental tuberculosis in mice, points ( $M \pm m$ ).**

Groups	Index lesion				
	Liver	Spleen	Abdominal cavity	Lungs	Sum
1	0	0	0	0	0
2	$3.33 \pm 0.21$	$2.33 \pm 0.21$	$1.50 \pm 0.22$	$4.33 \pm 0.21$	$11.49 \pm 0.22$
3	$3.00 \pm 0.36$	$1.66 \pm 0.21$	$1.16 \pm 0.16$	$2.83 \pm 0.16$	$8.65 \pm 0.40$
4	$2.50 \pm 0.22^*$	$1.50 \pm 0.22^*$	$0.50 \pm 0.22^*$	$3.33 \pm 0.21^*$	$7.83 \pm 0.22^*$
5	$1.66 \pm 0.21^{**}$	$0.83 \pm 0.3^{**}$	$0.50 \pm 0.22^{**}$	$1.66 \pm 0.21^{**}$	$4.59 \pm 0.31^{**}$

\* Discrepancy is significant ( $p < 0.05$ ) when compared with Group 2.

\*\* Discrepancy is significant ( $p < 0.05$ ) when compared with Group 3.

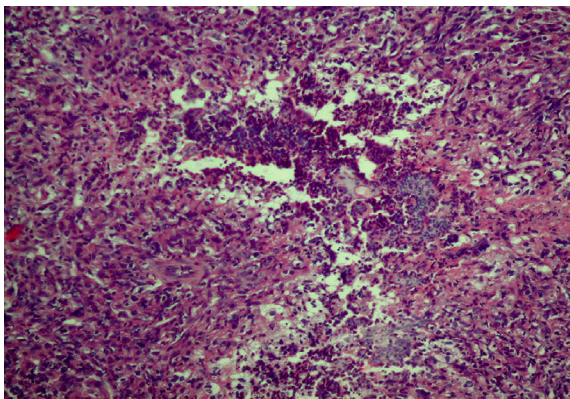




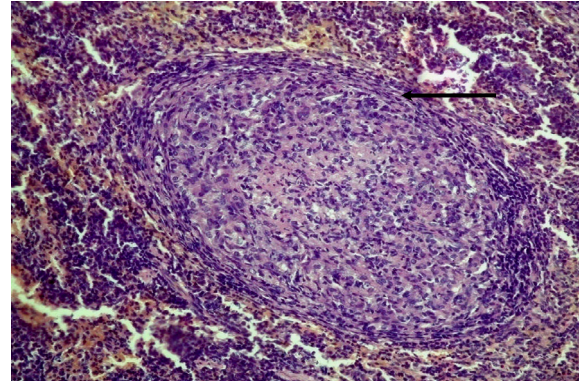
**Fig. 1 – Observation number 3, male, Group 2 (MBT H37Rv infected). A typical epithelioid tubercle in the spleen with caseous necrosis in the center (hematoxylin and eosin stain, original magnification, ×200).**

and lungs. Besides the specific changes, fatty degeneration of varying degrees in the livers and vascular full-blooded in the spleens and lungs were detected.

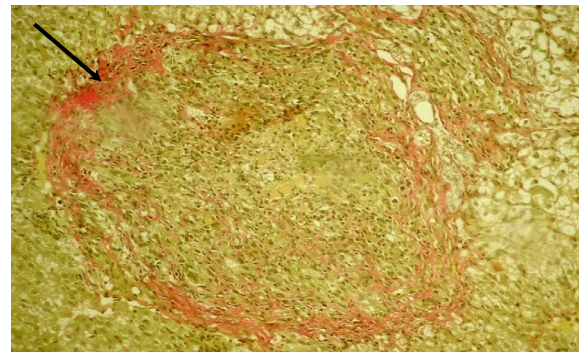
3. In the third control group (infected mice) treated with ATP, epithelioid cellular granulomas were detected, but to a lesser degree and were of smaller size, with caseous necrosis in the center in 50% of the cases (Fig. 2). In the examined organs, vascular full-blooded and fatty degeneration of hepatocytes in the livers were found.
4. In the first experimental group (infected mice) treated with QP, a small number of epithelioid cellular tubercles of smaller size were observed, almost without caseous necrosis, including a limiting area of connective tissue in 50% of the cases (Figs. 3 and 4). Giant multinucleate Langhans cells and lymphocytes were found. Some epithelioid cellular tubercles were fibrotized.
5. The smallest number of tubercles was found in the second experimental group (infected mice) treated with QP and ATP. The microscopic investigation showed epithelioid cellular tubercles without necrosis in the center, with an area



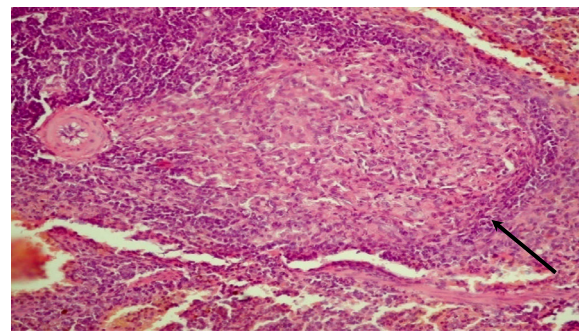
**Fig. 2 – Observation number 23, male, Group 3 (MBT H37Rv infected and treated with antituberculosis preparation). A typical epithelioid tubercle in the spleen with caseous necrosis in the center (hematoxylin and eosin stain, original magnification, ×200).**



**Fig. 3 – Observation number 25, male, Group 4 (MBT H37Rv infected and treated with quercetin and polyvinylpyrrolidone). An epithelioid tubercle in the spleen with distinct limiting area of connective tissue with fibrotization in the center (hematoxylin and eosin stain, original magnification, ×200).**

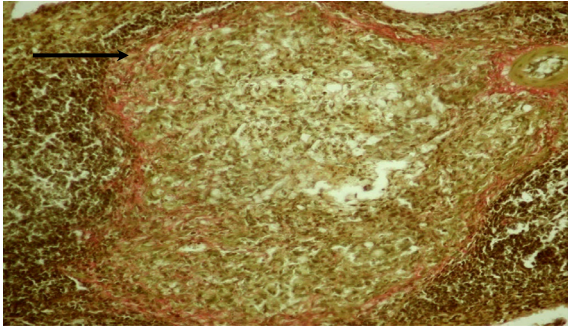


**Fig. 4 – Observation number 2, male, Group 4 (MBT H37Rv infected and treated with quercetin and polyvinylpyrrolidone). An epithelioid tubercle in the spleen with distinct limiting area of connective tissue with fibrotization in the center (van Gieson's stain, original magnification, ×200).**

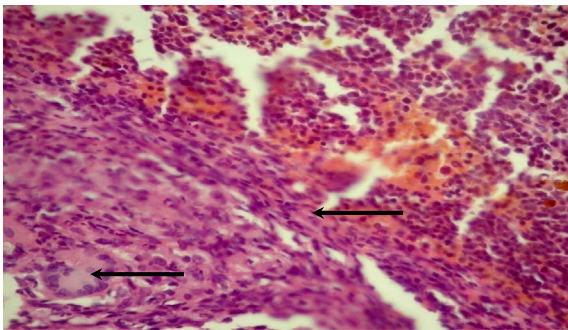


**Fig. 5 – Observation number 18, female, Group 5 (MBT H37Rv infected and treated with antituberculosis preparation and quercetin and polyvinylpyrrolidone). An epithelioid tubercle in the spleen with distinct limiting area of connective tissue with fibrotization in the center (hematoxylin and eosin stain, original magnification, ×200).**





**Fig. 6 – Observation number 6, female, Group 5 (MBT H37Rv infected and treated with antituberculosis preparation and quercetin and polyvinylpyrrolidone). An epithelioid tubercle in the spleen with distinct limiting area of connective tissue (van Gieson's stain, original magnification,  $\times 200$ ).**



**Fig. 7 – Observation number 6, female, Group 5 (MBT H37Rv infected and treated with antituberculosis preparation and quercetin and polyvinylpyrrolidone). An epithelioid tubercle in the spleen with distinct limiting area of connective tissue with giant multinucleate Langhans cell (hematoxylin and eosin stain, original magnification,  $\times 400$ ).**

of connective tissue limited from the surrounding tissue with fibrotization in the center (Figs. 5 and 6). A large number of giant multinucleate Langhans cells (Fig. 7) and lymphocytes are observed. No fatty degeneration of hepatocytes in the liver was found.

## Conclusions

Under the influence of QP, the separation of caseous necrosis of granulomas from unaffected areas begins through connective tissue with fibrotization in the central part and a large number of Langhans cells and lymphocytes that are not observed in the control groups. The interaction of QP with anti-TB drugs shows more obvious effects: fast tendency of epithelioid cellular tubercles to fibrotization and separation of TB granulomas through connective tissue. In addition, in the control groups of animals infected with TB, in contrast to the experimental groups, fatty degeneration of hepatocytes is observed. Thus, we have shown the hepatoprotective function of QP against TB.

## Conflicts of interest

The authors have declared that no competing interests exist. The study was supported by the President of Ukraine scholarship grant for gifted youth. The funder had no role in the study design, data collection and analysis, decision to publish, or preparation of the manuscript.

## Acknowledgments

The authors thank the Mechnikov Institute of Microbiology and Immunology of the National Academy of Medical Sciences of Ukraine, where this study was conducted. The wholehearted support of the laboratory personnel who contributed their effort made this study possible. The authors' gratitude is expressed to the many experts in tuberculosis and immunology fields who kindly shared their opinions and critiques prior to and after the completion of this study.

## REFERENCES

- [1] World Health Organization, Global tuberculosis report 2014: WHO report 2014, World Health Organization, Geneva, 2014.
- [2] R.T. Bell, *Tuberculosis of the 1990s: the quiet public health threat*, Pa Med. 95 (1992) 24–25.
- [3] M. Tool, C. Drummond, N. Binkin, et al, *Tuberculosis Control in Refugee Situations: An Inter-agency Field Manual*, World Health Organization, Geneva, 1997.
- [4] World Health Organization, *The Use of Delamanid in the Treatment of Multidrug-resistant Tuberculosis: Interim Policy Guidance*, World Health Organization, Geneva, 2014.
- [5] J.T. Wu, C.T. Chiu, Y.F. Wei, et al, *Comparison of the safety and efficacy of a fixed-dose combination regimen and separate formulations for pulmonary tuberculosis treatment*, Clinics (Sao Paulo) 70 (2015) 429–434.
- [6] S. Kasozi, J. Clark, S.A. Doi, *Intermittent versus daily pulmonary tuberculosis treatment regimens: a meta-analysis*, Clin. Med. Res. (2015). <http://www.clinmedres.org/content/early/2015/06/04/cm.2015.1272.full.pdf+html>.
- [7] J.D. Walley, M.A. Khan, J.N. Newell, et al, *Effectiveness of the direct observation component of DOTS for tuberculosis: a randomized controlled trial in Pakistan*, Lancet 357 (2001) 664–669.
- [8] R. Singla, N. Al-Sharif, M.O. Al-Sayegh, et al, *Influence of anti-tuberculosis drug resistance on the treatment outcome of pulmonary tuberculosis patients receiving DOTS in Riyadh, Saudi Arabia*, Int. J. Tuberc. Lung Dis. 6 (2002) 585–591.
- [9] T. Santha, R. Garg, T.R. Frieden, et al, *Risk factors associated with default, failure and death among tuberculosis patients treated in a DOTS programme in Tiruvallur District, South India, 2000*, Int. J. Tuberc. Lung Dis. 6 (2002) 780–788.
- [10] K. Klinger, K.M. Tchou-Wong, O. Brandi, et al, *Effects of mycobacteria on regulation of apoptosis in mononuclear phagocytes*, Infect. Immun. 65 (1997) 5272–5278.
- [11] D.A. Butov, Y.N. Pashkov, A.L. Stepanenko, et al, *Phase IIb randomized trial of adjunct immunotherapy in patients with first-diagnosed tuberculosis, relapsed and multi-drug-resistant (MDR) TB*, J. Immune Based Ther. Vaccines 9 (2011) 3. <http://www.jibtherapies.com/content/9/1/3>.
- [12] M. Bland, *An Introduction to Medical Statistics*, third ed., Oxford University Press, Oxford, 2000. pp. 335–347.
- [13] A.S. Bourinbaia, M.V. Mezentseva, D.A. Butov, et al, *Immune approaches in tuberculosis therapy: a brief overview*, Expert Rev. Anti Infect. Ther. 10 (2012) 381–389.

- 
- [14] Z. Boras, A. Juretić, M. Rudolf, et al, Cellular and humoral immunity to purified protein derivative (PPD) in PPD skin reactive and nonreactive patients with pulmonary tuberculosis: comparative analysis of antigen-specific lymphocyte proliferation and IgG antibodies, *Croat. Med. J.* 43 (2002) 301–305.
- [15] B.A. Eisaev, Results of the treatment of patients with recurrence of pulmonary tuberculosis with different types of haptoglobin, *Probl. Tuberk.* 6 (1995) 20–22.
- [16] F.E. Vartanian, K.P. Shakhovskii, Tuberculosis: problems and research in the world's countries, *Probl. Tuberk.* 2 (2002) 48–50.
- [17] D.A. Butov, Y.V. Efremenko, N.D. Prihoda, et al, Adjunct immune therapy of first-diagnosed TB, relapsed TB, treatment-failed TB, multidrug-resistant TB and TB/HIV, *Immunotherapy* 4 (2012) 687–695.
- [18] B.R. Bloom, *Tuberculosis: Pathogenesis, Protection, and Control*, ASM Press, Washington, DC, 1994.
- [19] F.P. Fisenko (Ed.), *Manual on Experimental (Preclinical) Study of New Pharmacological Substances*, "TSIA Remedium" Ltd., Moscow, 2000.
- [20] Y.R. Rybolovlev, R.S. Rybolovlev, Dosage of matters for mammals on the constant of biological activity, *J. Acad. Med. Sci.* 247 (1976) 1513–1516.
- [21] M.B. Rappoport, On methods of killing of laboratory animals, *Lab Delo* 6 (1967) 363–364.
- [22] R.O. Drabkina, T.S. Ginzburg, Efficiency intermittent treatment of tuberculosis (experimental research), *Antibiotics* 6 (1972) 555–560.