

Available online at
ScienceDirect
www.sciencedirect.comElsevier Masson France
EM|consulte
www.em-consulte.com/en

Special Vol. 100

Femoral and tibial bone torsions associated with medial femoro-tibial osteoarthritis. Index of cumulative torsions[☆]

F. Duparc^{a,*}, J.M. Thomine^a, J. Simonet^b, N. Biga^a^a Clinique chirurgicale orthopédique et traumatologique, hôpital Charles-Nicolle, 1, rue de Germont, 76031 Rouen cedex, France^b Service de radiologie centrale, hôpital Charles-Nicolle, 1, rue de Germont, 76031 Rouen cedex, France

ARTICLE INFO

Keywords:

Knee
Knee osteoarthritis
Bone torsion
CT scan

ABSTRACT

Frontal plane varus deviation is one of the mechanisms hypothesized to be involved in the pathogenesis of medial compartment osteoarthritis of the knee. But only a few authors have suggested a role for tibial and femoral torsion. In the current study, CT scan was used to measure bone torsion. The torsional morphology of the lower limb was defined by the “index of cumulative torsions” (ICT). The resulting values were compared to the frontal angular deviation data. The effects of tibial and femoral torsion on the position of the lower limb during the stance phase of walking and the consequences for the knee are discussed.

© 2013 Published by Elsevier Masson SAS.

1. Introduction

In patients where the frontal plane mechanical alignment is altered and the lateral stays are weak or missing, lower limb bone torsion has been proposed to contribute to knee osteoarthritis [1,18,21,22], based on Maquet's classic diagram [16]. Research on bone torsion in knee osteoarthritis has mostly been carried out on the tibia or the entire leg. Yagi [22] looked at 85 limbs with medial compartment osteoarthritis of the knee and found a relationship between lack of external tibial torsion and the progression of osteoarthritis. Takai [18] looked at 43 patients and found that external tibial torsion was 5° less on average in patients with knee osteoarthritis than in a control group. He suggested a correlation between femoral torsion and leg torsion, and secondary decrease in external leg torsion during the progression of medial compartment osteoarthritis. Turner and Smillie [21] found low external tibial torsion in cases of multi-joint arthritis (12.4° ± 6.4°). Conversely, single-compartment osteoarthritis had an average tibial torsion of 19.0° ± 6.3°, which was similar to the average value of the control group.

The concept of overall lower limb morphology and its correlation with foot angle during gait can be attributed mainly to Lerat's work on patellar instability [15]. The greatest merit of his reasoning was considering the entire lower limb as being made of several bone

segments having variable torsion that are connected by joints having similarly variable rotational potential. The tibiofemoral index described by Lerat was the basis for our work.

The goal of the current study was to evaluate tibial and femoral torsions in a series of knees affected by medial compartment osteoarthritis and to relate these back to each patient to identify the torsional bone morphology of the involved limb.

2. Materials and methods

Forty-seven knees in 25 patients (7 men, 18 women) having an average age of 64.8 years (range 57 to 73) and suffering from medial compartment osteoarthritis in varus were evaluated before they underwent surgery. Osteoarthritis was classified using standard, weight bearing A/P radiographs according to the four stages proposed by Debeyre [2] (Table 1).

Tibiofemoral misalignment in the frontal plane was measured on standing A/P long-leg radiographs. Full-frontal knee position was defined by the projection of the tip of the patella through the femur's intercondylar notch.

The femur and tibia mechanical axes were traced onto these radiographs, along with the load bearing axis for each limb, defined as a line projected from the second sacral vertebra to the middle of the ankle mortise. The varus tibiofemoral angles and the intrinsic, extrinsic and total varus deviations were measured [20].

2.1. Measurement of bone torsion

Tibial and femoral torsions were evaluated on templates over the CT scan slices; each measurement was performed by the same operator and repeated twice [4]. With the patient in

[☆] Original article. For citation, use not the present reference but that of the original publication: Duparc F, Thomine JM, Simonet J, Biga N. [Femoral and tibial bone torsions associated with internal femoro-tibial osteoarthritis. Index of cumulative torsions]. *Rev Chir Orthop Reparatrice Appar Mot* 1992;78(7):430-7.

* Corresponding author.

E-mail address: rcot@sofcot.fr (F. Duparc).

Table 1
Distribution of the osteoarthritis stage in the 47 knees included in this study (according to the Debyre [2] classification).

Stage	Description	Number
Stage I	< 50% joint space narrowing	5/47
Stage II	50% joint space narrowing	6/47
Stage III	> 50% joint space narrowing with articular surfaces that may be touching	33/47
Stage IV	Severe osteoarthritis with dislocation and lateral or anteroposterior subluxation	3/47

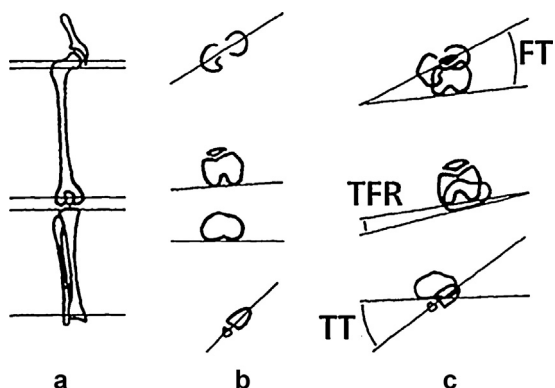


Fig. 1. a: slice levels; b: axis lines; c: angle measurements; FT: femoral torsion; TT: tibial torsion; TFR: tibiofemoral rotation.

dorsal decubitus and the lower limbs immobilized by sand bags in a spontaneous, resting position with the knees extended, five transverse slice planes were defined and then used to trace four axes and to measure three angles (Fig. 1).

A - Slice topography:

- slice 1 went through the middle of the femoral head;
- slice 2 went through the middle of the base of the femoral neck. These two slices were superimposed on the template to trace axis I of the superior femoral epiphysis; this takes into account the orientation and inclination of the neck, which would not be captured if only one slice had been used;
- slice 3 was defined as the best posterior contour of the femoral condyles, typically located 20 mm above the joint line [3];
- slice 4, which passes through the best posterior contour of the tibial plateaus, was used to trace axis III of the proximal tibial epiphysis;
- slice 5, which passes through the distal tibial epiphysis at the level of the talotibial joint line, was used to trace axis IV of the distal tibial epiphysis.

B - Axes:

- axis I of the proximal femoral epiphysis was defined above;
- axis II of the distal femoral epiphysis was represented by a line tangent to the posterior condyles;
- axis III of the proximal tibial epiphysis was represented by a line tangent to the posterior contours of the tibial plateaus;
- axis IV of the distal tibial epiphysis corresponded to the transverse major axis of the epiphysis.

C - Torsion angles:

femoral torsion (FT) was defined as the angle between axes I and II. If axis II was oriented posterior to axis I, FT (or anteversion) was internal, thus recorded as a negative value by convention. Tibial torsion (TT) was defined as the angle between axes III and IV. Since tibial torsion is typically external, it was recorded as a positive value. The third angle was tibiofemoral rotation (TFR), which was defined as the angle between axes II and III.

Tibiofemoral rotation



Fig. 2. The knee is a hinge between two segments with opposing torsion.

2.2. Reference values

The average normal femoral torsion in adults is $-14^\circ \pm 6^\circ$ [3,12,15].

Based on anthropometric and cadaver data [5,12,14], clinical studies [5,7], radiology studies [6,17] and CT scan studies [3,8–11,13], a range of 24° to 30° seems to correspond to normal values for external tibial torsion for patients of European origin. Values for Japanese people were lower overall.

Tibiofemoral rotation represents the position of the proximal tibial epiphysis relative to the distal end of the femur in a non-weight bearing, resting position with the knee in full extension; in theory, it does not have a normal value while in extension. Lerat [15] found the average rotation between the femoral condyles and tibial plateaus to be 3° (Fig. 2).

Measurements of hip rotation: none of the patients had hip osteoarthritis. External hip rotation (EHR) and internal hip rotation (IHR) have been measured clinically. Normal values range from 40° to 50° for EHR and 30° to 45° IHR.

3. Results

3.1. Femoral torsion (Fig. 3a)

The average FT was -16° in the studied group. Although this was close to normal values, the minimum and maximum values (-31° to $+3^\circ$) revealed large variability in measured FT. Twenty-six femurs had very high FT of less than -16° , with 14 of them having values less than -20° , which corresponded to excessive anteversion. Twenty-one femurs had greater than -16° torsion, with three having no torsion or positive torsion, which was evidence of femoral retroversion.

3.2. Tibial torsion (Fig. 3b)

Tibial torsion was always external. The average TT was $27.7^\circ \pm 11.6^\circ$. Although this was close to published normal values, the minimum and maximum values ($+9^\circ$ to $+45^\circ$) revealed large variability in this measurement also. Fifteen of the 47 limbs had values that could be considered normal, 17 had strong external tibial torsion and 14 had weak external tibial torsion (less than 24°). The distribution was fairly homogeneous around the normal range.

3.3. Tibiofemoral rotation (Fig. 4)

Tibiofemoral rotation was external on average $3^\circ \pm 5.47^\circ$ and not very pronounced (-7° to $+15^\circ$). Only nine limbs had negative values (intra-articular internal rotation).

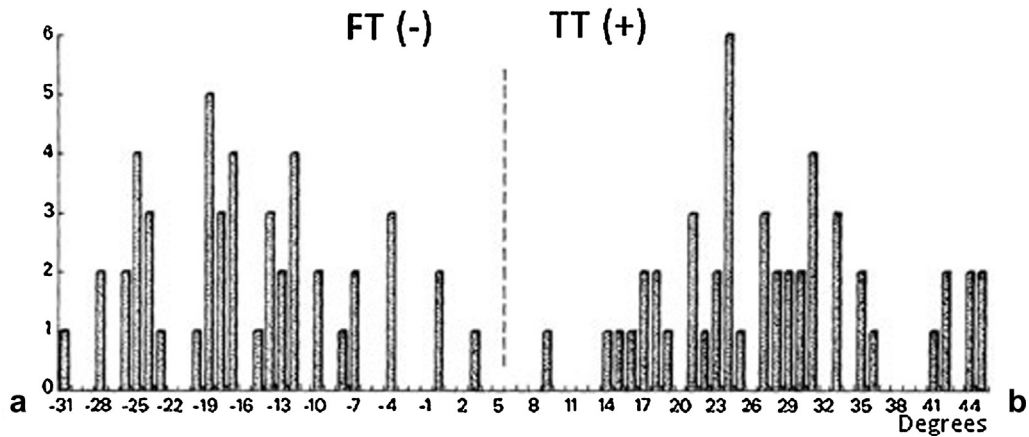


Fig. 3. Value of the femoral and tibial torsions in degrees (n = 47).

3.4. Hip rotation

Internal hip rotation (Fig. 5a) had an average value of 21.8° (0 to 40°). Fifteen limbs had a limited amount of internal rotation (−10° to 0). External hip rotation had an average value of 32° (0 to 45°). Three limbs had 10° or less external hip rotation (Fig. 5b).

3.5. Index of cumulative torsions

In every patient, we calculated the algebraic sum of the tibial and femoral torsions, which we called the index of cumulative

torsions (ICT) (Fig. 6). The 11.7° average in the study group seemed to correspond to the sum of the known normal values of FT and TT, but this index was also highly variable (7° to +32°) (Fig. 6). Only 17 of our patients had an ICT between 10° and 20°, which corresponds to the normal TT and FT values added together. These patients were placed in the Medium ICT group.

On either side of this group were limbs having an overall bone morphology labeled as either Low ICT (less than 10°) or High ICT (greater than 20°).

3.5.1. Medium ICT group

The average index value was 14° in the Medium ICT group (17 of 47 patients). This ICT combined the following average torsion values:

- FT: −15.1°, TT: 29.2° with TFR of 3.3°;
- the average tibiofemoral varus was 5.3°;
- intrinsic varus deviation: 17.7 mm; extrinsic varus deviation: 37.2 mm; total varus deviation: 54.9 mm;

The average hip rotation values were 33° for EHR and 25° for IHR.

- patients with a medium ICT had a combination of average femoral torsion and tibial torsion values.

3.5.2. Low ICT

The average index value was 1.0° in the Low ICT group (21 of 47 patients). This ICT combined the following average torsion values:

- FT: −20.3°, TT: 22.2° with TFR of 5°;
- the average tibiofemoral varus was 6°, which was related to an intrinsic varus deviation of 20.6 mm, extrinsic varus deviation of 37.3 mm, and total varus deviation of 58 mm;
- the average values for hip rotation were nearly normal: 30° for EHR and 24° for IHR;
- patients with a low ICT had a combination of high femoral anteversion and low external tibial torsion values.

3.5.3. High ICT

The average index value was 30.1° in the High ICT group (9 of 47 patients). This ICT combined the following average torsion values:

- FT: −7.5°; TT: 37.7°;
- the average tibiofemoral rotation was −1.7°, which corresponds to internal rotation of the tibia relative to the femur;
- there was a significant amount of tibiofemoral varus: 9.3°;
- intrinsic varus deviation: 30.1 mm; extrinsic varus deviation: 37.0 mm; total varus deviation: 67.1 mm;

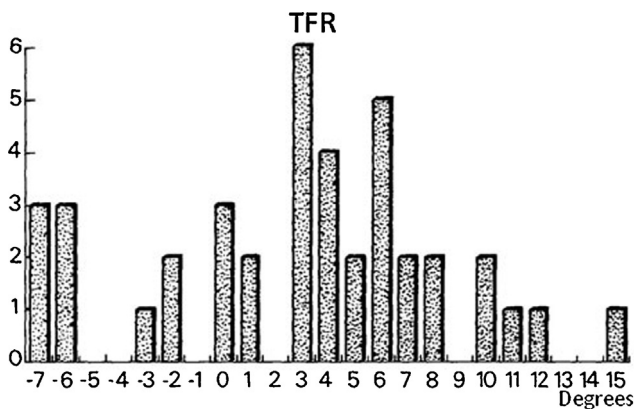


Fig. 4. Value of the tibiofemoral rotation in degrees.

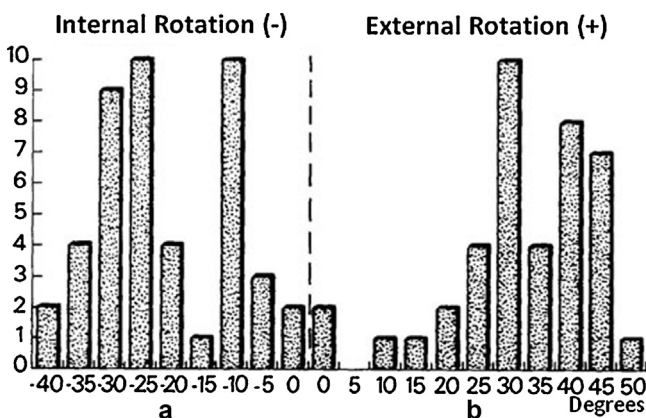


Fig. 5. a: internal hip rotation is labelled as negative; b: external hip rotation is labelled as positive.

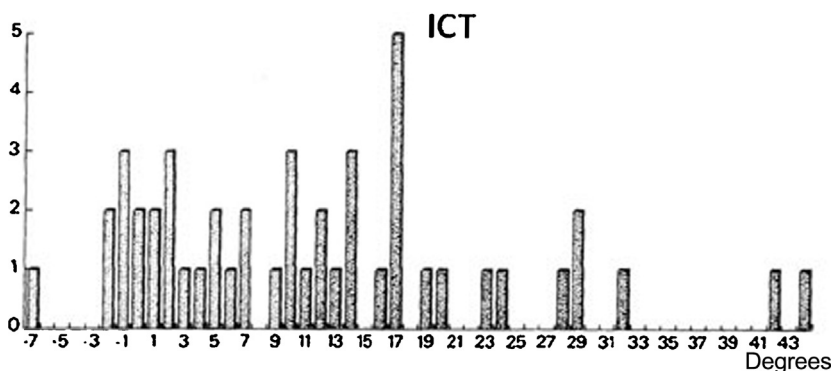


Fig. 6. The index of cumulative torsions (ICT) is the sum of the tibial torsion and femoral torsion in the lower limb.

- external hip rotation (34.3°) and internal hip rotation (12.5°) were notable because of inadequate internal rotation in every patient in this sub-group, and no rotation at all in two of them;
- patients with a high ICT had a combination of low femoral anteversion and high external tibial torsion values with reduced internal knee rotation and internal hip rotation.

3.6. Correlations

3.6.1. ICT and hip rotation

Internal and external hip rotations were normal in the low and medium ICT groups. Only the high ICT patients had insufficient internal hip rotation.

3.6.2. ICT and varus

Tibiofemoral varus was especially pronounced in the high ICT group (9.3°), although this misalignment was not related to the joint in more severe osteoarthritis. The total and intrinsic varus deviations were higher in the high ICT patients. The external varus deviations were similar in every group.

3.6.3. ICT asymmetry between a patient's two legs

In 7 of 25 patients, the left and right limbs were in different ICT groups. The average difference was 17° . This asymmetry involved tibial torsion in five cases and femoral torsion in two cases.

4. Discussion

4.1. Methods

The measurement of torsion on CT scans is justified due to its reliability, reproducibility and ease of angle measurement. It has been used and validated in several published studies [3,6,8–11,13,15,18,19,22]. Clinical methods such as tomography and radiology are more difficult to perform and the results are more random. In addition, they have been described in the context of patellar instability or in children – younger patients than in our study.

Selection of slice planes:

- proximal femoral epiphysis: By determining this axis on two slices, the femoral neck inclination can be taken into account [19];
- the posterior condylar axis is easier to find than the major axis of the epiphysis; this axis passes through the middle of the condylar surfaces or bisects the anterior and posterior tangents;
- the proximal tibial slice level is harder to define and can be the source of errors. It must be as close as possible to the tibial plateau plane, but arthritis-related bone changes can make it difficult to find. Jakob [10] and Yagi [22] pointed out that tibial torsion mainly

occurs in the first 4 cm of the tibia. As a consequence, we selected slices that were as proximal as possible and avoided slices passing through the proximal tibiofibular joint line;

- the distal tibial epiphysis has an easy-to-trace major axis that is placed slightly ahead of the bimalleolar axis, but landmarks on the latter seem to be random. We based our choice of tibial torsion measurement on these findings. Use of the condylar-malleolar angle would not have allowed us to evaluate tibiofemoral rotation and would have resulted in excessively high torsion values.

Sub-malleolar detorsion was not evaluated in this study of lower limb morphology. In our opinion, measurements performed with the patient lying down using the CT scan landmarks proposed by Lerat [15] were too far away from angles measured with foot scanners and the forefoot position during the stance phase of walking. Furthermore, immobilizing the foot would change the limb position and tibiofemoral rotation during the CT scan.

Acetabular anteversion was also not measured. Theoretically it could affect the magnitude of hip rotation and its distribution around the 0 point. It could also affect the rotational positions actually used during walking.

5. Results

In the current patient series, tibial torsion was not consistently low as found in other published studies [18,21,22].

The femoral torsion was extremely variable, with a large number of high or low anteversion femurs. Up to now, this point has not been discussed relative to knee osteoarthritis.

Kobyliansky [12] observed a statistically significant relationship between femoral torsion and tibial torsion. We could not verify his finding in the current study.

The index of cumulative torsions cannot be compared to the findings of Lerat [15] and Deprey [3] because these authors evaluated either patellar instability or torsional problems during walking in subjects without osteoarthritis. However, similar to their studies, the ICT revealed different morphology amongst arthritis patients. Based on these statistical observations, we can put forward hypotheses about its dynamic consequences and the assumed effects on walking and the position of the knee plane during weight bearing.

Hypotheses:

- A) in patients with medium ICT (Fig. 7), superimposing the axes from the proximal femur epiphysis axis, which was arbitrarily placed in the frontal plane, places the oblique foot axis outside the walking direction. The resulting 14° angle corresponds to the medium ICT and represents a normal foot angle, based on the reference value [15] if submalleolar detorsion is not taken into

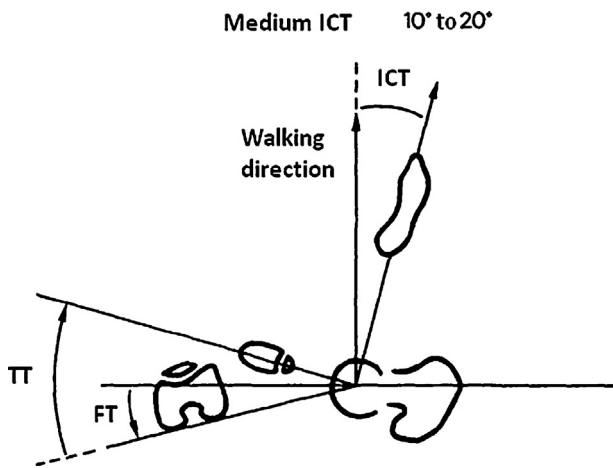


Fig. 7. Medium ICT 10° to 20°: The foot angle determined by adding bone torsions corresponds to a normal value.

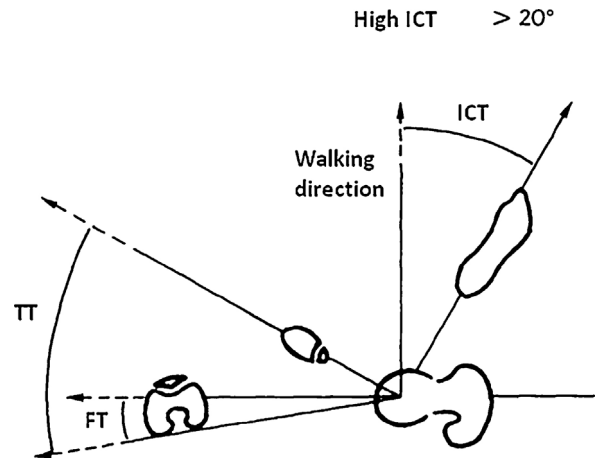


Fig. 9. High ICT 20°: Internal hip rotation cannot theoretically compensate for an excessively open foot angle.

account. This group could be labeled as having a “balanced torsional morphology”. The knee flexion plane is near the sagittal plane.

In cases of lateral compartment osteoarthritis, altered load distribution on the tibial plateau integrates itself in the explanation of the mechanical model of varus arthritis pathogenesis in the frontal plane proposed by Maquet [16]. This scenario was present in 17 of the 47 knees evaluated;

- B) the low ICT group was defined by the sum of high femoral anteversion and low external tibial torsion. If the structure (Fig. 8) were identical to the previous one, the foot would be placed in an axis nearly parallel to the walking direction. The foot angle can only be opened by externally rotating the hip. Based on our clinical measurements (EHR of 30°), this is a possibility.

If we agree with Maquet [16] that the knee is always in flexion during walking, any external hip rotation that separates the knee flexion plane from the sagittal plane could increase varus loads during weight bearing. It is well-known that the coronal projection of a flexed externally rotated knee results in tibiofemoral varus. In other terms, the knee centre moves forward and outside of the centre of gravity line, which increases the total varus deviation;

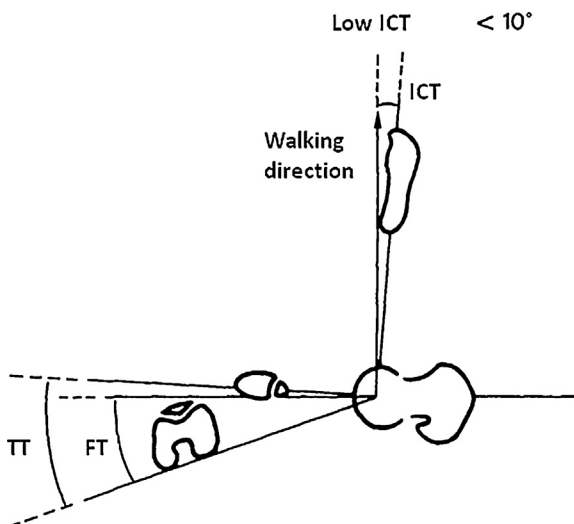


Fig. 8. Low ICT 10°: Along with opening the foot angle, the hip can also be externally rotated.

- C) in the high ICT patients, superimposing the various axes places the foot axis quite far away from the walking direction (Fig. 9). Correcting this overall limb orientation could theoretically be accomplished by internally rotating the hip. But this was consistently limited in the current study. However, tibiofemoral rotation was negative (internal) in this group only. This group also had the greatest amount of varus.

This led us to hypothesize that internal tibiofemoral rotation can partially compensate for this, which would then induce shear stresses on the cartilage and alter the load distribution on the tibial plateaus.

This internal knee rotation is not very large in extension, but is probably easier to accomplish during flexion because of rotational release.

6. Conclusion

By analyzing 47 knees with medial compartment osteoarthritis, we were able to evaluate the overall morphology of the lower limbs, while adding bone torsion measurements to the standard frontal data to provide evidence of gravity-induced, varus stresses.

The ICT appears to be the “regulatory ticket” for the limb. It corresponds to the angle resulting from combined tibial and femoral torsion. It can be used to determine the joint compensation angle needed to obtain a given foot angle. This adaptation can occur at three levels: hip (EHR could contribute to opening the foot angle in low index limbs); knee (internal knee rotation could contribute to reducing the foot angle in high index limbs); submalleolar detorsion (but this was not taken into consideration and should be evaluated in future studies).

Although different limbs can have similar a frontal plane projection when measured with a goniometer, taking into account bone torsion, walking habits and joint potentials could help to explain the pathogenesis of knee osteoarthritis and to explore treatment options.

Disclosure of interest

Authors’ disclosure of conflict of interest was not requested when the article was originally published.

References

[1] Blaimont P, Schoon R. À propos de deux cas de gonarthrose associée à un vice de torsion interne du tibia. *Acta Orthop Belg* 1977;43:476–80.

- [2] Debeyre J, Artigou JM. Les indications et les résultats de l'ostéotomie tibiale; influence de la laxité. *Rev Chir Orthop* 1973;59:641–56.
- [3] Deprey F [Thèse médecine, Reims] Place de l'ostéotomie tibiale de rotation dans le traitement des anomalies torsionnelles isolées des membres inférieurs (à propos d'une série de 92 cas); 1989.
- [4] Duparc F [Thèse médecine, Rouen] Gonarthrose et torsions; 1990.
- [5] Dupuis PV. La torsion tibiale, sa mesure, son intérêt clinique, radiologique et chirurgical. Paris: Masson; 1951.
- [6] Duvauferrier R, Blanc G, Fouche M, Catier P. Une méthode radiologique de mesure de la torsion du squelette jambier. Confrontation anatomique et tomodesitométrique. *Ann Radiol* 1980;23:605–8.
- [7] Elftmann H. Torsion of the lower extremity. *Ann J Phys Anthropol* 1945;3:255–65.
- [8] Garz G, Garz W, Buttner-Janz K. Computertomographische Messung der Tibia-torsion. *Radiol Diagn* 1988;29:215–20.
- [9] Ise N. Torsion of the lower extremity. *J Jpn Orthop Assoc* 1976;50:157–68.
- [10] Jakob RP, Haertel M, Stussi E. Tibial torsion calculated by computerized tomography and compared to other methods of measurement. *J Bone Joint Surg (Br)* 1980;6:238–42.
- [11] Jend MH, Heller M, Dallek M, Sghoettle H. Measurement of tibial torsion by computed tomography. *Acta Radiol (Diagn)* 1981;22:271–6.
- [12] Kobylansky E, Weissman SL, Nathan M. Femoral and tibial torsion. A correlation study in dry bones. *Int Orthop (SICOT)* 1979;3:145–7.
- [13] Laasonen EM, Jokio P, Lingholm TS. Tibial torsion measured by computed tomography. *Acta Radiol (Diagn)* 1984;25:325–9.
- [14] Damany LE. La torsion du tibia normale, pathologique, expérimentale. *JANAT (Paris)* 1909;45:598.
- [15] Lerat JL. Morphotypes des membres inférieurs de l'adulte. Symposium SOFCOT: les anomalies de rotation des membres inférieurs. *Rev Chir Orthop* 1982;68:1–71.
- [16] Maquet PGJ. Biomécanique du genou. Application à la pathogénie et au traitement chirurgical de la gonarthrose. Berlin: Springer Verlag; 1977.
- [17] Massare C. Place de la radiologie dans les mesures de la torsion des membres inférieurs. *Acta Orthop Belg* 1977;43:487–510.
- [18] Takai SK, Sakadjda K, Yamashjta F, Sozo F, Izuta F. Rotational alignment of the lower limb in osteoarthritis of the knee. *Int Orthop (SICOT)* 1985;9:209–16.
- [19] Terver S. Critique de l'utilisation du scanner dans les mesures des torsions et des rotations. *Ann Orthop Ouest* 1982;14:44–6.
- [20] Thomine JM, Boudjema A, Gibon Y, Biga N. Les écarts varisants dans la gonarthrose: fondement théorique et essai d'évaluation pratique. *Rev Chir Orthop* 1981;67:319–27.
- [21] Turner MS, Smillie JS. The effect of tibial torsion on the pathology of the knee. *J Bone Joint Surg (Br)* 1981;63:396–8.
- [22] Yagi T, Sasaki T. Tibial torsion in patients with medial types osteoarthritic knee. *Clin Orthop* 1986;213:177–82.