

# HEMIPELVECTOMY: ERASTO GAERTNER HOSPITAL'S EXPERIENCES WITH 32 CASES IN 10 YEARS

Rosyane Rena de Freitas<sup>1</sup>, André Luiz Soares Crivellaro<sup>1</sup>, Glaucio José Pauka Mello<sup>2</sup>, Mário Armani Neto<sup>2</sup>, Geraldo de Freitas Filho<sup>2</sup>, Leticia Viani da Silva<sup>3</sup>

## ABSTRACT

*Objective:* To show the experience of the Erasto Gaertner Hospital with hemipelvectomy surgery over a 10-year period. *Methods:* This was a retrospective study on 32 patients who underwent hemipelvectomy at Erasto Gaertner Hospital between 1998 and 2008, assessing clinical and surgical characteristics. *Results:* Among the 32 patients, 15 were female and 17 were male. The mean age was 37.94 years. Eight cases showed involvement of the neurovascular bundle: three were located in the iliac and extended to the thigh, two were in the acetabulum and extended to the thigh and three were in the acetabulum and pubis. Twenty-three cases presented a neurovascular bundle free from neoplasia: 11 were restricted to the iliac, six were in the acetabular region, two were in the pubic ramus and four extended to the whole hemipelvis bone. One case involved the iliac-femoral vessels: one in the pubic ramus. Seven cases of chondrosarcoma and four cases of Ewing's sarcoma represented the majority. Eight cases underwent external hemipelvectomy and 24 underwent internal hemipelvectomy (11 were type I; four were type II; two were type II + III; three were type III and four were type IV). Of these 24 cases, 13 did not have any reconstruction, 10 had a fibular graft and one had an iliac-femoral vein and artery prosthesis. Twenty-six surgeries were curative and six were palliative. There were 14 deaths. Survival of two and five years was seen in 11 and 10 cases, respectively. For six cases, less than two years had passed since the operation. Three cases were lost during follow-up. *Conclusion:* This study shows the experiences of an oncology reference service specializing in highly complex surgical treatment.

**Keywords** – Hemipelvectomy; Pelvic neoplasms; Pelvis

## INTRODUCTION

The bones of the pelvic region are the site for less than 5% of all malignant bone tumors. Despite this rarity, they constitute a separate chapter regarding bone tumor treatment because of the anatomical complexity of this region. They therefore remain a problem that is difficult to solve, even today<sup>(1,2)</sup>.

External hemipelvectomy (resection of entire hemipelvis, including the lower limb) is especially indicated for patients with extensive tumors that compromise the hemipelvis with involvement of the root of the thigh. However, with the development of new chemotherapy drugs, radiotherapy, diagnostic methods and surgical techniques, increasing numbers of patients have been

undergoing limb-preserving surgery (internal hemipelvectomy)<sup>(1-4)</sup>. Provided that a good oncological resection margin is possible without amputation, preserving surgery is indicated with the aim of obtaining oncological results similar to those obtained through external hemipelvectomy. Occasionally, hemipelvectomy with palliative intent is performed with the aim of providing local control when other, less aggressive therapeutic methods that were indicated earlier, such as radiotherapy, chemotherapy, antibiotics and powerful analgesics, among others, have not given rise to the desired effect<sup>(3)</sup>.

The aim of the present study was to show the experience of Erasto Gaertner Hospital, in Curitiba, with pelvic belt surgery between 1998 and 2008.

1 – Medical Residents in Oncological Surgery, Erasto Gaertner Hospital, Curitiba, PR.

2 – Orthopedists in the Oncological Orthopedics Service, Erasto Gaertner Hospital, Curitiba, PR.

3 – Undergraduate Medical Student at PUC-PR.

Work performed at Erasto Gaertner Hospital and Paraná Cancer Combat League, Curitiba, PR.

Correspondence: Travessa Frei Caneca 105, Ap. 44, Centro, 80010-090 Curitiba, PR. E-mail: [rosyanerf@yahoo.com.br](mailto:rosyanerf@yahoo.com.br)

We declare that there is no conflict of interests in this article

## PATIENTS AND METHODS

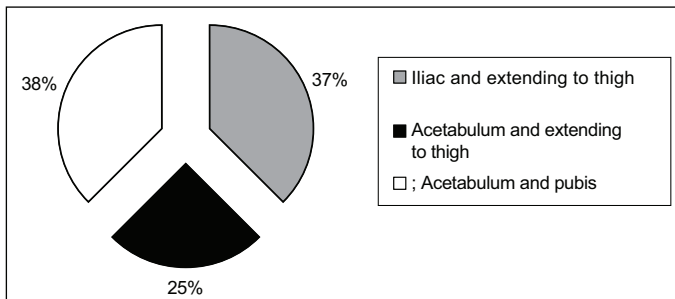
Thirty-two patients who underwent hemipelvectomy at Erasto Gaertner Hospital, in Curitiba, between 1998 and 2008, were retrospectively studied, and their clinical and surgical characteristics were assessed.

## RESULTS

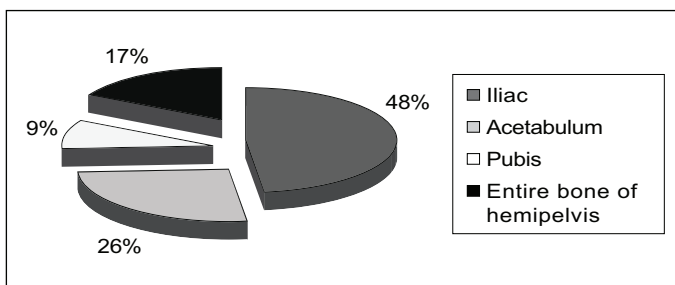
Among the 32 patients, the minimum age was nine years, the maximum was 73 and the mean was 37.94 years.

Fifteen cases were females and 17 were males.

Eight cases presented tumor invasion of the neurovascular bundle: three were located in the iliac and extended to the thigh, two were in the acetabulum and extended to the thigh and three were in the acetabulum and pubis (Figure 1). Twenty-three cases did not present any tumor invasion of the neurovascular bundle: 11 were restricted to the iliac, six were in the acetabular region, two were in the pubic ramus and four extended to the whole hemipelvis bone (Figure 2). One patient presented a tumor in the region of the pubic ramus that compromised the femoral artery and vein without neural involvement.



**Figure 1** – Locations of the tumors with neurovascular bundle involvement



**Figure 2** – Locations of the tumors without neurovascular bundle involvement

Among the 24 cases that underwent internal hemipelvectomy, 13 (54%) did not undergo reconstruction, 10 (42%) underwent insertion of a fibular graft and one case (4%) required a graft consisting of an iliac-femoral

vein and artery prosthesis. Among the 10 cases with a fibular graft, four underwent hemipelvectomy type IV,

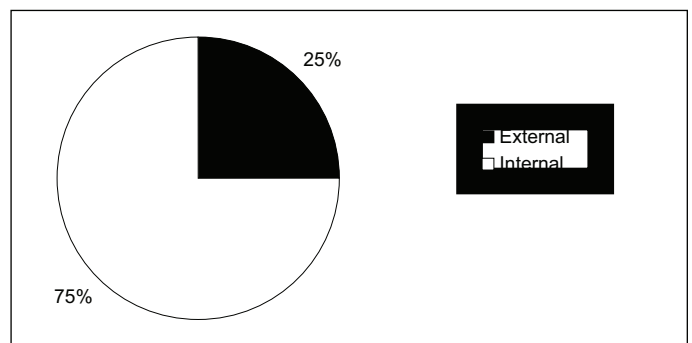
### Box 1 – Histopathology

Histological type	N
Adenocarcinoma	2
Squamous cell carcinoma	1
Chondrosarcoma	7
Malignant fibrohistiocytoma	3
Hemangiosarcoma	1
Osteosarcoma	3
PNET	2
Alveolar rhabdomyosarcoma	1
Embryonic rhabdomyosarcoma	1
Ewing's sarcoma	4
Pleomorphic and spindle cell sarcoma	2
Synovial sarcoma	3
Giant cell tumor	2
Total	32

The smallest tumor diameter was 8 cm and the maximum was 30 cm, with a mean of 16.13 cm.

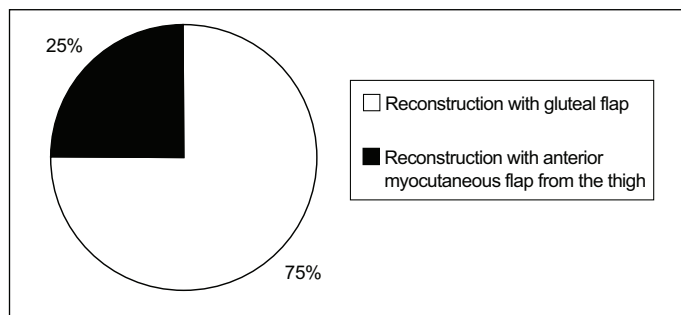
With regard to histological type, the largest number (seven cases) consisted of chondrosarcoma, while Ewing's sarcoma was in second place (four cases). The other histological types are described in Box 1.

Among the 32 patients, eight cases (25.1%) underwent external hemipelvectomy: six with reconstruction using a posterior gluteal flap and two with an anterior myocutaneous flap from the thigh (Figures 3 and 4).

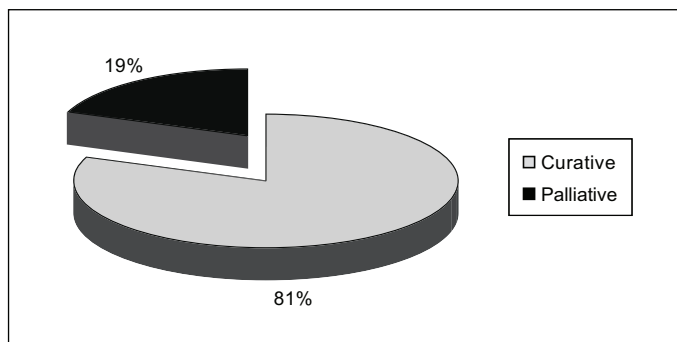


**Figure 3** – Type of hemipelvectomy

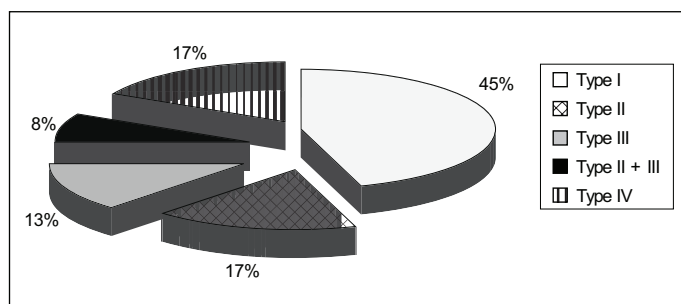
Twenty-four cases (75%) underwent internal hemipelvectomy, distributed thus according to the Enneking classification: 11 type I, four type II, two type II + III, three type III and four type IV (Figure 5).



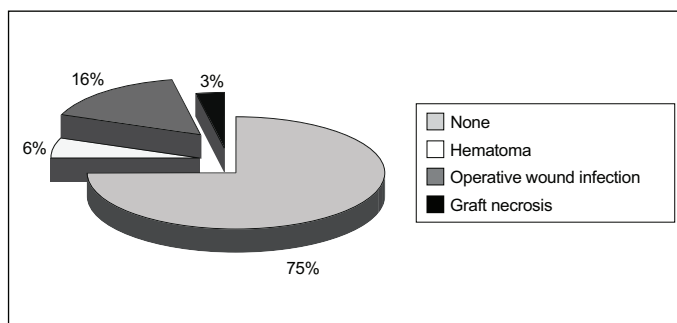
**Figure 4** – Type of reconstruction in cases of external hemipelvectomy



**Figure 7** – Intention: curative versus palliative



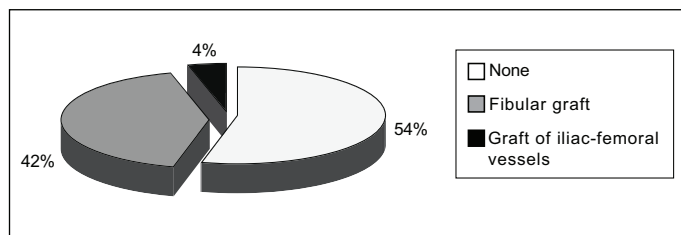
**Figure 5** – Type of internal hemipelvectomy



**Figure 8** – Complications

two type II + III and four type II (Figure 6).

The patient who underwent the graft of iliac-femoral vessels presented tumor formation with direct infiltration of the iliac-femoral vein and artery, without nerve involvement, and underwent hemipelvectomy type III with en-bloc resection of these vessels together with the tumor and reconstruction using PTFE prostheses for the vein and artery.



**Figure 6** – Reconstruction in cases of internal hemipelvectomy

Out of the 32 patients, 26 cases (81.3%) were operated with curative intent and six (18.8%) with palliative intent (Figure 7).

In 24 cases (75%), the surgery did not present complications. In five cases (15.6%), there was infection of the operative wound; in two (6%), hematoma; and in one (3.1%), partial necrosis of the graft (Figure 8).

In the present study, no local recurrence was observed. The rate of distant recurrence was 21.8% (Box 2).

With regard to the surgical margins, 12.5% presented margins that were microscopically compromised

**Box 2** – Deaths among patients with distant recurrence

One case six months later	LUNG – Death one year later
One case five years later	LUNG – Death five years later
Two cases one year later	LUNG – One lost from follow-up; the other died two years later
One case seven months later	LUNG – Death one year later
One case two months later	SPINE – Death three months later
One case four months later	SPINE – Death five months later

(R1 resection). All these cases underwent adjuvant treatment with radiotherapy and chemotherapy, without undergoing a new surgical intervention. The types of hemipelvectomy, survival and histological types of these tumors are specified in Box 3.

**Box 3** – Types of hemipelvectomy, survival and histological type of the tumors with R1 resection

One case	Type I internal hemipelvectomy	Death one year later	Ewing's sarcoma
One case	Type IV internal hemipelvectomy	Death five months later	Chondrosarcoma
One case	Type I internal hemipelvectomy	Lost from follow-up eight years later	Chondrosarcoma
One case	Type I internal hemipelvectomy	Surgery two months later	Malignant fibrohistiocytoma

Over the period studied, there were 14 cases (44%) of death and three cases (9%) of loss from the follow-up (Figure 9). The minimum length of survival was one day, the maximum was five years and the mean was 10.6 months. Among these 14 deaths, four were patients who had undergone palliative surgery, and they died as a direct consequence of the disease (Box 4). The other 10 patients died due to causes unrelated to the surgical intervention, and none of the reported surgical complications had any impact on the patients' survival.

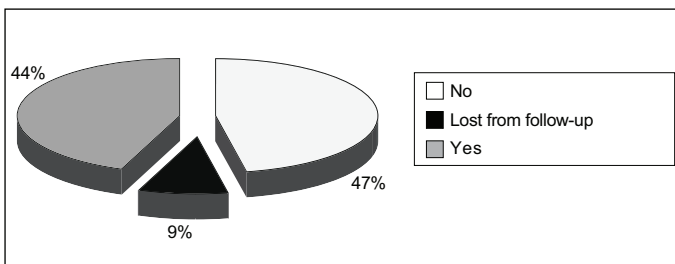


Figure 9 – Death

**Box 4 – Survival among patients who underwent palliative hemipelvectomy**

One case	One day
One case	Two months
One case	Three months
One case	Five months
Two cases	Lost from follow-up

Two years of survival was observed in 11 cases (34.4%), six cases (18.8%) had had recent surgery (less than two years of follow-up) and three cases (9.4%) were lost from the follow-up (Figure 10). None of the cases with distant recurrence survived for two years.

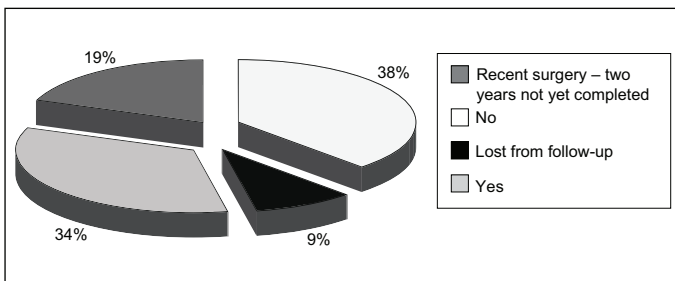


Figure 10 – Two-year survival

Five years of survival was observed in 10 cases (31.3%), six cases (18.8%) had had recent surgery (less than five years of follow-up) and three cases (9.4%) were lost from the follow-up (Figure 11). None of the cases with distant recurrence survived for five years.

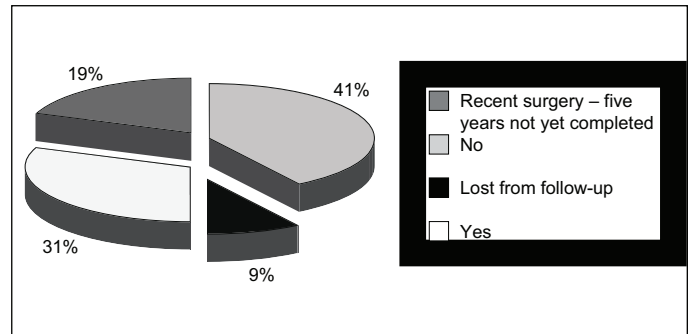


Figure 11 – Five-year survival

With regard to the functional point of view of the patients who underwent hemipelvectomy, the 15 surviving cases were interviewed recently for the present study, in order to ascertain their satisfaction with the surgery. The final result was based on the functional staging according to Enneking, as adopted by the Musculoskeletal Tumor Society. This classification is as follows:

*Excellent:* no pain, functions without restrictions, and excellent acceptance by the patient;

*Good:* low-intensity non-incapacitating pain and/or restrictions on recreation functions, and good acceptance by the patient;

*Regular:* moderate pain with intermittent incapacitation and/or partial occupational restriction, and regular acceptance by the patient;

*Poor:* high-intensity pain with continuous incapacitation, and/or total occupational restriction, and patient dissatisfaction.

The data obtained are shown in Figure 12.

Figures 13, 14 and 15 show, respectively: the time of the surgery, with reconstruction using the fibula in type IV internal hemipelvectomy; vascular reconstruction of the iliac-femoral vein and artery, in internal hemipelvectomy; and the final appearance of the lower limbs of the patient who underwent vascular reconstruction.

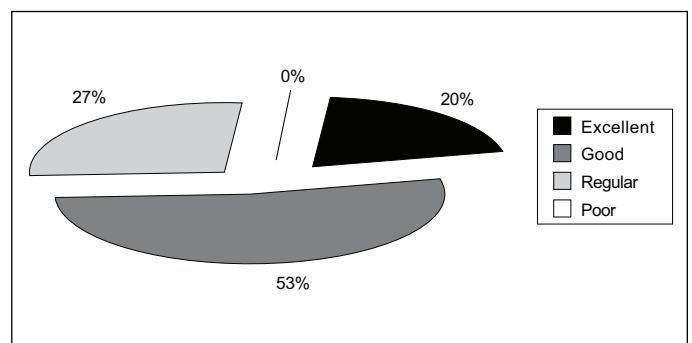
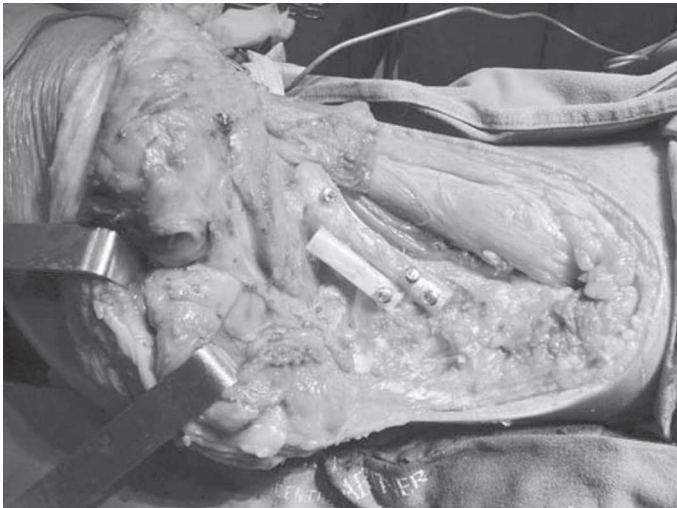
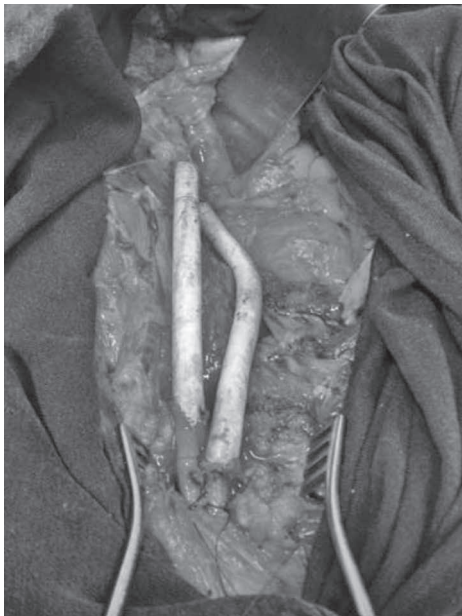

Figure 12 – Overall functional result, in accordance with the categories of the classification of Enneking *et al* (1993), among patients who underwent hemipelvectomy



**Figure 13** – Reconstruction using fibula in case of type IV internal hemipelvectomy



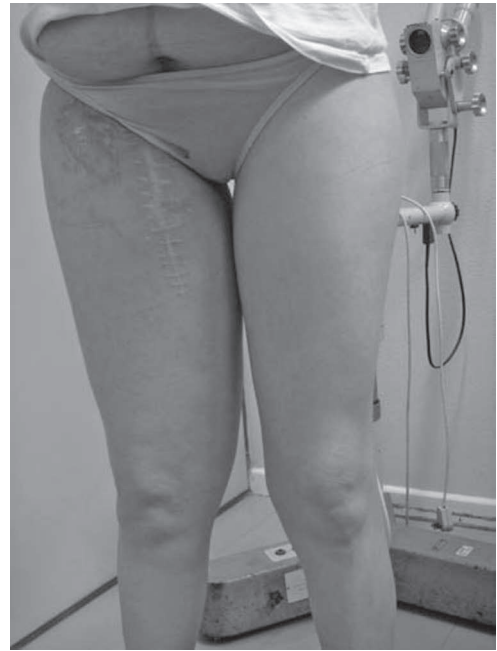**Figure 14** – Vascular reconstruction of iliac-femoral vein and artery in case of internal hemipelvectomy

## DISCUSSION

Despite all the development of oncological surgery, resection of pelvic tumors is one of the problems that have undergone most changes in limb-preserving surgery.

The malignant tumors most commonly encountered in the pelvic region are, in order of frequency, chondrosarcoma, Ewing's sarcoma and osteosarcoma<sup>(3)</sup>. In our study, the majority consisted of chondrosarcoma and, in second place, Ewing's sarcoma; these data agree with the literature.

The type of surgery (external or internal hemipelvectomy) is based on the size of the tumor and/or the lo-



**Figure 15** – Final appearance of lower limbs of patient who underwent vascular reconstruction

cation of the adjacent structures and tissues involved<sup>(5)</sup>. Extensive tumors of the pelvic region that invade bones, soft tissues, nerves and vessels are difficult to treat conservatively. External hemipelvectomy is a procedure with considerable morbidity and is today only indicated for a small proportion of pelvic tumors, when the extent of the tumor and the involvement of the root of the thigh and the neurovascular bundle make it impossible to preserve the limb. In such cases, it may be the only alternative for resection of these tumors with adequate margins and an acceptable disease-free interval. In a standard external hemipelvectomy procedure, a gluteal myocutaneous flap is the reconstruction most used. For extensive gluteal tumors or tumors of the posterior proximal region of the thigh that require hemipelvectomy for treatment, an anterior myocutaneous flap from the thigh, maintained using femoral veins, is without doubt the most appropriate and safest option<sup>(6,7)</sup>. In our study, out of the 32 patients, eight (25.1%) underwent external hemipelvectomy (six with a gluteal flap and two with an anterior myocutaneous flap from the thigh).

Internal hemipelvectomy is a complex procedure but cosmetically superior to external hemipelvectomy. It is indicated for smaller tumors that are restricted to the hemipelvis, without compromising the thigh and without neurovascular invasion of the iliofemoral bundle. In cases in which there is vascular invasion, without neural involvement, surgery may be indicated with re-

construction of the artery and/or vein with a vascular prosthesis, in order to keep the ipsilateral lower limb functional<sup>(8)</sup>. In our study, one of the cases underwent associated vascular reconstruction.

The type of internal hemipelvectomy according to the Enneking classification is based on the location of the tumor in the pelvis: type I (wing of the iliac), type II (periacetabular region), type III (pubic arch) and type IV (entire bone of the hemipelvis). In our study, 24 cases (75%) underwent internal hemipelvectomy: 11 cases of type I, two of type II + III, four of type II, three of type III and four of type IV.

One point that remains controversial in the literature is the question of reconstruction in cases of internal hemipelvectomy. In a study retrospectively evaluating 31 cases (12 at the AC Camargo Hospital in São Paulo and 19 at the Boldrini Hospital in Campinas) that underwent type II hemipelvectomy, with or without reconstruction of the pelvic ring using the fibula, the patients who underwent internal hemipelvectomy with reconstruction of the pelvic ring using an autograft from the fibula had better overall functional results than shown by the group that did not undergo reconstruction ( $p = 0.007$ )<sup>(9)</sup>. In our study, out of the 24 cases that underwent internal hemipelvectomy, 10 (42%) received a fibular graft: four type IV, two type II + III and four type II. No comparative functional study between the two groups was made at our service.

In the literature, two non-consensual strands can be seen in relation to indications for pelvic reconstruction after internal hemipelvectomy:

Surgeons who have not indicated pelvic reconstruction have emphasized the difficulty in making surgical approaches to the pelvis, because of the proximity to organs and neurovascular bundles. Guest *et al*<sup>(10)</sup> mentioned that reconstruction of the acetabulum was as difficult as the removal of the tumor. Veth *et al*<sup>(11)</sup> emphasized the fact that after resection of the pelvic tumor, the hip and lower-limb function would never be normal, independent of the reconstruction performed. These authors published satisfactory functional results from patients without reconstruction. Another point considered by Hugate and Sim<sup>(12)</sup> was the duration of the operation and the blood loss, which are less in operations without reconstruction. It is important to note that, for patients who undergo type I resection (iliac wing lesions) or type III resection (lesions in the ischiopubic region), reconstruction is not necessary because the biomechanical change that is caused does not lead to any considerable functional loss<sup>(12)</sup>.

Surgeons who advocate reconstruction justify this in terms of the possibility of restoring pelvic stability, maintaining hip mobility, minimizing the discrepancy in leg length and, consequently, obtaining better functional and esthetic results<sup>(13,14)</sup>.

Nevertheless, there is still no consensus regarding whether or not to reconstruct the pelvis after tumor resection. It has not been defined which type of surgery would bring greatest benefit to patients. Several studies have been conducted over recent decades, and each of them has presented advantages and disadvantages of a variety of surgical techniques relating to resection of pelvic tumors.

Certain other points also remain controversial. The first of these is postoperative disease control and survival. Studies have shown that after resection consisting of hemipelvectomy for high-grade sarcomas, the survival rate has ranged up to 40%, with local recurrence of 70%<sup>(8,15)</sup>. In our study, considering the different histological types, the mean length of survival was 10.6 months, and the two and five-year survival rates were 34.4% and 31.3%, respectively. Local recurrence, which is one of the main complications, with an important impact on survival, was not observed in our study. The second point concerns the high complication rate reported in relation to these extensive and complex surgical procedures. Among the most common of these complications are superficial and deep infections, seroma, suture dehiscence, loosening of fibular grafts, neuropraxia and venous thrombosis. Infections and nerve lesions, among others, can reach incidence of 50%<sup>(5,8,16)</sup>. In our study, there were no complications in 75% of the patients, while superficial infection of the operative wound occurred in 15.6%, superficial subcutaneous hematomas in 6% and partial graft necrosis in 3.1%. None of these complications required a new surgical intervention, and they were treated using antibiotic therapy, outpatient drainage of the superficial hematoma in the operative wound and debridement of the edges of the operative wound, respectively. No cases of loosening of fibular grafts, severe neuropraxia, thrombosis or other, more severe complications were observed.

Palliative hemipelvectomy has been indicated for patients with metastatic or locally advanced bone disease<sup>(17,18)</sup>. The indications include intractable pain, ulceration, hemorrhage, infection and unstable pathological fracture; however, there is still no consensus in the literature regarding this indication. Because palliative hemipelvectomy is controversial, especially in cases

with less than one year of survival, it is of utmost importance to evaluate other options before surgery<sup>(17,18)</sup>. In our study, six patients were operated with palliative intent. Among these, the survival was one, 60, 90 and 180 days among the patients who continued with the follow-up, while two cases were lost from the follow-up and their survival could therefore not be determined. The final analysis on the improvement of quality of life achieved through the surgery was not quantified through standardized questionnaires. Thus, because of the retrospective design of this study, we were unable to come to conclusions regarding the results attained through the palliative indication. Nonetheless, it is worth emphasizing that the indications were based on the patients' symptoms of worsening pain, infection and local bleeding that were unresponsive to drug treatment and radiotherapy, with a desire to undergo surgery mentioned by the patient, who was made aware of the impossibility of a cure and the extent of the procedure.

With regard to the functional results, in several cases they have been good and encouraging, even allowing some patients to walk without the aid of crutches or sticks and allowing single-leg loading of body weight. Some patients have required several months for rehabilitation but have achieved the possibility of walking without crutches, while others have been able to walk

without any type of orthosis<sup>(17-20)</sup>. However, because of the retrospective nature of most of these studies, it is difficult to quantify and qualify the degree of control over the symptoms that was achieved. The functional evaluation in the present study was made using the Enneking staging system<sup>(21)</sup>, as adopted by the Musculoskeletal Tumor Society. Through this classification, among the 15 surviving patients who we recently interviewed for this study regarding the functioning of the operated limb, three said that the result was excellent, eight said that it was good and four said that it was regular. These last four patients said that the result was regular because they needed to use crutches to carry out their habitual activities, but for less than 50% of the time.

In conclusion, this study showed that hemipelvectomy is a viable surgical procedure because of the low incidence of postoperative complications and the absence of local recurrence in our sample. The percentages that we obtained were lower than in the literature. The type of hemipelvectomy indicated depends essentially on the local extent of the disease. For patients for whom a cure is not expected, prospective studies on quality of life are needed in order to validate this surgical procedure, taking into consideration patients' wishes, the local conditions of the tumor and the previous treatments carried out.

## REFERENCES

1. Campanacci M, Capanna R. "Reconstruction for periacetabular pelvic resection: closing remarks". In: Enneking WF. *Limb salvage in musculoskeletal oncology*. New York: Churchill-Livingstone; 1987. p. 181-91.
2. Campanacci M, Capanna R. *Pelvic resections: the Rizzoli Institute experience*. Orthop Clin North Am. 1991;22(1):65-86.
3. Eilber FR, Eckardt JJ, Grant TG. "Resection of malignant bone tumors of the pelvis": evaluation of local recurrence, survival, and function". In Enneking WF. *Limb salvage in musculoskeletal oncology*. New York: Churchill-Livingstone; 1987. p.136-41.
4. Enneking WF, Dunham WK. Resection and reconstruction for primary neoplasms involving the innominate bone. *J Bone Joint Surg Am*. 1978;60(6):731-46.
5. Ham SJ, Schraffordt Koops H, Veth RP, van Horn JR, Eisma WH, Hoekstra HJ. External and internal hemipelvectomy for sarcomas of the pelvic girdle: consequences of limb-salvage treatment. *Eur J Surg Oncol*. 1997;23(6):540-6.
6. Corrêa DS, Rossi BM, Ferreira FO, Nakagawa WT, Guimarães GC, Lopes A. Reconstrução com retalho miocutâneo anterior da coxa após hemipelvectomy por carcinoma de células escamosas de região glútea: relato de caso. *Rev Bras Cancerol*. 2002;48(2):253-6.
7. Vieira LJ, Vieira JP, Oliveira AF, Freitas RR. Hemipelvectomy utilizing an anterior myocutaneous flap: case report and surgical technique description. *Rev Bras Cancerol*. 2004;50(4):301-5.
8. Apffelstaedt JP, Driscoll DL, Spellman JE, Velez AF, Gibbs JF, Karakousis CP. Complications and outcome of external hemipelvectomy in the management of pelvic tumors. *Ann Surg Oncol*. 1996;3(3):304-9.
9. Deneno BP, Gonçalves JCB, Lopes A, Brandalise SR. Resultado funcional em crianças e adolescentes submetidos à hemipelvectomy interna tipo II, com ou sem reconstrução do anel pélvico. *Rev Bras Ortop*. 2007;42(5):125-32.
10. Guest CB, Bell RS, Davis A, Langer F, Ling H, Gross AE, Czitrom A. Allograft-implant composite reconstruction following periacetabular sarcoma resection. *J Arthroplasty*. 1990;5 Suppl:S25-34.
11. Veth RP, Schraffordt Koops H, Nielsen HK, Oldhoff J, Verkerke GJ, Postma A. A critique of techniques for reconstruction after internal hemipelvectomy for osteosarcoma. *Cancer Treat Res*. 1993;62:221-9.
12. Hugate R Jr, Sim FH. Pelvic reconstruction techniques. *Orthop Clin North Am*. 2006;37(1):85-97.
13. Marchese VG, Ogle S, Womer RB, Dormans J, Ginsberg JP. An examination of outcome measures to assess functional mobility in childhood survivors of osteosarcoma. *Pediatr Blood Cancer*. 2004;42(1):41-5.
14. Pring ME, Weber KL, Unni KK, Sim FH. Chondrosarcoma of the pelvis. A review of sixty-four cases. *J Bone Joint Surg Am*. 2001;83(11):1630-42.
15. Renard AJ, Veth RP, Schreuder HW, Pruszczynski M, Keller A, van Hoesel Q et al. The saddle prosthesis in pelvic primary and secondary musculoskeletal tumors: functional results at several postoperative intervals. *Arch Orthop Trauma Surg*. 2000;120(3-4):188-94.
16. Apffelstaedt JP, Driscoll DL, Karakousis CP. Partial and complete internal hemipelvectomy: complications and long-term follow-up. *J Am Coll Surg*. 1995;181(1):86-64.
17. Malawer MM, Buch RG, Thompson WE, Sugarbaker PH. Major amputations done with palliative intent in the treatment of local bony complications associated with advanced cancer. *J Surg Oncol*. 1991;47(2):121-30.
18. Merimsky O, Kollender Y, Inbar M, Chaitchik S, Meller I. Palliative major amputation and quality of life in cancer patients. *Acta Oncol*. 1997;36(2):151-7.
19. Karakousis CP, Amrich LJ, Driscoll DL. Variants of hemipelvectomy and their complications. *Am J Surg*. 1989;158(5):404-8.
20. King LA, Downey GO, Savage JE, Twigg LB, Oakley GJ, Prem KA. Resection of the pubic bone as an adjunct to management of primary, recurrent, and metastatic pelvic malignancies. *Obstet Gynecol*. 1989;73(6):1022-6.
21. Enneking WF, Dunham W, Gebhardt MC, Malawar M, Pritchard DJ. A system for the functional evaluation of reconstructive procedures after surgical treatment of tumors of the musculoskeletal system. *Clin Orthop Relat Res*. 1993