



Available online at  
**ScienceDirect**  
[www.sciencedirect.com](http://www.sciencedirect.com)

Elsevier Masson France  
**EM|consulte**  
[www.em-consulte.com/en](http://www.em-consulte.com/en)



Original article

## Staged reimplantation for the treatment of fungal peri-prosthetic joint infection following primary total knee arthroplasty



Q.-J. Wang, H. Shen, X.-L. Zhang\*, Y. Jiang, Q. Wang, Y.S. Chen, J.-J. Shao

Department of Orthopaedic Surgery, Shanghai Jiao Tong University Affiliated Sixth People's Hospital, 600 Yishan Road, 200233 Shanghai, PR China

### ARTICLE INFO

#### Article history:

Accepted 5 November 2014

#### Keywords:

Fungal peri-prosthetic infection  
 Reimplantation  
 Antifungal therapy  
 Antifungal-loaded bone cement  
 Two-stage revision

### ABSTRACT

**Background:** Fungal peri-prosthetic joint infections (PJI) are rare complication following total knee arthroplasty (TKA). There exists no established guidelines in the treatment of these infections and controversies are focused on the usefulness of antifungal-loaded cement spacers, the duration of systemic antifungal treatment and the ideal interval between implant removal and reimplantation. Therefore we ask if: (1) adding antifungal in cement space is a viable solution to manage fungal PJI; (2) there is no adverse effect adding antifungal medication in cement?

**Hypothesis:** We hypothesized that fungal PJI following TKA could be managed successfully by 2-stage reimplantation strategy using antifungal-loaded cement spacer.

**Patients and methods:** Five cases of fungal PJI following total knee arthroplasty were treated in our institution between 2007 and 2013 using a 2-stage reimplantation strategy. The median elapsed time from primary arthroplasty to the diagnosis of infection was 7.4 months (range, 5–10 months). The infection was caused by *Candida* species in 4 cases and *Pichia anomala* in 1 case. Antibiotic- and antifungal-loaded articulating cement spacer was implanted during the interval between stages. Systemic antifungal agents were administered for at least 6 weeks after removal of prosthesis in all cases. The mean interval between removal and reimplantation was 6 months (range, 3–9 months).

**Results:** At a mean follow-up of 41.6 months (range, 24–65 months) after reimplantation, no patient had recurrent infection or revision due to any other reasons. The mean global IKS score improved from 58.4 (range, 37–96 points) preoperatively to 152.4 (range, 136–169 points) at final follow-up. The average range of motion of the knee for flexion improved from 63° (range, 10–110°) preoperatively to 98° (range, 80–120°) at final follow-up.

**Conclusions:** Fungal PJI following TKA can be successfully treated by a staged reimplantation strategy. Antibiotic- and antifungal-loaded cement spacer implanted during interval period between stages may be an effective adjunct to therapy. Effective antifungal therapy is crucial to a successful result without adverse effect.

**Level of evidence:** IV: retrospective or historical series.

© 2015 Elsevier Masson SAS. All rights reserved.

### 1. Introduction

Prosthetic joint infection (PJI) is the most debilitating and expensive complication following arthroplasty. A nationwide study performed in the USA showed an infection burden of 1.21% for total knee arthroplasty (TKA) [1]. Fungal PJI following TKA is uncommon, with a current incidence not precisely known, but estimated to constitute about 1% of all PJI [2]. A recent evaluation of the English

literature for the past 30 years revealed only 94 cases of fungal infection of a knee arthroplasty [3].

So far, there exists no established guidelines in the treatment of fungal peri-prosthetic joint infections. Several different treatment methods, including antifungal drugs, debridement with retained prosthesis, resection arthroplasty, and two-stage exchange arthroplasty have been reported, with variable outcomes [4–8]. Although a two-stage exchange arthroplasty was preferred by most surgeons [3], controversies still exist with regard to the ideal interval between implant removal and reimplantation, the usefulness of antifungal-loaded cement spacers and the duration of systemic antifungal treatment. Therefore, we introduced a 2-stage strategy

\* Corresponding author. Tel.: +86 21 24058101; fax: +86 21 24058101.  
 E-mail address: [xlzhang40@gmail.com](mailto:xlzhang40@gmail.com) (X.-L. Zhang).

and we treated 5 cases of fungal PJI following total knee arthroplasty. The aims of this study were to assess:

- if adding antifungal in cement space is a viable solution to manage fungal PJI;
- the rate of healing after a specific 2-stage protocol.

We hypothesized that fungal PJI following TKA could be managed successfully by removal of all the infected components, implantation of antibiotic- and antifungal-loaded cement spacers during interval stage, appropriate antifungal treatment for at least six weeks and a two-stage reimplantation.

## 2. Patients and methods

### 2.1. Study population

After Institutional Review Board approval, we retrospectively reviewed our institutional joint arthroplasty database to identify patients who were diagnosed with a knee fungal peri-prosthetic joint infection at our institution. We defined fungal PJI as “definite” if 2 cultures of either a joint aspiration specimen or a surgical specimen yielded definitive positive result, in conjunction with an appropriate clinical syndrome [9]. Growth on the chromogenic medium *Candida* (CHROMagar) and the automated VITEK-60 system (bioMérieux) were used for fungal identification. Treatment failure was defined as the occurrence of any of the following conditions at any time after the initial surgical procedure:

- peri-prosthetic joint infections attributable to the presence of the original microorganism (relapse of infection) or a different strain (reinfection);
- development of a sinus tract;
- death related to the peri-prosthetic joint infection.

Between January 2007 and November 2013, a total of 95 patients with PJI following TKA were treated at our institution. Among these, 5 cases in 5 patients (2 male, 3 female) mean aged 67 years (56 to 72) were identified as having fungal PJI following TKA (Table 1). The diagnosis indicated for primary arthroplasty was osteoarthritis and the initial TKA was cemented in all 5 patients. The median duration of time from prosthesis implantation to the diagnosis of PJI was 7.4 months (range, 5–10). No patient had prior hospitalization or prolonged antibiotic use. One patient (case No. 1) had diabetes mellitus and leucopenia, 1 patient (case No. 3) had diabetes mellitus, the other 3 patients had no identifiable risk factors for fungal infection and/or fungal PJI.

### 2.2. Surgical therapy

Table 2 summarizes the surgical and medical therapy for these 5 patients. Two-stage exchange arthroplasty was performed for all 5 patients. After removal of all components and a thorough debridement, an articulating cement spacer made intraoperatively according to Shen et al. [10] was implanted (Fig. 1A). Amphotericin B and vancomycin loaded bone cement (100 mg amphotericin B combined with 1 g vancomycin per batch of bone cement) was used in all patients. The mean interval between resection and reimplantation was 6 months (range, 3 to 9 months). Bone cement used for reimplantation was loaded with amphotericin B and vancomycin (100 mg amphotericin B combined with 1 g vancomycin per 40 g bone cement) in all patients.

### 2.3. Medical therapy

Systemic antifungal therapy was administered to all patients. After implant removal and bone cement spacer implantation, patients were treated with parenteral fluconazole (400 mg/day) combined with parenteral cefuroxime and levofloxacin for 2 weeks, followed by oral fluconazole (400 mg/day), levofloxacin and rifampicin for 4 to 8 weeks until CRP and ESR values returned to normal. After reimplantation, antimicrobial therapy for all 5 patients was consisted of parenteral fluconazole (400 mg/day), cefuroxime and levofloxacin for 2 weeks. Culture of intraoperative specimen during reimplantation yielded *Staphylococcus auricularis* in one patient (case No. 4). Prolonged antimicrobial therapy consisted of oral levofloxacin and rifampicin for 4 more weeks was prescribed for this patient. The other 4 patients received no prolonged antimicrobial therapy.

### 2.4. Data collection

Data collected from the patient’s medical record and follow-up record included: age, sex, primary or revision surgery, comorbidity, preoperative diagnosis, symptoms, global IKS score [11], range of motion of the knee joint, interval between primary surgery and onset of symptoms of infection, species isolated, origin of culture samples (i.e. aspiration, intraoperative, other), other microorganisms cultured, C-reactive protein (CRP, mg/L) and erythrocyte sedimentation rate (ESR, mm/h) at presentation, radiographic findings, local and systemic antimicrobial therapy, duration of antimicrobial therapy, type of surgical treatment, time from resection to reimplantation, and duration of follow-up.

## 3. Results

### 3.1. Clinical features

Four patients (80%) had significant pain, swelling, warmth, redness and sinus tract formation at presentation (Fig. 1B). The other patient without draining sinus had slight pain, swelling and stiffness of the knee, with an active range of motion (ROM) of only 10 degrees and a passive ROM of about 30 degrees (Table 1). At presentation, 1 patient had normal CRP and ESR, 1 patient had normal CRP and elevated ESR, the other 3 patients had significantly elevated CRP and ESR. On plain X-ray film, 1 patient (case No. 1) had only slight radiolucent lines (RLLs) around the posterior condyle of the femoral component and had no osteolytic lesions. The other 4 patients had significant osteolysis beneath the tibial components (Fig. 1C).

### 3.2. Microbiology

Cultures of preoperative aspirate specimens from all 5 patients were positive for fungus. The pathogen organisms included *Pichia anomala* (also named *Candida pelliculosa*) in 1 patient, *Candida utilis* in 1 patient and *Candida parapsilosis* in the other 3 patients, which were consistent with the culture results of their intraoperative specimens (Table 1). Susceptibility tests were performed in all cases. The causative organism was susceptible to fluconazole, ketoconazole, voriconazole, itraconazole and amphotericin B in all cases. No patient had a polymicrobial infection at the time of diagnosis.

### 3.3. Treatment outcome

We did not observe mechanical complications between stages such as spacer fractures or dislocations. The median duration of

**Table 1**  
Demographic and clinical characteristics of patients with fungal peri-prosthetic joint infection following primary total knee arthroplasty.

Case No.	Age (year)/sex	Comorbidities/risk factors	Pathogen organism	Symptoms	Radiographic findings	Time from implantation to diagnosis of PJI (months)	CRP (mg/l) at presentation	ESR (mm/h) at presentation
1	67/F	Leucopenia, diabetes mellitus	<i>Candida parapsilosis</i>	Slight pain, warmth, swelling and stiffness of the knee	Radiolucency at femoral side	5	22.4	39
2	56/F	None	<i>Candida utilis</i>	Significant pain, swelling, warmth, redness and sinus tract formation	Osteolysis beneath the tibial tray	5	3.53	29
3	74/M	Diabetes mellitus	<i>Candida parapsilosis</i>	Significant pain, swelling, warmth, redness and sinus tract formation	Radiolucency at femoral side and osteolysis beneath the tibial tray	10	5.22	41
4	68/M	None	<i>Pichia anomala</i>	Significant pain, swelling, warmth, redness and sinus tract formation	Osteolysis beneath the tibial tray	8	48	38
5	71/F	None	<i>Candida parapsilosis</i>	Significant pain, swelling, warmth, redness and sinus tract formation	Osteolysis beneath the tibial tray	9	34.6	54

CRP: C-reactive protein; ESR: erythrocyte sedimentation rate; F: female; M: male.

follow-up was 41.6 months (range, 24–65 months) after reimplantation. At latest follow-up visit, no patient had recurrent infection after successful reimplantation. All patients performed activities of daily living well and were satisfied with the revision TKA. The mean global IKS score improved from 58.4 (range, 37 to 96 points) preoperatively to 152.4 (range, 136 to 169 points) at final follow-up. The average range of motion of the knee for flexion improved from 63° (range, 10 to 110°) preoperatively to 98° (range, 80 to 120°) at final follow-up. There was no radiological evidence of loosening of the revised prosthesis in any patient (Fig. 1D). No adverse events related to antifungal or antibiotic therapy were noted in all patients.

#### 4. Discussion

With the significantly improved functional outcome and no recurrence of infection in our 5 cases of fungal PJI following TKA, our working hypothesis was confirmed. Fungal PJI can be treated successfully by our 2-stage reimplantation strategy. Antibiotic- and antifungal-loaded cement articulating spacers may be an effective adjunct to therapy. Systemic antifungal therapy for at least 6 weeks is crucial to a successful result in treating fungal PJI and prolonged antifungal therapy more than 2 weeks is not necessary after reimplantation.

The major limitation of the current study is the small number of cases due to the rarity of fungal PJI. However, we treated all 5 cases with the same protocol including the use of antibiotic- and antifungal-loaded cement spacer and the combined use of rifampin and antibiotics with antifungal agent, which is different to those of other studies and can provide new and valuable information to the treatment of fungal PJI. We did not evaluate the serum level of fluconazole, which is a limitation of our present study. But the dosage of fluconazole we prescribed for our patients (400 mg/day)

was relatively high, and this might possibly resulted in a serum level of fluconazole above the MIC despite the influence of rifampicin.

There exist no established guidelines in the treatment of fungal PJI. Although there is now a growing number of reports of successful 2-stage reimplantation, there were still a large proportion of patients (28.6%, 34/119) with fungal PJI who underwent permanent prosthesis removal and subsequently had poor functional outcome [3]. This differs from the common practice of delayed reimplantation arthroplasty for total hip and knee PJIs due to other organisms.

Staged revision has the highest success rate (85%) in treating fungal PJI [3], thus it should be the standard treatment for fungal PJI. The ideal interval between implant removal and reimplantation is unknown, because fungal PJIs are notoriously indolent and there is no consistent test for successful eradication. A review of 79 two-stage revision cases found a mean interval of 4.8 months, with a range from 1 week to 1.5 years [3]. The mean interval in our case series was 6 months (range, 3 to 9 months). We recommend that reimplantation should be performed only in the absence of clinical signs of infectious symptoms, with CRP and ESR serum levels within the normal range.

The introduction of antibiotic-loaded bone cement improved the results of revision arthroplasty for bacterial sepsis, and it is now considered the gold standard for the treatment of bacterial peri-prosthetic joint infections [12]. However, the efficacy of antifungal-loaded cement spacers in the treatment of fungal peri-prosthetic joint infections is controversial. Theoretically, amphotericin B seems to be an ideal agent to be mixed with bone cement because of its heat stability, broad antimicrobial spectrum, and availability in powder form. The placement of amphotericin B-loaded cement spacers has been reported to successfully eradicate fungal peri-prosthetic joint infections [6]. Bone cement loaded with amphotericin B inhibits fungal growth in an agar diffusion assay [13]. Another in vitro study of amphotericin B-loaded cement

**Table 2**  
Treatment characteristics of 5 patients with fungal peri-prosthetic joint infection following primary total knee arthroplasty.

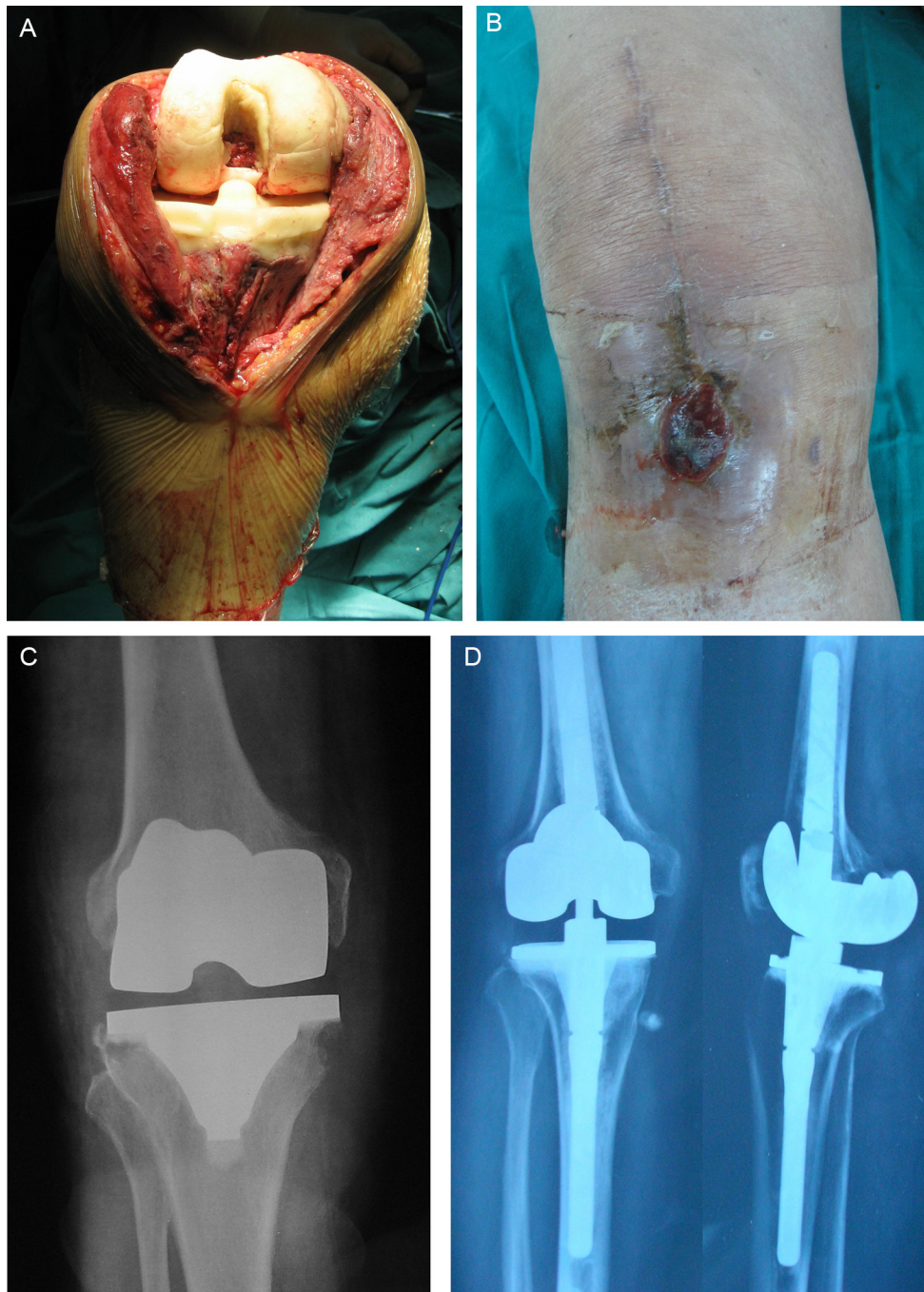
Case No.	Impregnation of bone cement during stage 1 revision	Medical therapy after stage 1 revision	Impregnation of bone cement during reimplantation	Medical therapy after reimplantation	Duration of follow-up (months)	Outcome (failure defined as recurrence of infection)
1	V + A	Parenteral fluconazole (400 mg/day) combined with parenteral cefuroxime and levofloxacin for 2 weeks, followed by oral fluconazole (400 mg/day), levofloxacin and rifampicin (450 mg/day) for 8 weeks	V + A	Parenteral fluconazole (400 mg/day) combined with parenteral cefuroxime and levofloxacin for 2 weeks	27	Cure
2	V + A	Parenteral fluconazole (400 mg/day) combined with parenteral cefuroxime and levofloxacin for 2 weeks, followed by oral fluconazole (400 mg/day), levofloxacin and rifampicin for 4 weeks	V + A	Parenteral fluconazole (400 mg/day) combined with parenteral cefuroxime and levofloxacin for 2 weeks	24	Cure
3	V + A	Parenteral fluconazole (400 mg/day) combined with parenteral cefuroxime and levofloxacin for 2 weeks, followed by oral fluconazole (400 mg/day), levofloxacin and rifampicin for 6 weeks	V + A	Parenteral fluconazole (400 mg/day) combined with parenteral cefuroxime and levofloxacin for 2 weeks	30	Cure
4	V + A	Parenteral fluconazole (400 mg/day) combined with parenteral cefuroxime and levofloxacin for 2 weeks, followed by oral fluconazole (400 mg/day), levofloxacin and rifampicin for 8 weeks	V + A	Parenteral fluconazole (400 mg/day) combined with parenteral cefuroxime and levofloxacin for 2 weeks, followed by oral levofloxacin and rifampicin for 4 weeks	65	Cure
5	V + A	Parenteral fluconazole (400 mg/day) combined with parenteral cefuroxime and levofloxacin for 2 weeks, followed by oral fluconazole (400 mg/day), levofloxacin and rifampicin for 4 weeks	V + A	Parenteral fluconazole (400 mg/day) combined with parenteral cefuroxime and levofloxacin for 2 weeks	62	Cure

V + A: 1 g of vancomycin and 100 mg of amphotericin B per 40 g of bone cement.

has shown only poor elution characteristics for amphotericin B [14]. However, the elution characteristics of amphotericin B in vivo circumstances could be different. Deelstra et al. [15] reported clinically detectable elution of amphotericin B from bone cement for at least 72 hours, with the elution levels well above the MIC levels determined for *Candida albicans*. We consider local antifungal delivery an important part in treating fungal PJI. According to literature, fungal joint infections have a high risk of subsequent bacterial infections [16], culture of intraoperative specimen during reimplantation yielded *S. auricularis* in one of our patients, and a lot of patients have a combined fungal and bacterial PJI (33%) [3]. Thus, we decided to impregnate the bone cement with vancomycin and amphotericin B during cement spacer implantation and second stage reimplantation in all patients. Addition of amphotericin B did not impair the mechanical properties of bone cement [14].

Antifungal therapy appears to be an important component in the successful treatment of fungal PJI. There is evidence that oral fluconazole penetrates tissues well and has excellent bioavailability [17]. It appears that fluconazole is an ideal drug for fungal PJI. A long period of oral antifungal treatment has been recognized as being an essential factor for the success of staged reimplantation after a fungal peri-prosthetic joint infection. However, the required duration of treatment is unclear. The Infectious Diseases Society of America recommends treatment with fluconazole or amphotericin

B for at least 6 weeks after removal of the arthroplasty in most patients with fungal PJI [9]. A review of the literatures shows that duration (comparing 6 weeks and 3 months of antifungal treatment) does not appear to influence outcome after reimplantation [3]. We agree with the opinion of most authors that a minimum duration of antifungal treatment of 6 weeks is required. In the current study, systemic administration of fluconazole was given for 6 to 10 weeks after implant removal until serum CRP and ESR levels had normalized. All these 5 patients received only 2 weeks of antifungal therapy after reimplantation. Because antifungal agents possess a good tissue penetration in infected wounds after systemic administration, we believe that prolonged antifungal therapy is not necessary after reimplantation. Because of the concern about the subsequent or combined bacterial infections with fungal PJI, we decided to use other antibiotics (rifampicin and levofloxacin) in combination with fluconazole as our medical treatment regimen. The use of rifampicin and levofloxacin after implant removal in spite of negative bacterial culture is specific to our center. Indeed current recommendations do not support this systematic antibiotic adjunction to antifungal treatment without microbiological argument [9]. There is a major concern about the pharmacokinetic interaction between rifampicin and antifungal agent. A synergistic effect between amphotericin B and rifampicin was demonstrated against *Candida* species biofilms [18]. Moreover, rifampicin showed



**Fig. 1.** A 74-year-old male patient presented with significant pain and swelling of the right knee 10 months after primary total knee arthroplasty. A. After removal of all implants and a thorough debridement, a cement spacer impregnated with vancomycin and amphotericin B was implanted. B. Warmth, redness and a draining sinus were noted on physical examination. C. Preoperative X-ray showed significant osteolysis beneath the tibial components. D. Anteroposterior and lateral view X-ray film 18 months after reimplantation.

high in vitro activity against most staphylococcal strains isolated from the PJIs tested [19]. Although rifampicin can induce the metabolism of azole antifungals and reduce their serum levels [20], in Turker et al. study [21], four of five patients with cryptococcosis who received itraconazole and rifampin responded despite decreases in their serum itraconazole concentrations. In another study, rifampicin did not change the clinical outcome of fluconazole in treating patients with AIDS-related cryptococcal meningitis despite decreased serum fluconazole concentrations [22]. We were fully aware of the potential side effects and fluconazole and rifampicin interactions, but we tried our best to monitor

the side effects of these drugs closely. It turned out that all our 5 patients tolerated our medical therapy regimen well.

## 5. Conclusions

Fungal peri-prosthetic joint infection following total knee arthroplasty can be successfully treated by removal of the prosthesis, thorough debridement, and effective antifungal therapy. Antibiotic- and antifungal-loaded cement spacer implanted during interval period between stages may be an effective adjunct to therapy. Systemic antifungal therapy for at least 6 weeks is crucial

to a successful result in treating fungal PJI and prolonged antifungal therapy more than 2 weeks is not necessary after reimplantation.

### Disclosure of interest

The authors declare that they have no conflicts of interest concerning this article.

### Acknowledgments

This work was supported by grants from the Shanghai Science and Technology Commission Research Fund (No. 124119a7201).

### References

- [1] Kurtz SM, Lau E, Schmier J, Ong KL, Zhao K, Parvizi J. Infection burden for hip and knee arthroplasty in the United States. *J Arthroplasty* 2008;23:984–91.
- [2] Darouiche RO, Hamill RJ, Musher DM, Young EJ, Harris RL. Periprosthetic candidal infections following arthroplasty. *Rev Infect Dis* 1989;11:89–96.
- [3] Kuiper JW, van den Bekerom MP, van der Stappen J, Nolte PA, Colen S. 2-stage revision recommended for treatment of fungal hip and knee prosthetic joint infections. *Acta Orthop* 2013;84:517–23.
- [4] Merrer J, Dupont B, Nieszkowska A, De Jonghe B, Outin H. Candida albicans prosthetic arthritis treated with fluconazole alone. *J Infect* 2001;42:208–9.
- [5] Wyman J, McGough R, Limbird R. Fungal infection of a total knee prosthesis: successful treatment using articulating cement spacers and staged reimplantation. *Orthopedics* 2002;25:1391–4.
- [6] Wu MH, Hsu KY. Candidal arthritis in revision knee arthroplasty successfully treated with sequential parenteral–oral fluconazole and amphotericin B-loaded cement spacer. *Knee Surg Sports Traumatol Arthrosc* 2011;19:273–6.
- [7] Hwang BH, Yoon JY, Nam CH, Jung KA, Lee SC, Han CD, et al. Fungal periprosthetic joint infection after primary total knee replacement. *J Bone Joint Surg Br* 2012;94:656–9.
- [8] Anagnostakos K, Kelm J, Schmitt E, Jung J. Fungal periprosthetic hip and knee joint infections clinical experience with a 2-stage treatment protocol. *J Arthroplasty* 2012;27:293–8.
- [9] Osmon DR, Berbari EF, Berendt AR, et al. Diagnosis and management of prosthetic joint infection: clinical practice guidelines by the Infectious Diseases Society of America. *Clin Infect Dis* 2013;56:e1–25.
- [10] Shen H, Zhang X, Jiang Y, Wang Q, Chen Y, Shao J. Intraoperatively-made cement-on-cement antibiotic-loaded articulating spacer for infected total knee arthroplasty. *Knee* 2010;17:407–11.
- [11] Insall JN, Dorr LD, Scott RD, Scott WN. Rationale of the Knee Society clinical rating system. *Clin Orthop Relat Res* 1989;248:13–4.
- [12] Cui Q, Mihalko WM, Shields JS, Ries M, Saleh KJ. Antibiotic-impregnated cement spacers for the treatment of infection associated with total hip or knee arthroplasty. *J Bone Joint Surg Am* 2007;89:871–82.
- [13] Silverberg D, Kodali P, Dipersio J, Acus R, Askew M. In vitro analysis of antifungal impregnated polymethylmethacrylate bone cement. *Clin Orthop Relat Res* 2002;403:228–31.
- [14] Goss B, Lutton C, Weinrauch P, Jabur M, Gillett G, Crawford R. Elution and mechanical properties of antifungal bone cement. *J Arthroplasty* 2007;22:902–8.
- [15] Deelstra JJ, Neut D, Jutte PC. Successful treatment of Candida albicans-infected total hip prosthesis with staged procedure using an antifungal-loaded cement spacer. *J Arthroplasty* 2013;28:374 [e5–8].
- [16] Azzam K, Parvizi J, Jungkind D, et al. Microbiological, clinical, and surgical features of fungal prosthetic joint infections: a multi-institutional experience. *J Bone Joint Surg Am* 2009;91(Suppl. 6):142–9.
- [17] Tunkel AR, Thomas CY, Wispelwey B. Candida prosthetic arthritis: report of a case treated with fluconazole and review of the literature. *Am J Med* 1993;94:100–3.
- [18] Del Pozo JL, Frances ML, Hernaez S, Serrera A, Alonso M, Rubio MF. Effect of amphotericin B alone or in combination with rifampicin or clarithromycin against Candida species biofilms. *Int J Artif Organs* 2011;34:766–70.
- [19] Molina-Manso D, del Prado G, Ortiz-Perez A, et al. In vitro susceptibility of Staphylococcus aureus and Staphylococcus epidermidis isolated from prosthetic joint infections. *J Antibiot (Tokyo)* 2012;65:505–8.
- [20] Albengres E, Le Louet H, Tillement JP. Systemic antifungal agents. Drug interactions of clinical significance. *Drug Saf* 1998;18:83–97.
- [21] Tucker RM, Denning DW, Hanson LH, et al. Interaction of azoles with rifampin, phenytoin, and carbamazepine: in vitro and clinical observations. *Clin Infect Dis* 1992;14:165–74.
- [22] Panomvanna Na Ayudhya D, Thanompuangseree N, Tansuphaswadikul S. Effect of rifampicin on the pharmacokinetics of fluconazole in patients with AIDS. *Clin Pharmacokinet* 2004;43:725–32.