



# Massive gastrointestinal bleeding in AIDS patients secondary to histoplasma and cytomegalovirus infection



Marco Antonio Bruno\*, Matías Parodi, Ignacio Olmedo, Héctor Picón Molina, Rafael Palencia, Alejandro Doniquian

General Surgery Service, University Clinic Reina Fabiola, Catholic University of Córdoba, Oncativo 1248 street, Córdoba Capital, Argentina

## ARTICLE INFO

### Article history:

Received 4 February 2016

Received in revised form 23 May 2016

Accepted 25 May 2016

Available online 29 June 2016

### Keywords:

Massive gastrointestinal bleeding

Cytomegalovirus

Histoplasmosis

HIV

AIDS

Case report

## ABSTRACT

**INTRODUCTION:** The Cytomegalovirus (CMV) is a virus that affects the host and remains latent. When cellular immunity is suppressed, the virus is reactivated and can cause an asymptomatic or devastating infection in immunosuppressed patients.

On the other hand, Histoplasmosis is typically a respiratory condition. However, in immunosuppressed patients, it may be found in unusual locations, as in the case of an intestinal condition. In some cases, this can be fatal.

Small intestine CMV location is extremely rare.

**CASE PRESENTATION:** 40-year-old man with AIDS presenting secondary massive lower gastrointestinal bleeding (MLGB) symptoms and ulcer granulomatous injuries located in the proximal ileum produced by the association of CMV and histoplasmosis.

**CONCLUSION:** Lower gastrointestinal bleeding diagnosis and treatment pose a challenge, considering the intestine extension and difficulties for its exploration. On the other hand, the association between Histoplasmosis and CMV as a massive gastrointestinal bleeding cause has not been described. There is no bibliography on the matter.

© 2016 Published by Elsevier Ltd on behalf of IJS Publishing Group Ltd. This is an open access article under the CC BY-NC-ND license (<http://creativecommons.org/licenses/by-nc-nd/4.0/>).

## 1. Introduction

The Cytomegalovirus (CMV) is a virus belonging to the herpesviridae family. It can produce several clinical manifestations according to the age and immune condition of the host [1,2].

Contagion occurs through the contact with bodily fluids such as blood, saliva, vaginal secretion and semen, among others [2].

CMV produces an infection and remains latent. It may reactivate itself once cellular immunity is suppressed, causing an asymptomatic or devastating infection in immunosuppressed patients [3].

CMV is the most common opportunistic pathogenic virus in the acquired immunodeficiency syndrome (AIDS) [4,5].

On the other hand, histoplasmosis is a fungal disease produced by inhaling particles from the ground that are contaminated with birds' excrement containing spores of this fungus [2,5,6].

It is typically a respiratory condition. However, in immunosuppressed patients, it can be found in unusual locations, as in the case of an intestinal condition [2].

\* Corresponding author at: Punilla 1842 street. Córdoba Capital, Argentina.

E-mail addresses: [marcobruno.cba@gmail.com](mailto:marcobruno.cba@gmail.com) (M.A. Bruno), [matipa22@hotmail.com](mailto:matipa22@hotmail.com) (M. Parodi), [ignacio.olmedo88@gmail.com](mailto:ignacio.olmedo88@gmail.com) (I. Olmedo), [piconmolina@hotmail.com](mailto:piconmolina@hotmail.com) (H. Picón Molina), [palencia.rafael@hotmail.com](mailto:palencia.rafael@hotmail.com) (R. Palencia), [marceloadoniquian@gmail.com](mailto:marceloadoniquian@gmail.com) (A. Doniquian).

In 90% of the cases, histoplasmosis is presented as a mild infection or in an asymptomatic way. In the remaining 10%, it may be presented as a serious lung disease and, sometimes, it can be fatal. In immunosuppressed patients, it is presented as a scattered serious disease [5,7,8]. Patients with CD4 counts, which are less than 150 cells/ $\mu$ L, are at most risk [9].

Small intestine CMV location is highly infrequent [1,10–12].

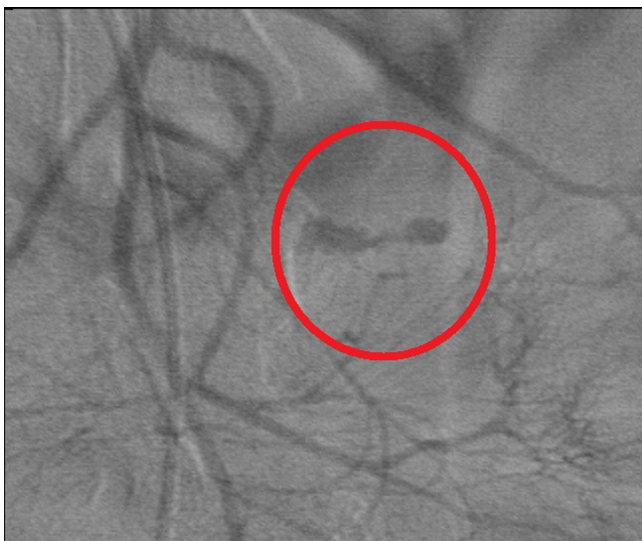The association between Histoplasmosis and CMV as a massive gastrointestinal bleeding cause has not been described. There is no bibliography on the matter.

We will introduce below the case of a 40-year-old patient with AIDS presenting secondary massive lower gastrointestinal bleeding (MLGB) symptoms and ulcer granulomatous injuries located in the proximal ileum produced by the association of CMV and histoplasmosis.

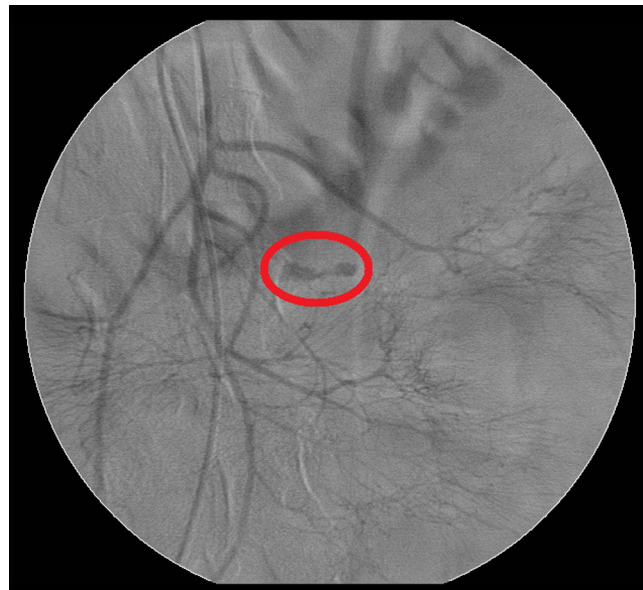
## 2. Report of case

### 2.1. Personal history

40-year-old male patient, with a recent AIDS diagnose (CD4+ 8/ $\text{mm}^3$  and a viral load of 39100 RNA copies– HIV/ml), without antiretroviral therapy and with Herpes Zoster and appendectomy history. The subject has no antecedents of intravenous drug consumption, blood transfusions or risky sexual behavior. At the moment of the admission, the subject had a chest radiograph with



**Fig. 1.** Mesenteric angiography. Bleeding in the third part of the superior mesenteric artery.



**Fig. 2.** Mesenteric angiography. Bleeding in the third part of the superior mesenteric artery.

interstitial reticulonodular infiltrates in both lung fields. During the fifth hospitalization day due to an atypical pneumonia, which had started 15 days before with odynophagia, cough, asthenia, night sweats and progressive dyspnea and being able to rest in the last 24 h, the subject presented hematochezia episodes that led to hemodynamic decompensation, requiring hospitalization in the intensive care unit (ICU) for stabilization, evaluation and nursing.

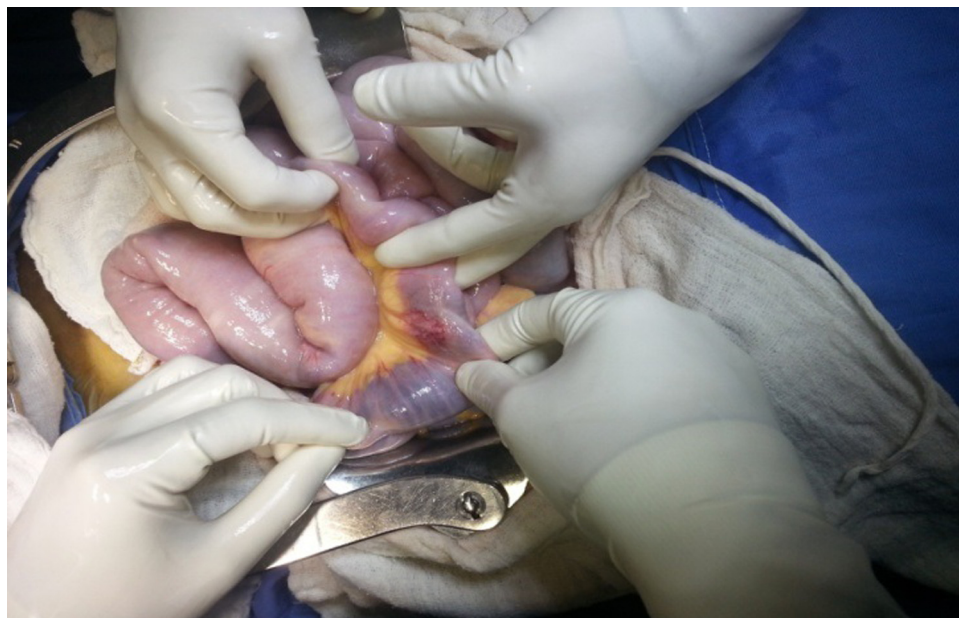
The physical examination revealed an afebrile patient, with low blood pressure (40/80 mm Hg) with tachycardia (110 beats per minute) and sweaty. In addition, the patient presented pale mucous membrane and skin and flat non-distended asymmetrical abdomen due to McBurney's surgical incision. The abdomen was soft, depressible, and not painful upon palpation and with no peritoneal signs. He presented hyperactive bowel sounds, increasing in frequency and intensity and preserved dull liver percussion. The rest was within regular values.

## 2.2. Laboratory

Erythrocytes  $1.8 \times 10^{12}/L$ ; hemoglobin 43 g/L, hematocrit 0.14, leukocytes  $6.3 \times 10^9/L$  (0.66 segmented neutrophils, 0.31 lymphocyte, 0.3 monocytes); urea 18.92 mmol/L; creatinine 104.3  $\mu\text{mol}/L$ ; APP 81%; KPTT 35 s; platelets 154 000; blood sugar 9.88 mmol/L; ionogram in regular values.

## 2.3. Complementary methods

In ICU, after administering volumes with crystalloids and colloids and performing the transfusion of four segmented red blood cells volumes, the patient was stabilised. This made possible the realization of a videocolonoscopy, which, due to technical difficulties, was difficult to evaluate. Subsequently, a mesenteric



**Fig. 3.** Surgery. A  $2 \times 2$  cm tumor was observed in the ileum.

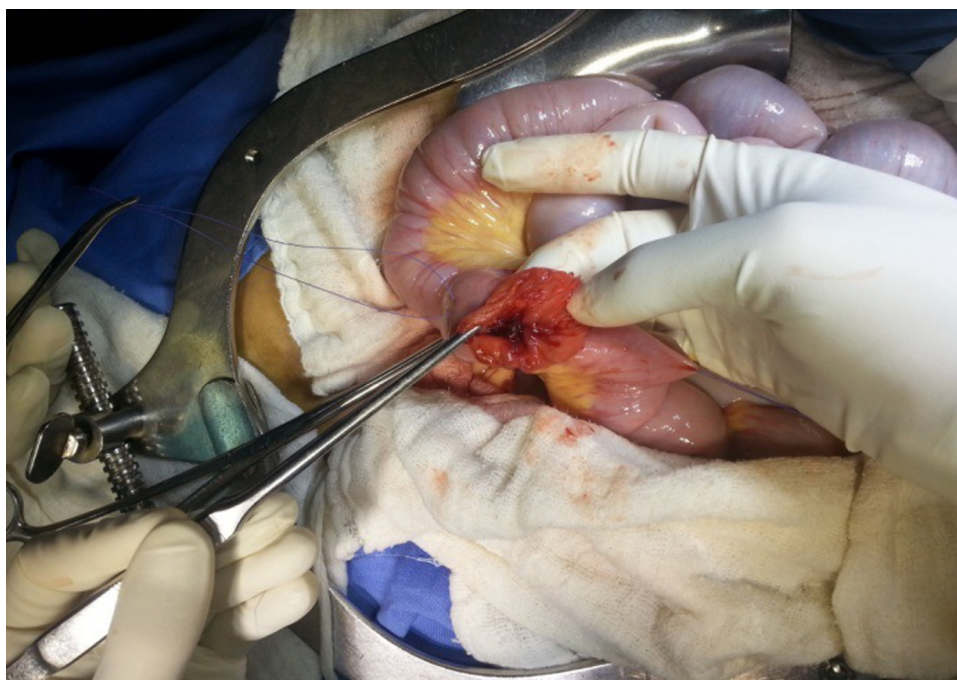


Fig. 4. Surgery. Enterotomy at the level of the tumor related injury.

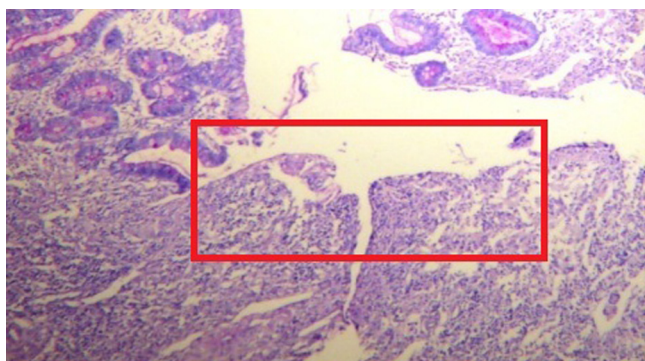


Fig. 5. Ulcers caused by CMV and Histoplasmosis. Intestinal mucous interruption.

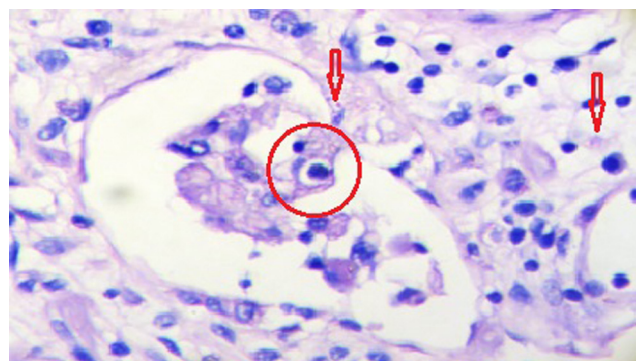


Fig. 6. Circle: Cell with viral cytopathic changes in owl's eyes inclusion in macrophage cause by CMV. Arrows: Histoplasmosis.

angiography test was performed to locate the bleeding section and to evaluate treatment possibilities. This test evidenced active bleeding in the third part of the superior mesenteric artery. Inferior mesenteric and celiac arteries were normal. A diffused bleeding was detected but it was difficult to identify which section of the third part of the mesenteric artery was the responsible vessel (Figs. 1 and 2).

Due to technical difficulties, hemodynamist decided not to perform an embolization to prevent attributing higher morbidity to the procedure.

#### 2.4. Treatment

Etiological diagnosis and massive gastrointestinal bleeding treatment by endoscopy were not possible due to the lack of staff with experience in endoscopic and endovascular techniques in this hospital. A surgery was decided.

An exploratory laparotomy was performed and it evidenced dilated small intestine loops with hematic content. At the ileum level and 3 m from the angle of Treitz, a 2 × 2 cm tumor was evidenced (Fig. 3). It compromised the mesentery and the wall of the ileum. An enterotomy was performed at the tumor-related injury

level (Fig. 4). When active bleeding was detected, a segmental resection and an end-ileostomy were performed. Throughout the explored small intestine, from the angle of Treitz up to the ileocecal valve, multiple tumours with similar characteristics and same size were observed. They did not pose any difficulty during surgery.

The surgical specimen was sent to pathology.

#### 2.5. Clinical course

The patient is in post-surgical ICU and presents good clinical course. He is hemodynamically stable, febrile and with good oral tolerance.

#### 2.6. Anatomical pathology

Ulcer injuries with inclusions compatible with infections by Cytomegalovirus spp (Figs. 5 and 6). A granulomatous reaction with microorganisms compatible with Histoplasma spp (Fig. 6).

A treatment with Ganciclovir is initiated for Cytomegalovirus and with Amphotericin B for Histoplasma. The response is positive.

### 3. Discussion

Gastrointestinal bleedings come from the small intestine in less than the 5% [13].

Treatment procedures through endoscopy or arteriogram are not always possible since they have high levels of failure and are not exempt from serious complications.

CMV affects 90% of patients with AIDS during their disease. Infection by CMV is not common if CD4 absolute count exceeds 100 cel/ml [10,14]. The infection can manifest in various ways. Gastrointestinal CMV infection can be part of a widespread infection or it can remain isolated in the gastrointestinal tract. The most affected regions are the colon, the esophagus and the stomach. Distal small intestine condition is rare (0–1.4%) [1]. CMV typically presents injuries that are similar to ulcers and that erode arteries producing massive gastrointestinal bleeding. Generally, these injuries are located in the cecum. Islet-shaped ulcers located in the ileum are extremely rare [5,15].

CMV and Histoplasmosis association as the responsible of lower gastrointestinal bleeding is infrequent. There is no bibliography on the matter.

An 85% of the patients presenting lower gastrointestinal bleeding stop bleeding spontaneously. The remaining 15% continue bleeding abundantly and require resuscitation, examination and emergency treatment [5,12,13].

When bleeding location is known, segmental resection guarantees recovery with a mortality rate below 3–5% [12,15] and a recurrence rate of 2%–10% [15].

### 4. Conclusion

Lower digestive bleeding is a nosologic entity that poses a challenge regarding diagnose and treatment considering the intestine extension and difficulties for exploration.

Treatment for this pathology shall have a multidisciplinary, coordinated and forceful approach since the time that elapses until diagnose and treatment decision is extremely important.

### Conflict of interest

Authors state not presenting any conflict of interest in the production, presentation and dissemination of this paper.

### Acknowledgement

Special thanks to Dr. Gabriela Sambuelli from the anatomical pathology service, Clínica Universitaria Reina Fabiola, for her contribution with terms from the field of histology.

### References

- [1] F.H. Weber Jr, H.F. Frierson Jr, B.M. Myers, Cytomegalovirus as a cause of isolated severe ileal bleeding, *J. Clin. Gastroenterol.* 14 (1992) 52–55.
- [2] Vinay Kumar, K. Abul Abbas, Nelson Fausto, *Patología estructural y funcional de Robinson y Cotran*, 7ma edición, Edición es español, Editorial Elsevier, Madrid España, 2006.
- [3] Stephen E. Dolgin, John G. Larsen, Kumudini D. Shah, Elmer David, CMV enteritis causing hemorrhage and obstruction in an infant with AIDS, *J. Pediatr. Surg.* 25 (1990) 696–698.
- [4] Philip H. Gordon, Santhat Nivatvongs, *Principles and Practice of Surgery for the Colon Rectum and Anus*, 3rd ed., Informa Healthcare, Nueva York USA, 2007.
- [5] P. Farreras, C. Rozman, *Medicina Interna*, 16ta edición, Editorial Elsevier, Barcelona España, 2009.
- [6] J.F. Murray, J. Mills, Pulmonary infectious complications of human immunodeficiency virus infection, *Am. Rev. Respir. Dis.* 141 (6) (1990) 1582.
- [7] R.A. Goodwin Jr, J.L. Shapiro, G.H. Thurman, S.S. Thurman, Disseminated histoplasmosis: clinical and pathologic correlations, *Medicine (Baltimore)*. 59 (1) (1980) 1.
- [8] L.J. Wheat, P.A. Connolly-Stringfield, R.L. Baker, M.F. Curfman, M.E. Eads, Disseminated histoplasmosis in the acquired immune deficiency syndrome: clinical findings, diagnosis and treatment, and review of the literature, *Medicine (Baltimore)*. 69 (6) (1990) 361.
- [9] Carol A. Kauffman, Histoplasmosis: a clinical and laboratory update, *Clin. Microbiol. Rev.* 20 (January (1)) (2007) 115–132.
- [10] A.T. Mathew, P. Zacharias, S. Ponnambathayil, A. Kumar, L. Madhavan, M.y. Harris, et al., Massive gastrointestinal bleeding in a patient with AIDS, *Natl. Med. J. India* 18 (March–April (2)) (2005) 76–77.
- [11] R.S. Chamberlain, S. Atkins, N. Saini, J.C. White, Ileal perforation by cytomegalovirus infection in a critically ill adult, *J. Clin. Gastroenterol.* 30 (4) (2000) 432.
- [12] Mariano Gimenez. *Cirugía, Fundamentos para la práctica clínico-quirúrgica*. 1er edición. Editorial médica Panamericana, Buenos Aires, Argentina, 2014.
- [13] Courtney Townsend, Daniel Beauchamp, Mark Evers, Kenneth Mattox, *Sabiston Textbook of Surgery: The Biological Basis of Modern Surgical Practice*. Edición en español. 19 ed. Editorial Elsevier, Barcelona España, 2013.
- [14] R. Vialle, G. Burdy, O. Drain, M. Bernier, P. Frileux, Cytomegalovirus enterocolitis: a rare cause of gastrointestinal ischemia and bleeding, *Gastroenterol. Clin. Biol.* 29 (2005) 1057–1059.
- [15] F. Bruncardi, Dana Andersen, Timothy Billiar, David Dunn, John Hunter, Jeffrey Matthews, E. Raphael Pollock, *Schwartz's Principles of Surgery*, 8th edition, 2016.

### Open Access

This article is published Open Access at [sciendo.com](http://sciendo.com). It is distributed under the [IJSCR Supplemental terms and conditions](#), which permits unrestricted non commercial use, distribution, and reproduction in any medium, provided the original authors and source are credited.