

Contents lists available at [ScienceDirect](http://www.sciencedirect.com)

International Journal of Surgery Case Reports

journal homepage: www.casereports.com

Successful management using airway pressure release ventilation for severe postoperative pulmonary edema



Yoshihisa Morimoto (MD, PhD)*, Takaki Sugimoto (MD, PhD), Hiroki Arase (MD), Fumiya Haba (MD)

Division of Cardiovascular Surgery, Awaji Medical Center, Hyogo, Japan

ARTICLE INFO

Article history:

Received 3 May 2016

Received in revised form 8 August 2016

Accepted 8 August 2016

Available online 28 August 2016

Keywords:

Severe hypoxia

Pulmonary edema

Airway pressure release ventilation (APRV)

Extracorporeal membrane oxygenation (ECMO)

Postoperative complication

ABSTRACT

INTRODUCTION: Postoperative pulmonary edema is a fatal adverse event after a cardiac surgery. We here report successful management using airway pressure release ventilation (APRV) for severe hypoxia with pulmonary edema after a cardiac surgery.

PRESENTATION OF CASE: A 58-year-old man underwent an uneventful mitral valve repair. Immediately afterwards, the patient became agitated and made vigorous inspiratory efforts. His oxygen saturation dropped to 90%. Coarse inspiratory rhonchi were heard on auscultation, and copious, pink, frothy sputum was obtained with suctioning. Initial chest radiograph showed right-sided patchy opacities and interstitial infiltrates. A transthoracic echocardiogram demonstrated normal cardiac function. With worsening respiratory failure on mechanical ventilation, APRV was attempted. His condition and blood gas was subsequently improved. Over the following 3 days, the patient experienced an uneventful postoperative course and was discharged to home on postoperative day 14.

DISCUSSION: Extracorporeal membrane oxygenation (ECMO) is the most effective for severe hypoxia with pulmonary edema; however, ECMO is associated with hemorrhage and infectious complications. Alternatively, APRV was required for the successful management for severe hypoxia with pulmonary edema.

CONCLUSION: APRV could be effective for severe hypoxia with pulmonary edema after a cardiac surgery.

© 2016 The Author(s). Published by Elsevier Ltd on behalf of IJS Publishing Group Ltd. This is an open access article under the CC BY-NC-ND license (<http://creativecommons.org/licenses/by-nc-nd/4.0/>).

1. Introduction

Severe postoperative pulmonary edema is a fatal adverse event after a cardiac surgery. Conventional ventilator therapy with administration of some medications may be used for treatment of mild cases. However, there is no definitive treatment method for severe cases. Extracorporeal membrane oxygenation (ECMO) is the most effective tool for severe hypoxia with pulmonary edema [1].

There is no previous literature on Airway pressure-release ventilation (APRV) in patients with severe postoperative pulmonary edema. APRV is a novel mode of positive-pressure ventilation that has several advantages over low-tidal-volume, assist-control ventilation in patients with acute respiratory distress syndrome [2]. There are few clinical trials showing that APRV is able to provide improved gas exchange, and it is unclear if APRV results in improved clinical outcomes or worsen lung injuries.

We here report successful management using APRV for postoperative pulmonary edema after a cardiac surgery.

2. Case report

A 58-year-old man with a history of severe mitral valve regurgitation was admitted to our institution for a mitral valve repair. Chest x-ray confirmed no pulmonary edema. After transesophageal echocardiography (TEE) demonstrated severe MR, the patient was scheduled for elective surgery. Subsequently, the patient underwent an uneventful mitral valve repair.

Following the procedure, the patient was transferred to the intensive care unit. Immediately afterwards, the patient became agitated and exhibited vigorous inspiratory efforts. His oxygen saturation dropped to 90%. At that time he was ventilated using pressure control continuous mandatory ventilation (PC-CMV) with an inspiratory pressure (above PEEP) of 25 cm H₂O, PEEP = 15 cm H₂O, and FiO₂ = 1.0. Coarse inspiratory rhonchi were heard on auscultation, and copious, pink, frothy sputum was obtained with suctioning. Blood gas demonstrated a pH of 7.33, PaCO₂ of 40, PaO₂ of 71, and a bicarbonate level of 22. The initial portable chest radiograph showed right-sided patchy opacities and interstitial infiltrates (Fig. 1). A transthoracic echocardiogram demonstrated normal cardiac function. The patient was intravenously treated with furosemide (40 mg/day) and methylprednisolone (125 mg/day). With worsening respiratory failure

* Corresponding author at: Division of Cardiovascular Surgery, Awaji Medical Center, 1-1-137 Shioya, Sumoto, Hyogo, 656-0021, Japan.
E-mail address: yoshimor@gmail.com (Y. Morimoto).

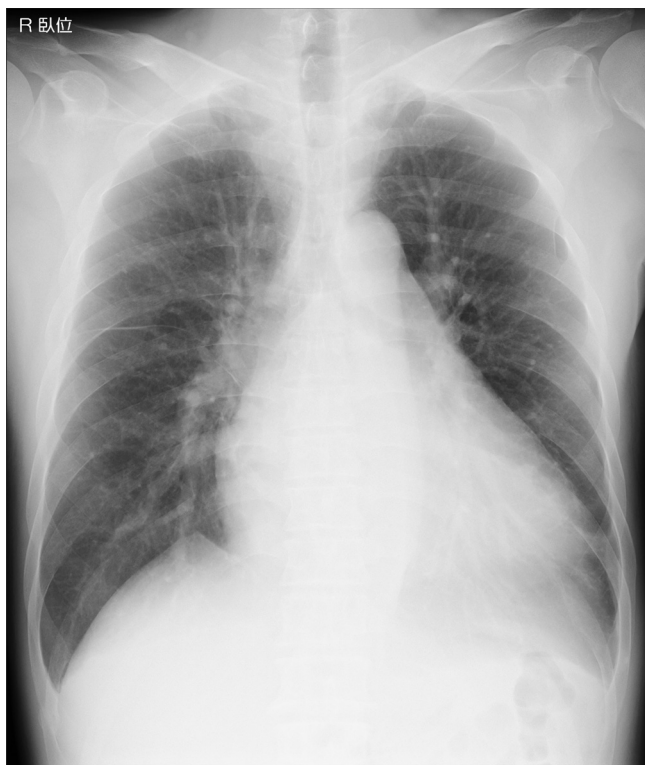

Fig. 1. An initial portable chest radiograph postoperatively showed right-sided patchy opacities and interstitial infiltrates.

Table 1
Hemodynamic and ventilatory parameters on pressure-controlled mechanical ventilation (PCMV) and after switching to airway pressure release ventilation (APRV).

	PCMV	APRV
BP mmHg	78/42(56)	83/45(60)
PAP mmHg	32/12	33/11
CVP mmHg	13	17
Ventilator rate/min	12	9
Mean airway pressure cmH2O	10	23
Peak pressure	28	30
Vt (exhaled)	600	630
pH	7.33	7.38
PaO2	71	92
PaCO2	40	38

BP: blood pressure, PAP: pulmonary artery pressure, CVP: central venous pressure, Vt: tidal volume.

on mechanical ventilation, APRV was attempted on postoperative day 1. Settings of APRV were P high = 30 cm H₂O, P low = 5 cm H₂O (inspiratory pressure = 25 cm H₂O) T high = 6.4 s, and T low = 0.5 s, which resulted in a mandatory breath frequency of 9 breaths/min. He was able to take spontaneous breaths on the APRV mode and sedative requirements were decreased. His hemodynamic condition was not altered under APRV (Table 1).

Over the following days his P high and length spent on high pressure (T high) were manipulated in order to maintain oxygenation. His condition and blood gas subsequently improved. pH of 7.43, PaCO₂ of 42, PaO₂ of 144, and a bicarbonate level of 22 was observed. His sputum was also decreased. Chest radiography showed that the right-sided infiltrates were insignificantly changed (Fig. 2). By postoperative day 2, the patient's respiratory parameters and blood gas parameters had improved, and he was successfully extubated. Over the following 3 days, the patient experienced an uneventful postoperative course and was discharged to home on postoperative day 14. A chest radiograph before the discharge showed right-sided infiltrates were significantly improved

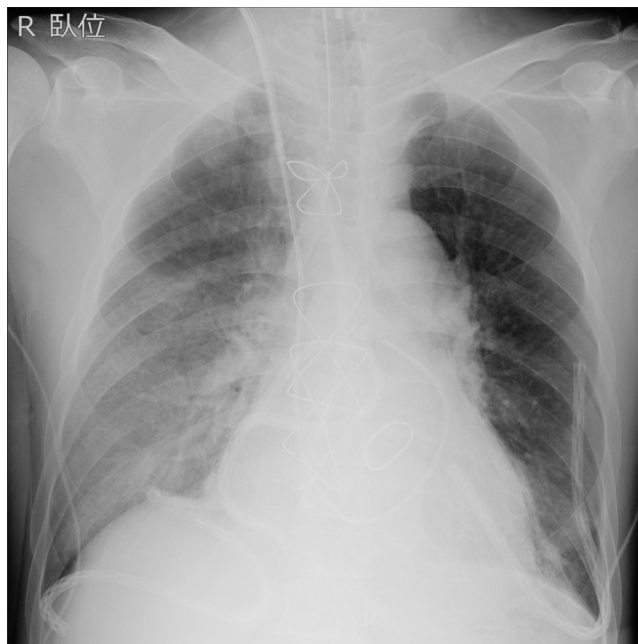


Fig. 2. A chest radiograph after the extubation showed right-sided infiltrates were insignificantly changed on postoperative day 2.

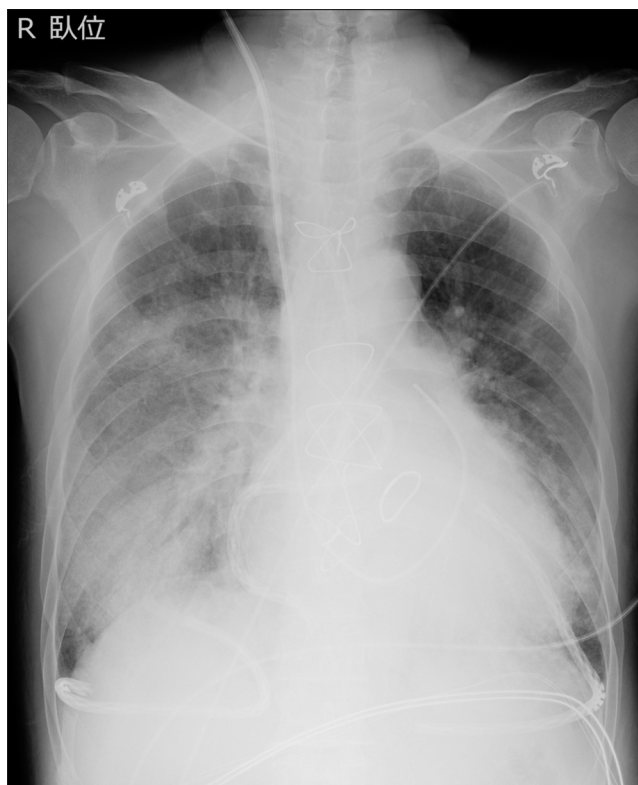


Fig. 3. A chest radiograph before the discharge showed right-sided infiltrates were significantly improved on postoperative day 10.

on postoperative day 10 (Fig. 3). Two weeks later, patient had no complaints at his postoperative follow-up visit.

3. Discussion and conclusion

Postoperative pulmonary edema is a well-known postoperative complication especially following minimally invasive cardiac

surgery that combines right minithoracotomy. In most cases, the complication clear over several days and management of hypoxia is most important.

In a subset of patients with severe pulmonary edema, standard ventilatory strategies may be unable to maintain adequate arterial oxygenation. ECMO is the most effective for severe hypoxia with pulmonary edema [1]. However, ECMO is associated with hemorrhage and infectious complications. There are two case reports using high frequency jet ventilation and asynchronous differential lung ventilation for this disorder [3,4]. These treatments need the special ventilator. In our case, conventional supportive care, including mechanical ventilation using high PEEP, diuretics, steroids, and inotropic drugs, was ineffective. Alternatively, APRV was required for the successful management of the patient.

Given the difficulty in oxygenation, we believe that the use of APRV in our patient resulted in improved oxygenation and ventilation. APRV is well tolerated by patients, requires minimal sedation and allows spontaneous breathing, which improves ventilation-perfusion mismatching and cardiac performance [5].

APRV may be an ideal ventilatory mode in patients after cardiac surgery with severe hypoxia due to pulmonary edema, as the increased mean alveolar pressure with short release time (time low) will recruit collapsed, dependent lung while preventing overdistention of ventilated alveoli. We believe that APRV should be considered as an alternative ventilator strategy in patients after cardiac surgery with severe hypoxia due to postoperative pulmonary edema. There is no previous literature on APRV for postoperative pulmonary edema. APRV aids pulmonary dysfunction management by maximizing alveolar recruitment while limiting the transalveolar pressure gradient, thereby lessening the risk of barotrauma [6]. Given the difficulty in oxygenation, the use of APRV for postoperative pulmonary edema may improve oxygenation and ventilation without any special ventilator or ECMO.

We believe that APRV should be considered as an alternative strategy for severe hypoxia with postoperative pulmonary edema instead of ECMO.

Conflict of interest

We have no COI.

Funding

We have no funding.

Ethical approval

The institutional review board in Awaji medical center approved the study.

Consent

We had consent to publish a case report.

Author contribution

Y. Morimoto : study concept, data collection, interpretation, writing the paper.

T. Sugimoto : study concept, interpretation.

H. Arase and F. Haba : data collection.

Guarantor

Takaki Sugimoto.

References

- [1] A.L. Shires, T.M. Green, H.L. Owen, T.N. Hansen, Z. Iqbal, S. Markan, et al., Severe reexpansion pulmonary edema after minimally invasive aortic valve replacement: management using extracorporeal membrane oxygenation, *J. Cardiothorac. Vasc. Anesth.* 23 (2009) 549–554.
- [2] T.R. Myers, N.R. MacIntyre, Respiratory controversies in the critical care setting. Does airway pressure release ventilation offer important new advantages in mechanical ventilator support? *Respir. Care* (52) (2007) 452–458.
- [3] M. Waga, Y. Sanagawa, Y. Okamoto, A case of anesthetic management for re-expansion pulmonary edema of the dependent lung saved by superimposed HFJV during one lung ventilation for the thoracoscopic operation associated with bilateral pneumothorax, *Masui* 49 (2000) 643–645.
- [4] S.R. Cho, J.S. Lee, M.S. Kim, New treatment method for reexpansion pulmonary edema: differential lung ventilation, *Ann. Thorac. Surg.* 80 (2005) 1933–1934.
- [5] C. Putensen, N.J. Mutz, G. Putensen-Himmer, J. Zinserling, Spontaneous breathing during ventilatory support improves ventilation-perfusion distributions in patients with acute respiratory distress syndrome, *Am. J. Respir. Crit. Care Med.* 159 (1999) 1241–1248.
- [6] M. Sydow, H. Burchardi, E. Ephraim, S. Zielmann, T.A. Crozier, Long-term effects of two different ventilatory modes on oxygenation in acute lung injury. Comparison of airway pressure release ventilation and volume-controlled inverse ratio ventilation, *Am. J. Respir. Crit. Care Med.* 149 (1994) 1550–1556.

Open Access

This article is published Open Access at [sciencedirect.com](https://www.sciencedirect.com). It is distributed under the [IJSCR Supplemental terms and conditions](#), which permits unrestricted non commercial use, distribution, and reproduction in any medium, provided the original authors and source are credited.