


Contents lists available at ScienceDirect

Urology Case Reports

journal homepage: www.elsevier.com/locate/eucr

Pediatrics

Advanced Uropathy in a Child With Underactive Bladder: Unusual Presentation, Treatment, and Long-term Follow Up



Rami S. Alazab*, Rola S. Saqan, Faris Abu Shamma

Faculty of Medicine, Jordan University of Science and Technology, Irbid 22110, Jordan

ARTICLE INFO

Article history:

Received 3 December 2014

Received in revised form

11 December 2014

Accepted 12 December 2014

Available online 17 January 2015

Keywords:

Lazy-bladder syndrome

Underactive bladder

Vesico-ureteral reflux

Voiding dysfunction

ABSTRACT

Underactive bladder in children is characterized by low voiding frequency; straining, hypotonic high capacity bladder, and significant residual urine. The usual presentation is recurrent urinary tract infections. Accurate evidence-based diagnosis and treatment is crucial. Subjective and objective improvement and regain of normal voiding can be achieved in response to bladder rehabilitation program and correction of serious complications.

© 2015 The Authors. Published by Elsevier Inc. This is an open access article under the CC BY-NC-ND license (<http://creativecommons.org/licenses/by-nc-nd/4.0/>).

Introduction

Abnormal micturition patterns can be acquired during the early life; they are not necessarily associated with neurological or anatomical abnormalities. Their usual presentation is recurrent urinary tract infection (UTI), accurate diagnosis and appropriate treatment plan can lead to improvement or recovery. Here we report a case with unusually late presentation of dysfunctional voiding; atypical course and destructive uropathy, along with long-term treatment and follow up.

Case report

A 10-year-old boy was referred with right pyelonephritis, bilateral hydronephrosis and distended bladder. Foley catheter drained 1200 cc of clear urine. Serum creatinine was high normal (58 mmol/L). After successful control of UTI by parenteral antibiotics, patient discharged with Foley catheter, prophylactic antibiotics, and stool softener. Past history indicated secondary nocturnal enuresis for 1 year, no constipation, no previous UTIs or admissions; Prior to his presentation patient voided rarely (once or twice daily and he attributed this to not feeling that his bladder is

full), his family reported that it started at school age when the patient was avoiding using public toilets and prefer to hold his urine until he comes back home, then they noticed that he gradually needed more time to void, general Physical examination was normal.

Micturition cystourethrogram (MCUG) and DMSA scans were performed 1 month later. MCUG ([Fig. 1](#)) indicated Right grade 5 VUR with secondary pelvi-ureteral Junction (PUJ obstruction), Left grade 4 VUR, and distended bladder with diverticuli. The urethra could not be assessed because patient could not void.

DMSA-scan ([Fig. 2](#)) showing severe impairment of the right kidney with split function of 7% on the Right and 93% on the Left. Neurological evaluation reported as normal by a pediatric neurologist, Lumbosacral spine MRI was normal. Diagnostic Cystourethroscopy showed normal urethra, huge urinary bladder with diverticuli, and golf-hole ureteric orifices, Intravenous pyelography revealed sac-like Right kidney. The function of the right kidney was also calculated by 24-urine collection via the right nephrostomy tube which revealed creatinine clearance-corrected of 5 mL/min/1.73 m².

Few days later, patient returned with right pyonephrosis, Nephrostomy tube inserted, Two weeks later Right side laparoscopic nephroureterectomy was performed; 10 cm of the right ureter was left to divert vesical pressure away from the left reflexive ureter.

Initial video-assisted urodynamic study (UDS) ([Fig. 3](#) upper) indicated delayed sensation, high bladder capacity (750 cc), no

* Corresponding author. Tel.: +962 796515808.

E-mail addresses: ramiazab@gmail.com, ramiazab@yahoo.com (R.S. Alazab).

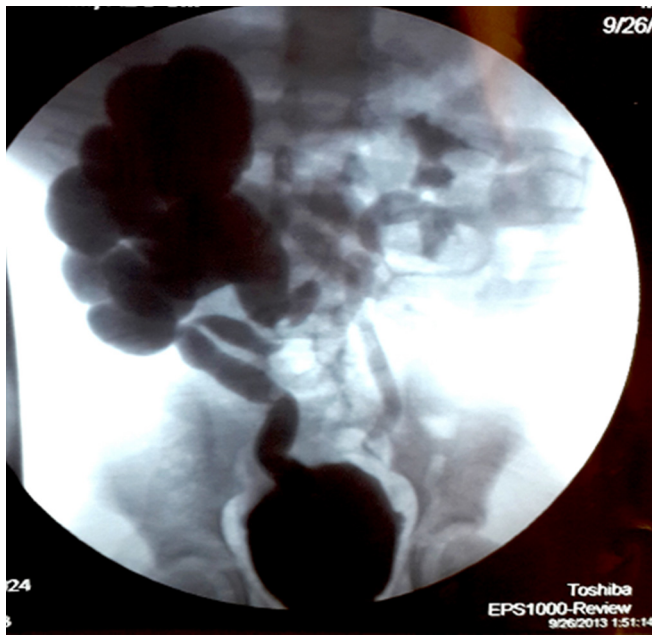


Figure 1. Voiding cystourethrogram after treatment of severe pyelonephritis showing Grade 5 right vesicoureteral reflux and grade 4 left vesicoureteral reflux.

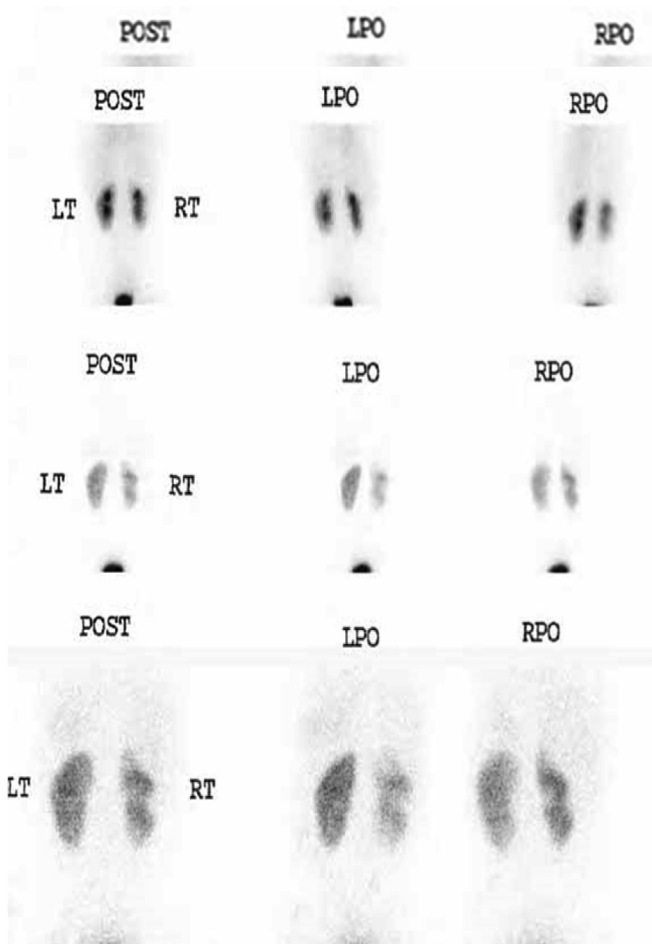


Figure 2. DMSA-scan showing severe impairment of the right kidney compared split function reported as 7%.

detrusor contraction, passive left VUR, and VUR into remnant right ureteric stump, with end-filling detrusor pressure (Pdet) <5–7 cm/H₂O, voiding phase could not be assessed, and detrusor pressure did not change during patient's attempts to void.

Patient was trained to perform clean intermittent catheterization (CIC) every 3–4 hours during daytime and indwelling Foley catheter overnight. Three months later, at 3 months, ultrasound showed no hydronephrosis, and MCUG indicated grade 3 left VUR. At Six months MCUG showed persistence of left VUR. Bulking agent (VANTRIS®) was injected into both ureteric orifices via STING procedure. MCUG 3 months after the procedure indicated no further VUR.

At 9 months of follow-up, video-assisted UDS (Fig. 3 lower) demonstrated normal bladder sensation (first sensation at 109 cc, first desire at 200 cc, strong desire at 334 cc, MCC at 348 cc). Pdet 5–8 cm/H₂O, No phasic detrusor contraction, VUR, or leak during filling phase. Pdet rose to 30 cm/H₂O, Q-max of 15 mL/s, voided volume = 300 cc with minimal post-void residual urine (PVRU).

Patient was asked to continue timed voiding and CIC after each void. The schedule was maintained over 6 months; his voiding diary indicating good stream, PVRU ≤30–40 cc and the disappearance of nocturnal enuresis. Normal Serum creatinine (in the range of 50–60 mmol/L normal as per pediatric nephrology), patient blood pressure was normal all through treatment course and no break-through UTIs.

Discussion

The International Children's Continence Society (ICCS) aiming to clarify semantic confusion associated with the terminology of voiding dysfunction in children replaced the term "lazy bladder" with the neutral term underactive bladder.¹ While According to the International Continence Society (ICS), underactive bladder is defined as a contraction of reduced strength and/or duration, resulting in prolonged and incomplete bladder emptying,² the common denominator is an inability or reduced ability to empty.

It is unusual to present with severe UTI with underactive bladder; diagnosis is based on careful history imaging and UDS. Successful management relies on long-term training. Our plan entailed removal of non-functioning kidney, leaving ureteric stump as a pop-off mechanism to protect the left kidney; along with rehabilitating the bladder, and treatment of bilateral VUR with bulking agent.

Regular voiding aimed at maintaining low pressure, improved detrusor contractility and bladder emptying. Some children eventually wean from CIC. Reliability of the patient and his family is a cornerstone of management, recognition of complications and providing psychological support for the child, as treatment is lengthy and does not depend solely on pharmacological agents.

Dysfunctional voiding is commoner in girls, staccato and interrupted stream occur with inappropriate relaxation of pelvic floor during voiding. Residual urine is increased gradually. Loss of feeling of the filling state of both the bladder and the rectum characterizes dysfunctional voiding, and incontinence caused by voiding postponement³; dysfunctional voiding is a specific condition in neurologically normal individuals, and does not refer to the storage phase, characterized by habitual contraction of the external urethral sphincter during voiding, diagnosis requires evidence of external sphincter overactivity during voiding.⁴ Hoebeke et al reported an expanded bladder capacity and hypocontractility in only 4% of the children studied.⁵

Detrusor underactivity is characterized by a low pressure and poorly sustained or wavelike detrusor contraction with poor flow rate. Glassberg et al proposed that the term "underactive bladder" "to be inappropriate without UDS and simultaneous pelvic floor EMG during uroflow studies; these bladders are better described as "detrusor underutilization disorder" (DUD) implying inactivity and

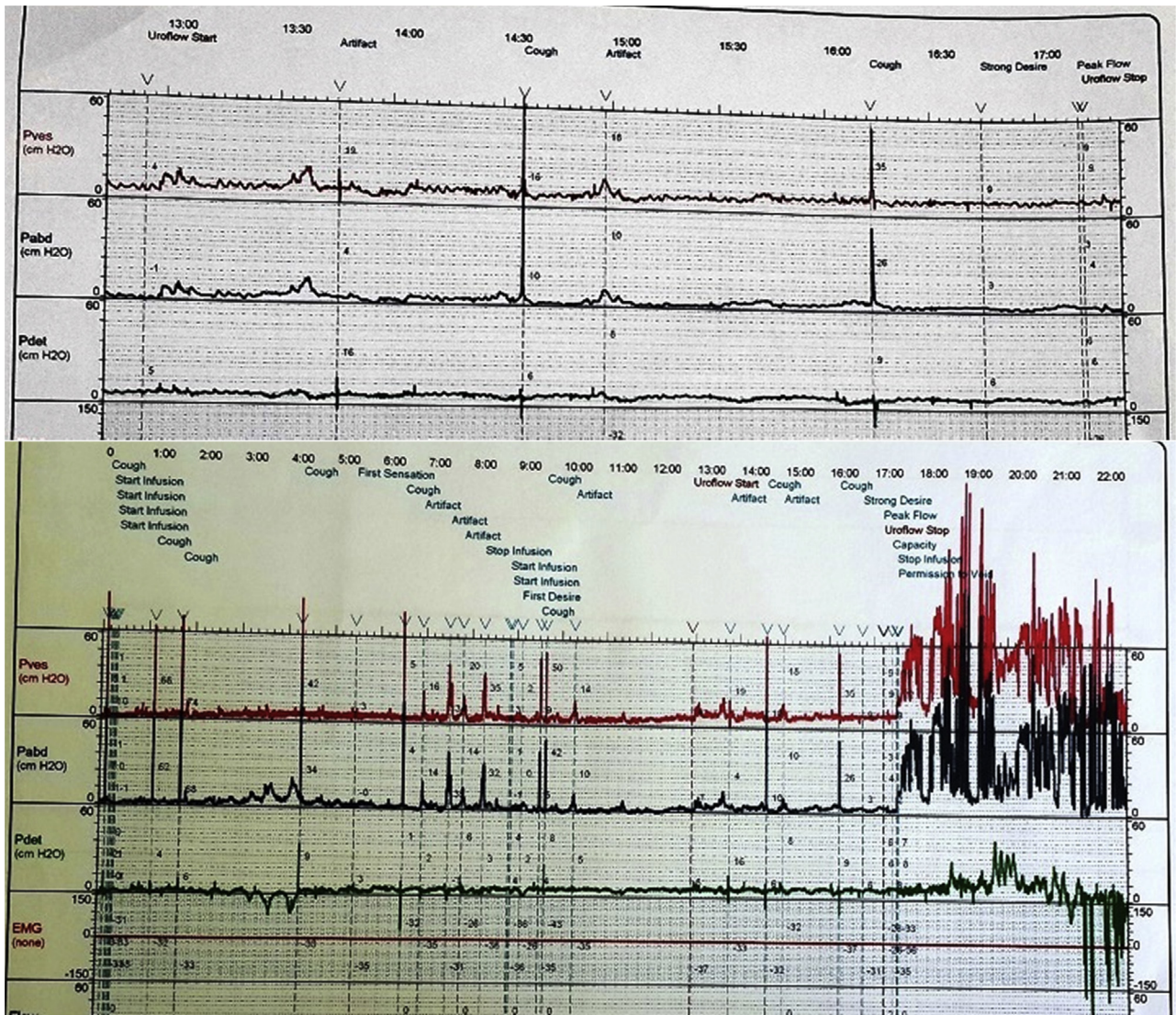


Figure 3. Urodynamic studies, 1 – At presentation (Above) showing very low detrusor pressure with filling, the patient was unable to void, 2 – After rehabilitation showing some detrusor activity and increased intravesical pressure after reaching 200 cc; the increased IV-pressure is attributed as shown to increase in both detrusor and abdominal pressure.

lack of effort.⁴ The coexistence of VUR and detrusor overactivity or uncoordinated detrusor-sphincter function during micturition correlates with the non-resolution of high-grade, which may lead to advanced uropathy.

Conclusion

Accurate diagnosis and categorization of voiding dysfunction is mandatory for planning management. In our case, perseverance, patient and family motivation in addition to long-term treatment management resulted in bladder rehabilitation and reversal of bladder underactivity with minimal surgical cost.

Conflict of interest

This case report was done in the division of urology for academic purposes and was not funded by any external fund, the submission

has no commercial interests, and the authors of this case report are not linked to any external agencies.

References

1. Nevés T, von Gontard A, Hoebeke P, et al. The standardization of terminology of lower urinary tract function in children and adolescents: Report from the Standardisation Committee of the International Children's Continence Society. *J Urol.* July 2006;176:314–324.
2. Abrams P, Cardozo L, Fall M, et al. The standardisation of terminology of lower urinary tract function: report from the standardisation subcommittee of the international continence society. *Neurourol Urodyn.* 2002;21:167e78.
3. de Jong Tom PVM, Klijn Aart J, Vijverberg Marianne AW. Lower urinary tract dysfunction in children. *Eur Urol Suppl.* 2012;11:10–15.
4. Glassberg Kenneth I, Combs Andrew J. Rethinking current concepts and terminology in lower urinary tract dysfunction. *J Pediatr Urol.* 2012;8:454–458.
5. Hoebeke P, Van Laecke E, Van Camp C, et al. One thousand video-urodynamic studies in children with non-neurogenic bladder sphincter dysfunction. *BJU Int.* 2001;87:575.